

Dr. Jayesh Timane
DNB (Gen.Medicine), EDIC
Sr. Consultant Physician
Reg No -2021031063

Date :

Name : Dhiraj Bhoyar 34/male.

UHID : WKM 2. 339 716

Primary Diagnosis : Chyloleak
सिलेज (N)
पाचन त्रुटि

Brief Complaints :

R_x

T. Eggact (60) खोले ? # 10

T-Afebrile / Febrile	___ OF
P-	___ / min
R-	<u>18</u> / min
B.P.	<u>120 / 80</u> mmHg
Pain - Yes / No	___
Fall Risk : Yes / No	___

CBC ✓
HbA1c FBS
PMS ✓
KFT. ✓
CHO 179 TAG 161.
TFT ✓
LFT ✓
X-ray ✓
USG ✓
ECG ✓
2DE ✓
Fundus ✓

Adv
Lipid profile
S-vit B12
S-vit D

FOLLOW-UP AFTER
___ DAYS

HT
09-06-2023



DEPARTMENT OF LABORATORY MEDICINE

HEMATOLOGY

Final Report

Patient Name : MR. DHIRAJ R BHOYAR
 Age / Sex : 34 Years / Male
 UHID : WHN2.0000339716
 Primary Consultant : DR.WOCKHARDT DOCTOR
 Order No. : 8922
 Bill No. : OCR3/24/0000974
 Order Date : 09/06/2023 08:44 AM
 Sample Collection : 09/06/2023 08:48 AM
 Report Date : 09/06/2023 11:12 AM
 Specimen : EDTA Blood

PARAMETER	METHOD	RESULT	UNIT	B.R.I
MEDIWHEEL FULL BODY HCU MALE AND FEMALE BELOW 40				
Complete Blood Count (With ESR)- EDTA Blood				
Haemoglobin	SLS Method	14.0	g%	11-15
Haematocrit	RBC Pulse Height Detection	42.7	%	40 - 50
MCV	Calculated	84.6	fl	83-101
MCH	Calculated	27.7	pg	27-32
MCHC	Calculated	32.8	g/dl	32-35
RBC Count	DC Detection	5.05	Million/ul	4.5-5.5
RDW-CV	Calculated	12.9	%	12-14
WBC Total Count (TLC)	Electrical Impedance	5650	Cells/cumm	4000 - 10000
Neutrophils	Hydrodynamic Focussing And Microscopy	41	%	40-80
Lymphocytes	Hydrodynamic Focussing And Microscopy	48	%	20-40
Monocytes	Hydrodynamic Focussing And Microscopy	08	%	2-10
Eosinophils	Hydrodynamic Focussing And Microscopy	03.	%	0-6
Basophils	Hydrodynamic Focussing And Microscopy	00	%	0-2
Platelet Count	Hydrodynamic Focusing DC	296	Thou/Cumm	150-450
MPV	Calculated	9.7	fl	9.4-12.3
Neutrophil Lymphocyte Ratio		0.85		
Leucocytes		Lymphocytosis		



DEPARTMENT OF LABORATORY MEDICINE

HEMATOLOGY

Final Report

Patient Name	: MR. DHIRAJ R BHOYAR	Order Date	: 09/06/2023 08:44 AM
Age / Sex	: 34 Years / Male	Sample Collection	: 09/06/2023 08:48 AM
UHID	: WHN2.0000339716	Report Date	: 09/06/2023 11:12 AM
Primary Consultant	: DR.WOCKHARDT DOCTOR	Specimen	: EDTA Blood
Order No.	: 8922		
Bill No.	: OCR3/24/0000974		

<u>PARAMETER</u>	<u>METHOD</u>	<u>RESULT</u>	<u>UNIT</u>	<u>B.R.I</u>
------------------	---------------	---------------	-------------	--------------


MEDIWHEEL FULL BODY HCU MALE AND FEMALE BELOW 40

Complete Blood Count (With ESR)- EDTA Blood

Blood ESR	Westergren Method	04	mm/hr	0-15
-----------	-------------------	----	-------	------

--- END OF REPORT ---

SONAL BHAIARE
Verified By


Dr. Alka Thool
Consultant Pathologist
M.B.B.S, MD PATH

Partial Reproduction of Report not permitted. This Report Relates to Sample received by Laboratory
* B.R.I - BIOLOGICAL REFERENCE INTERVAL ** Test not in Scope of Accreditation



DEPARTMENT OF LABORATORY MEDICINE

BIOCHEMISTRY

Final Report

Patient Name	: MR. DHIRAJ R BHOYAR	Order Date	: 09/06/2023 08:44 AM
Age / Sex	: 34 Years / Male	Sample Collection	: 09/06/2023 08:48 AM
UHID	: WHN2.0000339716	Report Date	: 09/06/2023 11:12 AM
Primary Consultant	: DR.WOCKHARDT DOCTOR	Specimen	: EDTA Blood
Order No.	: 8922		
Bill No.	: OCR3/24/0000974		

PARAMETER	METHOD	RESULT	UNIT	B.R.I
MEDIWHEEL FULL BODY HCU MALE AND FEMALE BELOW 40				
Glycosylated Haemoglobin- EDTA Blood				
Glycosylated Haemoglobin	HPLC	5.3	%	Action required: 7.0-8.0% Good control: 6.5-7.0% Normal control: 4.8-6.4% Poor control: >8.0%
Estimated Mean glucose	Calculated	111.38	mg/dL	

--- END OF REPORT ---



Dr. Alka Thool
Consultant Pathologist
M.B.B.S, MD PATH

SONAL BHAI SARE
Verified By

Partial Reproduction of Report not permitted. This Report Relates to Sample received by Laboratory
* B.R.I - BIOLOGICAL REFERENCE INTERVAL ** Test not in Scope of Accreditation



DEPARTMENT OF LABORATORY MEDICINE

BIOCHEMISTRY

Final Report

Patient Name	: MR. DHIRAJ R BHOYAR	Order Date	: 09/06/2023 08:44 AM
Age / Sex	: 34 Years / Male	Sample Collection	: 09/06/2023 08:48 AM
UHID	: WHN2.0000339716	Report Date	: 09/06/2023 12:35 PM
Primary Consultant	: DR.WOCKHARDT DOCTOR	Specimen	: Fluroide Blood
Order No.	: 8922		
Bill No.	: OCR3/24/0000974		

<u>PARAMETER</u>	<u>METHOD</u>	<u>RESULT</u>	<u>UNIT</u>	<u>B.R.I</u>
------------------	---------------	---------------	-------------	--------------

MEDIWHEEL FULL BODY HCU MALE AND FEMALE BELOW 40

Plasma Glucose

Plasma Glucose - Fasting.	Enzymatic Hexokinase	95.4	mg/dL	74-109
---------------------------	----------------------	------	-------	--------

--- END OF REPORT ---



Dr. Alka Thool
Consultant Pathologist
M.B.B.S, MD PATH

AMAN SUBA
Verified By

Partial reproduction of Report not permitted. This Report Relates to Sample received by Laboratory
* B.R.I : BIOLOGICAL REFERENCE INTERVAL ** Test not in Scope of Accreditation



DEPARTMENT OF LABORATORY MEDICINE

BIOCHEMISTRY


Final Report

Patient Name : MR. DHIRAJ R BHOYAR
 Age / Sex : 34 Years / Male
 UHID : WHN2.0000339716
 Primary Consultant : DR. WOCKHARDT DOCTOR
 Order No. : 8922
 Bill No. : OCR3/24/0000974
 Order Date : 09/06/2023 08:44 AM
 Sample Collection : 09/06/2023 11:13 AM
 Report Date : 09/06/2023 12:15 PM
 Specimen : Plasma

PARAMETER	METHOD	RESULT	UNIT	B.R.I
MEDIWHEEL FULL BODY HCU MALE AND FEMALE BELOW 40				
Plasma Glucose- Post Glucose		114.37	mg/dL	70-140
Urine Sugar Post Prandial	Double Sequential Enzyme Reaction - GOD/ POD	NA		

--- END OF REPORT ---

SONAL BHAIASARE
Verified By


Dr. Alka Thool
 Consultant Pathologist
 M.B.B.S, MD PATH

Partial Reproduction of Report not permitted. This Report Relates to Sample received by Laboratory
 * B.R.I : BIOLOGICAL REFERENCE INTERVAL ** Test not in Scope of Accreditation



DEPARTMENT OF LABORATORY MEDICINE

BIOCHEMISTRY

Final Report

Patient Name	: MR. DHIRAJ R BHOYAR	Order Date	: 09/06/2023 08:44 AM
Age / Sex	: 34 Years / Male	Sample Collection	: 09/06/2023 08:48 AM
UHID	: WHN2.0000339716	Report Date	: 09/06/2023 11:12 AM
Primary Consultant	: DR.WOCKHARDT DOCTOR	Specimen	: Serum
Order No.	: 8922		
Bill No.	: OCR3/24/0000974		

PARAMETER	METHOD	RESULT	UNIT	B.R.I
MEDIWHEEL FULL BODY HCU MALE AND FEMALE BELOW 40				
Serum Urea	Urease-GLDH	19.8	mg/dL	1-50
Blood Urea Nitrogen	Calculated	9.25	mg/dL	6-20
Creatinine- Serum				
Creatinine	Enzymatic colorimetric	0.89	mg/dL	0.67-1.17
Uric Acid- Serum				
Uric Acid	Enzymatic colorimetric	6.4	mg/dL	3.4-7
Lipid Profile				
Cholesterol	Colorimetric - Cholesterol Oxidase	179.83	mg/dL	0-200
Triglycerides	Enzymatic colorimetric	161.6	mg/dL	0-150
HDL Cholesterol - Direct	Direct Homogenous Enzymatic Colorimetric	42.8		1. No Risk: >65 2. Moderate Risk: 45-65 3. High Risk: <45
LDL-Cholesterol -Direct	Direct Homogenous Enzymatic Colorimetric	104.71	mg/dL	0-100
VLDL Cholesterol	Calculated	32.32	mg/dL	10-35
Chol/HDL Ratio		4.20		1.Low Risk: 3.3-4.4 2.Average Risk: 4.4-7.1 3.Moderate Risk: 7.1-11.0 4.High Risk: >11.0
Liver Function Test (L.F.T.)				
Alkaline Phosphatase	Colorimetric IFCC	70.5	U/L	40-129
S.G.O.T (AST)	IFCC Without Pyridoxal 5 Phosphate	17.3	U/L	0-40



DEPARTMENT OF LABORATORY MEDICINE

BIOCHEMISTRY

Final Report

Patient Name	: MR. DHIRAJ R BHOYAR	Order Date	: 09/06/2023 08:44 AM
Age / Sex	: 34 Years / Male	Sample Collection	: 09/06/2023 08:48 AM
UHID	: WHN2.0000339716	Report Date	: 09/06/2023 11:12 AM
Primary Consultant	: DR. WOCKHARDT DOCTOR	Specimen	: Serum
Order No.	: 8922		
Bill No.	: OCR3/24/0000974		

PARAMETER	METHOD	RESULT	UNIT	B.R.I
-----------	--------	--------	------	-------


MEDIWHEEL FULL BODY HCU MALE AND FEMALE BELOW 40

Liver Function Test (L.F.T.)

S.G.P.T (ALT)	IFCC Without Pyridoxal 5 Phosphate	6.9	U/L	0-50
Total Protein (Serum)	Colorimetric - Biuret Method	6.81	g/dL	6.4-8.3
Albumin, BCG	Colorimetric - Bromo-Cresol Green	5.05	g/dL	3.5-5.2
Globulin	Calculated	1.76	g/dL	1.9-3.5
Albumin/Globulin Ratio	Calculated	2.86		0.9-2
Serum Total Bilirubin	Colorimetric Diazo	0.39	mg/dL	0-1.2
Serum Direct Bilirubin	Colorimetric Diazo	0.17	mg/dL	0-0.4
Serum Indirect Bilirubin	Calculated	0.22	mg/dL	0-1

--- END OF REPORT ---

SONAL BHAI SARE
Verified By


Dr. Alka Thool
Consultant Pathologist
M.B.B.S, MD PATH

Partial Reproduction of Report not permitted. This Report Relates to Sample received by Laboratory
* B.R.I : BIOLOGICAL REFERENCE INTERVAL ** Test not in Scope of Accreditation



DEPARTMENT OF LABORATORY MEDICINE

IMMUNOLOGY


Final Report

Patient Name	: MR. DHIRAJ R BHOYAR	Order Date	: 09/06/2023 08:44 AM
Age / Sex	: 34 Years / Male	Sample Collection	: 09/06/2023 08:48 AM
UHID	: WHN2.0000339716	Report Date	: 09/06/2023 12:15 PM
Primary Consultant	: DR.WOCKHARDT DOCTOR	Specimen	: Serum
Order No.	: 8922		
Bill No.	: OCR3/24/0000974		

PARAMETER	METHOD	RESULT	UNIT	B.R.I
MEDIWHEEL FULL BODY HCU MALE AND FEMALE BELOW 40				
TOTAL T3	ECLIA	126.4	ng/dl	80-200
TOTAL T4	ECLIA	9.10	ug/dl	4.5-11.7
TSH	ECLIA	0.577	μIU/mL	0.27-4.2

--- END OF REPORT ---

SONAL BHAIASRE
Verified By


Dr. Alka Thool
Consultant Pathologist
M.B.B.S, MD PATH

Partial Reproduction of Report not permitted. This Report Relates to Sample received by Laboratory
* B.R.I : BIOLOGICAL REFERENCE INTERVAL ** Test not in Scope of Accreditation



DEPARTMENT OF LABORATORY MEDICINE

CLINICAL PATHOLOGY

Final Report

Patient Name	: MR. DHIRAJ R BHOYAR	Order Date	: 09/06/2023 08:44 AM
Age / Sex	: 34 Years / Male	Sample Collection	: 09/06/2023 08:48 AM
UHID	: WHN2.0000339716	Report Date	: 09/06/2023 10:15 AM
Primary Consultant	: DR. WOCKHARDT DOCTOR	Specimen	: Urine
Order No.	: 8922		
Bill No.	: OCR3/24/0000974		

<u>PARAMETER</u>	<u>METHOD</u>	<u>RESULT</u>	<u>UNIT</u>	<u>B.R.I</u>
------------------	---------------	---------------	-------------	--------------

MEDIWHEEL FULL BODY HCU MALE AND FEMALE BELOW 40


Urine Routine

Physical Examination

Colour	Pale Yellow		
Appearance	Clear		
Urinalyser (Roche UriSys 1100)			
Specific Gravity	1.020		1.003 - 1.035
Reaction (pH)	5		
Leukocytes, microscopy	00	/hpf	
Erythrocytes, microscopy	00	/hpf	
Nitrite, urinalyser	Negative		
Protein, urinalyser	Present (+)		
Glucose, urinalyzer	Negative		
Ketone, urinalyser	Negative		
Urobilinogen urinalyser	Normal		
Billirubin uirnalyser	Negative		

--- END OF REPORT ---

SONAL BHAIASARE
Verified By


Dr. Alka Thool
Consultant Pathologist
M.B.B.S, MD PATH

Partial Reproduction of Report not permitted. This Report Relates to Sample received by Laboratory
* B.R.I - BIOLOGICAL REFERENCE INTERVAL ** Test not in Scope of Accreditation



DEPARTMENT OF RADIODIAGNOSTICS

Patient Name : MR. DHIRAJ R BHOYAR

Age/Sex : 34 Yrs / Male

UHID : WHN2.0000339716

Reporting Date : 09/06/2023 11:14 AM

Bill No. : OCR3/24/0000974

Order Date : 09/06/2023 08:44 AM

Referred by :

Order No. : 3827

CHEST X-RAY PA VIEW :

Both lung fields are clear.

The costophrenic angles and domes of diaphragm appear normal.

No hilar or mediastinal lesion seen.

Cardiac silhouette is within normal limits.

Visualised bony thorax and soft tissues appear normal.

Impression:

Normal Chest X-Ray.



DR. NITIN DEVKATE
M.B.B.S., M.D.
RADIOLOGIST



DEPARTMENT OF RADIODIAGNOSTICS

Patient Name : MR. DHIRAJ R BHOYAR

Age/Sex : 34 Yrs / Male

Order Date : 09/06/2023 08:44 AM

UHID : WHN2.0000339716

Referred by :

Reporting Date : 09/06/2023 11:51 AM

Order No. : 3827

Bill No. : OCR3/24/0000974

USG ABDOMEN WITH PELVIS :

Real time sonography of the abdomen and pelvis was performed using the 3.5 MHz transducer.

The liver is normal in size and shows bright echotexture suggesting fatty infiltration. No focal parenchymal lesion noted. Intrahepatic biliary tree and venous radicles are normal.

The portal vein and CBD appear normal in course and calibre.

The gall bladder is normal in size with a normal wall thickness and there are no calculi noted within.

The pancreas is normal in size and echotexture. No evidence of focal lesion or calcification or duct dilatation seen.

The spleen is normal in size and echotexture.

Both kidneys are normal in size, position and echogenecity.

Cortical thickness and corticomedullary differentiation are normal.

No hydronephrosis or calculi noted.

The bladder is normal in contour, capacity and wall thickness. No vesical calculi noted.

The prostate is normal in size and homogenous in echotexture.

There is no evidence of ascites.

Impression :

Grade I fatty infiltration of liver.



DR. NITIN DEVKATE
M.B.B.S., M.D.
RADIOLOGIST



WOCKHARDT HOSPITALS, NAGPUR

1643, North Ambazari Road, Nagpur - 440 010. Tel : (0712) 6624444, 6624100

Website : www.wockhardthospitals.com

Registered Office : Wockhardt Towers, BKC, Bandra (East) Mumbai - 400051

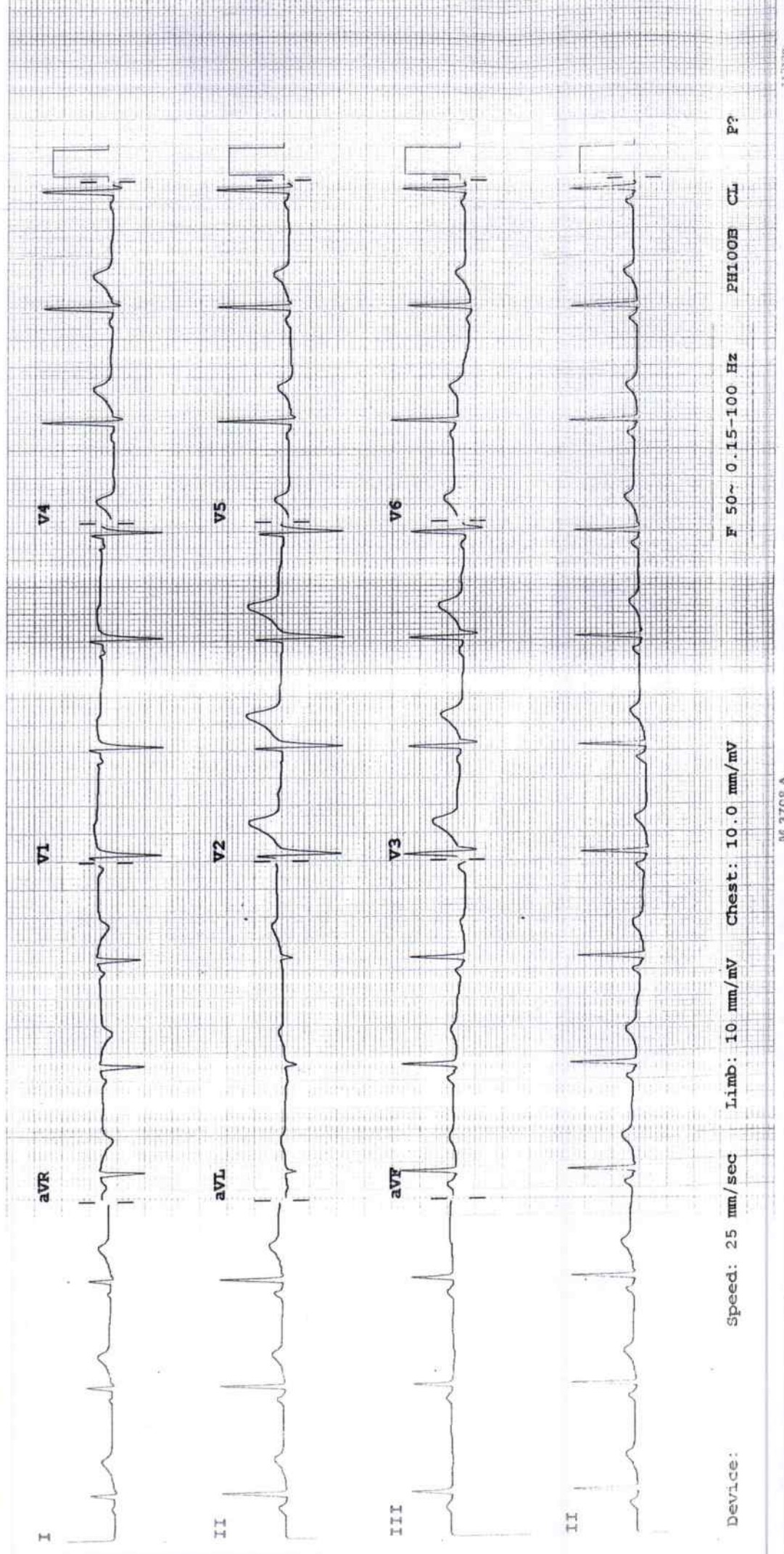
CIN : U85100MH1991PLC063096

Rate 76 . Age not entered, assumed to be 50 years old for purpose of ECG interpretation
 . Sinus rhythm.....normal P axis, V-rate 50-99
 PR 119 . Borderline short PR interval.....PR int <120ms
 QRSD 84 . Probable left atrial enlargement.....P >50ms, <-0.10mV V1
 QT 363 . Baseline wander in lead(s) V5
 QTC 409

--AXIS--
 P 75
 QRS 69
 T 27
 1.2 Lead: Standard Placement

- BORDERLINE ECG -

Unconfirmed Diagnosis



Device: Speed: 25 mm/sec Limb: 10 mm/mV Chest: 10.0 mm/mV

F 50~ 0.15-100 Hz PH100B CL P?

2D ECHOCARDIOGRAPHY & DOPPLER REPORT

Name : Mr. Dinesh Bhojar Age / Sex : 35 yrs / Male
Done by : Dr. Dinesh Padole Date : June 09, 2023
UHID NO : 339716 OPD

2D Echo :


CHAMBERS → Normal in size
RWMA → No RWMA
LVEF → 64 %
VALVES → Valves are normal structurally
SEPTAE → Intact
PERICARDIUM → No pericardial effusion
CLOTS/VEGETATIONS → Absent
IVC → Normal

DOPPLER

E > A
Flow across valves → Trivial mitral regurgitation

CONCLUSION :

Good LV systolic function
LVEF – 64 %
No regional wall motion abnormality is present
No diastolic dysfunction
Trivial mitral regurgitation
No pulmonary hypertension


Dr. Dinesh Padole
MBBS, MD (Gen. Med.), DNB (Cardiology)
Consultant – Interventional Cardiologist



WOCKHARDT HOSPITALS, NAGPUR

1643, North Ambazari Road, Nagpur - 440 010. Tel : (0712) 6624444, 6624100
Website : www.wockhardthospitals.com
Registered Office : Wockhardt Towers, BKC, Bandra (East) Mumbai - 400051
CIN : U85100MH1991PLC063095

Dr. Vaibhav Parekh.

B.D.S., Cert. In Implantology.
Consultant - Dentist
M.S.D.C Reg No. A-19780

Date: 9/6/23

Name: Mr. Dhruv Bhayal

UHID:

Primary Diagnosis: Health check up

Chief Complaints:

T-Afebrile / Febrile	___ OF
P-	___ / min
R-	___ / min
B.P.-	___ / ___ mmHg
Pain - Yes / No	___
Fall Risk : Yes / No	___

Rx

O/E - Stains +
Calculus

Plan - Scaling & polishing

FOLLOW UP AFTER
___ DAYS



WOCKHARDT HOSPITALS, NAGPUR

1643, North Ambazari Road, Nagpur - 440 010. Tel : (0712) 6624444, 6624100

Fax : (0712) 2261266 Website : www.wockhardthospitals.com

Registered Office Address :- Wockhardt Towers , BKC , Bandra (East) Mumbai 400051

CIN: U85100MH1991PLC063096

Name : Mr. Shiraj Bhogya Age/ Sex : 35 yrs / M Date: 9/6/23

Fundus Examination
(Direct Ophthalmoscopy)

	Right	Left
Media	(B) clear	
Optic Disc		
Colour	WNL	
Size	WNL	
Shape	Round	
Margin	well defined	
NRR	Healthy	
C:D	0.3	
Blood Vessels		
A:V ratio	2:3	
Abnormalities	None	
Macula		
FR	Bright	
Abnormalities	None	
Periphery	(B) WNL as far as seen	
Impression	(B) Fundus WNL	

Joshi

Dr Sanyogita Joshi
Consultant Ophthalmology



WOCKHARDT HOSPITALS, NAGPUR

1643, North Ambazari Road, Nagpur - 440 010. Tel : (0712) 6624444, 6624100
Website : www.wockhardthospitals.com
Registered Office : Wockhardt Towers, BKC, Bandra (East) Mumbai - 400051
CIN : U85100MH1991PLC063096