

Uma Rawal - 55y / F

Routine eye check up
 known hypothyroid on R₄

Unaided 6/6 (OD)
 NB = pass

Colour vision - NAB


Fundus (undilated) → C/D 0.3:1
 vessels A:V 2:3

Adv
 eye drop

Refresh Tear.
 (0.5% CMC)

o B/E

o 1 month


 19/7/22

Annual eye check up

Consultant
 Department of Ophthalmology
SIGNATURE HOSPITAL
 Gurugram



(This is only professional opinion and not the diagnosis. Please correlate clinically)

Sector 37-D, BPTP, Dwarka Express Way, Gurugram, Hry.,

h.: 0124-6034444, 8526000000, E-mail : signaturehospital@gmail.com, Web.: www.thesignaturehealthcare.com

MARK GROUP OF HOSPITAL : ★ West Delhi ★ South Delhi ★ Gurugram ★ Faridabad ★ Panipat ★ Karnal

Patient Name : Mrs. USHA RANI SHARMA UHID : 22551
Age / Gender : 55 Years 11 Months 4Days / Female IPNO :
Referred By : Dr. CMO Registered : 19/09/2022/ 8.59 AM
Req.No : 22225507 Sample Collection Dt & Tm : 19/09/2022/ 09.42 AM
Sample ID : 2235915 Sample Receiving Dt & Tm : 19/09/2022/ 09:42 AM
Patient Type : OPD Report Released on : 19/09/2022/ 2.36 PM
Bed No :

HEMATOLOGY

Blood Group And Rh Factor


TEST NAME	RESULT	UNITS	BIOLOGICAL
TEST METHOD			REFERENCE INTERVAL SPECIMEN TYPE
BLOOD GROUP(ABORh)	"O" POSITIVE		

**** End of Report ****

Lab Technician

Dr.NishaTiwari
(MD.Microbiology)


Dr. Neha Gupta
MBBS,MD(Pathology)
(Consultant Pathologist)


Dr. Shreya Pradhan
MBBS,MD(Microbiology)
(Consultant Microbiologist)

Page 1 of 1

(This is only professional opinion and not the diagnosis. Please correlate clinically)

Sector 37-D, BPTP, Dwarka Express Way, Gurugram, Hry.,

Ph.: 0124-6034444, 8526000000, E-mail : signaturehospital@gmail.com, Web.: www.thesignaturehealthcare.com
PARK GROUP OF HOSPITAL : ★ West Delhi ★ South Delhi ★ Gurugram ★ Faridabad ★ Panipat ★ Karnal


The Signature
ADVANCED SUPER SPECIALITY
H O S P I T A L



(This is only professional opinion and not the diagnosis. Please correlate clinically)

Sector 37-D, BPTP, Dwarka Express Way, Gurugram, Hry.,

Ph.: 0124-6034444, 8526000000, E-mail : signaturehospital@gmail.com, Web.: www.thesignaturehealthcare.com

PARK GROUP OF HOSPITAL : ★ West Delhi ★ South Delhi ★ Gurugram ★ Faridabad ★ Panipat ★ Karnal

Patient Name : Mrs. USHA RANI SHARMA	UHID : 22551
Age / Gender : 55 Years 11 Months 4Days / Female	IPNO :
Referred By : Dr. CMO	Registered : 19/09/2022/ 8.59 AM
Req.No : 22225507	Sample Collection Dt & Tm : 19/09/2022/ 09.42 AM
Sample ID : 2235915	Sample Receiving Dt & Tm : 19/09/2022/ 09:42 AM
Patient Type : OPD	Report Released on : 19/09/2022/ 1.53 PM
Bed No :	

BIOCHEMISTRY

Liver Function Test Profile


TEST NAME TEST METHOD	RESULT	UNITS	BIOLOGICAL REFERENCE INTERVAL	SPECIMEN TYPE
<u>BILIRUBIN TOTAL AND DIRECT</u>				
BILIRUBIN TOTAL (Diazonium Salt)	0.8	mg/dl	0.1 - 1.2	SERUM
BILIRUBIN DIRECT (Diazonium Salt)	0.2	mg/dl	00 - 0.3	SERUM
BILIRUBIN INDIRECT (CALCULATED)	0.6	md/dl	0 - 0.9	
SGOT/AST (UV-KINETIC)	25	U/l	0 - 45	SERUM
SGPT/ALT (UV-KINETIC)	19	U/l	0 - 45	SERUM
ALKALINE PHOSPHATASE (ALP) (Kinetic)	108	U/l	39 - 118	SERUM

-**** End of Report ****

Lab Technician

Dr.NishaTiwari
(MD.Microbiology)


 Dr. Neha Gupta
 MBBS,MD(Pathology)
 (Consultant Pathologist)


 Dr. Shreya Pradhan
 MBBS,MD(Microbiology)
 (Consultant Microbiologist)

Page 1 of 2

(This is only professional opinion and not the diagnosis. Please correlate clinically)

Sector 37-D, BPTP, Dwarka Express Way, Gurugram, Hry.,

Ph.: 0124-6034444, 8526000000, E-mail : signaturehospital@gmail.com, Web.: www.thesignaturehealthcare.co
PARK GROUP OF HOSPITAL : ★ West Delhi ★ South Delhi ★ Gurugram ★ Faridabad ★ Panipat ★ Karr

TRANSTHORACIC ECHO- DOPPLER REPORT

NAME - MRS USHA RANI SHARMA	AGE/SEX -55/F
MR. NO. -22551	DATE - 19/9/2022

M-MODE / 2-D DESCRIPTION

- ❖ **Left Ventricle:** No regional wall motion abnormality. LVEF ~ 55 %.
- ❖ **Left Atrium:** Normal.
- ❖ **Right atrium:** It is Normal Sized.
- ❖ **Right ventricle:** It is Normal Sized. RV Systolic Function is Normal.
- ❖ **Aortic valve:** Aortic Cusps are Normal.
- ❖ **Mitral valve:** It Appears Normal.
- ❖ **Tricuspid valve:** It Appears Normal.
- ❖ **Pulmonic valve:** It Appears Normal.
- ❖ **Main pulmonary artery & its branches:** Appear Normal.
- ❖ **Pericardium:** No Pericardial Effusion Seen
- ❖ **Inter atrial septum:** It is Intact.
- ❖ **Inter ventricular septum:** It is Intact.
- ❖ **IVC:** It is Normal in Size, collapsing & Respiratory Variability.
- ❖ **Clot / Vegetation:** No Intracardiac Clot, Vegetation.

Measurements (mm):

LEFT HEART			RIGHT HEART		
	Observed values (mm)	Normal values		Observed values (mm)	Normal values
Aortic root	30	20-36 (22mm/M ²)	IVC size	-	17-21mm
Aortic valve opening		15-26 (mm/M ²)	IVC respiratory variability		>50%
LA size	32	19-40 (mm/M ²)	RA size	-	<18cm ²
LA volume index (ml/M ²)		<34 ml/M ²		-	
LVID(D)	50	(ED=37-56)	RV basal		24-42mm
LVID(S)	40		RV mid cavity	-	20-35mm
IVS(D)	9	(ED=6-12)	RV longitudinal	-	56-86mm
			RVOT proximal	-	18-33mm
PW(D)	11	(ED=5-10)	TAPSE	-	>15mm
LVEF(%)	55 %	55%-70%	RV free wall thickness	-	<5mm
			RVEF		

(This is only professional opinion and not the diagnosis. Please correlate clinically)

Sector 37-D, BPTP, Dwarka Express Way, Gurugram, Hry.,

Ph.: 0124-6034444, 8526000000, E-mail : signaturehospital@gmail.com, Web.: www.thesignaturehealthcare.com

PARK GROUP OF HOSPITAL : ★ West Delhi ★ South Delhi ★ Gurugram ★ Faridabad ★ Panipat ★ Karn

Doppler velocities (cm/sec)

Aortic valve		Pulmonary valve	
Max/ Vel	111	Max velocity	108
Max/ PG		Max PG	
Mitral valve		Tricuspid valve	
E	62	Max Velocity	
A	61	PASP	
DT	-	E/E' (>6)	-
E/A	-	S' Velocity (>10cm2/sec)	-

Regurgitation

MR		TR	
Severity	Nil	Severity	Nil
AR		PR	
Severity	Nil	Severity	Nil

Final Interpretation:

- No regional wall motion abnormality. LVEF ~ 55 %.
- Normal Cardiac Chamber Dimension.
- No MR, No AR, No TR.
- Grade I Diastolic dysfunction
- No Vegetation, Pericardial Effusion.



Dr. AJAY DUA

DNB (Medicine), DNB (Cardiology)
 Sr. Consultant Interventional Cardiology

(This is only professional opinion and not the diagnosis. Please correlate clinically)

Sector 37-D, BPTP, Dwarka Express Way, Gurugram, Hry.,

Ph.: 0124-6034444, 8526000000, E-mail : signaturehospital@gmail.com, Web.: www.thesignaturehealthcare.com

PARK GROUP OF HOSPITAL : ★ West Delhi ★ South Delhi ★ Gurugram ★ Faridabad ★ Panipat ★ Karna

UID 22551 Date: 19 Sep 2022
Name/Age/Sex : USHA RANI SHARMA 55Yr / Female
Treating Dr. :

X-RAY CHEST PA VIEW

FINDINGS:

The lungs on the either side show equal translucency.
The peripheral pulmonary vasculature is normal.
No focal lung lesion is seen.
Bilateral CP angles are normal.
Both hila are normal in size, have equal density and bear normal relationship.
The heart and trachea are central in position and no mediastinal abnormality is visible.
The cardiac size is normal.
The domes of the diaphragms are normal in position, and show smooth outline.

IMPRESSION:

No significant abnormality detected.
Suggest clinical correlation and follow up.



Dr. Avinash Rathod (DMRD)
Consultant Radiologist
Reg. No. 2011/05/1616/1616

(This is only professional opinion and not the diagnosis. Please correlate clinically)

Sector 37-D, BPTP, Dwarka Express Way, Gurugram, Haryana
Webrad associated center
Powered by www.stradus.in

SIGNALURE HOSPITAL
SEC 37D GURUGRAM

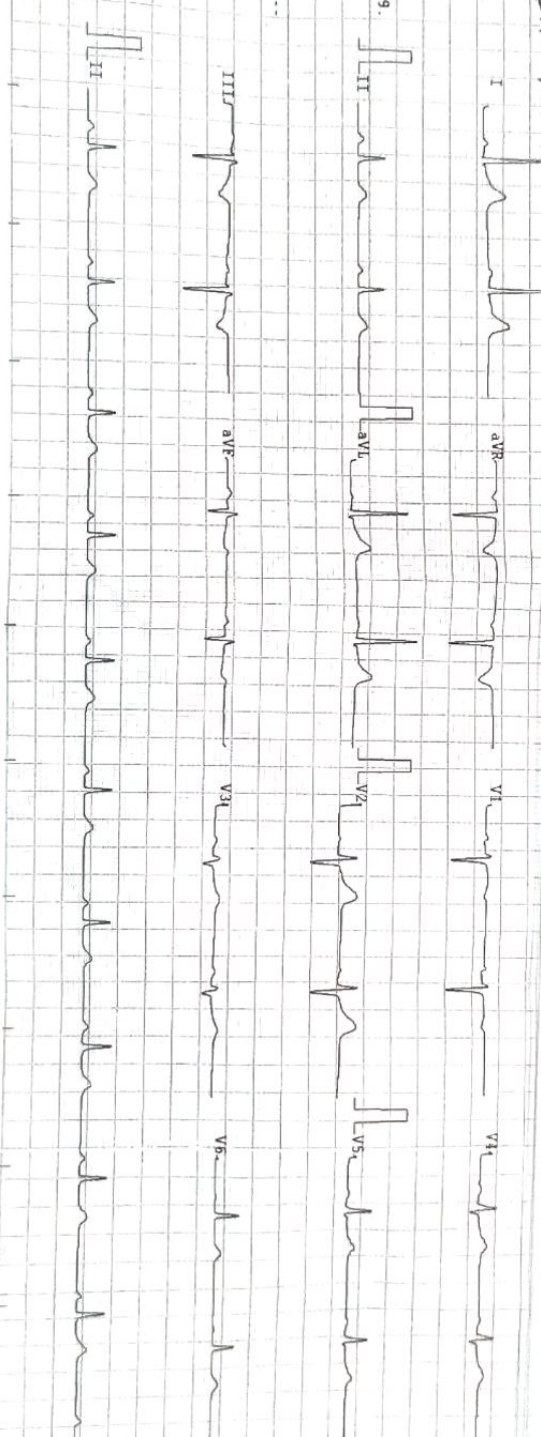
PATIENT INFORMATION

ID: 22509 CASE: -
NAME: -
AGE: - GENDER: - SMOKER: -
HEIGHT: - .cms WEIGHT: - K9.
DOCTOR: - DR CMO
REF: -
DATE/TIME: - 19/09/2022 09:03:01

ECG SETTINGS

PRINTING MODE: - AUTO 3+1
GAIN mm/mV: - 10
SPEED mm/Sec: - 25
FILTER Hz: - 0.05 - 35
NOTCH/BLC: - ON/OFF
RHYTHM LEAD: - II

ERS PSCBS VER-5.021



OBSERVATIONS

HEART RATE: 62 bpm
R-R: 963 ms
P-R: 152 ms
P-DUR: 98 ms
QRS: 78 ms
T-DUR: 168 ms
ST DUR: 138 ms
QT: 388 ms
QTc: 42 ms
P AXIS: 02°
R AXIS: 01°
T AXIS: -01°
SP AXIS: -02°

REMARKS:

