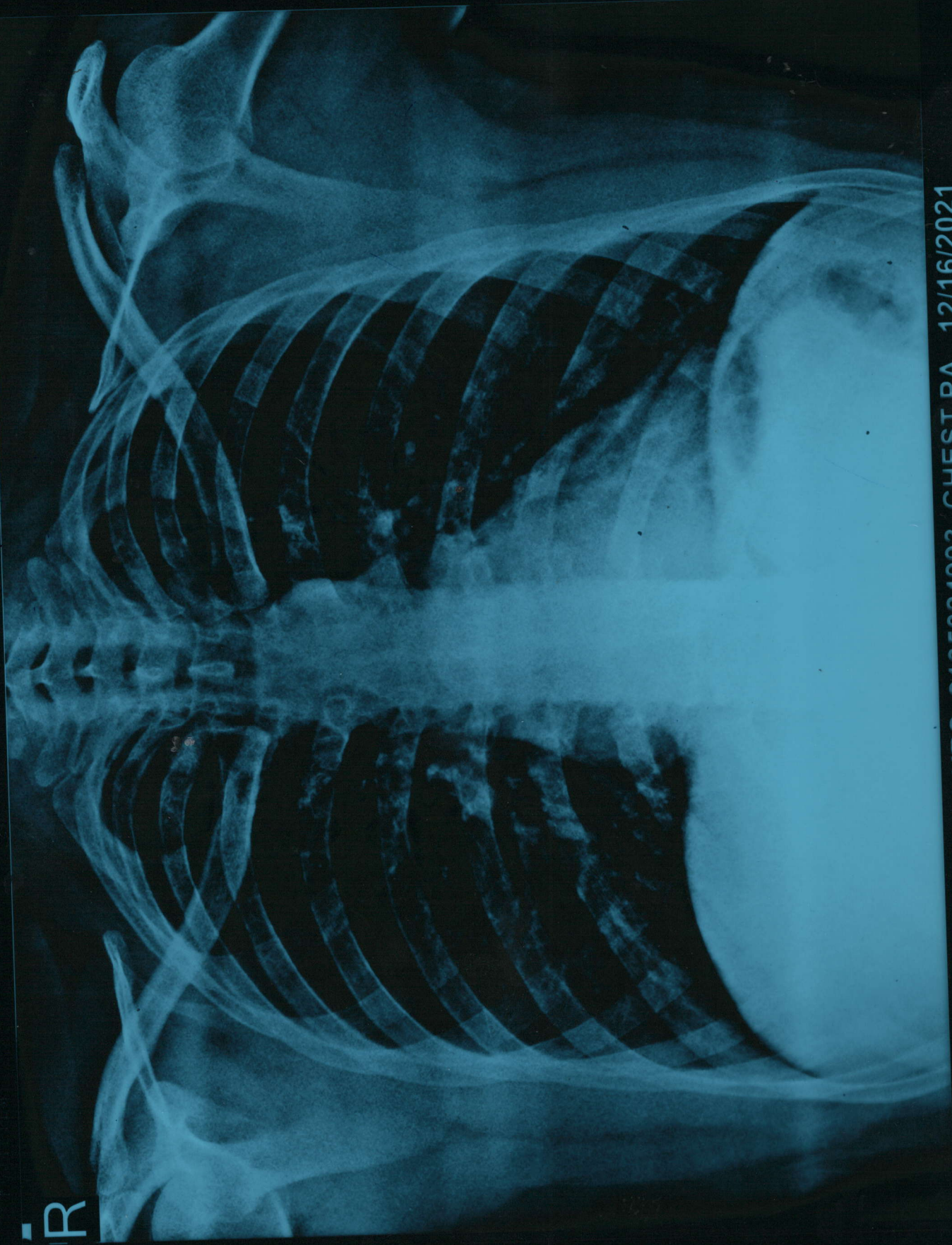
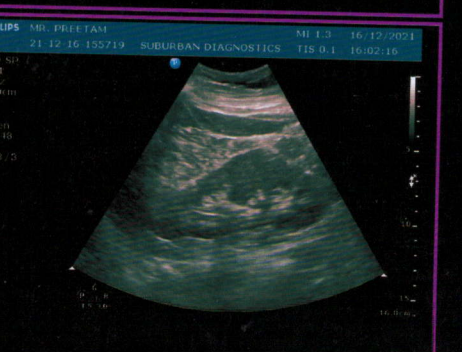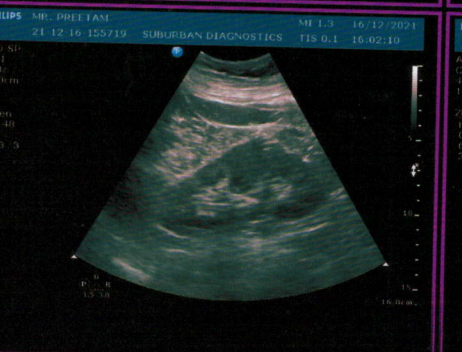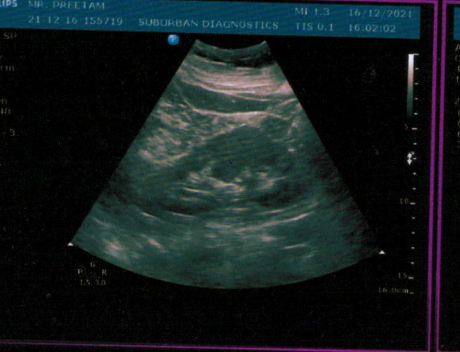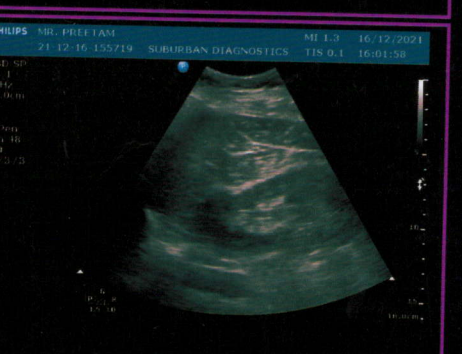
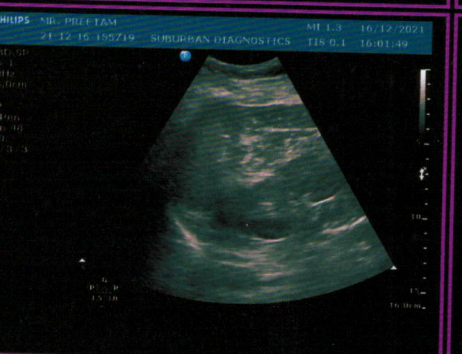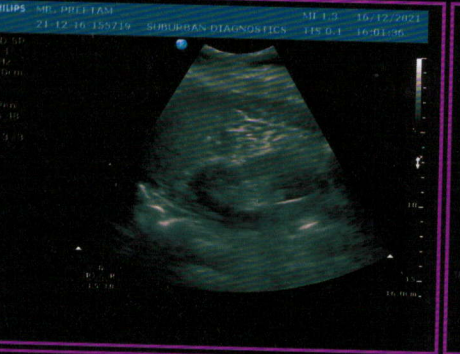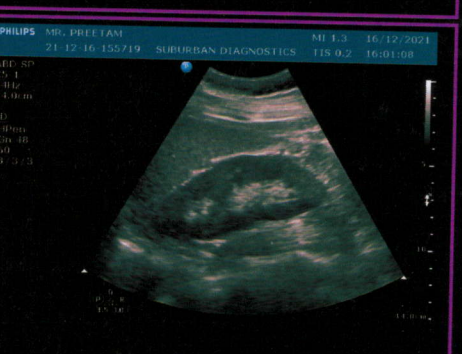
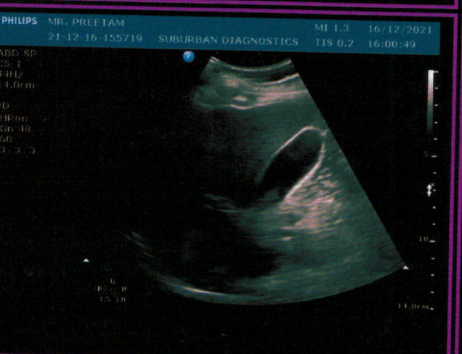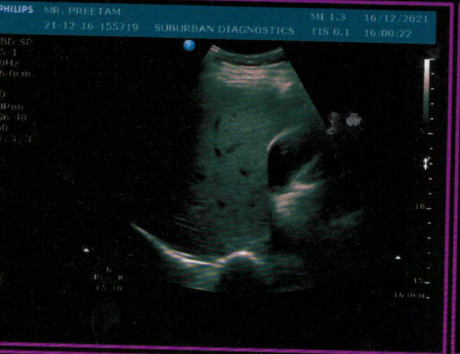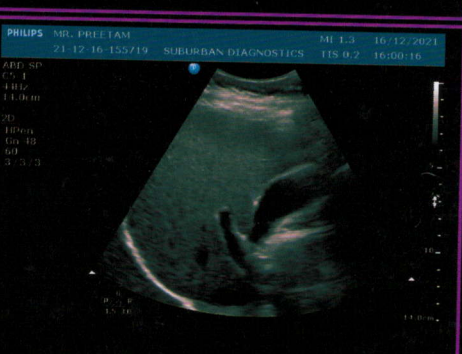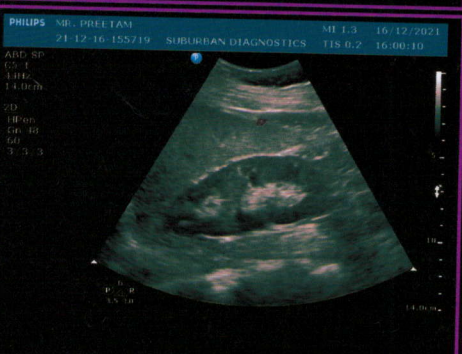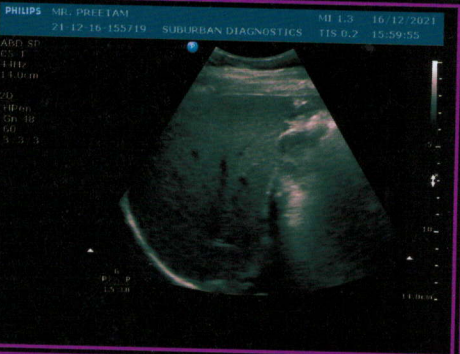
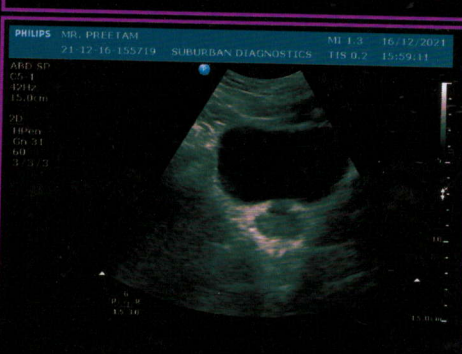
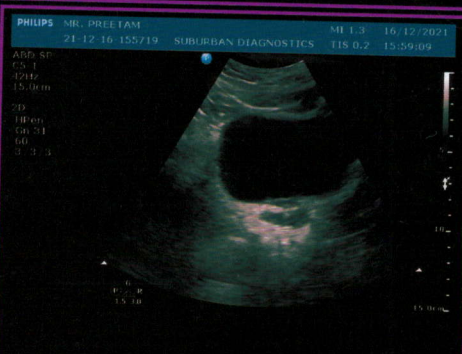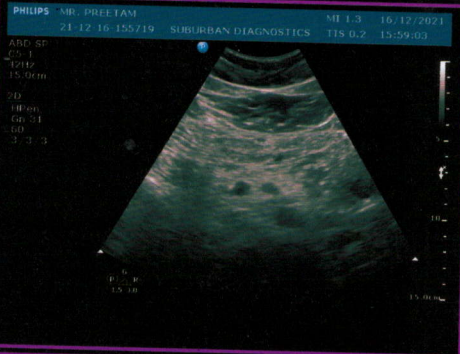
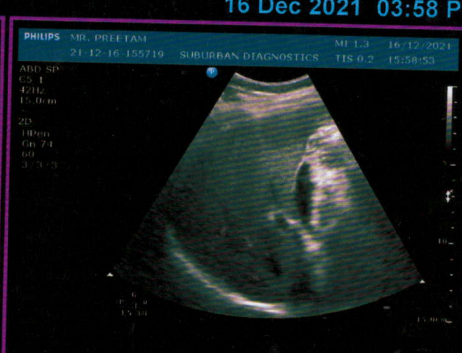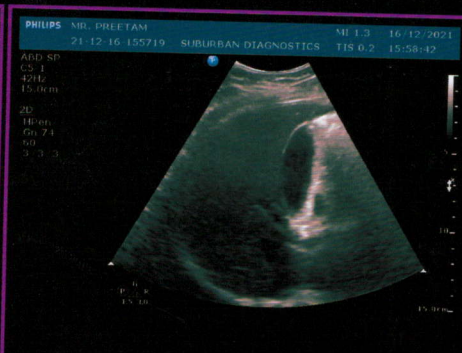


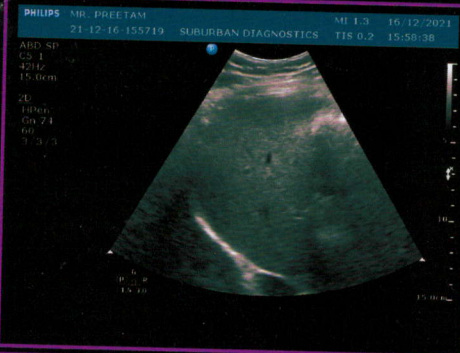R



M. ROBERTAM M 30 YRS 2135024993 CHEST PA 12/16/2021



TMT

Preetam .
31/M

16/12/21

PHY2.

History and Complaints:

nil

EXAMINATION FINDINGS:

Height (cms):		Weight (kg):	BMI
Temp (0c): Afebrile	98.6	Skin: Normal	[Signature]
Blood Pressure (mm/hg):		Nails: Healthy	
Pulse:		Lymph Node: Not Palpable	

Systems

Cardiovascular: S1,S2 Normal No Murmurs
Respiratory: Air Entry Bilaterally Equal
Genitourinary: Normal
GI System: Soft non tender No Organomegaly
CNS: Normal

IMPRESSION:

FHJ
 non + HDL ↑
 other WNL

ADVICE:

Diet + Exercise .



CHIEF COMPLAINTS:


1)	Hypertension:	[Signature]
2)	IHD:	
3)	Arrhythmia:	
4)	Diabetes Mellitus :	
5)	Tuberculosis :	
6)	Asthama:	
7)	Pulmonary Disease :	

PUNE LAB ADDRESS: Seraph Centre, Opp. BSNL Exchange, Shahu College Road, Off Pune-Satara Road, Behind Panchami Hotel, Pune - 411009

CENTRAL PROCESSING LAB: 2nd Floor, Aston, Sundervan Complex, Above Mercedes Showroom, Andheri West, Mumbai - 400053

HEALTHLINE - MUMBAI: 022-6170-0000 | OTHER CITIES: 1800-266-4343 | For Feedback - customerservice@suburbandiagnosics.com | www.suburbandiagnosics.com

8)	Thyroid/ Endocrine disorders :		
9)	Nervous disorders :		
10)	GI system :		
11)	Genital urinary disorder :		
12)	Rheumatic joint diseases or symptoms :		
13)	Blood disease or disorder :		
14)	Cancer/lump growth/cyst :		
15)	Congenital disease :		
16)	Surgeries :		
PERSONAL HISTORY:			
1)	Alcohol		
2)	Smoking		
3)	Diet		
4)	Medication		



Dr. KRUTIKA INGLE

MBBS, D.DM, PG in Diabetology (USA)
MMC Regd - 2012 103018

Preventive Health Check-up | Pathology | Digital X-Ray | Sonography | Colour Doppler | Mammography | BMD (DXA Scan) | OPG | Stress Test/TMT | 2D Echo | Spirometry | Eye Examination | Dental Examination | Diet Consultation | Audiometry | OT Sterility | Water Sterility | Clinical Res

Date:- 18/12/21

CID:

Name:- Preetam

Sex / Age: 31 / (M)

EYE CHECK UP

Chief complaints:

Systemic Diseases:

Past history:

Unaided Vision:

Aided Vision:

Refraction:

no.
- WNL -
NA

(Right Eye)

(Left Eye)

	Sph	Cyl	Axis	Vn	Sph	Cyl	Axis	Vn
Distance	_____	_____	_____	2	_____	_____	_____	2
Near	_____	_____	_____	2	_____	_____	_____	2

Colour Vision: Normal / Abnormal

Remark: WNL

Krutika Ingle

Dr. KRUTIKA INGLE

MBBS, D.DM, PG in Diabetology (USA)
MMC Regd - 2012 103018

Pat-Name:

HR 91/min

Res. extension

Age: 3.1 / M / F

173 cm / 81 kg

110 / 80 mmHg

K10 N1L

Normal Axis, Sine Rhythm

NAD

PE TMT

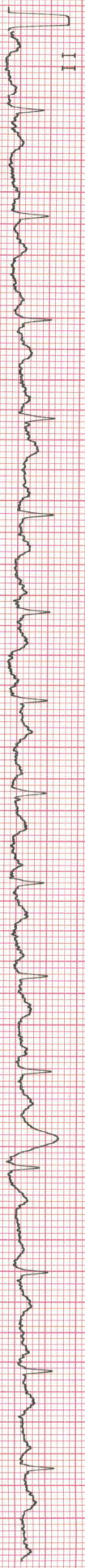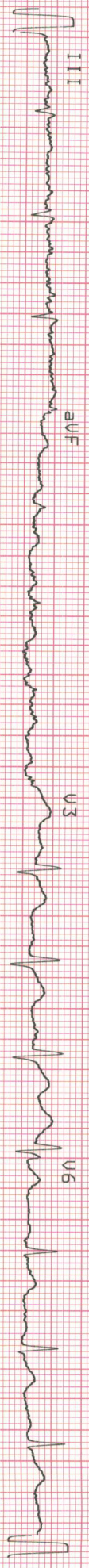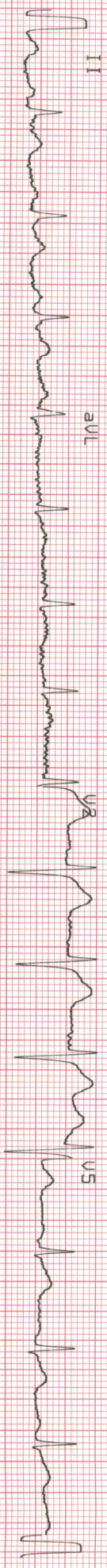
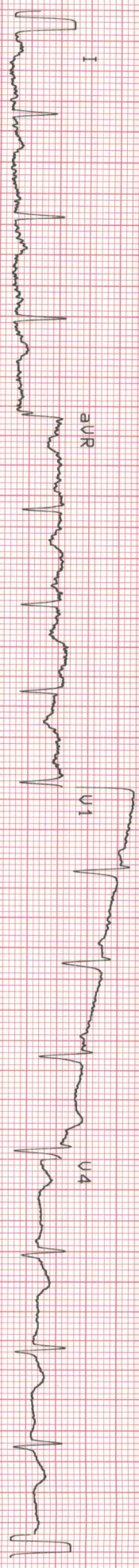
[Signature]
DR. KRUTIKA INGLE

MBBS, D.DM, PG in Diabetology (USA)
MMC Regd - 2012 103018

[Signature]
K10 N1L

10 mm/mV

10 mm/mV



25 mm/s


0.05-25 Hz F50 TH 16-DEC-21 13:48:36

AT-2 3.03

SCHILLER

Part No. 2.157017M

K 88



CID : 2135024993
Name : Mr PREETAM .
Age / Sex : 30 Years/Male
Ref. Dr :
Reg.Location : Pimple Saudagar, Pune Main Centre

Reg. Date : 16-Dec-2021 / 12:22
Reported : 16-Dec-2021 / 13:36

X-RAY CHEST PA VIEW

There is no evidence of any parenchymal lesion in either lung.
Both lung fields are clear.
Cardio-aortic silhouette has a normal appearance.
Diaphragmatic domes have normal contours and positions.
There is no evidence of any pleural effusion.
Bony thorax and soft-tissues are normal.

CONCLUSION:

NORMAL CHEST X-RAY.

-----End of Report-----

DR. RUJUTA SAWANT
MBBS DMRE
Regd. No. 2011/11/3329
Consultant Radiologist

Click here to view images <http://202.143.96.162/Suburban/Viewer?ViewerType=3&AccessionNo=2021121611001100>

PATIENT NAME : MR. PREETAM.
AGE : 30/Y/M.
CID -2135024993.
DATE : 16.12.2021.

USG (ABDOMEN + PELVIS)

LIVER : The liver is normal in size, shape and smooth margins. It shows normal parenchymal echo pattern. The intra hepatic biliary and portal radical appear normal. No evidence of any intra hepatic cystic or solid lesion seen. The main portal vein and CBD appears normal.

GALL BLADDER : The gall bladder is physiologically distended. The visualized gall bladder appears normal. No evidence of pericholecystic fluid is seen.

PANCREAS : The pancreas is well visualised and appears normal. No evidence of solid or cystic mass lesion is noted.

KIDNEYS : Both the kidneys are normal in size, shape and echotexture. No evidence of any calculus, hydronephrosis or mass lesion seen.

SPLEEN : The spleen is normal in size, shape and echotexture. No evidence of focal lesion is noted.

URINARY BLADDER : The urinary bladder is well distended. It shows thin walls and sharp mucosa. No evidence of calculus is noted. No mass or diverticulum is seen.

PROSTATE : The prostate is normal in size and echotexture.

Visualized small bowel loops appear non-dilated. Gaseous distension of large bowel loops. There is no evidence of any lymphadenopathy or ascitis.

IMPRESSION :

➤ **No significant abnormality seen.**

Advice - Clinical correlation.


Navids

DR. NAVID SHATTARI
MD, DNB, RADIO-DIAGNOSIS.

DR. NAVID SHATTARI.
MD. DNB RADIODIAGNOSIS.
REG NO 2015/05/2742.

SUBURBAN DIAGNOSTIC (I) PVT. LTD.
"Fortuna" Ground Floor, Near Shivar
Hotel, Pimple Saudagar, Pune-411 027.

Issue Date: 20/12/2011




भारत सरकार
Government of India

श्रीराम
Preetam
श्रीराम शिवा / DOB: 25/03/1990
पुरुष / MALE

6765 9275 7039

मेरा आधार, मेरी पहचान



Pradeep