


**MR. KAPIL SAINI**  
**MEDIWHEEL****36 Years /M****01-06-2024****HEAMOGRAM**

Test Name	Results	Normal Range
Haemoglobin (HB)	12.4	13 - 18 gm%
R.B.C. Count	4.34	4.5 - 5.5 milli./cu.mm
PCV	37.9	40 - 50 %
MCV	87.33	80 - 95 fl
MCH	28.57	27 - 32 pg
MCHC	32.72	31.5 - 34.5 %
TOTAL WBC COUNT	8.400	4,000 to 11,000 /cu.mm
DIFFERENTIAL WBC COUNT	.	
Neutrophils	70	40 - 75 %
Lymphocytes	25	20 - 40 %
Monocytes	03	02 - 08 %
Eosinophils	02	01 - 05 %
Basophils	00	00 - 01 %
PLATELET COUNT	3.48	1.5 - 4 Lacs/cu.mm.
E.S.R	12.0	M- 0-10 at the end of 1 hr. F- 0-20 at the end of 1 hr

  
**Dr. POOJA PRAPANNA**  
**MD**  
**DR. POOJA PRAPANNA**  
**M.D.**

Note :- All pathological tests have technical and biological limitations. Please correlate clinically as well as with other investigative findings.  
A review should be requested in case of any disparity. This report is not valid for medicolegal purpose.



MR. KAPIL SAINI

36 Years /M

MEDIWHEEL

01-06-2024

Test Name	Results	Normal Range
<b><u>BIOCHEMISTRY</u></b>		
CREATININE	0.98	0.6 - 1.4 mg\dl
DIRECT BILIRUBIN	0.78	<0.25 mg/dl
INDIRECT BILIRUBIN	0.13	< 1.0 mg/dl
FASTING BLOOD SUGAR	136.0	70 - 110 mg/dl
S.G.P.T	33.0	0 - 45 IU\l
BUN	10.0	5 - 21 Mg/dl

  
**Dr. POOJA PRAPANNA**  
MD

DR. POOJA PRAPANNA  
M.D.

Note :- All pathological tests have technical and biological limitations. Please correlate clinically as well as with other investigative findings.  
A review should be requested in case of any disparity. This report is not valid for medicolegal purpose.

MR. KAPIL SAINI  
MEDIWHEEL

36 Years /M  
01-06-2024

**BLOOD GROUP**

Test Name	Results	Normal Range
BLOOD GROUP	: -	
"ABO " GROUP	"A"	
Rh (D) Factor	Positive	
	.	
	.	
	.	
(Cross matching & recheck of Blood Group is mandatory before any transfusion)	.	

  
Dr. POOJA PRAPANNA  
MD

DR. POOJA PRAPANNA  
M.D.

Note :- All pathological tests have technical and biological limitations. Please correlate clinically as well as with other investigative findings.  
A review should be requested in case of any disparity. This report is not valid for medicolegal purpose.




MR. KAPIL SAINI  
MEDIWHEEL

36 Years /M  
01-06-2024

**BLOOD EXAMINATION REPORT**

Test Name	Results	Normal Range
P.P. BLOOD SUGAR	265.0	upto 140 mg/dl

  
Dr. POOJA PRAPANNA  
MD  
DR. POOJA PRAPANNA  
M.D.

Note :- All pathological tests have technical and biological limitations. Please correlate clinically as well as with other investigative findings.  
A review should be requested in case of any disparity. This report is not valid for medicolegal purpose.



MR. KAPIL SAINI  
MEDIWHEEL36 Years /M  
01-06-2024**URINE EXAMINATION**

Test Name	Results	Normal Range
<b>PHYSICAL EXAMINATION</b>		
Quantity	30 ml	
Colour	Pale Yellow	
Appearance	Clear	
Deposits	Absent	
Specific Gravity	1.015	
Reaction	Acidic	
<b>CHEMICAL EXAMINATION</b>		
Albumin	Nil	
Sugar	Nil	
Ketones	Absent	
Bile Pigments	Negative	
Bile Salt	Negative	
Hematuria	Negative	
<b>MICROSCOPIC EXAMINATION</b>		
Pus Cells	1- 2 /hpf	
Red Blood Cells	Nil/hpf	
Epithelial Cell	1 - 2 /hpf	
Crystals	Nil	
Casts	Absent	

  
Dr. POOJA PRAPANNA  
M.D.DR. POOJA PRAPANNA  
M.D.

Note :- All pathological tests have technical and biological limitations. Please correlate clinically as well as with other investigative findings.  
A review should be requested in case of any disparity. This report is not valid for medicolegal purpose.

4D SONOGRAPHY • COLOR DOPPLER • ECHO • PATHOLOGY • DIGITAL X-RAY & OPG • TMT • ECG • HOLTER

**MR. KAPIL SANINI**

*36* Yrs./M

**MEDIWEEL**

**1st June, 2024**

**X-RAY CHEST PA VIEW**

Bony cage is normal.

Trachea is central. C.P. angles are clear.

Cardiac contour and cardiothoracic ratio are normal.

Lung fields are clear.

**DR.D.S.CHHABRA.**  
M.D.



MR Kapil Saini

36YEARS /MALE

Mediweel

01/06/2024

Height: - 164

Weight: - 71

BP: - 120/83 mmhg

Pulse: -71/- Regular

BMI: - 19.8

The Medical Examiner should record the findings under one of the following categories:-

Overweight

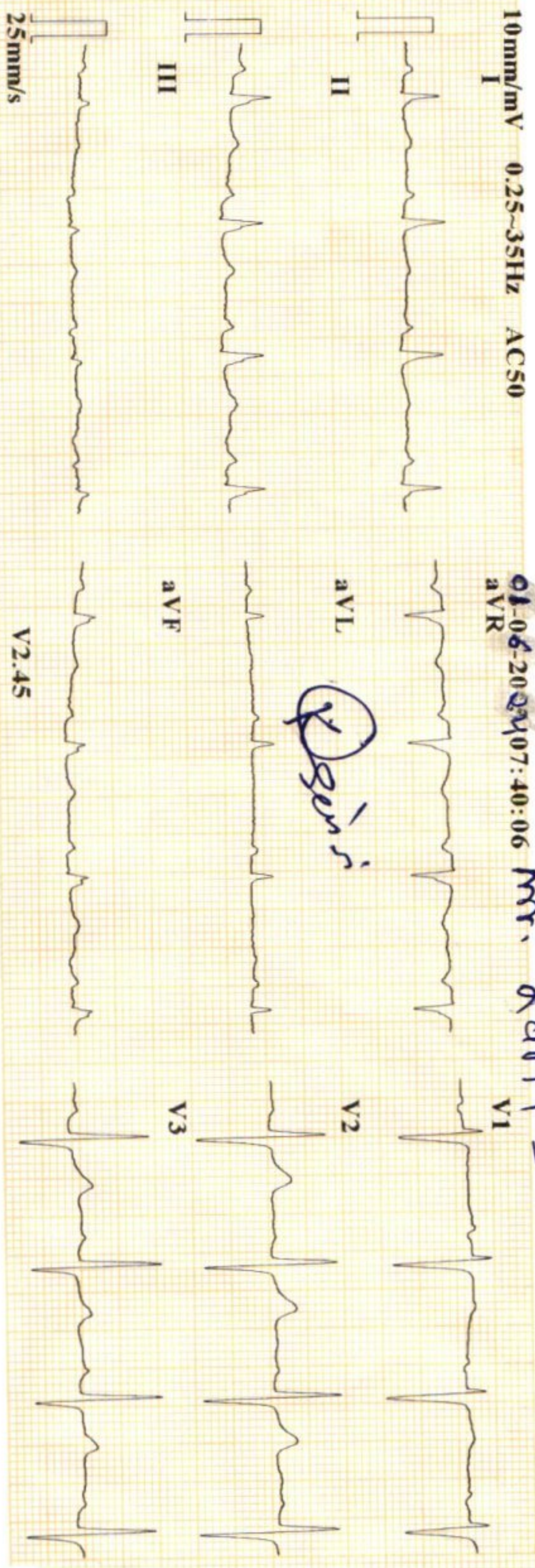


DR. D.S. CHHABRA

MBBS, MD. Chhabra  
M.B.B.S., M.D.

Reg. No.-5007





01-06-2024 07:40:06 Mr. Karil Samir  
aVR

ID	: 050608-0740
Name	:
Age	: 36 yr
Sex	: Male
BP	:
Height	: cm
Weight	: kg
HR	: 83 bpm
P Dur	: 94 ms
PR int	: 162 ms
QRS Dur	: 111 ms
QT/QTc int	: 351/414 ms
P/QRS/T axis	: 34/41/48 °
RV5/SV1 amp	: 0.651/1.055 mV
RV5+SV1 amp	: 1.706 mV
RV6/SV2 amp	: 0.602/1.013 mV



Diagnosis Information:  
800: Sinus Rhythm  
\*\*\*Normal ECG\*\*\*

*(Handwritten Signature)*

Report Confirmed by: **DR. PRIYANK JAIN**  
MBBS, MD, DM.  
Reg. No. 19547

CARDIART



<b>Patient :</b>	<b>MR. KAPIL SAINI</b>	<b>Doctor :</b>	<b>Dr. RAJU MAGLAWAT</b>
<b>Age/Sex :</b>	36 years 0 months /Male	<b>Facility :</b>	Dr Agarwals Eye Hospitals-Janjeerwala Square
<b>Contact :</b>	9165067787	<b>Appt. Dt :</b>	01 Jun'24
<b>MR No. :</b>	JWS/77656/24	<b>Address :</b>	INDORE, Indore G.P.O., Indore, MADHYA PRADESH 452001
<b>Note Dt :</b>	01 Jun'24		

**OPD SUMMARY**

**HISTORY**

**Visit:** Routine Checkup  
**Chief Complaints :** None  
**Ophthalmic History :**  
 • Glasses  
 PG NOT BRING.  
**Systemic History :** None  
**Allergies :** None

**REFRACTION**

R/OD

**Keratometry:**

	Value	Axis
Kh	42.00	150
Kv	42.50	60

Avg. K: 42.25  
 Cyl: -0.50

**Auto Refraction:**

	Sph	Cyl	Axis
Dry	+2.50	--	--
	--	--	--
	--	--	--

Dilated	--	--	--
	--	--	--
	--	--	--

**Dry Refraction:**

L/OS

**Keratometry:**

	Value	Axis
Kh	42.50	180
Kv	42.50	90

Avg. K: 42.50  
 Cyl: 0.00

**Auto Refraction:**

	Sph	Cyl	Axis
Dry	+1.75	+0.50	10
	--	--	--
	--	--	--

Dilated	--	--	--
	--	--	--
	--	--	--

**Dry Refraction:**



	Sph	Cyl	Axis	Vision
Distant	+1.75	--	--	6/6
Near	--	--	--	N6

	Sph	Cyl	Axis	Vision
Distant	+1.25	--	--	6/6
Near	--	--	--	N6

- FOGGING DONE...DILATED REF.

## EXAMINATION

### R/OD

**VA:** UCVA - 6/12 UCVA Near- N6 PH- 6/6  
**IOP(1):** 14 at 11:43 AM  
**Appearance:** Normal  
**Appendages:** Normal  
**Conjunctiva:** Normal  
**Sclera:** Normal  
**Cornea:** Size/Shape/Surface Normal  
**Anterior Chamber:** Normal depth, No cells/flare  
**Pupil:** Round shape, Normal direct & Consensual reflex  
**Iris:** Within normal Limits  
**Lens:** Clear, Crystalline, Central  
**Extra Ocular Movements:** Uniocular and Binocular movements full and normal

### L/OS

**VA:** UCVA - 6/9 UCVA Near- N6 PH- 6/6  
**IOP(1):** 16 at 11:43 AM  
**Appearance:** Normal  
**Appendages:** Normal  
**Conjunctiva:** Normal  
**Sclera:** Normal  
**Cornea:** Size/Shape/Surface Normal  
**Anterior Chamber:** Normal depth, No cells/flare  
**Pupil:** Round shape, Normal direct & Consensual reflex  
**Iris:** Within normal Limits  
**Lens:** Clear, Crystalline, Central  
**Extra Ocular Movements:** Uniocular and Binocular movements full and normal

## DIAGNOSIS

1. Hypermetropia, bilateral - H52.03

## ADVICE


**Management Plan:**  
 CYCLOPLAGIC REFRACTION

*Raju*

**Dr. Raju Maglawat**

Printed on: 01 Jun'2024, 11:57 AM





**Indore, Madhya Pradesh, India**

202, Bhopal - Indore Rd, South Tukoganj, Indore, Madhya Pradesh 452002, India

Lat 22.712385°

Long 75.880068°

01/06/24 10:49 AM GMT +05:30



भारत सरकार

केंद्र सरकार

केंद्र सरकार

केंद्र सरकार

केंद्र सरकार

केंद्र सरकार

केंद्र सरकार

केंद्र सरकार

भारत सरकार

केंद्र सरकार

भारत सरकार

