

Health Check up Booking Confirmed Request(bobS27293),Package Code-
PKG10000248, Beneficiary Code-76209

Mediwheel <wellness@mediwheel.in>

Thu 2/16/2023 8:50 AM

To: Info Sarjapur <info.sarjapur@narayanahealth.org>

Cc: mediwheelwellness@gmail.com <mediwheelwellness@gmail.com>

Attention: This email originated outside of Narayana Health domain. Links and attachments cannot be verified as authentic. Do not share personal/organisational data including passwords or act based on the content of the email, unless you have verified the authenticity of the sender and email address thoroughly.

011-41195959

Email:wellness@mediwheel.in

Hi **Narayana Multispeciality Clinic**,

Diagnostic/Hospital Location :83/3 Doddakanneli,Sarjapur,Main Road , Near Wipro Gate-
560035, City:Bangalore

We have received the confirmation for the following booking .

Beneficiary Name : PKG10000248

Beneficiary Name : VENKATARAO NERSU

Member Age : 38

Member Gender : Male

Member Relation : Spouse

Package Name : Mediwheel Metro Full Body Health Checkup Male Below 40

Location : BENGALURU,Karnataka-560038

Contact Details : 8639730793

Booking Date : 30-01-2023

Appointment Date : 25-02-2023

Instructions to undergo Health Check:

1. Please ensure you are on complete fasting for 10-To-12-Hours prior to check.
2. During fasting time do not take any kind of medication, alcohol, cigarettes, tobacco or any other liquids (except Water) in the morning.
3. Bring urine sample in a container if possible (containers are available at the Health Check centre).
4. Please bring all your medical prescriptions and previous health medical records with you.
5. Kindly inform the health check reception in case if you have a history of diabetes and cardiac problems.

For Women:

1. Pregnant Women or those suspecting are advised not to undergo any X-Ray test.
2. It is advisable not to undergo any Health Check during menstrual cycle.

We request you to facilitate the employee on priority.

TO WHOMSOEVER IT MAY CONCERN

I hereby give a consent 201-23971 (Patient Name) Mr. Venkatarao
(MRN No) that I have not taken service Stool, routine
(ECG/ECHO/Doppler/TMT/X-Ray/Investigation/Consultation against
Package/Health Checkup) Medicwheel pkg (Package Name/HC
Name) against Invoice number 2010-2302001766
dated 25-2-2023

New Center
Patient Sign

Resmi
Dept Sign

A.B.K
Unit Head Sign/Seal

9611441561
Mobile Number

342939
EC Number

316370
EC Number



Package Details

Patient Name : Mr Venkatarao Nesru, 20100000023971, male, 38y 11m
Package Name : EHP Mediwheel Full Body Health checkup Below 40 Male
Start Date : 25/02/2023 09:02 End Date : 26/02/2023 09:02
Generated By: Hemanth Kumar
Generated On : 25-02-2023 09:02

Service Name	Ordered Date	Service Center	Consultant	Qty	Explicit
✓ CONSULTATION - FIRST VISIT	25/02/2023 09:02 AM	OPD-2F	Dr. Sharma Vasant Kumar	1	No
✓ USG ABDOMEN	25/02/2023 09:02 AM	ULTRA SOUND-2F	Dr. Sharma Vasant Kumar	1	No
✓ XRAY CHEST PA	25/02/2023 09:02 AM	X-RAY	Dr. Sharma Vasant Kumar	1	No
✓ ECHO COLOR DOPPLER	25/02/2023 09:02 AM	ECHO-2F	Dr. Sharma Vasant Kumar	1	No
✓ TREADMILL TEST	25/02/2023 09:02 AM	OPD-2F	Dr. Sharma Vasant Kumar	1	No
✓ ECG	25/02/2023 09:02 AM	OPD-2F	Dr. Sharma Vasant Kumar	1	No
✓ BLOOD UREA NITROGEN (BUN)	25/02/2023 09:02 AM	BIOCHEMISTRY	Dr. Sharma Vasant Kumar	1	No
✓ URIC ACID	25/02/2023 09:02 AM	BIOCHEMISTRY	Dr. Sharma Vasant Kumar	1	No
✓ THYROID PROFILE (T3, T4, TSH)	25/02/2023 09:02 AM	BIOCHEMISTRY	Dr. Sharma Vasant Kumar	1	No
✓ LIVER FUNCTION TEST (LFT)	25/02/2023 09:02 AM	BIOCHEMISTRY	Dr. Sharma Vasant Kumar	1	No
✓ SERUM CREATININE	25/02/2023 09:02 AM	BIOCHEMISTRY	Dr. Sharma Vasant Kumar	1	No
✓ LIPID PROFILE (CHOL, TRIG, HDL, LDL, VLDL)	25/02/2023 09:02 AM	BIOCHEMISTRY	Dr. Sharma Vasant Kumar	1	No
✓ HBA1C	25/02/2023 09:02 AM	BIOCHEMISTRY	Dr. Sharma Vasant Kumar	1	No
✓ URINE FOR SUGAR (FASTING)	25/02/2023 09:02 AM	CLINICAL PATHOLOGY	Dr. Sharma Vasant Kumar	1	No
✓ URINE FOR SUGAR (POST PRANDIAL)	25/02/2023 09:02 AM	CLINICAL PATHOLOGY	Dr. Sharma Vasant Kumar	1	No
✓ POST PRANDIAL BLOOD SUGAR (PPBS)	25/02/2023 09:02 AM	BIOCHEMISTRY	Dr. Sharma Vasant Kumar	1	No
✓ FASTING BLOOD SUGAR (FBS)	25/02/2023 09:02 AM	BIOCHEMISTRY	Dr. Sharma Vasant Kumar	1	No
✓ BLOOD GROUP & RH TYPING	25/02/2023 09:02 AM	NARAYANA HRUDAYALAYA BLOOD CENTRE	Dr. Sharma Vasant Kumar	1	No
✓ STOOL ROUTINE EXAMINATION	25/02/2023 09:02 AM	CLINICAL PATHOLOGY	Dr. Sharma Vasant Kumar	1	No
✓ URINE ROUTINE & MICROSCOPY	25/02/2023 09:02 AM	CLINICAL PATHOLOGY	Dr. Sharma Vasant Kumar	1	No
✓ RYTHROCYTE SEDIMENTATION RATE (ESR)	25/02/2023 09:02 AM	HEMATOLOGY	Dr. Sharma Vasant Kumar	1	No

Wt - 77.5 kg

110/70 mmHg

HR - 123

Wt - 95 cm



Service Name	Ordered Date	Service Center	Consultant	Qty	Explicit
COMPLETE BLOOD COUNT (CBC)	25/02/2023 09:02 AM	HEMATOLOGY	Dr. Sharma Vasant Kumar	1	No



25-02-2023 09:02

TRANS-THORACIC ECHO REPORT

Patient MRN : 201-23971
Date : 25.02.2023
Patient Name : Mr.VENKATARAO NESRU
Age/Gender : 38 yrs/male
M-MODE / 2D MEASUREMENTS

LVEF (>55)% : 60%	LVID(d) (40-56)mm : 40mm	LVID (s) mm : 28mm
TAPSE (>16) mm : 20mm	IVS (d) (6-10)mm : 10mm	LV-EDV ml : --
LA (<39) mm : 30mm	PWD (d) (6-10)mm : 10mm	LV-ESV ml : --
RA (<44)mm : 31mm	RV (<35) mm : 27mm	BSA m² : --

DOPPLER MEASUREMENTS
MITRAL VALVE : E/A - 0.7/0.5 M/S, NORMAL LV DIASTOLIC FUNCTION, MR-TRIVIAL

AORTIC VALVE : PG - 3 MMHG /AR-TRIVIAL

TRICUSPID VALVE : TR -TRIVIAL

PULMONARY VALVE : PG - 3 MMHG

PA PRESSURE : PASP- 20 MMHG/ NORMAL PA PRESSURE.

FINDINGS

SITUS SOLITUS, LEVOCARDIA, AV AND VA CONCORDANT, NORMAL GREAT ARTERY RELATIONSHIP

VALVES
MITRAL : NORMAL

AORTIC : NORMAL

DOPPLER MEASUREMENTS
TRICUSPID : NORMAL

PULMONARY : NORMAL

CHAMBERS
LV : NORMAL SIZED, NORMAL LV SYSTOLIC FUNCTION.

RV : NORMAL SIZED, NORMAL RV FUNCTION.

RWMA : NO RWMA

LVOT : NORMAL

LEFT ATRIUM : NORMAL SIZED

RIGHT ATRIUM : NORMAL SIZED

SEPTAE

IVS : INTACT

IAS : INTACT

ARTERIES & VEINS

AORTA : AORTIC ANNULUS - 19 MM, ASCENDING AORTA- 27 MM,
NORMAL ARCH NORMAL SIZED.

PULMONARY ARTERY : NORMAL

IVC, SVC & CS : IVC - 14 MM, NORMAL SIZED, COLLAPSING, NORMAL RA PRESSURE.

PULMONARY VEINS : NORMAL

PERICARDIUM : NORMAL

VEGETATION / THROMBUS / TUMOR: NIL

OTHER FINDINGS:

SINUS RHYTHM- 84 BPM
NO PREVIOUS ECHO REPORT

CONCLUSION

NORMAL CHAMBER DIMENSIONS
NORMAL PA PRESSURE
NO RWMA
NORMAL LV SYSTOLIC FUNCTION
LVEF:- 55-60%


CHANDANA V
CARDIAC SONOGRAPHER

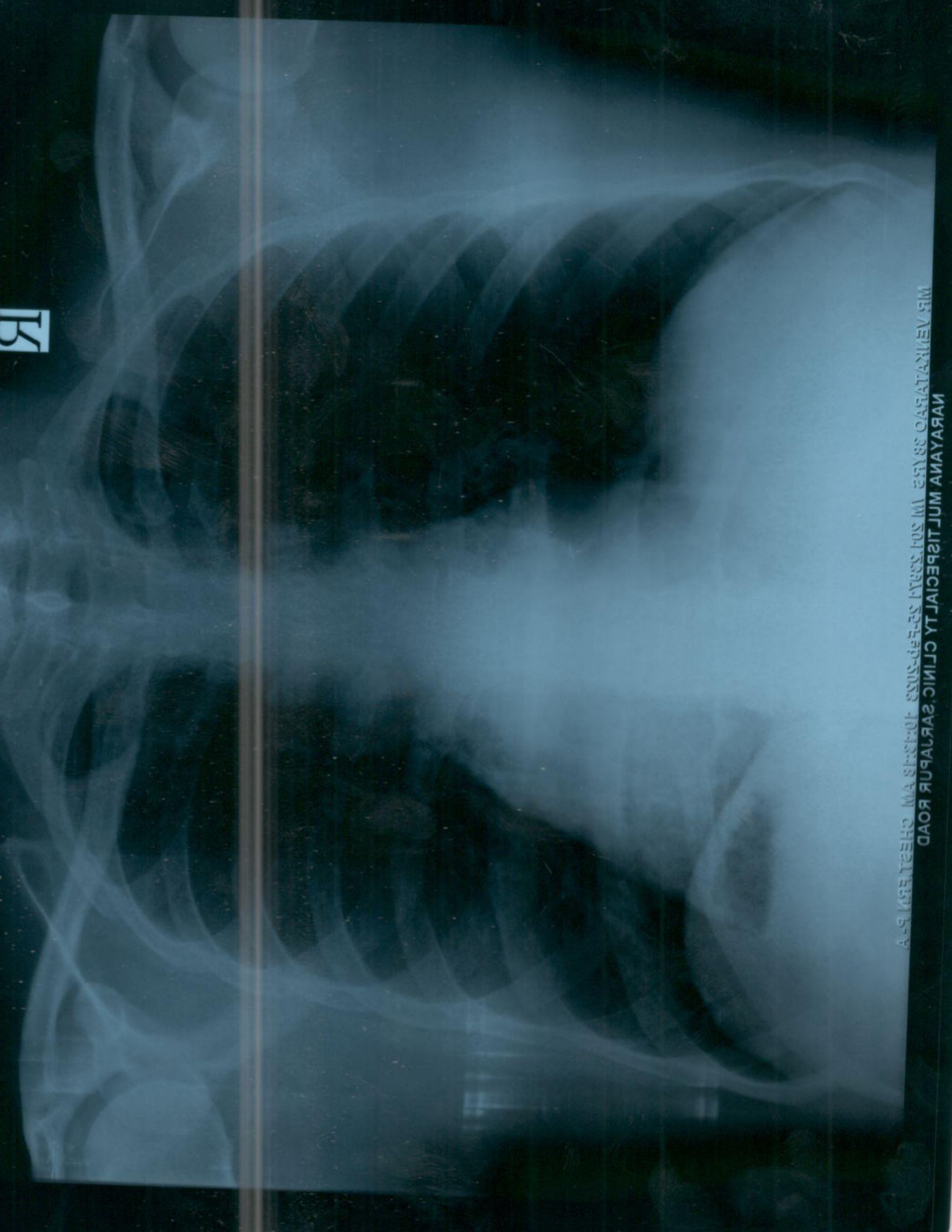


Narayana Hrudayalaya Limited
Above HDFC Bank, 83/3, Doddakanneli, Sarjapura Main Road,
Varthur Hobli, Bangalore - 560035

Tel: + 91 88844 31319, Email : info.sarjapura@narayanahealth.org
Registered Office: 258/A, Bommasandra Industrial Area, Anekal Taluk, Bangalore 560099
Branch Office: Bommasandra Industrial Area, Anekal Taluk, Bangalore 560099

MR. VENKATARAMO SRINIVAS (M) 2011 23221 25759-2022 JODISARI AVI CHESTNERSI P-4
NARAYANA MULTISPECIALTY CLINIC, SARJAPUR ROAD

R



ID: 201-23971
Name: MR. VENKATARAMA
Age: 38 Years
Gender: Male

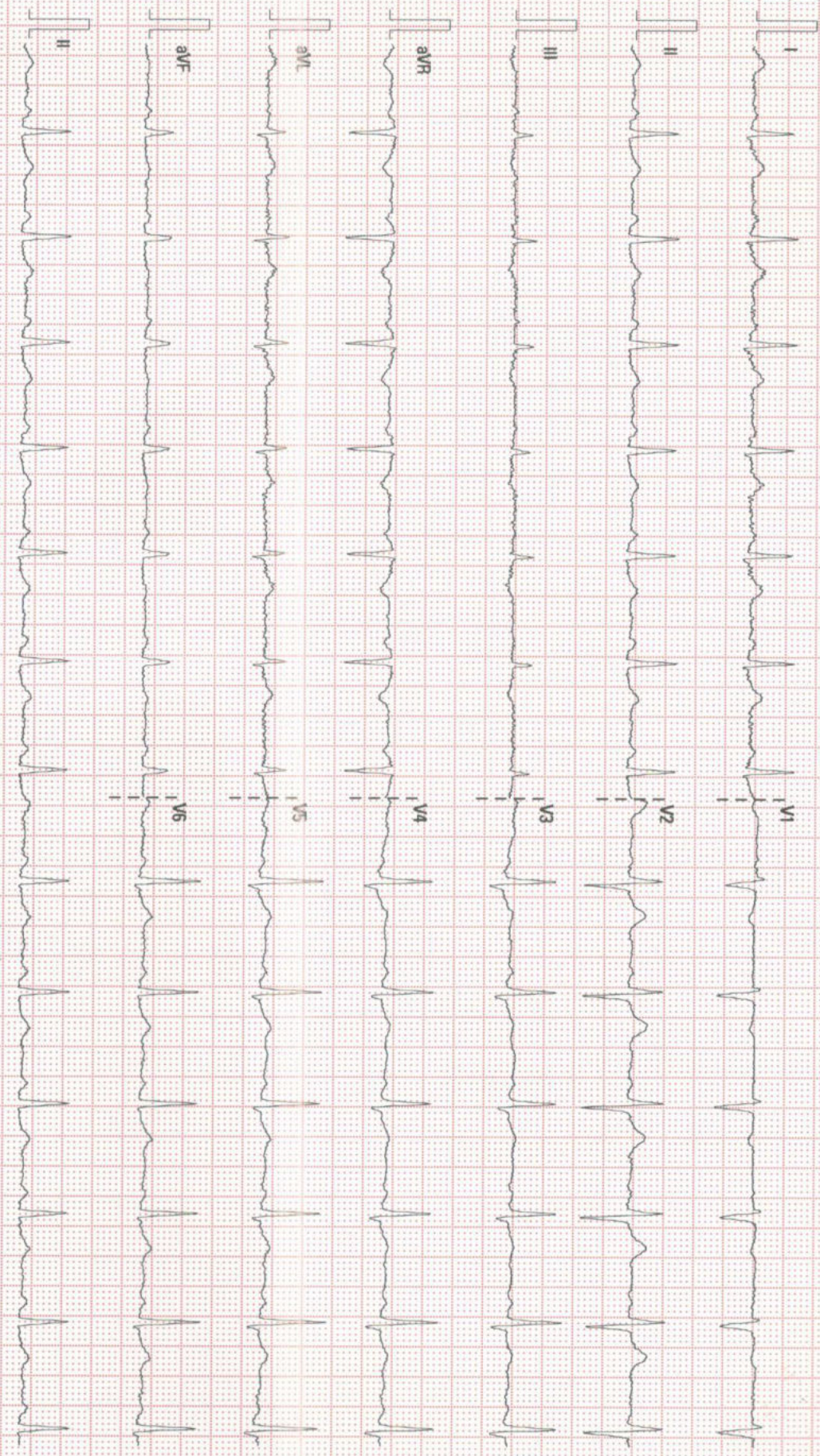
25-02-2023 10:53:23

Vert. Rate	94 bpm
PR Interval	132 ms
QRS Duration	94 ms
QT/QTc Interval	356/398 ms
P/QRS/T Axes	50/49/13 deg
RV5/SV1	1.106/0.629 mV
RV5 + SV1	1.735 mV

Sinus rhythm
Normal ECG

Unconfirmed Di.

Dr. C. Hodges



25 mm/s 10 mm/mV 50 Hz BPR 35 Hz

NARAYANA MSC-SARAJAPUR

02.04.00 V28.4.1

SN.FN

Patient Name : Mr.VENKATARAO NESRU
Age : 38 Years
Referring Doctor : PKG

Patient ID : 201- 23971
Sex : male
Date : 25 .02.2023

ULTRASOUND ABDOMEN AND PELVIS

FINDINGS:

Liver is normal in size (14.4 cm) and shows mild diffuse increase in echogenicity. No intra or extra hepatic biliary duct dilatation. No focal lesions.

Portal vein is normal in size, course and caliber. **CBD** is not dilated.

Gall bladder is normal without evidence of calculi, wall thickening or pericholecystic fluid.

Pancreas to the extent visualized, appears normal in size, contour and echogenicity.

Spleen is normal in size (10.9cm), shape, contour and echopattern. No evidence of mass or focal lesions.

Right Kidney is normal in size (measures 9.8 cm in length & 1.4 cm in parenchymal thickness), position, shape and echopattern. Corticomedullary differentiation is maintained. No evidence of calculi or hydronephrosis.

Left Kidney is normal in size (measures 10.2 cm in length & 1.6 cm in parenchymal thickness), position, shape and echopattern. Corticomedullary differentiation is maintained. No evidence of calculi or hydronephrosis.

Retroperitoneum – Obscured by bowel gas.

Urinary Bladder is minimally distended. Wall thickness is normal. No evidence of calculi, mass or mural lesion.

Prostate is normal in echopattern and size, (Volume =12cc).

Fluid - There is no ascites or pleural effusion.

IMPRESSION:

- **GRADE I FATTY LIVER**



Dr. Ananthakshmi.S
Sonologist

Report

