

CONSULTATION SUMMARY

Patient MRN : 17540000327742
Patient Name : Saurabh Ranjan
Gender/Age/Dob : Male , 40 Years , 23/02/83
Patient Phone No : 9953296205
Patient Address : shiv vatika ashwini nagar,
Raipur, Chhattisgarh, India

Consultation Date: 25/03/2023 01:55 PM
Consultant : Dr. Mukesh Kumar Sharma
(GENERAL MEDICINE)
Consultation Type : OP , NEW VISIT



CLINICAL DIAGNOSIS

• DYSLIPIDEMIA

CHIEF COMPLAINTS & HISTORY OF PRESENT ILLNESS





- CAME FOR HEALTH CHECK UP :
- NO COMPLAIN :
- NO H/O CO-MORBIDITIES :

VITALS

Blood Pressure: 119/83 mmHg Heart Rate: 118 bpm Temperature: 98.2 F
Respiratory Rate: 28 /min
SPO2 : 100 % , Room air
Weight: 68 kg
Fall Score: Low Pain Score: 0

MEDICATION ORDER

DRUG NAME

- 1) FENOFIBRATE-TABLET-145MG-STANLIP


- 2) BENFOTIAMIN+VB12+ALA+FOLICACID+INOSITOL-TABLET-BALAVIN FORTE

- 3) FOLIC ACID-TABLET-5MG-FOLVITE


PATIENT INSTRUCTION

Patient Instruction: Once Daily (0 - 0 - 0 - 1)
Tablet Orally After Food For 30 Days , Qty: 30 ,
Start Date: Mar 25, 2023 , End Date: Apr 23, 2023

Patient Instruction: Once Daily (1 - 0 - 0 - 0)
Tablet After Food , Qty: 1 , Start Date: Mar 25, 2023

Patient Instruction: Once Daily (1 - 0 - 0 - 0) After
Food For 30 Days , Qty: 1 , Start Date: Mar 25, 2023 , End Date: Apr 23, 2023

NOTES



NH MMI Narayana Superspeciality Hospital

(A unit of Narayana Hrudayalaya Limited) CIN: L85110KA2000PLC027497 | GST TIN: 22AABCN1665J1Z1
Registered Office: 258/A, Bommasandra Industrial Area, Anekal Taluk, Bangalore - 560099
Hospital Address: New Dhamteri Road, Lalpur, Raipur - 492001
Tel +91 771 4210901 / 902 | Fax +91 771 408 1106 | Email: info.rpr@narayanahealth.org | www.narayanahealth.org



Page 1 of 2
Appointments
1800-309-0309
Emergencies
8821-818181

LIFE STYLE MODIFICATIONS AS ADVISED
LOW SALT DIET, AVOID SPICY N JUNK FOODS
REGULAR EXERCISE

CONSULTANT DETAILS



Dr. Mukesh Kumar Sharma , CONSULTANT , GENERAL MEDICINE
Registration No : 5549/2014

One free consultation with the same doctor within next 6 days.


Printed By: Dr. Mukesh Kumar Sharma | Printed On: 25.03.2023 16:28



CONSULTATION SUMMARY

Patient MRN : 17540000327742
Patient Name : Saurabh Ranjan
Gender/Age/Dob : Male , 40 Years , 23/02/83
Patient Phone No : 9953296205
Patient Address : shiv vatika ashwini nagar,
Raipur, Chhattisgarh, India

Consultation Date: 25/03/2023 11:01 AM
Consultant : Dr.Kshitij Dwivedi (DENTAL)
Consultation Type : OP , NEW VISIT



CHIEF COMPLAINTS & HISTORY OF PRESENT ILLNESS

- regular health check up :

DENTAL EXAMINATION

- calculus +++
stains ++

CONSULTANT DETAILS



Dr.Kshitij Dwivedi , VISITING CONSULTANT , DENTAL
Registration No : 29664 A

One free consultation with the same doctor within next 6 days.

Printed By: Dr.Kshitij Dwivedi | Printed On: 25.03.2023 11:03



NHMMI Narayana Superspeciality Hospital

(A unit of Narayana Hrudayalaya Limited) CIN: L65110KA2000PLC027497 | GSTIN- 22AABCN1683J1Z1
Registered Office: 25B/A, Bommasandra Industrial Area, Anekal Taluk, Bangalore - 560099
Hospital Address: New Dhamteri Road, Lalpur, Raipur - 492001
Tel +91 771 4210901 / 902 | Fax +91 771 408 1106 | Email: info.rpr@narayanahealth.org | www.narayanahealth.org



Page 1 of 1
Appointments
1800-309-0309
Emergencies
8821-818181

Saurabh Ranjan

25/3/2023

uolm 101

No. DM, 2ITD

No Ocular complaint

OE V 6/6 (U-R) 20T OD
A 6/6 (U-L) 20T OD

N 6 (U-R)

Ms } OK



AMIS

6 Veldrop / Refresh Tear gel
0 0 0
- Cap. Lyustar 10D x 15 days

Dr. Renuka Sharma
DOMS, (Ophthalmology)
Reg.No : CGMC-2434/2009
NHMMI Raipur (C.G.)



DEPARTMENT OF LABORATORY MEDICINE

Patient Name : Saurabh Ranjan MRN : 17540000327742 Gender/Age : MALE , 40y (23/02/1983)
Collected On : 25/03/2023 10:28 AM Received On : 25/03/2023 11:15 AM Reported On : 25/03/2023 05:03 PM
Barcode : 0R2303250020 Specimen : Serum Consultant : Dr. Mukesh Kumar Sharma(GENERAL MEDICINE)
Sample adequacy : Satisfactory Visit No : OP-001 Patient Mobile No : 9953296205

IMMUNOLOGY

Test	Result	Unit	Biological Reference Interval
THYROID PROFILE (T3, T4, TSH)			
Tri Iodo Thyronine (T3) (Chemiluminescence)	1.39	ng/mL	0.97-1.69
Thyroxine (T4) (Chemiluminescence)	10.1	ug/dl	5.53-11.0
TSH (Thyroid Stimulating Hormone) (Chemiluminescence)	4.036	mIU/mL	0.465-4.68

--End of Report--

Dr. Neeraj Naik
M.B.B.S ,D.C.P Consultant Pathologist
Consultant

Note

- Abnormal results are highlighted.
- Results relate to the sample only.
- Kindly correlate clinically.



NHMMI Narayana Superspeciality Hospital

(A unit of Narayana Hrudayalaya Limited) CIN: LBS110KA2000PLC027497 | GSTIN: 22AABGN1665J1Z1
Registered Office: 258/A, Bommasandra Industrial Area, Anekal Taluk, Bangalore - 560099
Hospital Address: New Dharmtari Road, Lalpur, Raipur - 492001
Tel +91 771 4210901 / 902 | Fax +91 771 408 1106 | Email: info_rpr@narayanahealth.org | www.narayanahealth.org



Appointments
1800-309-0309

Emergencies
8821-818181

DEPARTMENT OF LABORATORY MEDICINE

Patient Name : Saurabh Ranjan MRN : 17540000327742 Gender/Age : MALE , 40y (23/02/1983)
 Collected On : 25/03/2023 10:28 AM Received On : 25/03/2023 11:15 AM Reported On : 25/03/2023 03:21 PM
 Barcode : 2R2303250111 Specimen : Whole Blood - ESR Consultant : Dr. Mukesh Kumar Sharma(GENERAL MEDICINE)
 Sample adequacy : Satisfactory Visit No : OP-001 Patient Mobile No : 9953296205

HAEMATOTOLOGY

Test	Result	Unit	Biological Reference Interval
Erythrocyte Sedimentation Rate (ESR) (Westergren Method)	35 H	mm/hr	0.0-10.0
COMPLETE BLOOD COUNT (CBC)			
Haemoglobin (Hb%) (Photometric Measurement)	13.59 L	g/dL	14.0-16.0
Red Blood Cell Count (Electrical Impedance)	4.62	millions/ μ L	4.5-6.5
PCV (Packed Cell Volume) / Hematocrit (Calculated)	40.2	%	40.0-54.0
MCV (Mean Corpuscular Volume) (Derived From RBC Histogram)	87.1	fL	76.0-96.0
MCH (Mean Corpuscular Haemoglobin) (Calculated)	29.4	pg	27.0-32.0
MCHC (Mean Corpuscular Haemoglobin Concentration) (Calculated)	33.8	%	30.0-36.0
Red Cell Distribution Width (RDW) (Derived)	13.8	%	11.6-14.0
Platelet Count (Electrical Impedance Plus Microscopy)	143 L	Thousand / μ L	150.0-450.0
Mean Platelet Volume (MPV)	13.67 H	fL	7.0-11.7
Total Leucocyte Count(WBC) (Electrical Impedance)	6.43	Thous/cumm	4.0-10.0
DIFFERENTIAL COUNT (DC)			
Neutrophils (VCS Technology Plus Microscopy)	72	%	40.0-75.0
Lymphocytes (VCS Technology Plus Microscopy)	23	%	20.0-45.0

NH MMI Narayana Superspeciality Hospital

(A unit of Narayana Hrudayalaya Limited) CIN: L55110KA2000PLC027497 | GSTIN: 22AABCN1685J1Z1
 Registered Office: 258/A, Bommasandra Industrial Area, Anekal Taluk, Bangalore - 560099
 Hospital Address: New Dhantari Road, Lalpur, Raipur - 492001
 Tel +91 771 4210901 / 902 | Fax +91 771 408 1106 | Email: info.rpr@narayanahealth.org | www.narayanahealth.org



Patient Name : Saurabh Ranjan MRN : 17540000327742 Gender/Age : MALE , 40y (23/02/1983)

Monocytes (VCS Technology Plus Microscopy)	04	%	2.0-10.0
Eosinophils (VCS Technology Plus Microscopy)	01	%	0.0-6.0
Basophils	00	%	0.0-1.0
Absolute Neutrophil Count	4.63	-	-
Absolute Lymphocyte Count	1.48	-	-
Absolute Monocyte Count	0.26	-	-
Absolute Eosinophil Count	0.06	-	-
BLOOD GROUP & RH TYPING			
Blood Group	"O"	-	-
RH Typing	Positive	-	-



Dr. Smriti Rathore
 M.B.BS, MD Pathology
 Consultant

BIOCHEMISTRY

Test	Result	Unit	Biological Reference Interval
Fasting Blood Sugar (FBS) (Hexokinase)	110 H	mg/dL	70.0-99.0
Post Prandial Blood Sugar (PPBS)	129	mg/dL	120.0-140.0
HBA1C			
HbA1c (HPLC NGSP Certified)	4.1	%	Both; Normal: 4.0-5.6 Both; Pre Diabetes: 5.7-6.4 Both; Diabetes: => 6.5 ADA Recommendation 2017
Estimated Average Glucose	70.97		-



NH MMI Narayana Superspeciality Hospital

(A unit of Narayana Hrudayalsya Limited) CIN: L85110KA2000PLC027497 | GSTIN- 22AABCN1685J1 ZI
 Registered Office: 25B/A, Bommasandra Industrial Area, Anekal Taluk, Bangalore - 560099
 Hospital Address: New Dhamtari Road, Lalpur, Raipur - 492001
 Tel +91 771 4210901 / 902 | Fax +91 771 408 1106 | Email: info_rpr@narayanahealth.org | www.narayanahealth.org

Patient Name : Saurabh Ranjan MRN : 17540000327742 Gender/Age : MALE , 40y (23/02/1983)

Interpretation:

1. HbA1C above 6.5% can be used to diagnose diabetes provided the patient has symptoms. If the patient does not have symptoms with HbA1C > 6.5%, repeat measurement on further sample. If the repeat test result is < 6.5%, consider as diabetes high risk and repeat measurement after 6 months.
2. HbA1C measurement is not appropriate in diagnosing diabetes in children, suspicion of type 1 diabetes, symptoms of diabetes for less than 2 months, pregnancy, hemoglobinopathies, medications that may result sudden increase in glucose, anemia, renal failure, HIV infection, malignancies, severe chronic hepatic, and renal disease.
3. Any sample with >15% should be suspected of having a haemoglobin variant.

LIPID PROFILE (CHOL,TRIG,HDL,LDL,VLDL)

Cholesterol Total (Cholesterol Oxidase/peroxidase)	180	mg/dL	0.0-200.0
Triglycerides (LPL/GK)	328 H	mg/dL	0.0-150.0
HDL Cholesterol (HDL) (Dextran Sulphate/ PEG Cholesterol Esterase)	31 L	mg/dL	40.0-60.0
Non-HDL Cholesterol	149.0	-	-
LDL Cholesterol (Cholesterol Oxidase Esterase Peroxidase)	84	mg/dL	0.0-100.0
VLDL Cholesterol (Calculated)	66 H	mg/dL	0.0-40.0
Cholesterol /HDL Ratio (Calculated)	5.9 H	-	0.0-5.0

LIVER FUNCTION TEST(LFT)

Bilirubin Total (Caffeine Benzoate)	1.6 H	mg/dL	0.2-1.3
Conjugated Bilirubin (Direct) (Caffeine Benzoate)	0.3	mg/dL	0.0-0.4
Unconjugated Bilirubin (Indirect) (Calculated)	1.3 H	-	0.2-0.8
Total Protein (Biuret Method)	8.5 H	gm/dL	6.3-8.3
Serum Albumin (Bromocresol Purple Dye Binding)	5.5 H	gm/dL	3.5-5.0
Serum Globulin (Calculated)	3	-	2.3-3.5
Albumin To Globulin (A/G)Ratio	1.83	-	1.0-2.1
SGOT (AST) (UV With Pyridoxal-5-phosphate)	24	IU/L	17.0-59.0
SGPT (ALT) (UV With Pyridoxal-5-phosphate)	24	U/L	21.0-72.0



NHMMI Narayana Superspeciality Hospital

(A unit of Narayana Hrudayalaya Limited) CIN: L85110KA2000PLC027497 | GSTIN- 22AABCN1885J1Z1
 Registered Office: 258/A, Bommasandra Industrial Area, Anekal Taluk, Bangalore - 560099
 Hospital Address: New Dhamtari Road, Lalpur, Raipur - 492001
 Tel +91 771 4210901 / 902 | Fax +91 771 408 1108 | Email: info.rpr@narayanahealth.org | www.narayanahealth.org



Patient Name : Saurabh Ranjan MRN : 17540000327742 Gender/Age : MALE , 40y (23/02/1983)

Alkaline Phosphatase (ALP)	112	IU/L	38.0-126.0
Gamma Glutamyl Transferase (GGT) (GCNA)	24	U/L	15.0-73.0

RENAL PACKAGE - 2 (RFT FASTING)

Fasting Blood Sugar (FBS) (Hexokinase)	106 H	mg/dL	70.0-99.0
Blood Urea Nitrogen (BUN) (Urease)	9	mg/dL	9.0-20.0

SERUM CREATININE

Serum Creatinine (Jaffe's Kinetic IDMS)	1.0	mg/dL	Male :0.66-1.25 Female :0.52-1.04
eGFR (Calculated)	82.8	mL/min/1.73m ²	Both: <60 indicative of renal impairment Both: Note:eGFR is inaccurate for Hemodynamically unstable patients eGFR is not applicable for less than 18

Serum Sodium (Indirect IMT)	144	mmol/L	137.0-150.0
Serum Potassium (Indirect IMT)	4.5	mmol/L	3.5-5.1
Serum Chloride	105	mmol/L	95.0-106.0
Serum Calcium (Cresol Complex)	10.1	mg/dL	8.4-10.2
Serum Magnesium (Methyl Thymol Blue Dye Binding)	2.0	mg/dL	1.6-2.3
Serum Uric Acid (Uricase)	6.5	mg/dL	3.5-8.5
Serum Phosphorus (Phosphomolybdate Reduction)	3.1	mg/dL	2.5-4.5



Dr. Smriti Rathore
 M.B.BS, MD Pathology
 Consultant



CLINICAL PATHOLOGY

NHMMI Narayana Superspeciality Hospital

(A unit of Narayana Hrudayalaya Limited) CIN: L85110KA2000PLC027497 | GSTIN- 22AABCN1685J1Z1
 Registered Office: 258/A, Bommasandra Industrial Area, Anekal Taluk, Bangalore - 560099
 Hospital Address: New Dhamtari Road, Lalpur, Raipur - 492001
 Tel +91 771 4210901 / 902 | Fax +91 771 408 1106 | Email: info.rpr@narayanahealth.org | www.narayanahealth.org



Appointments
1800-309-0309

Emergencies
8821-818181

Patient Name : Saurabh Ranjan MRN : 17540000327742 Gender/Age : MALE , 40y (23/02/1983)

Test	Result	Unit	Biological Reference Interval
URINE ROUTINE & MICROSCOPY			
PHYSICAL EXAMINATION			
Volume	.35	ml	-
Colour	Pale Yellow	-	-
Appearance	Slightly Turbid	-	-
CHEMICAL EXAMINATION			
pH(Reaction)	5.5	-	4.5-7.5
Sp. Gravity (Automated)	1.010	-	1.002-1.03
Protein	Negative	-	Negative
Urine Glucose	Negative	-	Negative
Ketone Bodies	Negative	-	Negative
Bile Salts	Negative	-	Negative
Bile Pigment (Bilirubin)	Negative	-	Negative
Urobilinogen	Negative	-	Negative
Urine Leucocyte Esterase	Negative	-	Negative
Blood Urine	Negative	-	Negative
Nitrite	Negative	-	Negative
MICROSCOPIC EXAMINATION			
Pus Cells (Microscopy)	4-6	/hpf	2-3
RBC (Microscopy)	NOT SEEN	/hpf	0-0
Epithelial Cells (Microscopy)	2-3	/hpf	2-3.



NH MMI Narayana Superspeciality Hospital

(A unit of Narayana Hrudayalaya Limited) CIN: L8511GKA2000PLC027497 | GSTIN: 22AABCN1685J1ZI
 Registered Office: 258/A, Bommasandra Industrial Area, Anekal Taluk, Bangalore - 560099
 Hospital Address: New Dhamtari Road, Lalpur, Raipur - 492001
 Tel +91 771 4210901 / 902 | Fax +91 771 408 1106 | Email: info.rpr@narayanahealth.org | www.narayanahealth.org



Appointments
1800-309-0309

Emergencies
8821-818181

Patient Name : Saurabh Ranjan MRN : 17540000327742 Gender/Age : MALE , 40y (23/02/1983)

Crystals	NOT SEEN	-	-
Casts	NOT SEEN	-	-
Bacteria	NOT SEEN	-	-
Yeast Cells	NOT SEEN	-	-
Mucus	NOT SEEN	-	-
Urine For Sugar (Fasting)	NEGATIVE	-	-
Urine For Sugar (Post Prandial)	NEGATIVE	-	-

--End of Report--



Dr. Neeraj Naik
 M.B.B.S ,D.C.P Consultant Pathologist
 Consultant

Note

- Abnormal results are highlighted.
- Results relate to the sample only.
- Kindly correlate clinically.



NH MMI Narayana Superspeciality Hospital

(A unit of Narayana Hrudayalaya Limited) CIN: L85110KA2600PLC027497 | GSTIN- 22AABCN1685J1Z1
 Registered Office: 258/A, Bommasandra Industrial Area, Anekal Taluk, Bangalore - 560099
 Hospital Address: New Dhamsarl Road, Lalpur, Raipur - 492001
 Tel +91 771 4210901 / 902 | Fax +91 771 408 1106 | Email: info.rpr@narayanahealth.org | www.narayanahealth.org



Appointments
1800-309-0309

Emergencies
8821-818181

ECHOCARDIOGRAPHY REPORT

Patient ID	: 17540000327742	Report Date	: 25/03/2023
Patient Name:	: Mr. Saurabh Ranjan		
Age / Gender	: 40 Years/ Male		

MEASUREMENT

AO : 22 (20 - 35)mm LVID(d) : 36 (36 - 52)mm IVS: 08 (06 - 11)mm
LA : 25 (19 - 40)mm LVID s : 25 (23 - 39)mm PW: 11 (06 - 11)mm
EF : 60%

VALVES

Mitral Valve : Normal
Aortic valve : Normal
Tricuspid Valve : Trivial TR, PASP-15+RA
Pulmonary Valve : Normal

CHAMBERS

Left Atrium : Normal
Right Atrium : Normal
Left Ventricle : Normal
Right Ventricle : Normal

SEPTAE

IVS : Intact
IAS : Intact

GREAT ARTERIES

Aorta : Normal
Pulmonary Artery : Normal



Patient ID : 17540000327742

Report Date : 25/03/2023

Patient Name: : Mr. Saurabh Ranjan

Age / Gender : 40 Years/ Male

WALL MOTION ABNORMALITIES

No RWMA at rest

FINAL DIAGNOSIS

- No RWMA at rest
- Normal LV systolic function. LVEF-60%.
- Normal cardiac chambers dimension
- Trivial TR, PASP-15+RA
- E>A
- IVC normal & collapsing >50% with respiratory variation.
- No I/C clot, vegetation or pericardial effusion



Dr. S. S. PADHI
MD, DM, PDF, FESC
Chief Consultant, Invasive Cardiology

DR. PRASHANT MADHARIA
MD, PGDCC
Consultant Non-Invasive Cardiology

DR. SNEHIL GOSWAMI
MD, DNB (Cardiology)
Consultant Invasive Cardiology



Dr. JINESH JAIN
MD, DM
Consultant, interventional Cardiology



NAME: MR. SAURABH RANJAN

AGE: 40YRS/M MRN:327742

REF. BY: DR. M.SHARMA

DATE: 25.03.2023

SONOGRAPHY OF ABDOMEN AND PELVIS

The Real time, B mode, gray scale sonography was performed.

LIVER : The liver is normal in size & reveals increased echotexture grade-I.

PORTAL VEIN : The portal vein is normal in calibre.

GALL BLADDER : The gall bladder is partially distended. Few echogenic foci with comet tail artifact on wall - Cholesterosis.

Visualized proximal CBD is normal in calibre.

SPLEEN : The spleen is normal in size and shape. No evidence of focal lesion is noted.

PANCREAS :The pancreas is poorly visualized.

B/L KIDNEYS :

The right kidney measures - 10.2 x 3.4cm and left kidney measures - 9.8 x 3.6cm in size. Both kidneys reveal normal cortical echotexture and have smooth margins. Cortico-medullary differentiation is maintained. No calculus or hydronephrosis is seen.

URINARY BLADDER : The urinary bladder is partially distended.

PROSTATE: The prostate is normal in size 28cc.

No free fluid is seen in the peritoneal cavity.

Excessive intrabowel gases are noted.

IMPRESSION :

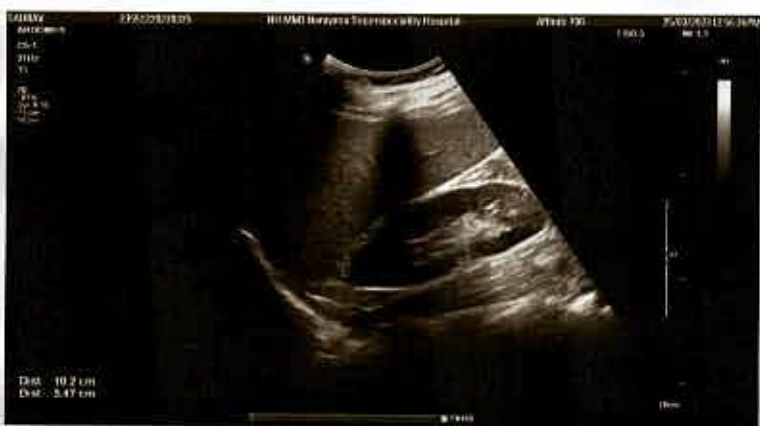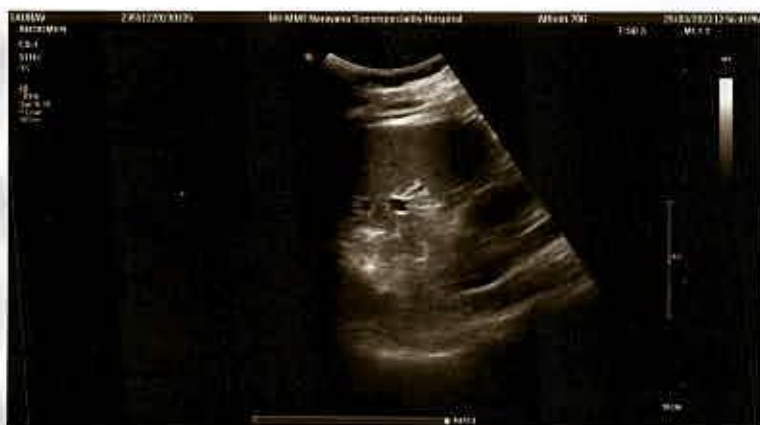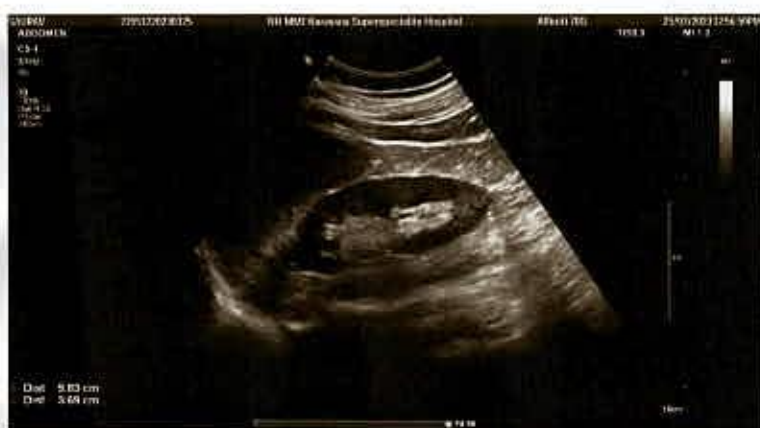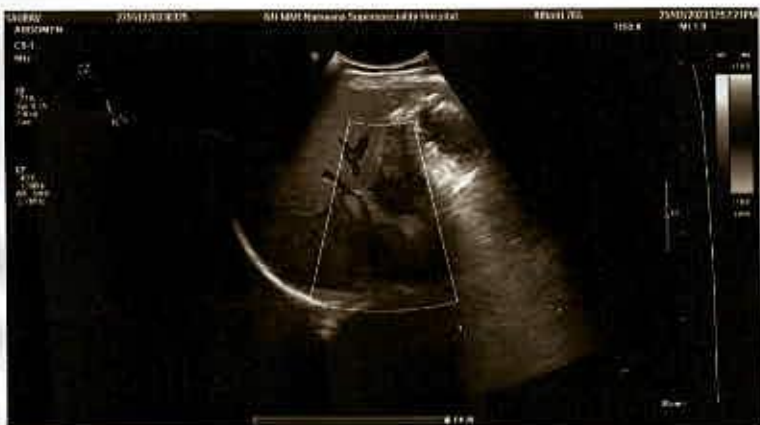Grade-I fatty liver.

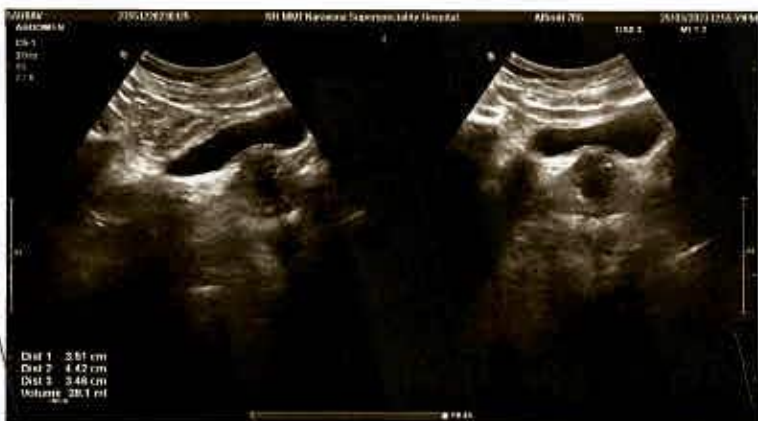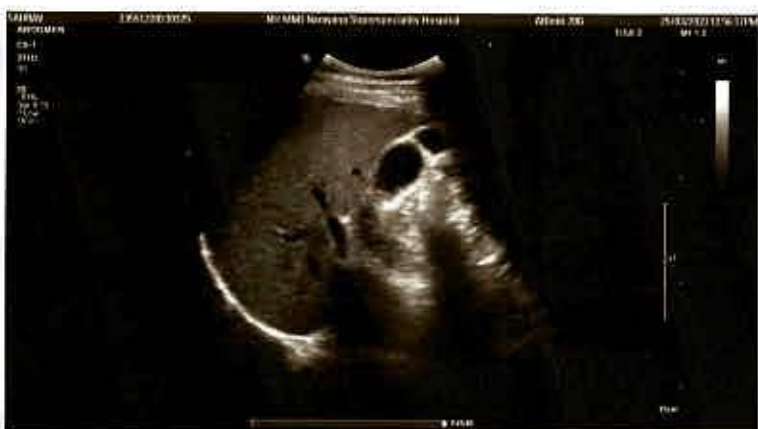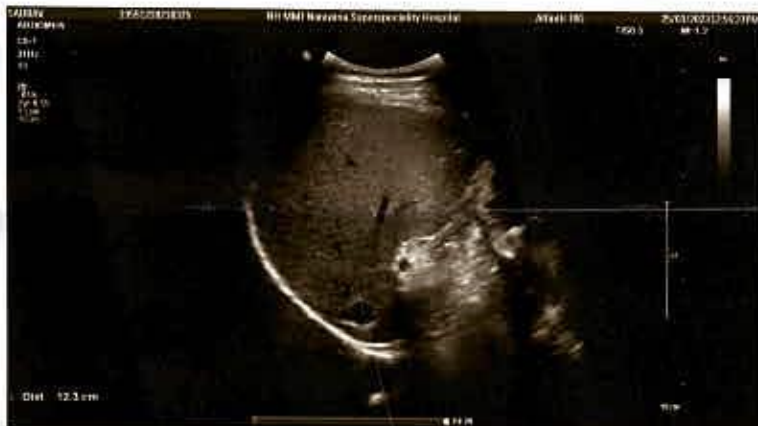Echogenic foci with comet tail artifact on GB wall - Cholesterosis.

ADVISED: Clinical correlation & appropriate further evaluation.



DR RANJANA KEDIA
MBBS, CBET
CONSULTANT SONOLOGIST





ID: 1754000927742

Name: MR SAURABH RANJAN

Age: 40 Years

Gender: Male

2023-03-25 09:59:33

Vent. Rate
 PR Interval
 QRS Duration
 QT/QTc Interval
 P/QRS/T Axes
 QTc/QTc

116 bpm
 102 ms
 76 ms
 302/400 ms
 67/1/63 deg

Sinus tachycardia
 Short PR interval
 Inferior-infarct - age undetermined
 Abnormal ECG

Unconfirmed Diagnosis

Please Xerox This Copy

