

**Diwakar Diagnostic Centre**  
E-7/636, Arera Colony, Bhopal

734 / MR. DINESH ARYA / 32 Yrs / M / 170 Cms / 77 Kg Date: 27-Aug-2022 Refd By : BOB

**Report**

(GEM213180307)(R)Allengers



**Report :**

TEST OBJECTIVE : ROUTINE CHECK UP  
RISK FACTOR : MALE  
ACTIVITY : MODERATE ACTIVE  
OTHER INVESTIGATION : ROUTINE BLOOD INVESTIGATION,USG,X RAY  
REASON FOR TERMINATION : HEART RATE ACHIEVED  
EXERCISE TOLERANCE : AVERAGE  
EXERCISE INDUCED ARRHYTHMIAS : NO  
HAEMODYNAMIC RESPONSE : NORMAL  
CHRONOTROPIC RESPONSE : NORMAL  
FINAL IMPRESSION : STRESS TEST IS NEGATIVE FOR EXERCYISE INDUCED ISCHAEMIC HEART DISEASE



Doctor : Cardiologist



734 / MR. DINESH ARYA / 32 Yrs / M / 170 Cms / 77 Kg Date: 27-Aug-2022 Refd By : BOB

(GEM213180307)(R)Allengers

Stage	Time	Duration	Belt Speed (mph)	Elevation	METs	Rate	%THR Achieved	BP	RPP	PVC	Comments
Supine	00:07	0:01	00.0	00.0	01.0	90	48%	---/---	000	00	
Standing	00:17	0:01	00.0	00.0	01.0	86	46%	---/---	000	00	
HV	00:20	0:01	00.0	00.0	01.0	086	46%	---/---	000	00	
Warm Up	00:28	0:02	01.7	10.0	01.0	084	45%	---/---	000	00	
ExStart	00:32	0:06	01.7	10.0	01.1	084	45%	---/---	000	00	
BRUCE Stage 1	03:32	3:00	01.7	10.0	04.7	134	71%	130/80	174	00	
BRUCE Stage 2	06:32	3:00	02.5	12.0	07.1	164	87%	140/90	229	00	
PeakEx	07:32	1:00	03.4	14.0	08.2	175	93%	140/90	245	00	
Recovery	08:31	1:00	00.0	00.0	01.2	119	63%	146/90	173	00	
Recovery	09:31	2:00	00.0	00.0	01.0	115	61%	136/86	156	00	
Recovery	09:36	2:04	00.0	00.0	01.0	115	61%	136/86	156	00	

**Findings :**

Exercise Time : 07:01  
 Max HR Attained : 175 bpm 93% of Target 188  
 Max BP Attained : (Sys) 146/90  
 Max Workload Attained : 8.2 Fair response to induced stress  
 Test End Reasons : Heart Rate Achieved

Doctor : Cardiologist

734 / MR. DINESH ARYA / 32 Yrs / M / 170 Cms / 77 Kg / HR : 86

STANDING



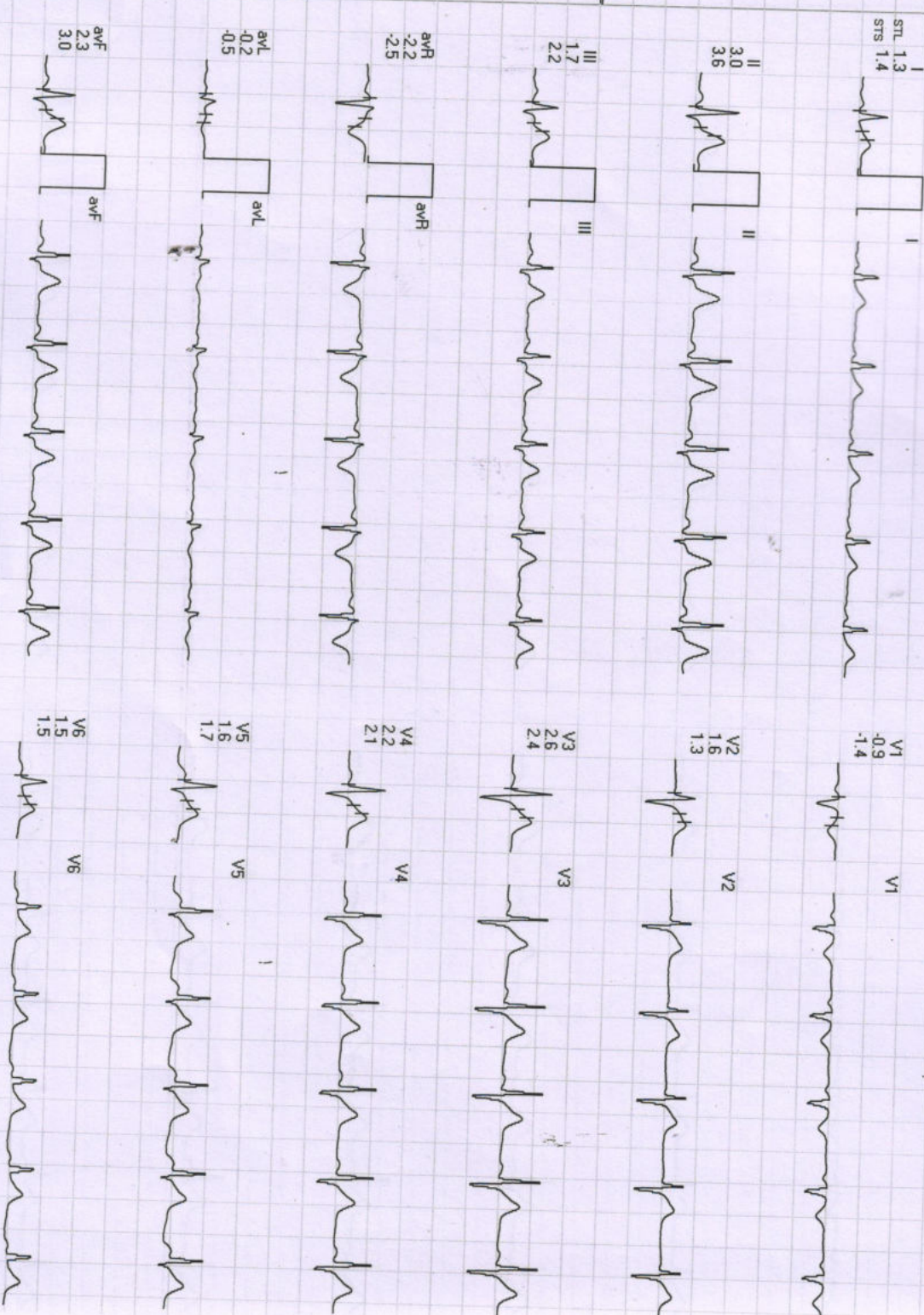
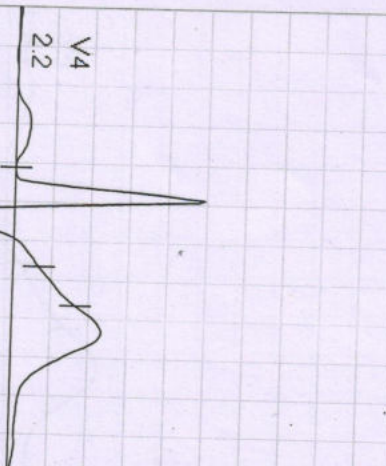
Date: 27-Aug-2022 10:41:40 AM

METS: 1.0/ 86 bpm 45% of THR BP: - / - mmHg Raw ECG/ BLC On/ Notch On/ HF 0.05 Hz/ LF 20 Hz

4X

60 ms Post J

ExTime: 00:16 0.0 mph, 0.0%  
25 mm/Sec. 1.0 Cm/mV



Lead	STL	STS
I	1.3	1.4
II	3.0	3.6
III	1.7	2.2
aVR	-2.2	-2.5
aVL	-0.2	-0.5
aVF	2.3	3.0
V1	-0.9	-1.4
V2	1.6	1.3
V3	2.6	2.4
V4	2.2	2.1
V5	1.6	1.7
V6	1.5	1.5

REMARKS:




734 / MR. DINESH ARYA / 32 Yrs / M / 170 Cms / 77 Kg / HR : 86

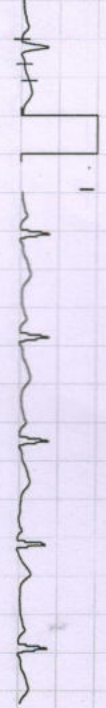
Date: 27-Aug-2022 10:41:40 AM METS: 1.0/ 86 bpm 45% of THR BP: - / - mmHg Raw ECG/ BLC On/ Notch On/ HF 0.05 Hz/LF 20 Hz

EXTime: 00:19 0.0 mph, 0.0%  
25 mm/Sec. 1.0 Cm/mV

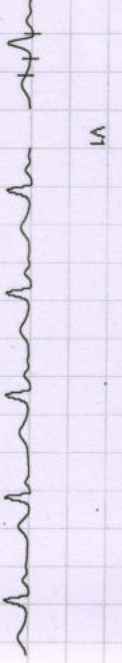
4X 80 mS Post J




I  
STL 1.0  
STS 0.8



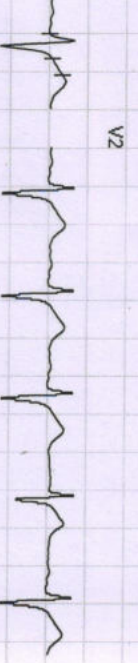V1  
-0.8  
-0.8



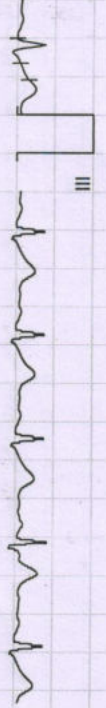II  
2.5  
2.3



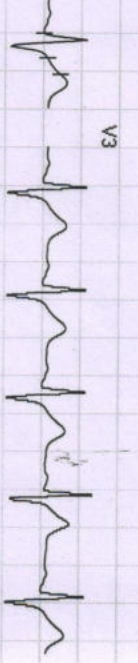V2  
1.7  
1.7  
1.6



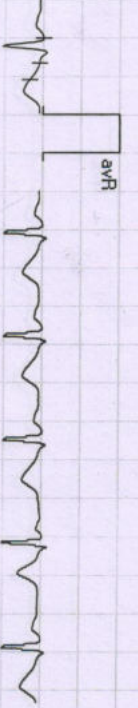III  
1.6  
1.5



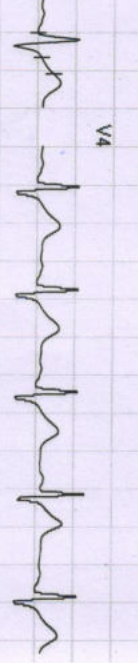
V3  
2.2  
2.2  
2.1



avR  
-1.8  
-1.6



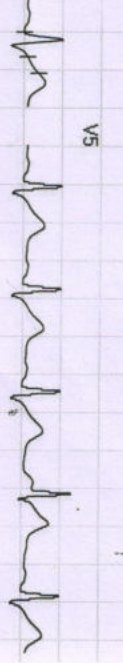V4  
2.1  
2.1  
2.0



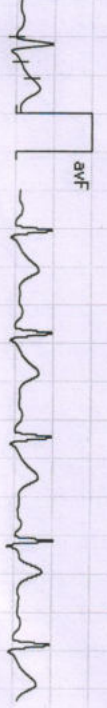avL  
-0.1  
-0.1



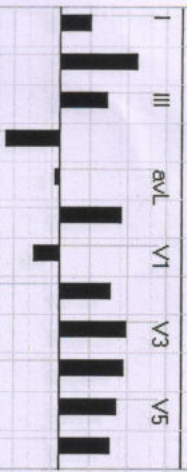

V5  
1.9  
1.9  
1.8



avF  
2.0  
1.9



V6  
1.7  
1.7  
1.5



REMARKS:  
I III avL V1 V3 V5  
II avR avF V2 V4 V6

734/MR DINESH ARYA / 32 Yrs / M / 170 Cms / 77 Kg / HR : 90

SUPINE



Date: 27-Aug-2022 10:41:40 AM

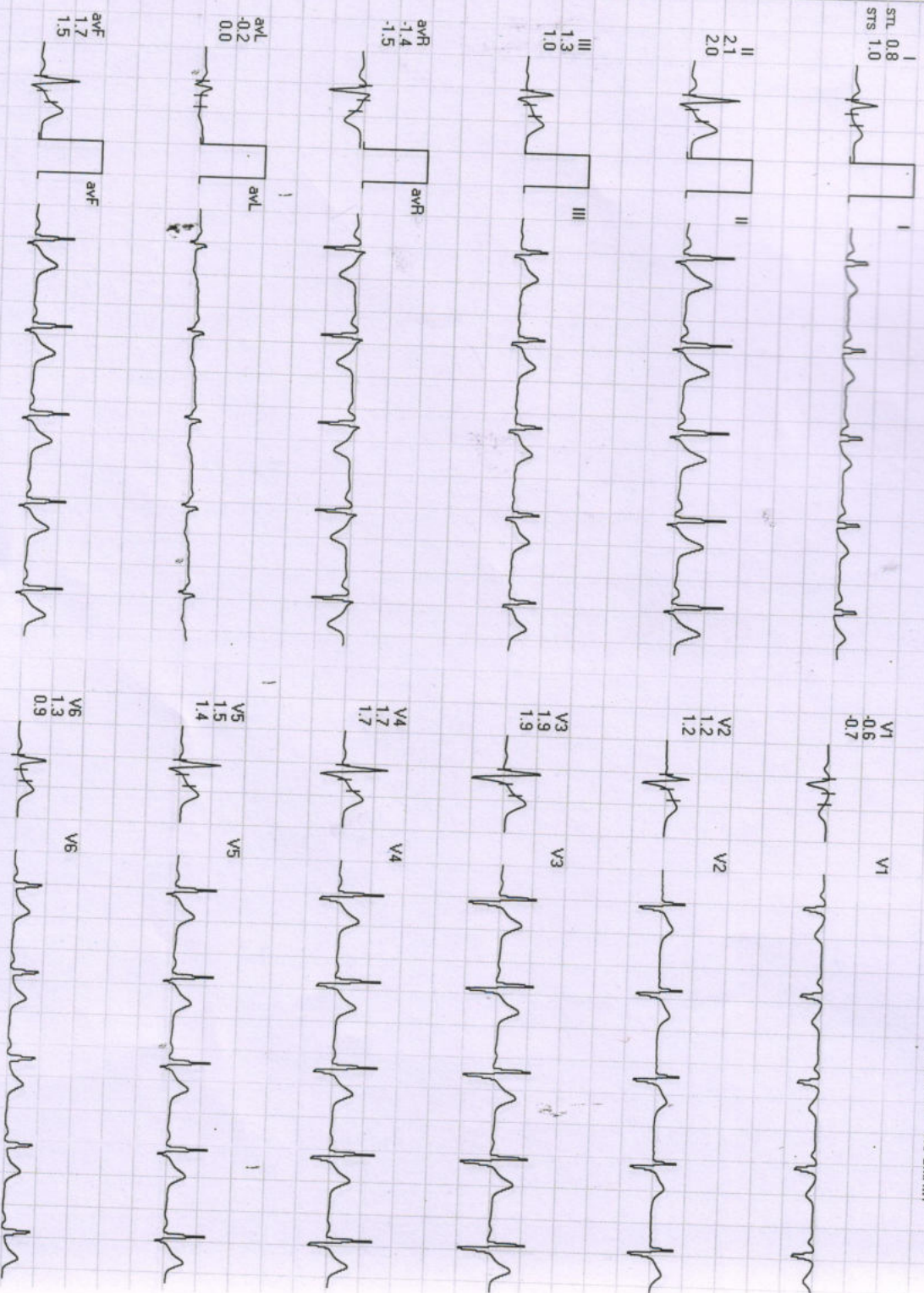

METS: 1.0/ 90 bpm 47% of THR BP: - / - mmHg

Raw ECG/ BLC On/ Notch On/ HF 0.05 Hz/LF 20 Hz

ExTime: 00:06 0.0 mph 0.0%

25 mm/Sec. 1.0 Cm/mV

4X 80 mS Post J



REMARKS:

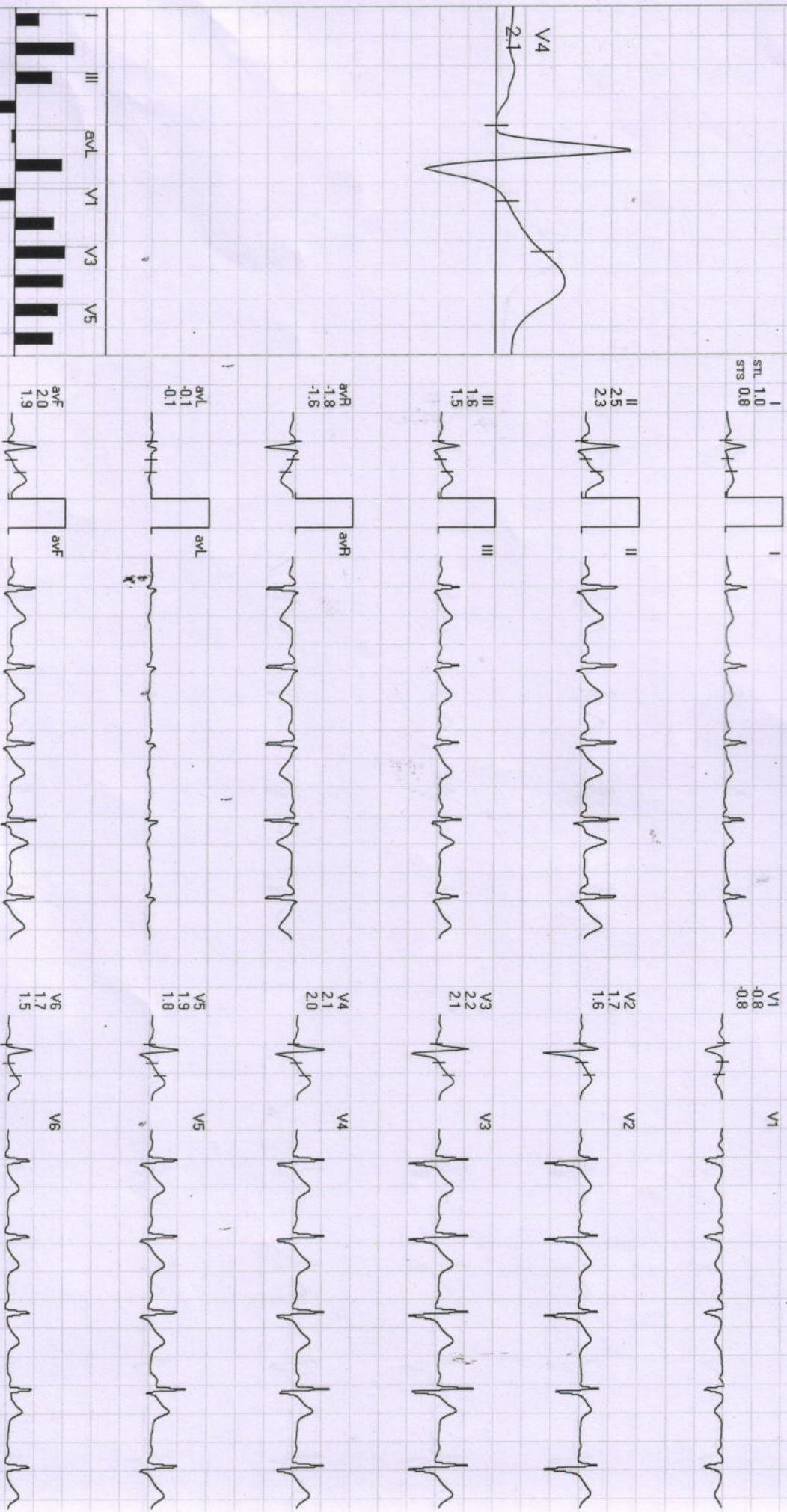



Date: 27-Aug-2022 10:41:40 AM METS: 1.0/86 bpm 45% of THR BP: - / - mmHg Raw ECG/BLC On/ Natch On/ HF 0.05 Hz/LF 20 Hz

EXTime: 00:27 1.0 mph, 0.0%

**4X** 80 mS Post J


25 mm/Sec. 1.0 Cm/mV



REMARKS:

4X

80 ms Post J



STL 1.1  
STS 1.1

II 2.6  
2.5

III 1.5  
1.4

avR 1.8  
1.8

avL -0.2  
-0.2

avF 2.0  
1.9

V1 -0.9  
-1.1

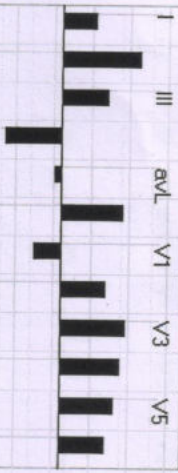
V2 1.5  
1.1

V3 2.1  
2.0

V4 2.0  
1.9

V5 1.7  
1.7

V6 1.5  
1.4



REMARKS:



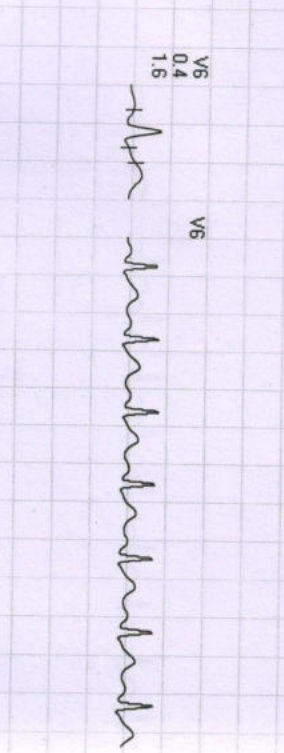
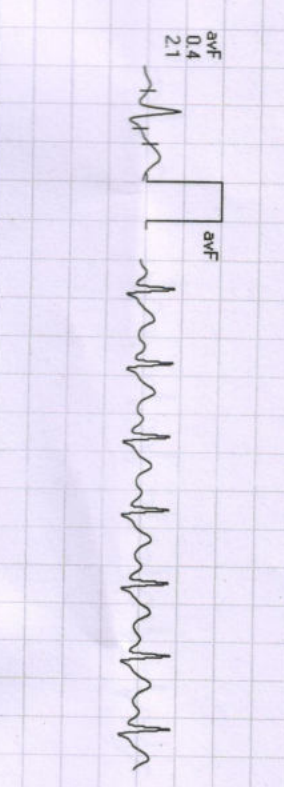
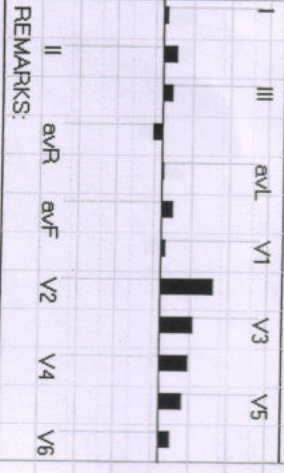



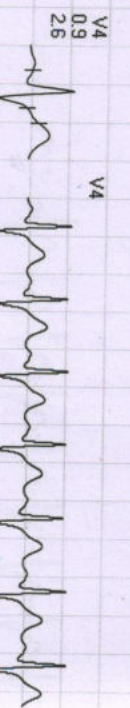



Date: 27-Aug-2022 10:41:40 AM METS: 4.7/134 bpm 71% of THR BP: 130/80 mmHg Raw ECG/ BLC On/ Notch On/ HF 0.05 Hz/LF 20 Hz

**4X**

60 ms Post J

EXTime: 03:00 1.7 mph, 10.0%

25 mm/Sec. 1.0 Cm/mV



REMARKS:





Date: 27-Aug-2022 10:41:40 AM

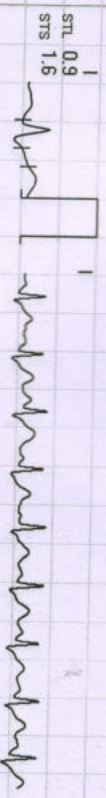
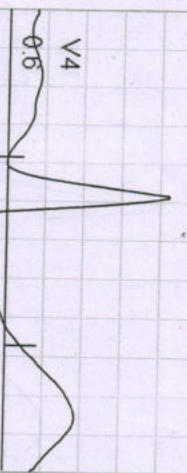
METS: 7.1/164 bpm 87% of THR BP: 140/90 mmHg

Raw ECG/BLC On/ Natch On/ HF 0.05 Hz/LF 20 Hz


EXTime: 06:00 2.5 mph, 12.0%

25 mm/Sec 1.0 Cm/mV



4X 60 ms Post J





I  
STL 0.9  
STS 1.6  
V1 0.5  
V6 0.3




II 0.9  
3.0  
V2 1.5  
V5 0.5



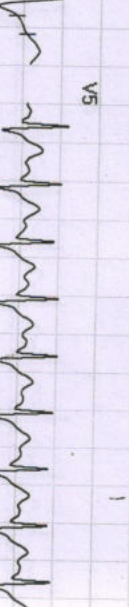
III 0.1  
1.3  
V3 0.7  
V4 0.6





aVR -0.9  
-2.3  
V4 0.6  
V5 0.5



aVL 0.6  
0.5  
V5 0.5  
V6 1.4



aVF 0.4  
2.2  
V6 0.3  
V6 1.4



REMARKS:

Date: 27-Aug-2022 10:41:40 AM

METS: 8.2 / 175 bpm 93% of THR

BP: 140/90 mmHg

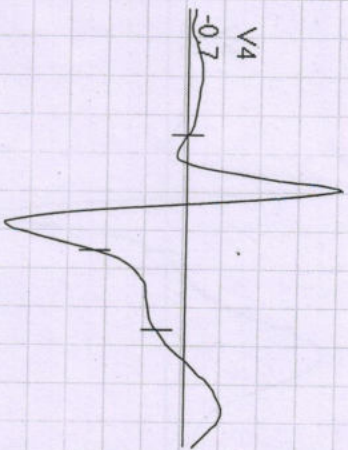
Raw ECG/ BLC On/ Notch On/ HF 0.05 Hz/LF 20 Hz

4X


60 ms Post J

ExTime: 07:00 3.4 mph, 14.0%

25 mm/Sec 1.0 Cm/mV




I  
STL 0.1  
STS 1.8




II  
-0.8  
2.7



III  
-0.9  
0.9



aVR  
0.4  
-2.3



aVL  
0.7  
0.8



aVF  
-0.9  
1.8



V1  
0.0  
0.0  
-0.6




V2  
1.2  
3.4




V3  
-0.3  
2.9



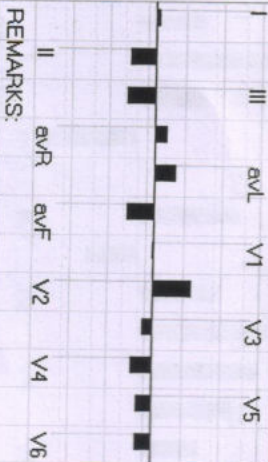

V4  
-0.7  
2.4



V5  
-0.5  
2.0



V6  
-0.5  
0.9



REMARKS:



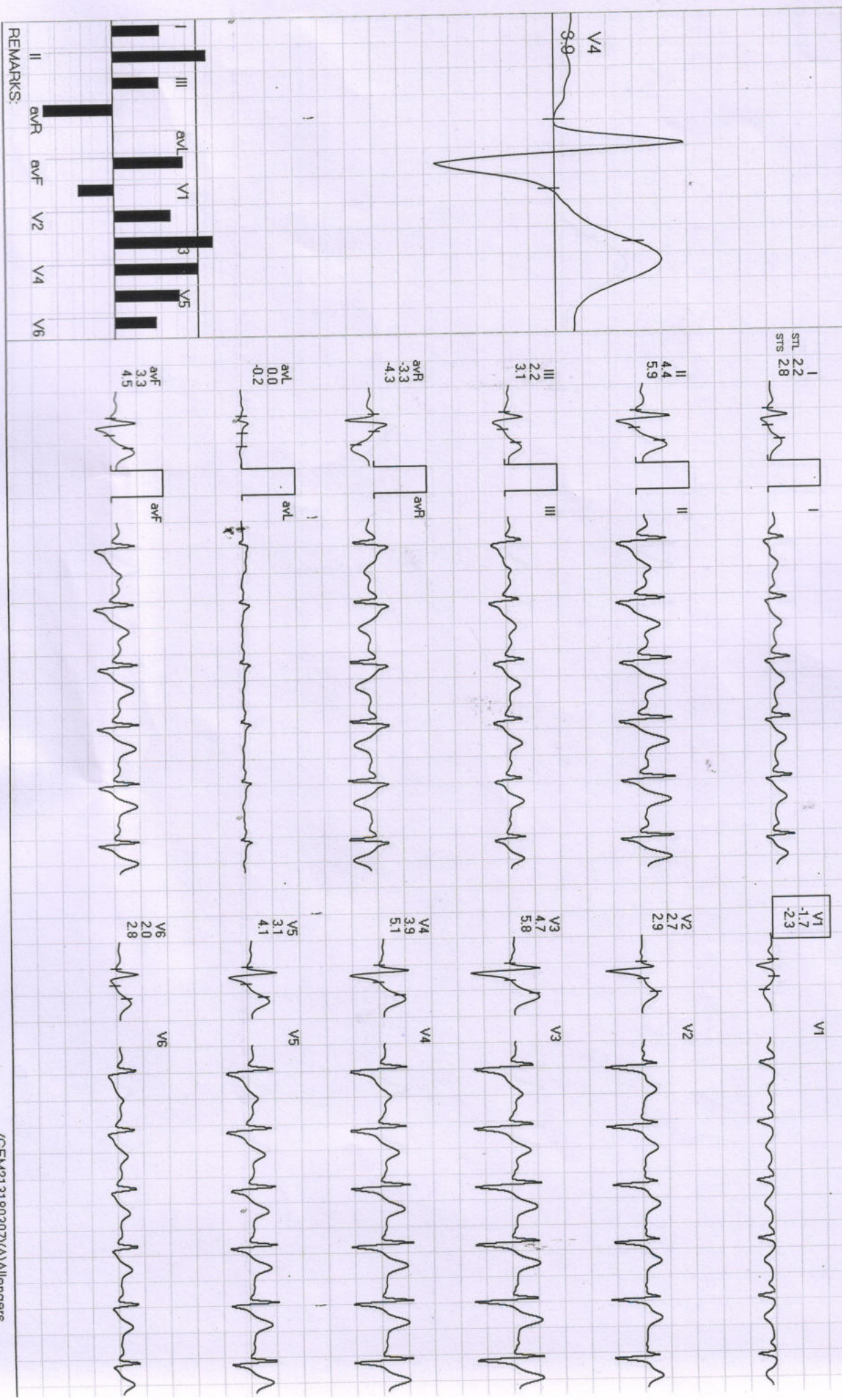
734 / MR. DINESH ARYA / 32 Yrs / M / 170 Cms / 77 Kg / HR : 119

Date: 27-Aug-2022 10:41:40 AM METS: 1.1/119 bpm 63% of THR BP: 146/90 mmHg Raw ECG/BLC On/ Notch On/ HF 0.05 Hz/LF 20 Hz

EXTime: 07:00 0.0 mph, 0.0%

4X 80 mS Post J

25 mm/Sec. 1.0 Cm/mV



REMARKS:

734 / MR. DINESH ARYA / 32 Yrs / M / 170 Cms / 77 Kg / HR : 115

Recovery : ( 02:00 )



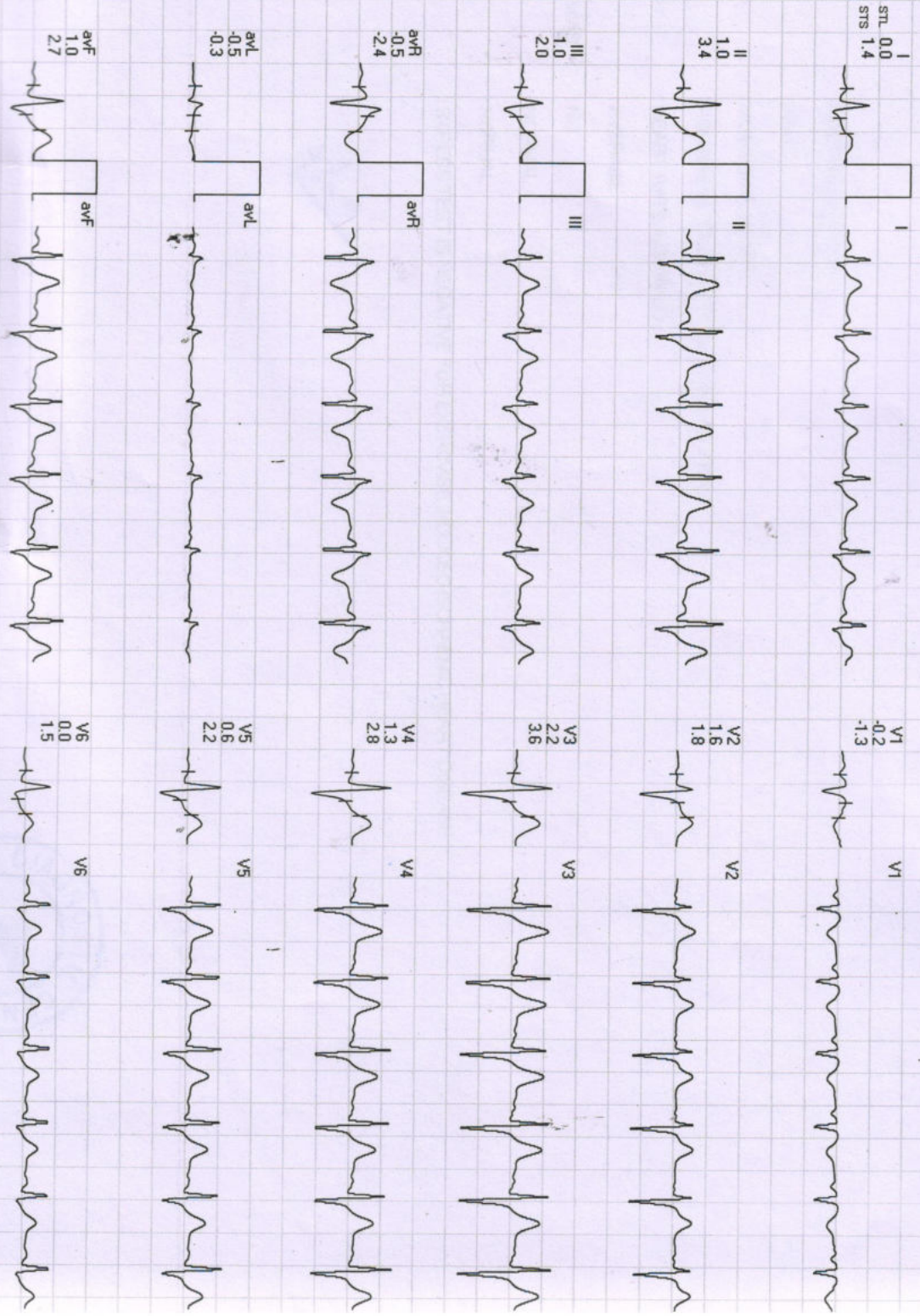
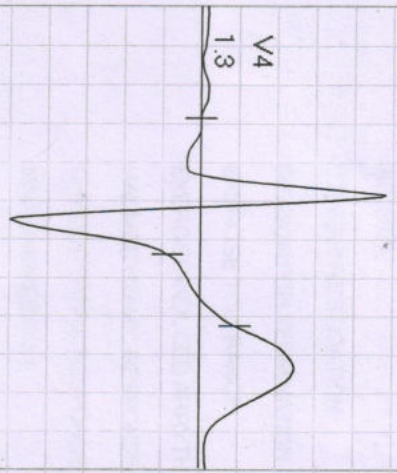
Date: 27-Aug-2022 10:41:40 AM

METS: 1.0/ 115 bpm 61% of THR BP: 136/86 mmHg Raw ECG/BLC On/ Natch On/ HF 0.05 Hz/LF 20 Hz

EXTime: 07:00 0.0 mph, 0.0%

4X 80 mS Post J

25 mm/Sec. 1.0 Cm/mV



I	III	aVL	V1	V3	V5
II	aVR	aVF	V2	V4	V6

REMARKS:



Dr. B. M. Agarwal  
MBBS, DCP  
Consultant Pathologist

*[Handwritten signature]*

आधार - आम आदमी का अधिकार

5132 7004 4451

QR Code

पुंश / MALE  
 नाम दिव / DOB : 23/06/1989  
 Dinesh Arya

*[Blacked out area]*

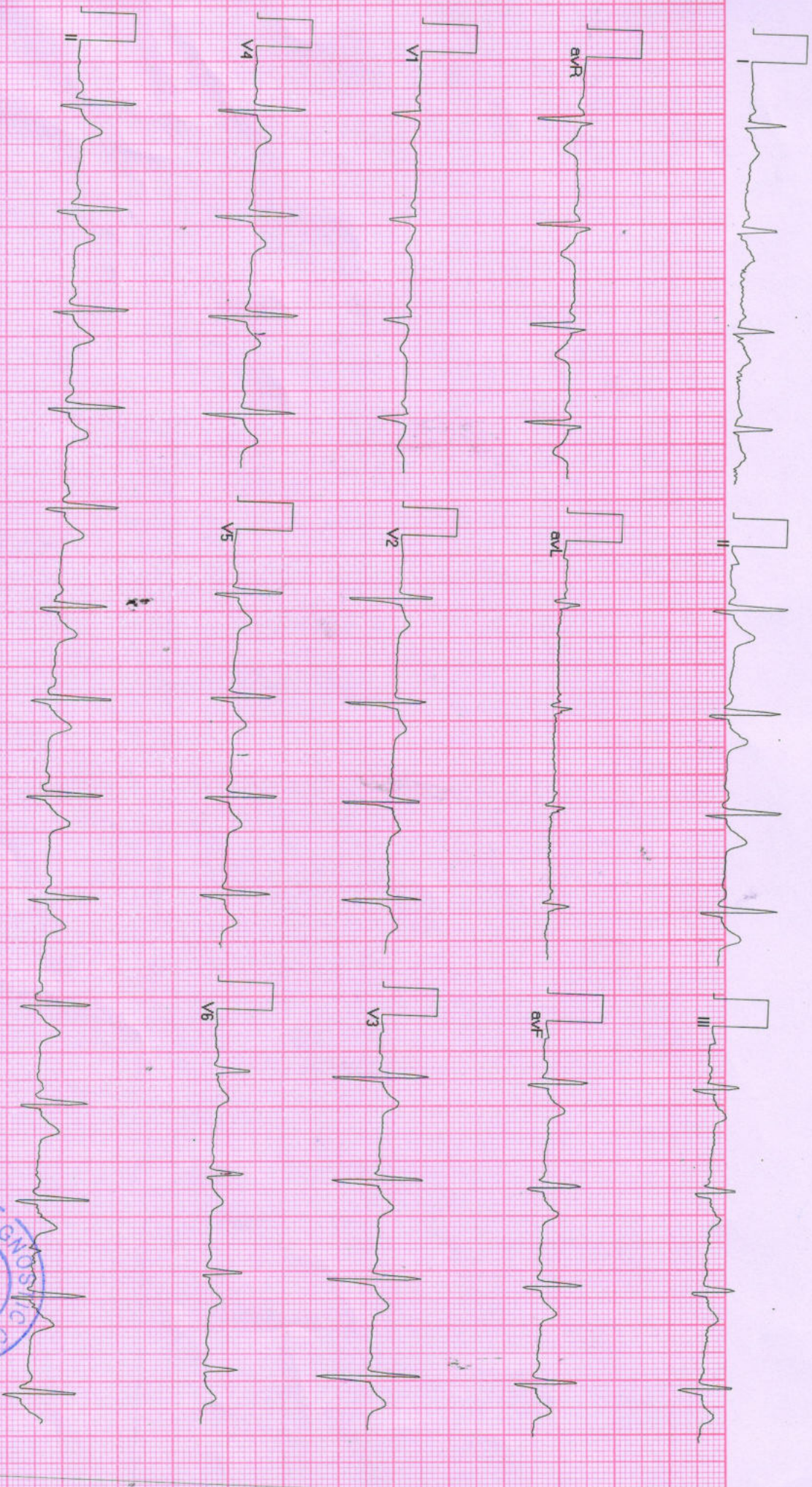
*[Blacked out area]*

**डिवाकर डायग्नोस्टिक सेंटर**

E-7/636, पंजाब नेशनल बैंक के पास, मैन रोड, असेा कॉलोनी भोपाल ( म.प्र. )  
 फोन: 0755-2465288, 0755-3520545 मां: 9826340190



*[Handwritten notes]*



BPL-DYNATRAC

*Dinesh*



Right Ovary  
No E/O HDN

PTO

noted. No E/O hydronephrosis / calculus is noted.

Right Kidney is normal in size, shape and position. Corticomedullary differentiation (CMD) is well maintained. Normal cortical thickness is

No evidence of free fluid is noted.

No evidence of lymphadenopathy is noted.

IVC and aorta appear to be normal.

Spleen is normal in size and echo texture.

contour. No peripancreatic pathology seen. (Not seen due to gases)

Pancreas appear normal in size, shape and echo texture with smooth

Common duct reveals normal course and caliber.

lumen. GB wall is normal / thickened. No E/O pericholecystic collection.

Gall Bladder is physiologically well distended. No. E/O echogenic foci in GB

No E/O subdiaphragmatic Collection.

dilatation is seen. Hepatic veins and portal veins appear normal.

increased parenchymal echogenicity is noted. No E/O focal lesion/ IHR

Liver appears normal in size and shape with normal outline. Normal/

Indication:

### WHOLE ABDOMEN ULTRASOUND REPORT

Name : Mrs. Binoo. Arya. 32/Male.  
Age : 32 YRS./F  
Date : 27/8/2017  
R/B : No. Health check-up.

Mob. : 89896649694, 95163333619  
Clinic Registration : CL/5392/Jun/2017  
PNDT Registration : MPPCPNDT/BPL/2017/206

34, भूतल, मोहिनी अदिति आर्कड, शाहिपुरा मस्जिद के पास  
भरत नगर रोड, ई-7/194, अररा कॉलोनी, भीपाल - 462038

# डॉ. सविता सिन्हा



**Left Kidney** is normal in size, shape and position. CMD is well maintained. Normal cortical thickness is noted. No E/O hydronephrosis or calculus is noted.

**Urinary Bladder** is well distended (physiological). its contents are echo free. No E/O bladder wall thickening is noted. Post-void residue is insignificant.

**Prostate** is normal in size. Shape and echo texture with smooth outline. No E/O focal lesion is noted.

**Uterus** is ante/ retro verted and normal in size, shape and echo texture with smooth outline. No E/O focal lesion is noted. Endometrial echo appear normal. Cervical and vaginal shadows appear normal.

**Right Ovary** appears enlarged/ Normal in size, shape and echo texture.

**Left Ovary** appears enlarged/ Normal in size, shape and echo texture.

**Impression : Normal study.**

*Pt Renuka Kulkarni*


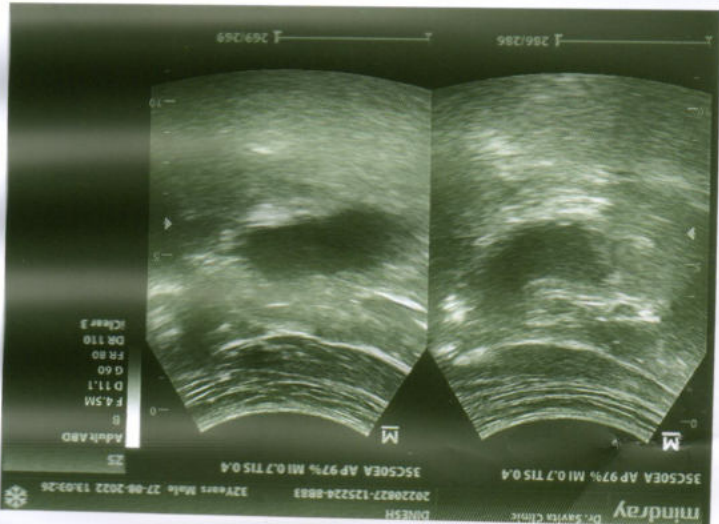
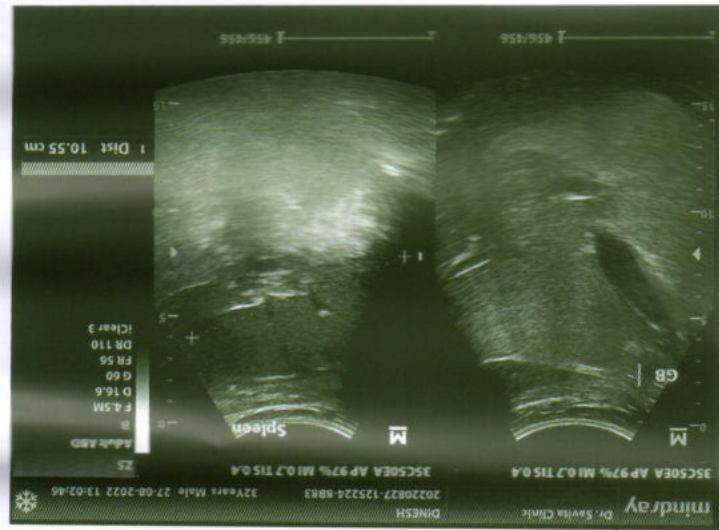
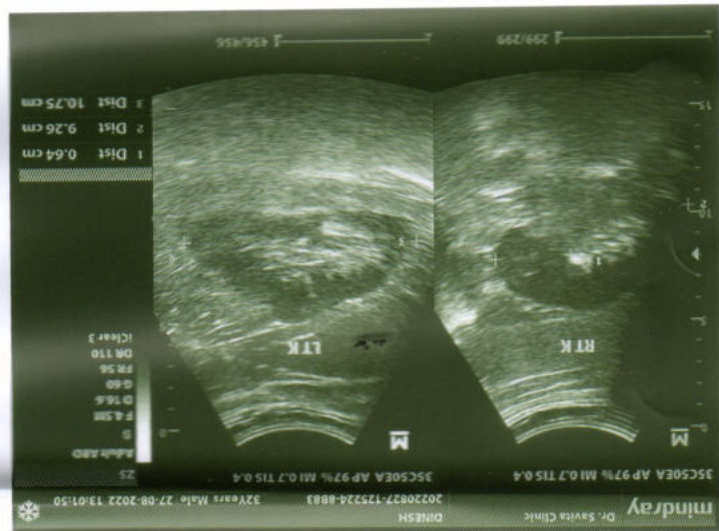
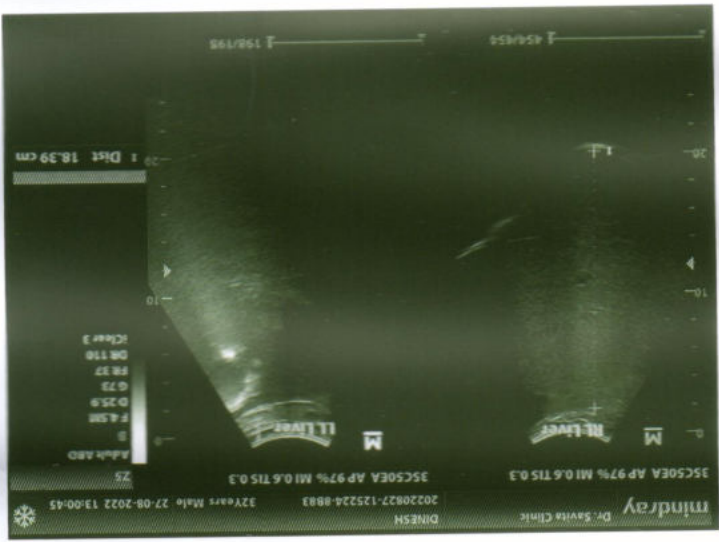
*Non Obstetrical Stone @ 6mm*

**Advised clinical Correlation.**

Dr. P. Savita, MD  
MBBS, MD (O&G) Reg. No. 9971  
श्री पी सावित्री

Dr. Jayant Yadav, MD  
MBBS, MD (Radiologist) Reg. No. 4166  
डॉ. जयान्त यादव







# द्विवाकर डायग्नोस्टिक सेंटर

E-7/636, पंजाब नेशनल बैंक के पास, मैन रोड, अरेरा कॉलोनी भोपाल ( म.प्र. )

फोन: 0755-2465288, 0755-3520545 मो: 9826340190

Pt Name :	Mr. Dinesh Arya
Age :	34/M
Ref.By :	BOB
Lab. No. :	188
Date :	27/08/2022


## EXAMINATION OF BLOOD

### Thyroid profile


TEST	RESULT	NORMAL VALUE
T3 - TOTAL	88.3	82-213 ng/dL
T4 - TOTAL	7.5	6.09-12.23 ug/dL
THYROID STIMULATING HORMONE (TSH)	1.99	0.45-4.25 ul/mL

#### Interpretation:

TSH Levels will be elevated in primary hypothyroidism, TSH levels will be low in Hyperthyroidism there is decreased production of thyroid hormones by the thyroid hence the person may experience symptoms such as weight gain, constipation, cold intolerance and fatigue. Iodine deficiency and Hashimoto thyroiditis is the most common cause of hypothyroidism It makes Thyroid stimulating hormone. If TSH levels are abnormally high it could mean you have an underactive thyroid or hypothyroidism.

  
Dr. B. M. Agarwal  
MBBS, DCP  
Pathologist  
Consultant Pathologist

All test have technical limitation. Collaborative clinic pathological interpretation is mandatory. In case of disparity test may be repeated immediately. Typographical mistakes should be get correct instantly. This report is not valid for medico legal purpose





# दिवकर डायग्नोस्टिक सेंटर

E-7/636, पंजाब नेशनल बैंक के पास, मैन रोड, अरेरा कॉलोनी भोपाल ( म.प्र. )  
फोन: 0755-2465288, 0755-3520545 मो: 9826340190

Pt Name :	Mr. Dinesh Arya
Age :	34/M
Ref.By :	BOB
Lab. No. :	188
Date :	27/08/2022
Skigram	X Ray Chest PA View
Radiologist	Dr. B.M.Agarwal MD (Radiology)

## REPORT

Tricia Central

Thoracic cage normal

Both Lungs Field Clear.

Both hilers normal

Cardiac border normal

Both cp angles clear

Both domes and diaphragm normal

## IMPRESSION

\*\*\*\*\*

- NO CARDIO PULMONARY PATHOLOGY
- COORELATE WITH CLINICAL FINDINGS.



*B*  
Dr. B. M. Agarwal  
MD, Radiology  
Consultant Radiologist  
Radiologist



# दिवाकर डायग्नोस्टिक सेंटर

E-7/636, पंजाब नेशनल बैंक के पास, मैन रोड, अरेरा कॉलोनी भोपाल ( म.प्र. )


फोन: 0755-2465288, 0755-3520545 मो: 9826340190

Pt Name :	Mr. Dinesh Arya
Age :	34/M
Ref.By :	BOB
Lab. No. :	188
Date :	27/08/2022

## URINE ANALYSIS

<u>A. PHYSICALEXAMINATION</u>		<u>C. MICROSCOPIEXAMINATION</u>	
1. Colour	Pale Yellow	Pus Cells	2-4/HPF
2. Appearance	Clear	R.B.C.	Nil
3. Specific Gravity	Q.N.S.	Epithelial Cell	occ/HPF
<u>B. CHEMICAL EXAMINATION</u>		Cast	Nil
1.Reaction	Acidic	Crystals(Cal.Oxa)	Nil
2.Albumin	Absent	Bacteria	Nil
3.Sugar	Nil	Amorphous	Nil
4.Bile Salts	Absent	T. Vaginatis	Nil

URINE COTININE	Negative	By Card method
----------------	----------	----------------



  
Dr. B. M. Agarwal  
MBBS DCP  
Pathologist  
Consultant Pathologist

All test have technical limitation. Collaborative clinic pathological interpretation is mandatory. In case of disparity test may be repeated immediately. Typographic mistakes should be get correct instantly. This report is not valid for medico legal purpose.



# द्विवाकर डायग्नोस्टिक सेंटर

E-7/636, पंजाब नेशनल बैंक के पास, मैन रोड, अरसा कॉलोनी भोपाल ( म.प्र. )


फोन: 0755-2465288, 0755-3520545 मो: 9826340190

Pt Name :	Mr. Dinesh Arya
Age :	34/M
Ref.By :	BOB
Lab. No. :	188
Date :	27/08/2022

## EXAMINATION OF BLOOD

TEST	RESULT	NORMAL VALUE
Haemoglobin	13.5mgs%	Female 12-16gms%, Male 14-18gms%
Red Cell count	4.4	4.5-5.6 million /cumm
Platelet Count	2.16	1.5-5.6 Lac/cumm
Leucocytes per.cu.mm	5500/cumm	5000-11000/cumm
Neutrophils	59%	50-70%
Lymphocytes	33%	20-40%
Eosinophils	05%	0-7%
Monocytes	03%	2-8%
PCV	43.4	37-47
MCV	96.9	76-96
MCH	30.1	27-32
MCHC	31.1	31-35
ESR	06	Male 0-9, Female 0-20mm/FHR
Blood Group	"AB" Positive	By Slide Method
S.Bilirubin(Total)	0.86	0.2-1.0mg/dl
Direct	0.35	0.0-0.25mg/dl
Indirect	0.51	
SGOT	30.6	5-35U/L
SGPT	38.2	8-40U/L
Alk Phosphatase	10.9	3-13 KA units
S. Protein(Total)	7.1	6.0-8.0mg%
Albumin	4.0	3.7-5.3mg%
Globulin	3.0	1.5 to 3.5 mg%
AG Ratio	1.22	1.-2.0
Blood Urea Nitrogen (BUN)	15.3	7-20 mg/dl
S.Creatinine	0.71	0.5-1.4mg/dl
Uric Acid	6.2	4.8 to 7.5 mg/dl
Calcium	9.4	8.5-10.5 gm/dl
GGTP	33.0	5-35 UL/dl
Fasting Blood Sugar	81.3	70 to 110mg/dl
Post Prandial Blood sugar	136.2	Up to 150mg/dl
Total Serum Cholesterol	185.3	100-250 mg%
Serum Triglyceride	169.9	Up to 160 mg%
Serum Cholesterol HDL	41.5	Up to 65 mg%
Serum Cholesterol LDL	109.8	Up to 125 mg%
VLDL	33.9	Up to 30 mg%
TC/HDL Ratio	3.28	Bellow 5
Glycosylated Hemoglobin HBA1c	5.1	Below - 6.0 % -Non Diabetic control 6-7 % -Excellent control Above- 8 % -Poor control

All test have technical limitation. Collaborative clinic pathological interpretation is mandatory. In case of disparity test may be repeated immediately. Typographical mistakes should be get correct instantly. This report is not valid for medico legal purpose.



Pathologist  
Dr. B. M. Agarwal  
MBBS, DCP  
Consultant Pathologist



# दिवकर डायग्नोस्टिक सेंटर

E-7/636, पंजाब नेशनल बैंक के पास, मैन रोड, अरेरा कॉलोनी भोपाल ( म.प्र. )  
फोन: 0755-2465288, 0755-3520545 मो: 9826340190

Pt Name :	Mr. Dinesh Arya
Age :	34/M
Ref.By :	BOB
Lab. No. :	188
Date :	27/08/2022

## EXAMINATION OF BLOOD

<u>TEST</u>	<u>RESULT</u>	<u>NORMAL VALUE</u>
PSA	4.56 ng/ml.	0.21-6.77 ng/ml.

Dr. B. M. Agarwal  
MBBS, DCP  
Consultant Pathologist

All test have technical limitation. Collaborative clinic pathological interpretation is mandatory. In case of disparity test may be repeated immediately. Typographic mistakes should be get correct instantly. This report is not valid for medico legal purpose





# Diwal Diagnostic Centre

पैथोलोजी | टी.सी.ए. | ई.सी.जी. | एको कार्डियो ग्राफी | सोनोग्राफी

