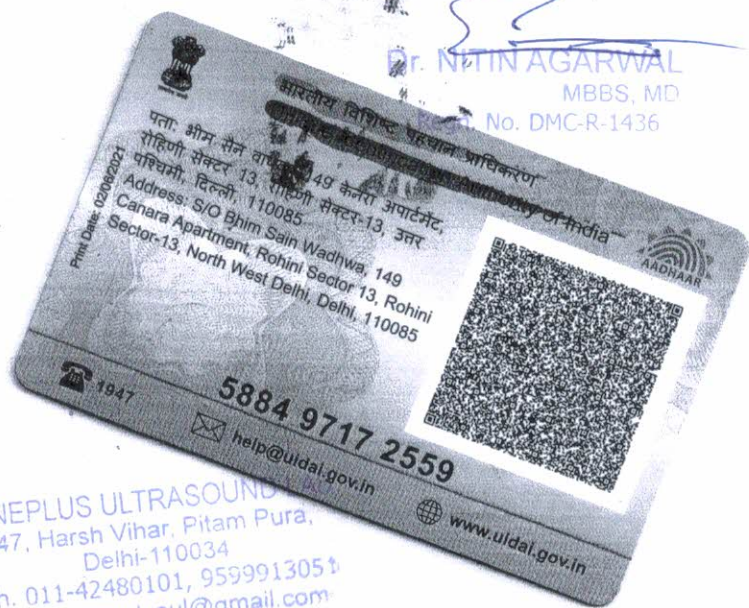





Handwritten signature in blue ink.



ONEPLUS ULTRASOUND
47, Harsh Vihar, Pitam Pura,
Delhi-110034
Ph. 011-42480101, 9599913051
E-mail: oneplusul@gmail.com





Handwritten signature in blue ink.

Handwritten signature in blue ink.

Dr. NITIN AGARWAL
MBBS, MD
Regn. No. DMC-R-1435

ONEPLUS ULTRASOUND L&E
47, Harsh Vihar, Pitam Fura,
Delhi-110034
Ph: 011-42480101, 9599913051
E-mail: oneplusul@gmail.com



ONEPLUS ULTRASOUND LAB

47, HARSH VIHAR, PITAMPURA, DELHI- 110034

Mr. SUMIT WADHWA
Age : 39/M

Ref. by : MEDIWHEEL
Indication1 :
Indication2 :
Indication3 :
COMMENTS : Normal ECG.

ID : 2260
H/Wt : 170/84
Recorded : 8-7-2023 8:55
Medication1 :
Medication2 :
Medication3 :

BPM : 91
BP : 132/88
P Axis : 44 deg
QRS Axis : 75 deg
T Axis : 54 deg

P duration : 96 msec
PR duration : 110 msec
QRS duration : 103 msec
QT interval : 300 msec
QTc interval : 354 msec

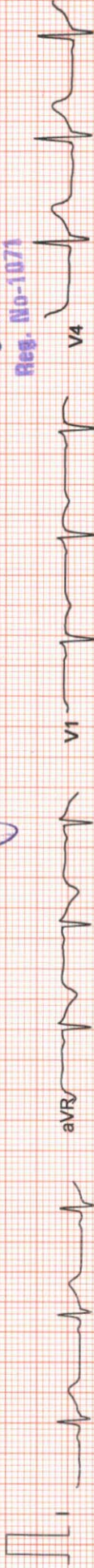Raw E.C.G.(Seq)

Unconfirmed Report Reviewed By:

Cardiologist

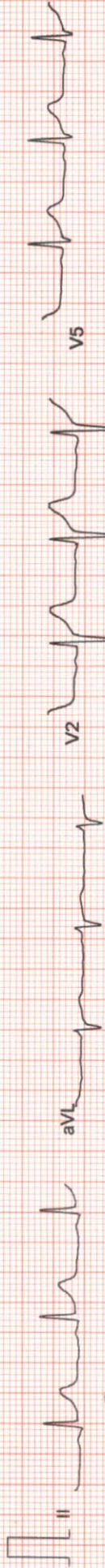
Dr. Pooja
Dr. Pooja
MBBS, MD

Reg. No-1071



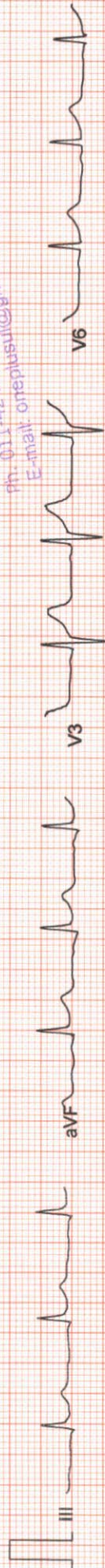
aVR

V1



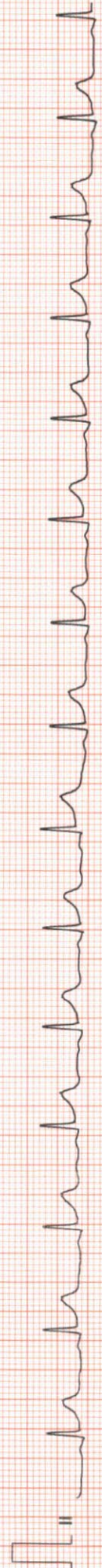
aVL

V2

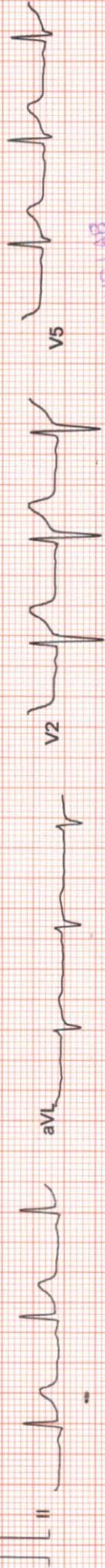


aVF

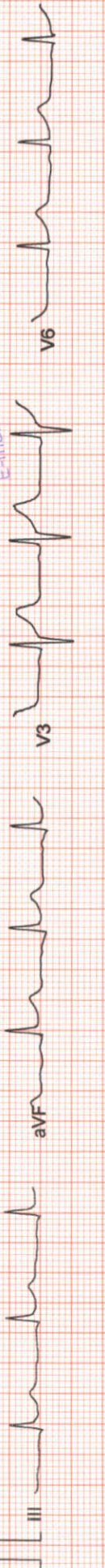
V3



V4



V5



V6

ONEPLUS ULTRASOUND LAB

47, HARSH VIHAR PITAMPURA DELHI 110034

Mr. SUMIT WADHWA
 Age/Sex : 39/M
 Ref. by : MEDIWHEEL
 Indication1 :
 Indication2 :
 Indication3 :

ID : 972
 Ht/Wt : 170/94
 Recorded : 8-7-2023 8:57

TREADMILL TEST SUMMARY REPORT

Protocol: BRUCE

History:
 Medication1 :
 Medication2 :
 Medication3 :

PHASE	PHASE TIME	STAGE TIME	SPEED (Km./Hr.)	GRADE (%)	H.R. (BPM)	B.P. (mmHg)	RPP X100	II	ST LEVEL V2	V5	METS
SUPINE					96	132/88	126	1.4	2.2	1.3	
STANDING					96	132/88	126	1.3	2.4	1.2	
STAGE 1	2:59	2:59	2.70	10.00	103	132/88	135	1.2	2.4	1.3	4.80
STAGE 2	5:59	2:59	4.00	12.00	120	146/90	175	1.3	2.3	1.1	7.10
STAGE 3	8:59	2:59	5.40	14.00	139	160/94	222	1.4	2.5	1.5	10.00
STAGE 4	9:59	0:59	6.70	16.00	167	174/98	290	0.9	2.3	0.6	11.32
PEAK EXER	10:01	1:01			166	174/98	288	0.9	2.3	0.6	11.36
RECOVERY	2:59	2:59	0.00	0.00	107	134/88	143	1.0	1.7	1.0	

RESULTS

Exercise Duration : 10:01 Minutes
 Max Heart Rate : 167 bpm 92 % of target heart rate 181 bpm
 Max Blood Pressure : 174/98 mmHg
 Max Work Load : 11.36 METS

Reason of Termination :

IMPRESSIONS

Referral for further work up

ONEPLUS ULTRASOUND LAB
 47, Harsh Vihar, Pitampura,
 Delhi-110034
 Ph: 011-27182101, 9593913051
 E-Mail: onepplusul@gmail.com

[Signature]
DR. P. GUPTA
MBBS, MD
Reg. No-1071
 Cardiologist

[Signature]

ONEPLUS ULTRASOUND LAB

SUPINE
PRETEST

Mr. SUMIT WADHWA

I.D. : 972

AGE/SEX : 39/M

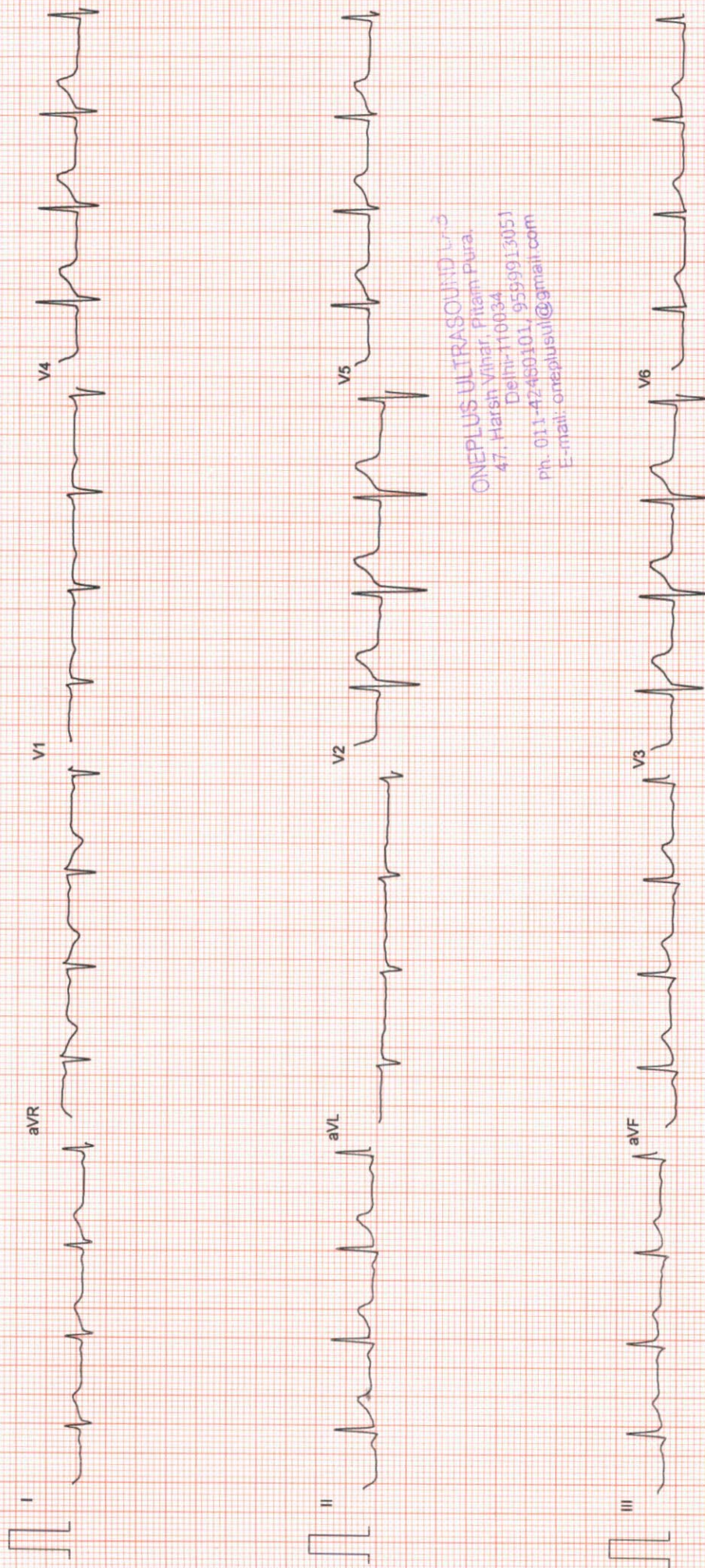
RECORDED : 8-7-2023 8:57

RATE : 96 BPM

B.P. : 132/88 mmHg

ST @ 10mm/mV
80ms PostJ

RAW E.C.G.



ONEPLUS ULTRASOUND LAB
47, Harsh Vihar, Pitam Pura,
Delhi-110034
Ph. 011-42460101, 9599913051
E-mail: onepplusul@gmail.com

Filtered

25mm/sec 10mm/mV

CardiCom, INDIA Ph.:091-731-2620740, TeleFax:091-731-2431214

ONEPLUS ULTRASOUND LAB

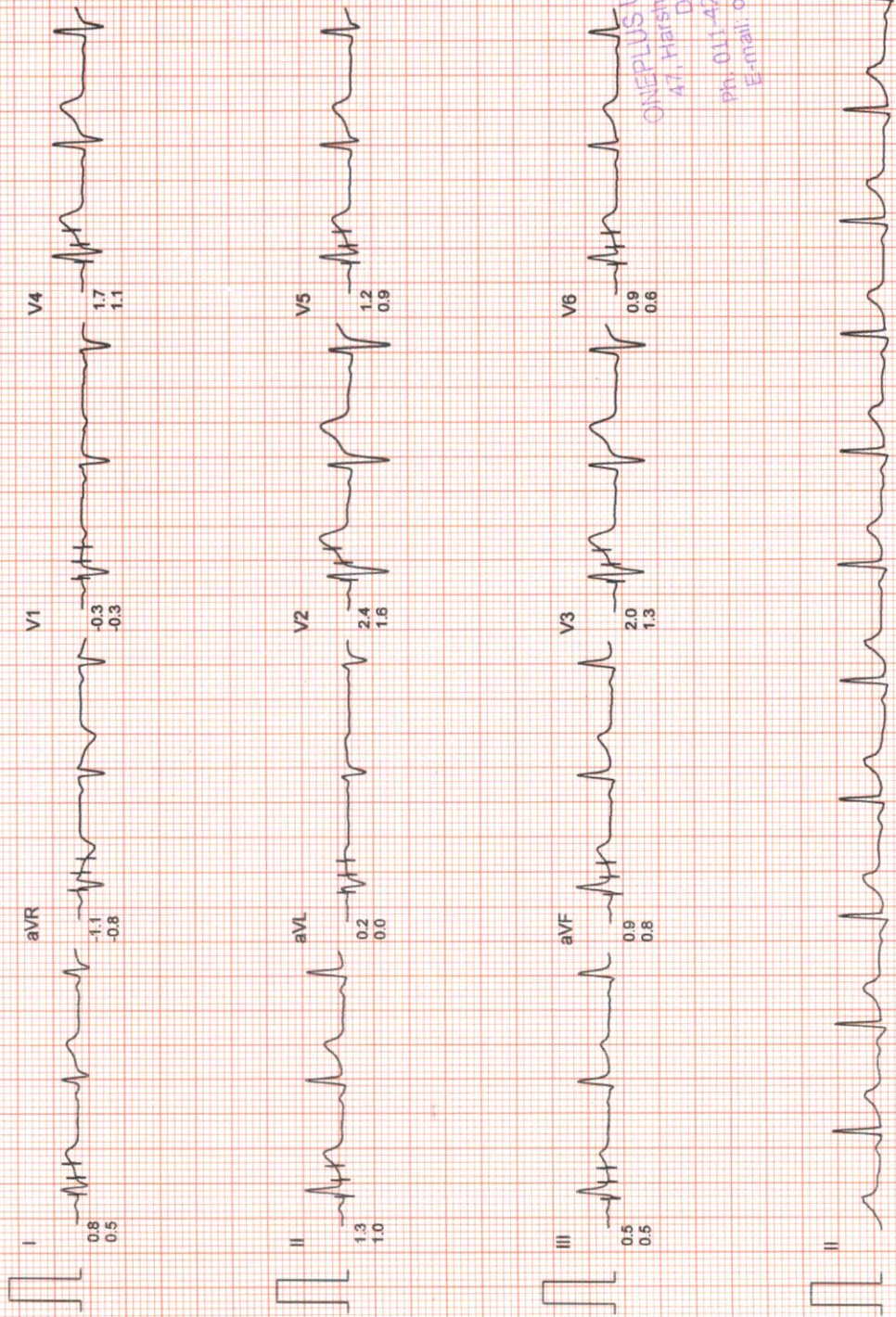
Mr. SUMIT WADHWA
I.D. : 972
AGE/SEX : 39/M
RECORDED : 8-7-2023 8:57

RATE : 96 BPM
B.P. : 132/88 mmHg

ST @ 10mm/mV
80ms PostJ

STANDING
PRETEST

LINKED MEDIAN



50mm/Sec 20mm/mV

ONEPLUS ULTRASOUND
Dr. Harsh Vihar Patil F.U.A
Delhi-110034
Ph. 011-42480101, 9599913051
E-mail: oneplusul@gmail.com

Filtered

Computer Corrected Baseline

25mm/sec 10mm/mV

CardiCom, INDIA Ph.:091-731-2620740, TeleFax:091-731-2431214

ONEPLUS ULTRASOUND LAB

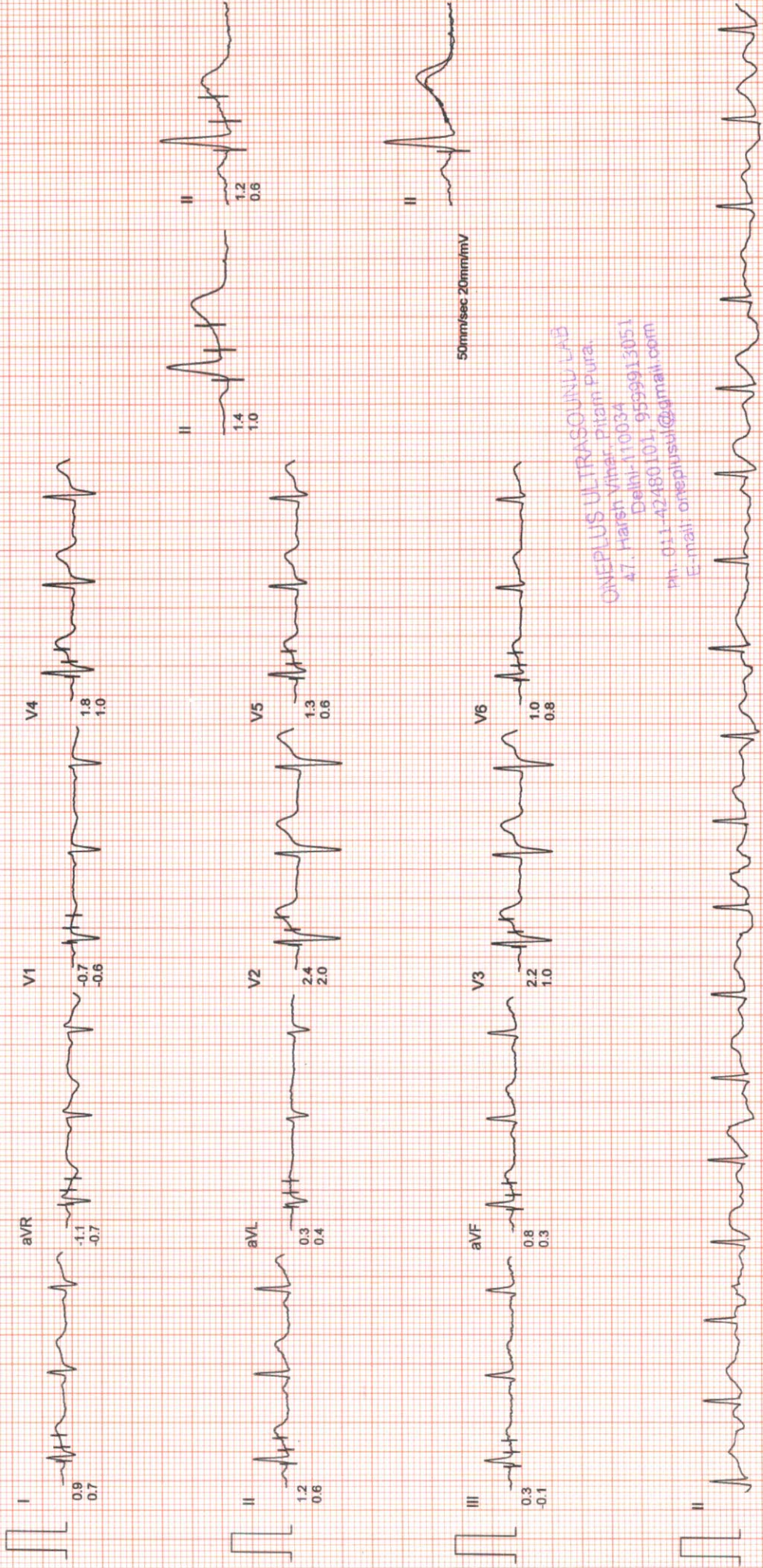
Mr. SUMIT WADHWA
I.D. : 972
AGE/SEX : 39/M
RECORDED : 8-7-2023 8:57

RATE : 103 BPM
B.P. : 132/88 mmHg

BRUCE
EXERCISE 1
PHASE TIME : 2:59
STAGE TIME : 2:59

ST @ 10mm/mV
80ms PostJ
SPEED : 2.7 Km./Hr.
GRADE : 10.0 %

LINKED MEDIAN



ONEPLUS ULTRASOUND LAB
47, Harsh Vihar, Pitam Pura,
Delhi-110034
Ph. 011-42480101, 9599913051
E-mail: oneplusul@ymail.com

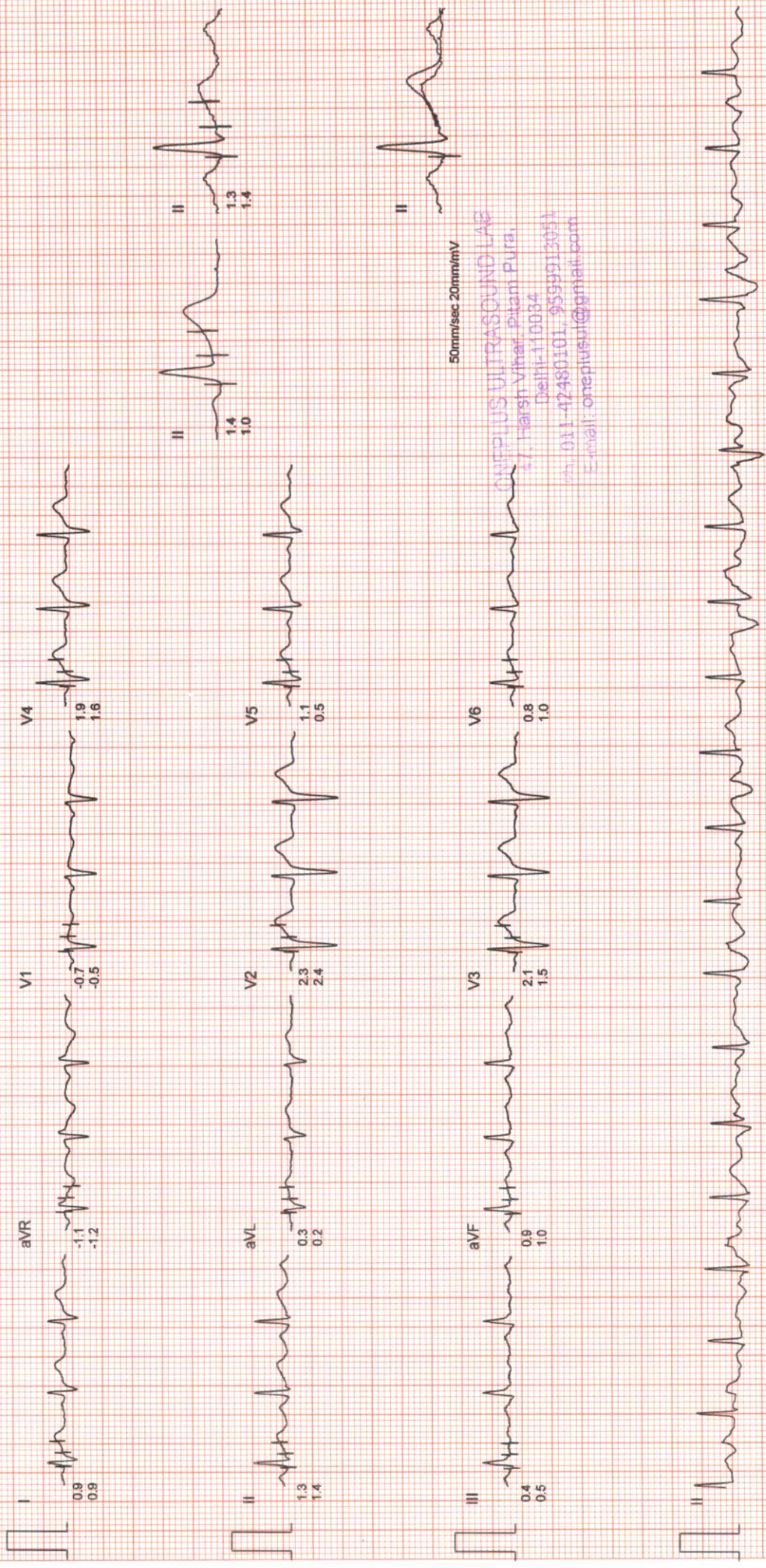
ONEPLUS ULTRASOUND LAB

Mr. SUMIT WADHWA
 I.D. : 972
 AGE/SEX : 39/M
 RECORDED : 8-7-2023 8:57

BRUCE
 EXERCISE 2
 PHASE TIME : 5:59
 STAGE TIME : 2:59

ST @ 10mm/mV
 80ms PostJ
 SPEED : 4.0 Km./Hr.
 GRADE : 12.0 %

LINKED MEDIAN



50mm/sec 20mm/mV
 ONEPLUS ULTRASOUND LAB
 Dr. Harsh Vihar, Pitam Pura,
 Delhi-110064
 Ph: 011-42480101, 9599913051
 E-mail: oneplusul@gmail.com

ONEPLUS ULTRASOUND LAB


Mr. SUMIT WADHWA
I.D. : 972
AGE/SEX : 39/M
RECORDED : 8-7-2023 8:57

RATE : 139 BPM
B.P. : 160/94 mmHg

BRUCE
EXERCISE 3
PHASE TIME : 8:59
STAGE TIME : 2:59

ST @ 10mm/mV
80ms PostJ
SPEED : 5.4 Km./Hr.
GRADE : 14.0 %

LINKED MEDIAN



50mm/sec 20mm/mV

ONEPLUS ULTRASOUND LAB
47, Harsh Vihar, Pitam Pura,
Delhi-110034
Ph: 011-42480101, 9599913051
E-mail: oneplusul@gmail.com

ONEPLUS ULTRASOUND LAB

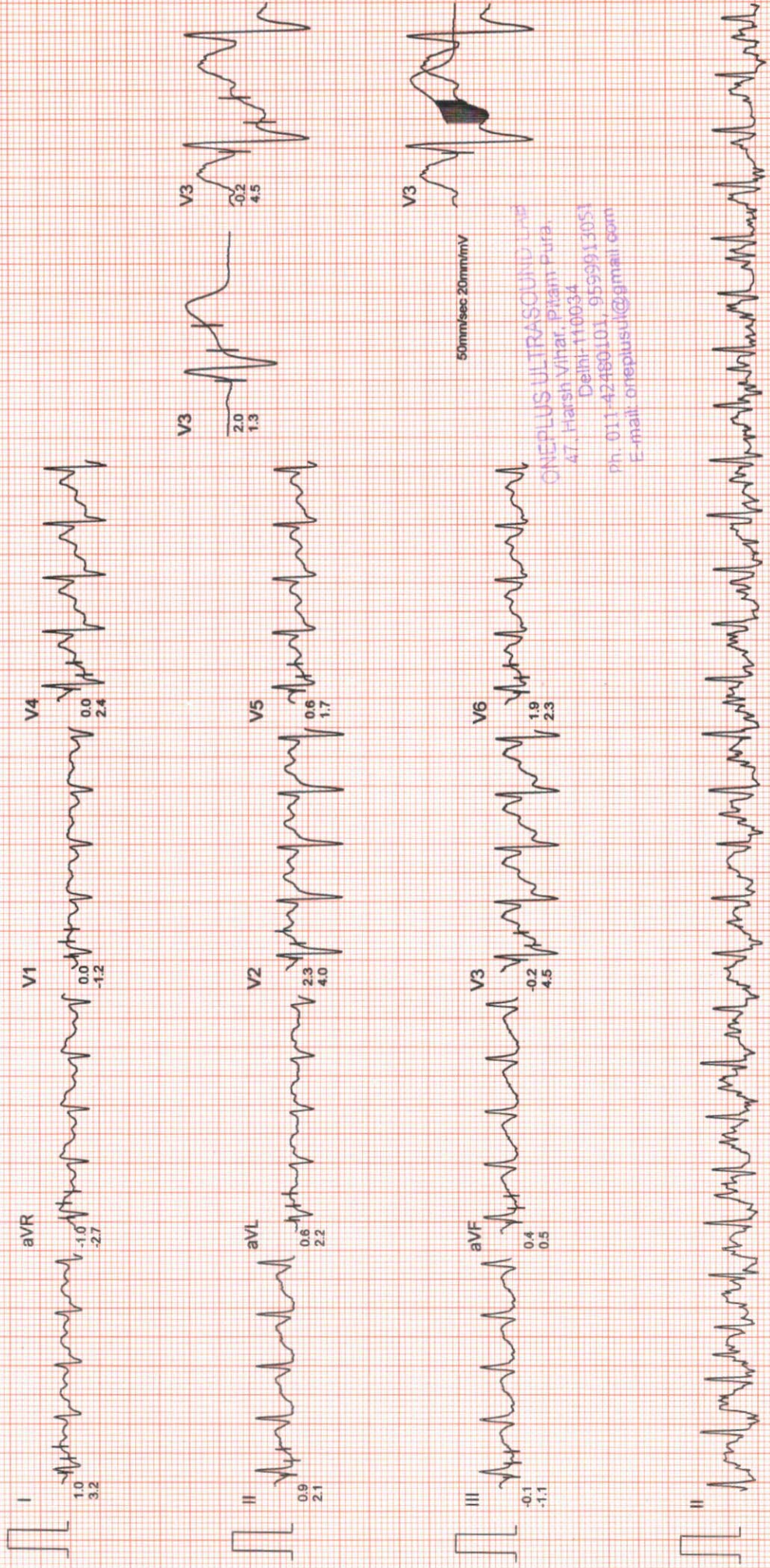
Mr. SUMIT WADHWA
 I.D : 972
 AGE/SEX : 39/M
 RECORDED : 8-7-2023 8:57

RATE : 167 BPM
 B.P. : 174/98 mmHg

BRUCE
 EXERCISE 4
 PHASE TIME : 9:59
 STAGE TIME : 0:59

ST @ 10mm/mV
 80ms PostJ
 SPEED : 6.7 Km./Hr.
 GRADE : 16.0 %

LINKED MEDIAN



ONEPLUS ULTRASOUND LAB
 47, Harsh Vihar, Pitam Pura,
 Delhi-110034
 Ph. 011-42469101, 9559913051
 E-mail: oneplusul@gmail.com

ONEPLUS ULTRASOUND LAB

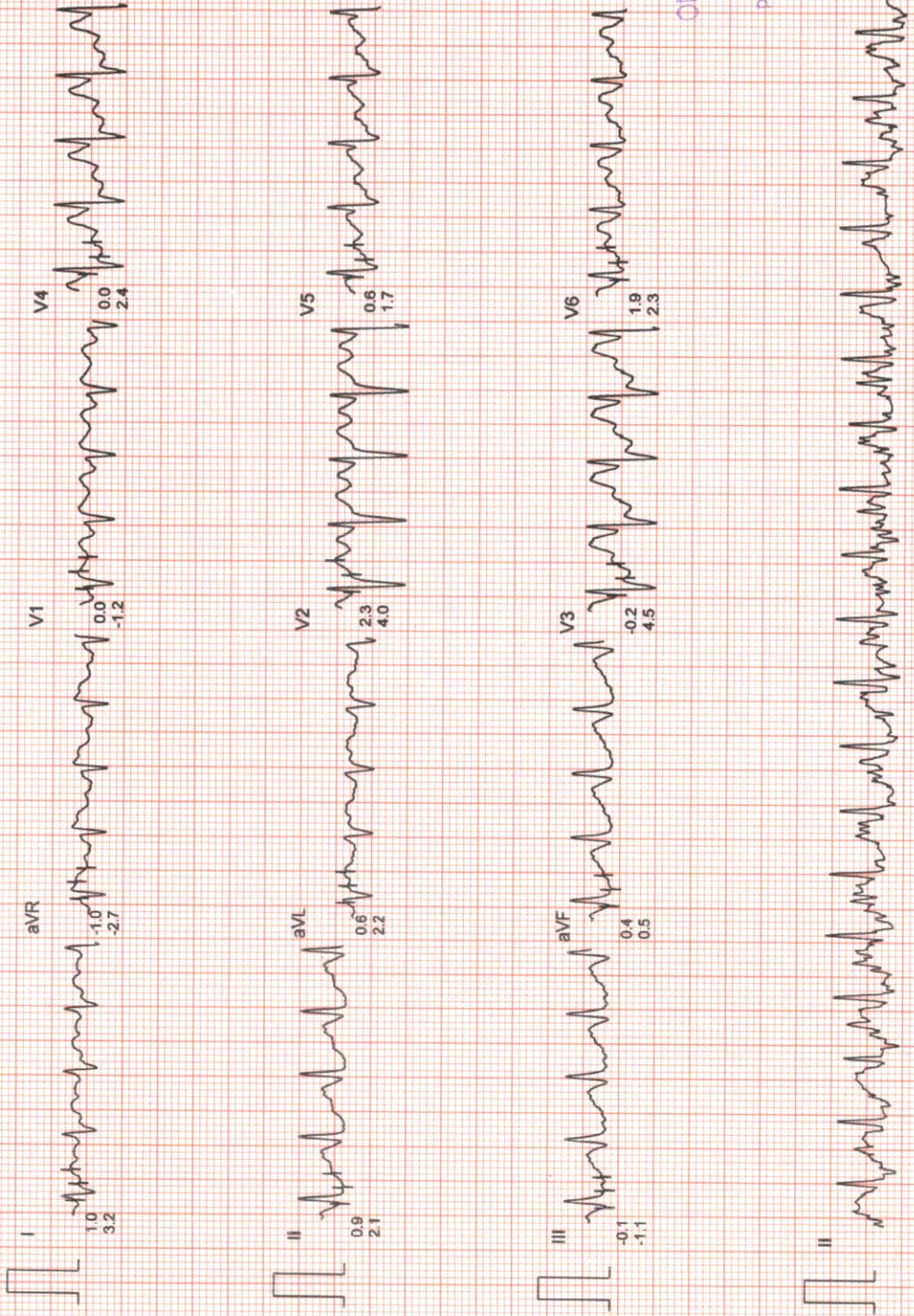
Mr. SUMIT WADHWA
 I.D. : 972
 AGE/SEX : 39/M
 RECORDED : 8-7-2023 8:57

RATE : 166 BPM
 B.P. : 174/98 mmHg

BRUCE
 PEAK EXER
 PHASE TIME : 10:01
 STAGE TIME : 1:01

ST @ 10mm/mV
 80ms PostJ
 SPEED : 6.7 Km./Hr.
 GRADE : 16.0 %

LINKED MEDIAN



ONEPLUS ULTRASOUND LAB
 47, Harsh Vihar, Pitam Pura,
 Delhi-110034
 Ph: 011-42480101, 9599913055
 E-mail: oneplusul@oneplusul.com

ONEPLUS ULTRASOUND LAB

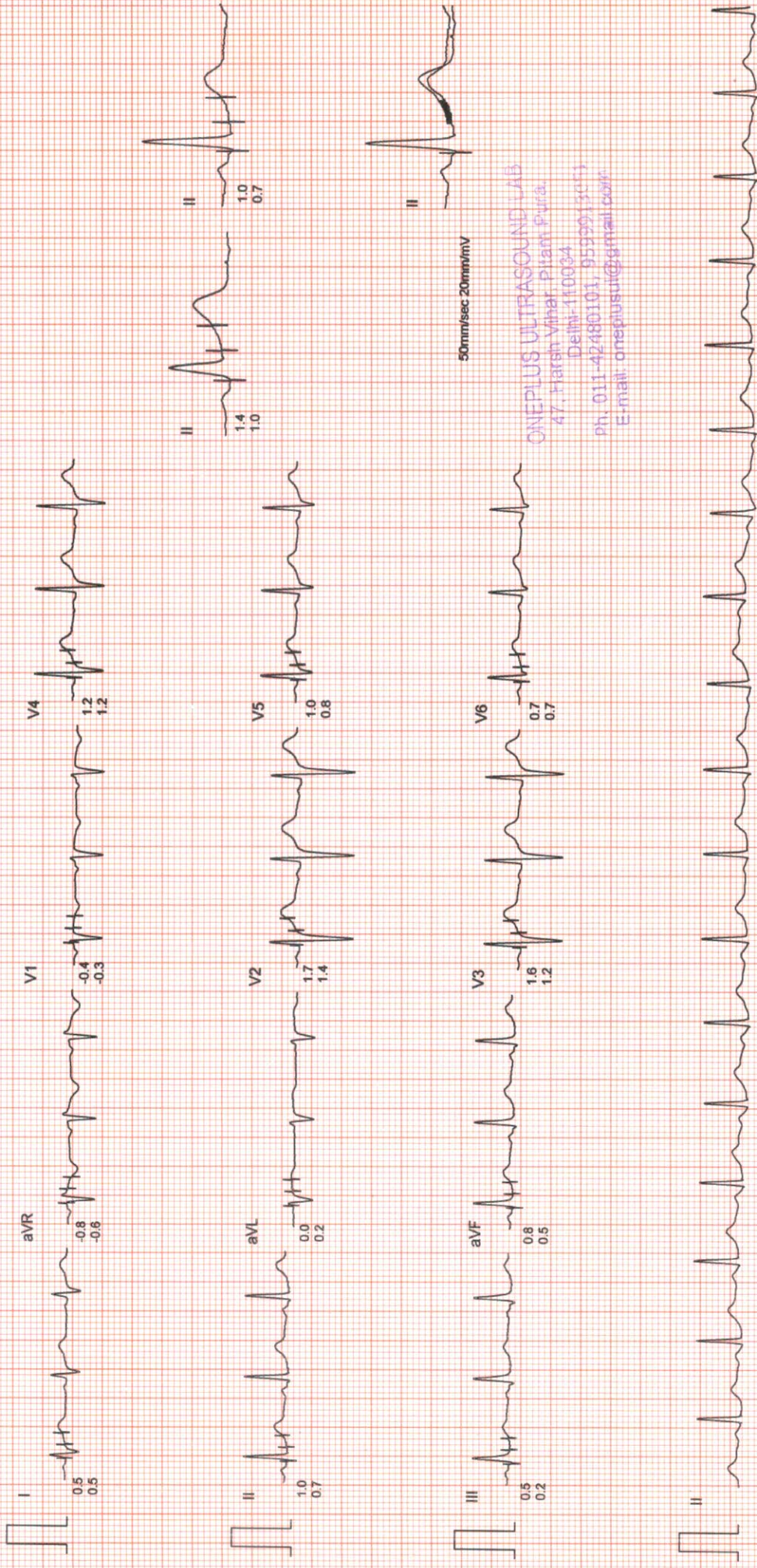
Mr. SUMIT WADHWA
I.D. : 972
AGE/SEX : 39/M
RECORDED : 8-7-2023 8:57

RATE : 107 BPM
B.P. : 134/88 mmHg

BRUCE
RECOVERY
PHASE TIME : 2:59

ST @ 10mm/mV
80ms PostJ
SPEED : 0.0 Km./Hr.
GRADE : 0.0 %

LINKED MEDIAN



50mm/sec 20mm/mV

ONEPLUS ULTRASOUND LAB
47, Harsh Vihar, Pitampura,
Delhi-110034
Ph. 011-42480101, 9599913013
E-mail: onepiusut@gmail.com

ONEPLUS ULTRASOUND LAB

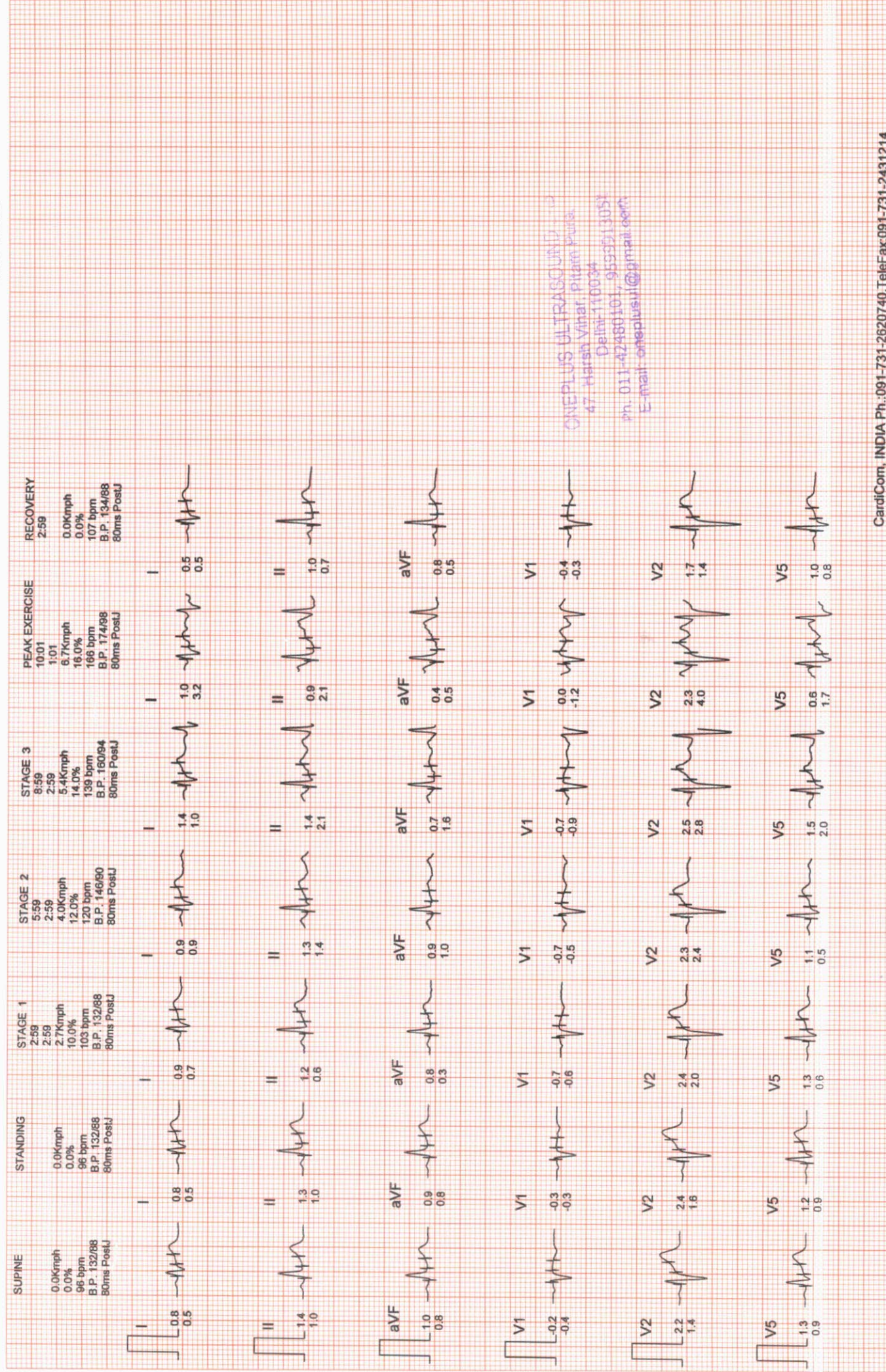
Mr. SUMIT WADHWA

I.D. : 972

AGE/SEX : 39/M

RECORDED : 8-7-2023 8:57

AVG E.C.G.



ONEPLUS ULTRASOUND LAB
47 Harsh Vihar, Pitambara Puri,
Delhi-110034
Ph. 011-42480101, 9559513051
E-mail: oneplus1@gmail.com

ONEPLUS ULTRASOUND LAB

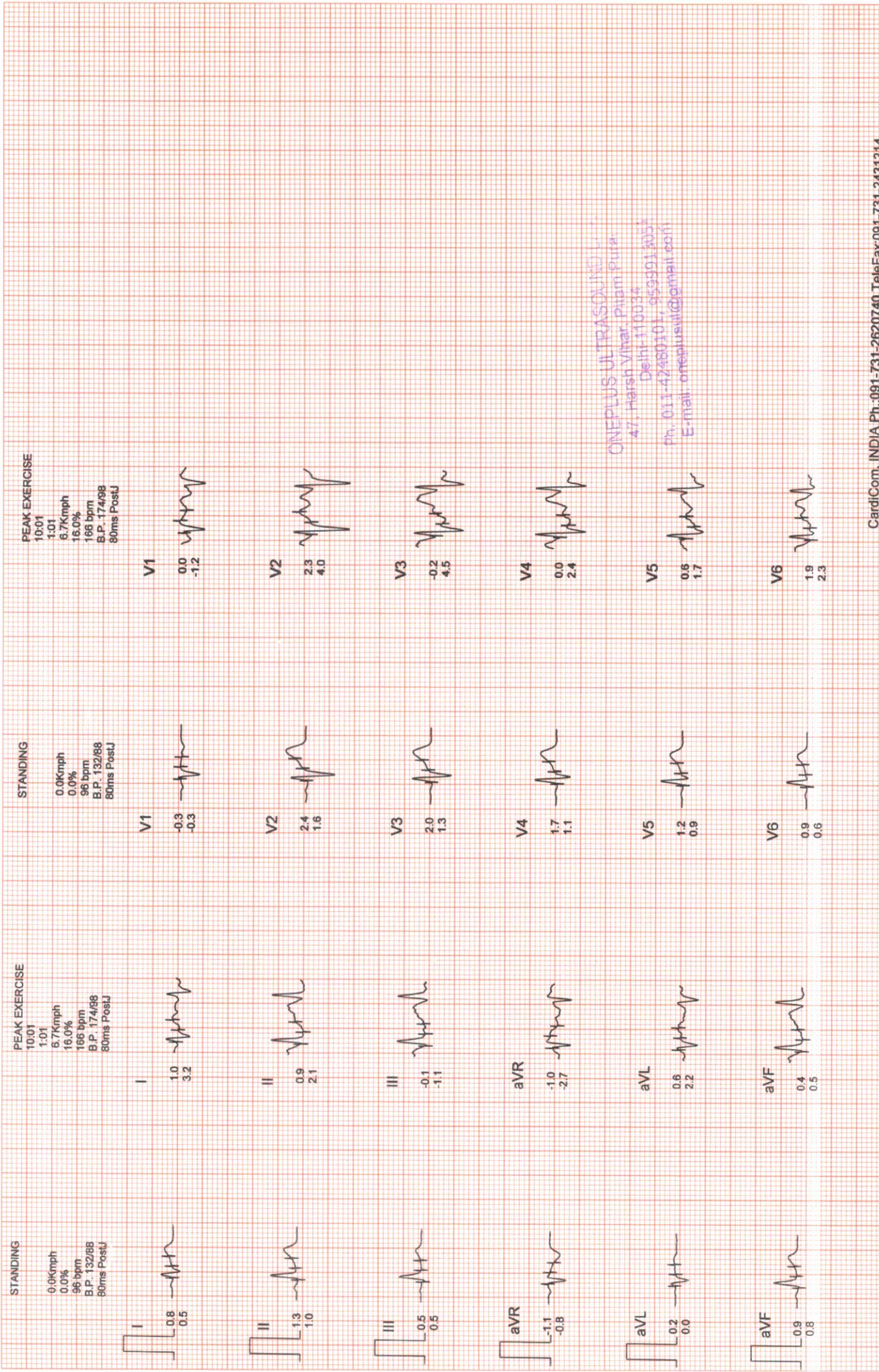
AGE/SEX : 39/M

I.D. : 972

Mr. SUMIT WADHWA

RECORDED : 8-7-2023 8:57

COMPARISON REPORT



ONEPLUS ULTRASOUND LAB
47, Harsh Vihar, Pitam Pura,
Delhi-110034
Ph. 011-42480101, 9599913053
E-mail: oneplusul@gmail.com



OnePLUS
Ultrasound Lab
— QUALITY FIRST... ALWAYS! —

Dr. Nitin Agarwal

Pathologist & Director
MBBS MD (Pathology)
Ex. Sr. Res. MAMC& Lok Nayak Hospital
Ex. Chief of Lab Dr. Lal Path labs.

Dr. Pooja (Garg) Agarwal

Radiologist & Director
MBBS (MAMC) DMRD (MAMC)
Imaging Expert In Fetal And Maternal Medicine,
University of Barcelona, Spain
Fetal Medicine Foundation (UK) Accreditation



NAME	:Mr. SUMIT WADHWA	Barcode No	:10148652
AGE/GENDER	:39 YRS/Male	SPECIMEN DATE	:08/Jul/2023 08:23AM
PATIENT ID	:117212	SPECIMEN RECEIVED	:08/Jul/2023 01:44PM
REFERRED BY	:Dr. MEDIWHEEL	REPORT DATE	:08/Jul/2023 04:12PM
CENTRE NAME	:ONEPLUS ULTRASOUND LAB	LAB NO.	:012307080005

Test Name	Result	Unit	Ref. Range
-----------	--------	------	------------

HAEMATOLOGY

Medi Wheel Health checkup < 40 Male

Glycosylated Hemoglobin (HbA1c) HPLC	5.2	%	Non Diabetic adults <5.7 Prediabetic (at risk) 5.7-6.4 Diabetes >6.4
--	-----	---	--

Estimated average blood glucose (eag) CALCULATED	103		
--	-----	--	--

Reference range (mg/dl):

90 - 120:Excellent control, 121 - 150:Good Control, 151 - 180:Average Control, 181 - 210:Action Suggested

>211:Panic value

BLOOD GROUP (ABO) Forward and Reverse grouping (Slide & Tube)	B		
---	---	--	--

Rh typing	POSITIVE		
------------------	----------	--	--

NOTE :

- * Apart from major A,B,H antigens which are used for ABO grouping and Rh typing, many minor blood group antigens exist. Agglutination may also vary according to titre of antigen and antibody.
- * So before transfusion, reconfirmation of blood group as well as cross-matching is needed.
- * Presence of maternal antibodies in newborns, may interfere with blood grouping.
- * Auto agglutination (due to cold antibody, falciparum malaria, sepsis, internal malignancy etc.) may also cause erroneous result.

CBC

Haemoglobin Non cyanide Hb analysis	15.6	g/dl	13.0-17.0
Total Leucocyte Count Electrical Impedance	6400	/cumm	4000-10000
Differential leucocyte count			
Neutrophils Electrical Impedance & Microscopic	64.4	%	40-80
Lymphocyte Electrical Impedance & Microscopic	28.90	%	20-40
Monocytes	4.00	%	2-10

Checked By.

DR. NITIN AGARWAL
MBBS, MD (PATHOLOGIST)
DMC/R/01436

47, Harsh Vihar, Pitampura, Delhi-34 ☎ 011-4248 0101, 9599913051

✉ Email: oneplusul@gmail.com 🌐 www.oneplusul.in

Page 1 of 6



NAME	:Mr. SUMIT WADHWA	Barcode No	:10148652
AGE/GENDER	:39 YRS/Male	SPECIMEN DATE	:08/Jul/2023 08:23AM
PATIENT ID	:117212	SPECIMEN RECEIVED	:08/Jul/2023 01:44PM
REFERRED BY	:Dr. MEDIWHEEL	REPORT DATE	:08/Jul/2023 04:12PM
CENTRE NAME	:ONEPLUS ULTRASOUND LAB	LAB NO.	:012307080005

Test Name	Result	Unit	Ref. Range
Electrical Impedance & Microscopic			
Eosinophils	2.0	%	1-6
Electrical Impedance & Microscopic			
Basophils	0.7	%	0-2
Electrical Impedance & Microscopic			
RBC Count	5.40	million/cumm	4.5 - 5.5
Electrical Impedance			
Hematocrit(PCV)	48.5	%	40-50
Flow Cytometry			
MCV	89.2	fl	83-101
Calculated			
MCH	28.6	pg	27-32
Calculated			
MCHC	32.1	g/dL	31.5-34.5
Calculated			
RDW-CV	13.4	%	11.4-14.0
Calculated			
Platelet count	246000	/cumm	150000-410000
Electrical Impedance			

BIOCHEMISTRY

Blood sugar fasting	89	mg/dl	70-100 mg/dl
GOD-POD			
Blood sugar pp	139	mg/dL	70.0-140.0
GOD-POD			
Bun (blood urea nitrogen)	11.20	mg/dl	8.9-21.6
CALCULATED			
Uric acid, serum	4.6	mg/dl	3.5-7.2
Uricase- PAP			
Creatinine, serum	0.6	mg/dl	0.60-1.2
Enzymatic			

LFT(LIVER FUNCTION TEST)

Bilirubin Total	0.52	mg/dl	0.1-1.2
Modified tab			
Bilirubin Conjugated	0.26	mg/dl	0-0.4
Diazotized sulfanilic acid			
Bilirubin Unconjugated	0.26	mg/dl	up to 0.7
Calculated			

Checked By.

Dr. NITIN AGARWAL
M B B S (MD (PAP))
DR. NITIN AGARWAL
MBBS (MD) (PATHOLOGIST)

47, Harsh Vihar, Pitampura, Delhi-34 ☎ 011-4248 0101, 9599913051

✉ Email: oneplusul@gmail.com 🌐 www.oneplusul.in

Page 2 of 6



OnePLUS
Ultrasound Lab
— QUALITY FIRST... ALWAYS! —

Dr. Nitin Agarwal

Pathologist & Director
MBBS MD (Pathology)
Ex. Sr. Res. MAMC& Lok Nayak Hospital
Ex. Chief of Lab Dr. Lal Path labs.

Dr. Pooja (Garg) Agarwal

Radiologist & Director
MBBS (MAMC) DMRD (MAMC)
Imaging Expert In Fetal And Maternal Medicine,
University of Barcelona, Spain
Fetal Medicine Foundation (UK) Accreditation



NAME	:Mr. SUMIT WADHWA	Barcode No	:10148652
AGE/GENDER	:39 YRS/Male	SPECIMEN DATE	:08/Jul/2023 08:23AM
PATIENT ID	:117212	SPECIMEN RECEIVED	:08/Jul/2023 01:44PM
REFERRED BY	:Dr. MEDIWHEEL	REPORT DATE	:08/Jul/2023 04:12PM
CENTRE NAME	:ONEPLUS ULTRASOUND LAB	LAB NO.	:012307080005

Test Name	Result	Unit	Ref. Range
SGOT (AST) Tris buffer	21	U/L	0-46
SGPT (ALT) Tris buffer	39	U/L	0-49
Alkaline phosphatase Amp buffer	68	U/L	40-129
GAMMA GT Szasz Method	26	U/L	10-45
Total Protein Biuret	6.8	gm/dl	6.60 - 8.70
Albumin serum BCG	3.9	g/dL	3.0-5.2
Globulin Calculated	2.90	gm/dl	1.8-3.4
Albumin/Globulin Ratio Calculated	1.34		1.10 - 2.50

LIPID PROFILE

Cholesterol CHOD-PAP	212	mg/dl	50-200
Triglycerides GPO-PAP	98	mg/dL	25-150
HDL Cholesterol Selective Inhibition	47	mg/dL	40 - 60
LDL cholesterol Calculated	145	mg/dL	<130
VLDL cholesterol Calculated	19.6	mg/dL	5-40
Cholesterol/HDL Ratio Calculated	4.5		Low Risk 3.3-4.97 Average Risk 4.4-7.1 Moderate Risk 7.1-11.0 High Risk >11.0
LDL/HDL Ratio Calculated	3.1		0 - 3.55

According to ATP III and NCEP guidelines

Parameter	Normal	Desirable	Borderline	High
-----------	--------	-----------	------------	------

Checked By.

DR. NITIN AGARWAL
MBBS, MD (PATHOLOGIST)
DMC/R/01436

47, Harsh Vihar, Pitampura, Delhi-34 ☎ 011-4248 0101, 9599913051

✉ Email: oneplusul@gmail.com 🌐 www.oneplusul.in

Page 3 of 6

• Clinical correlation is essential for final diagnosis. • If test results are unsatisfactory please contact personally or on phone. • This report is for perusal of doctors only.
• All disputes are subject to Delhi jurisdiction only. • Not for medico legal case. • All congenital anomalies in a foetus may not be diagnosed in routine obstetric ultrasound.



NAME	:Mr. SUMIT WADHWA	Barcode No	:10148652
AGE/GENDER	:39 YRS/Male	SPECIMEN DATE	:08/Jul/2023 08:23AM
PATIENT ID	:117212	SPECIMEN RECEIVED	:08/Jul/2023 01:44PM
REFERRED BY	:Dr. MEDIWHEEL	REPORT DATE	:08/Jul/2023 04:12PM
CENTRE NAME	:ONEPLUS ULTRASOUND LAB	LAB NO.	:012307080005

Test Name	Result	Unit	Ref. Range
Total cholesterol	<200	200-239	240
Triglycerides	<150	150-199 200-499	500
LDL	Optimal <100 Near Optimal 100-129	130-159 160-180	190
HDL	<40 : LOW 60 : HIGH		

BUN/Creatinine ratio

UREA UREASE-GLDH	24.00	mg/dl	15-45
Bun (blood urea nitrogen) CALCULATED	11.21	mg/dl	8.9-21.6
CREATININE ENZYMATIC	0.60	mg/dl	0.30-1.10
BUN/Creatinine ratio CALCULATED	18.68		10.0 - 20.0

ENDOCRINOLOGY

THYROID PROFILE(T3,T4,TSH)

Triiodothyronine total [t3] ECLIA	0.85	ng/dl	0.52-1.9
Thyroxine total [t4] ECLIA	7.60	µg/dl	4.4 - 10.8
TSH (Thyroid Stimulating Hormone) Enzyme linked fluorescent assay	3.40	µIU/ml	0.25-5.0

AGE WISE VARIATION IN TSH

AGE	TSH(µIU/ml)	AGE	TSH(µIU/ml)
1-4 weeks	1.00 - 19.0	16-20 yrs	0.25 - 5.0
1-12 mths	1.70 - 9.1	21 - 80 yrs	0.25 - 5.0
1-5 yrs	0.80 - 8.2	I st trimester	0.25 - 5.0
6-10 yrs	0.25 - 5.0	II nd trimester	0.50 - 5.0
11-15 yrs	0.25 - 5.0	II rd trimester	0.4 - 6.0

Checked By.

DR. NITIN AGARWAL
MBBS, MD (PATHOLOGIST)

Dr. NITIN AGARWAL
MBBS, MD (Path)
DMC/R/01436

47, Harsh Vihar, Pitampura, Delhi-34 ☎ 011-4248 0101, 9599913051

✉ Email: oneplusul@gmail.com 🌐 www.oneplusul.in



NAME	:Mr. SUMIT WADHWA	Barcode No	:10148652
AGE/GENDER	:39 YRS/Male	SPECIMEN DATE	:08/Jul/2023 08:23AM
PATIENT ID	:117212	SPECIMEN RECEIVED	:08/Jul/2023 01:44PM
REFERRED BY	:Dr. MEDIWHEEL	REPORT DATE	:08/Jul/2023 04:12PM
CENTRE NAME	:ONEPLUS ULTRASOUND LAB	LAB NO.	:012307080005

Test Name	Result	Unit	Ref. Range
-----------	--------	------	------------

Reference ranges - Interpretation of Diagnostic tests - (Jacques Wallach)

1. Primary hypothyroidism is accompanied by depressed serum T3 and T4 values and elevated serum TSH level.
2. Primary hyperthyroidism is accompanied by elevated serum T3 and T4 levels along with depressed TSH values.
3. Slightly elevated T3 levels may be found in pregnancy and estrogen therapy, while depressed levels may be encountered in severe illness, renal failure and during therapy with drugs like propranolol and propyl thiouracil.
4. Although elevated TSH levels are nearly always indicative of primary hypothyroidism, and may be seen in secondary thyrotoxicosis

CLINICAL PATHOLOGY

URINE ROUTINE (Strip/microscopy)

Physical examination

Quantity	20	ML
Colour	PALE YELLOW	
Transparency	CLEAR	CLEAR
Sp.gravity BROMOTHYMOL BLUE	1.015	1.010-1.030
pH Double Indicators Test	6.00	
Reaction	ACIDIC	ACIDIC

Chemical examination

Urine protein Protein Ionization	NIL	NIL
Urine sugar Oxidation Reaction	NIL	NIL
Bilirubin, urine	NEGATIVE	NEGATIVE
Urobilinogen P-Aminobenzoic Acid and Phenazopyridine Reaction	NORMAL	NORMAL
Ketones Acetoacetate and Dichlorobenzene Reaction	NEGATIVE	NEGATIVE

Microscopic examination

Pus cells. Microscopy	1-2	/HPF	0-2
Epithelial cells Microscopy	1-2	/HPF	NIL
R.B.C.	NIL	/HPF	NIL

Checked By.

Dr. NITIN AGARWAL
MBBS (MAMC)
DMC/KO/117212

47, Harsh Vihar, Pitampura, Delhi-34 ☎ 011-4248 0101, 9599913051

✉ Email: oneplusul@gmail.com 🌐 www.oneplusul.in

Page 5 of 6



OnePLUS
Ultrasound Lab

— QUALITY FIRST... ALWAYS! —

Dr. Nitin Agarwal

Pathologist & Director
MBBS MD (Pathology)
Ex. Sr. Res. MAMC& Lok Nayak Hospital
Ex. Chief of Lab Dr. Lal Path labs.

Dr. Pooja (Garg) Agarwal

Radiologist & Director
MBBS (MAMC) DMRD (MAMC)
Imaging Expert In Fetal And Maternal Medicine,
University of Barcelona, Spain
Fetal Medicine Foundation (UK) Accreditation



NAME	:Mr. SUMIT WADHWA	Barcode No	:10148652
AGE/GENDER	:39 YRS/Male	SPECIMEN DATE	:08/Jul/2023 08:23AM
PATIENT ID	:117212	SPECIMEN RECEIVED	:08/Jul/2023 01:44PM
REFERRED BY	:Dr. MEDIWHEEL	REPORT DATE	:08/Jul/2023 04:12PM
CENTRE NAME	:ONEPLUS ULTRASOUND LAB	LAB NO.	:012307080005

Test Name	Result	Unit	Ref. Range
Microscopy			
Casts	NIL	/HPF	NIL
Microscopy			
Crystals	NIL	/HPF	NIL
Microscopy			
Bacteria	NIL	/HPF	NIL
Microscopy			
Others.	NIL	NIL	NIL

STOOL ROUTINE(MANUAL METHOD/MICROSCOPY)

Physical examination

Colour	BROWNISH		
Consistency	SEMI FORMED		Semi Formed
Blood	ABSENT		Absent
Mucus	ABSENT		Absent

Chemical examination, stool

pH	6.00
Double Indicators Test	

Microscopic examination

Pus cells	0-1	/HPF	
Microscopy			
R.B.C.	NIL	/HPF	NIL
Microscopy			
Ova	NIL		NIL
Microscopy			
Cysts	NIL		NIL
Microscopy			
Bacteria	PRESENT	/HPF	NIL
Microscopy			
Others	NIL		

*** End Of Report ***

Checked By.

DR. NITIN AGARWAL
MBBS, MD (PATHOLOGIST)
DMC/R/01436

47, Harsh Vihar, Pitampura, Delhi-34 ☎ 011-4248 0101, 9599913051

📧 Email: oneplusul@gmail.com 🌐 www.oneplusul.in

Page 6 of 6

• Clinical correlation is essential for final diagnosis. • If test results are unsatisfactory please contact personally or on phone. • This report is for perusal of doctors only. • All disputes are subject to Delhi jurisdiction only. • Not for medico legal case. • All congenital anomalies in a foetus may not be diagnosed in routine obstetric ultrasound.

Name	: Mr. SUMIT WADHWA	Age/Sex	: 39 YRS/Male
Ref. By	: Dr. MEDIWHEEL	Lab No	: 012307080005
Date	: 08-Jul-2023	Patient ID	: LSHHI117212

ULTRASOUND EXAMINATION----WHOLE ABDOMEN

Liver is normal in size (15.0 cm) and normal in outline with **altered echopattern. Diffuse increase in echogenicity of liver parenchyma is noted, suggestive of fatty infiltration (grade II/III).** Intrahepatic biliary radicles are not dilated. No abscess or mass lesion seen. Hepatic veins, portal vein, IVC and aorta are normal. CBD is normal in caliber.

Gall bladder is well distended with anechoic lumen. Wall thickness is normal.

Both kidneys are normal in size, shape, position, outline and echopattern. Corticomedullary differentiation is maintained. No pelvicalyceal dilation or mass lesion is seen.

Spleen is normal in size and echotexture. No mass lesion seen.

Pancreas is normal in size, outline and echotexture.

Urinary bladder is normal in shape and position. No evidence of intravesical stone or mass seen.

Prostate is normal in size, shape and echopattern.

Prostate measures 3.5 x 3.2 x 3.2 cm. **Weight of prostate is 19.0 grams.**

No abnormal bowel wall thickening seen in right iliac fossa.

No free fluid seen anywhere in abdomen.

IMPRESSION:

- **Fatty infiltration of liver (grade II/III) with no hepatomegaly.**

DR. POOJA GARG
Dr. POOJA GARG
RADIOLOGIST
REG NO DMC/R/03398
Reg No. DMC/R/03398
Radiologist

Type By : POOJA

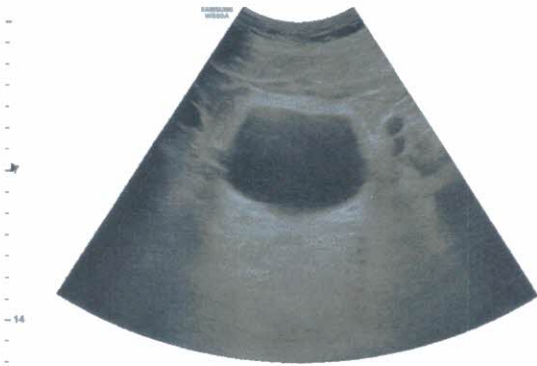47, Harsh Vihar, Pitampura, Delhi-34 ☎ 011-4248 0101, 9599913051

✉ Email: oneplusul@gmail.com 🌐 www.oneplusul.in

WS80A MR SUMIT 39/M OnePlus Ultrasound Lab MI 1.4 08-07-2023
CA1-7A / Abdomen / FR 25Hz Tis 0.1 10:08:14 AM

2D G50 DR135-FAB P90 Frq Gen. 16.0cm

SR CA1



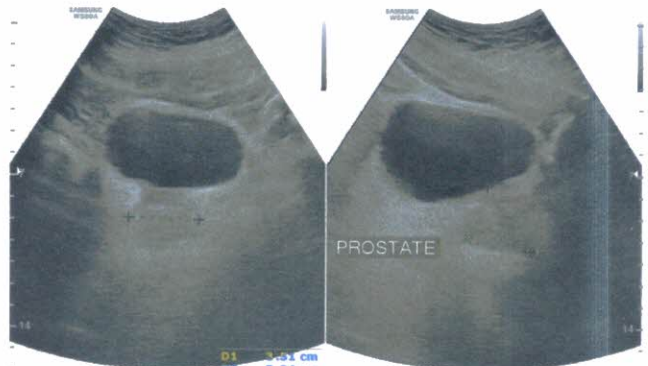WS80A MR SUMIT 39/M OnePlus Ultrasound Lab MI 1.4 08-07-2023
CA1-7A / Abdomen / FR 25Hz Tis 0.1 10:08:30 AM

2D G50 DR135-FAB P90 Frq Gen. 16.0cm

SR CA1

2D G50 DR135-FAB P90 Frq Gen. 16.0cm

SR CA1



D1 3.51 cm
D2 3.24 cm
D3 3.19 cm
Vol. 19.00 ml

D1 3.51 cm
D2 3.24 cm

WS80A MR SUMIT 39/M OnePlus Ultrasound Lab MI 1.4 08-07-2023
CA1-7A / Abdomen / FR 19Hz Tis 0.1 10:09:45 AM

2D G50 DR135-FAB P90 Frq Pen. 22.0cm

SR CA1

2D G50 DR135-FAB P90 Frq Pen. 22.0cm

SR CA1



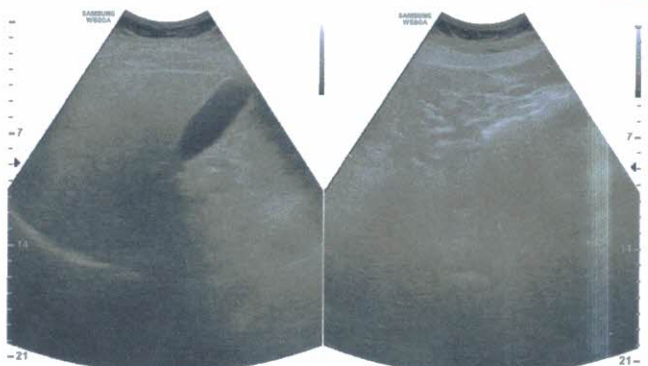WS80A MR SUMIT 39/M OnePlus Ultrasound Lab MI 1.4 08-07-2023
CA1-7A / Abdomen / FR 19Hz Tis 0.1 10:09:01 AM

2D G50 DR135-FAB P90 Frq Pen. 22.0cm

SR CA1

2D G50 DR135-FAB P90 Frq Pen. 22.0cm

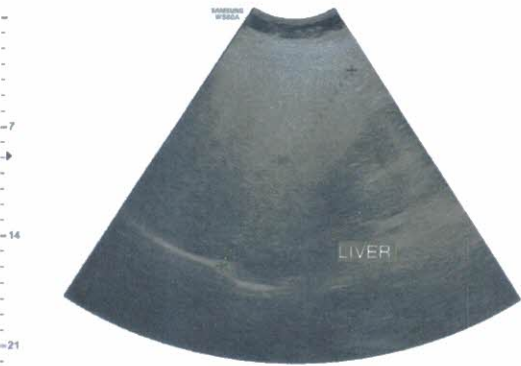SR CA1



WS80A MR SUMIT 39/M OnePlus Ultrasound Lab MI 1.4 08-07-2023
CA1-7A / Abdomen / FR 19Hz Tis 0.1 10:09:11 AM

2D G50 DR135-FAB P90 Frq Pen. 22.0cm

SR CA1



D1 14.95 cm

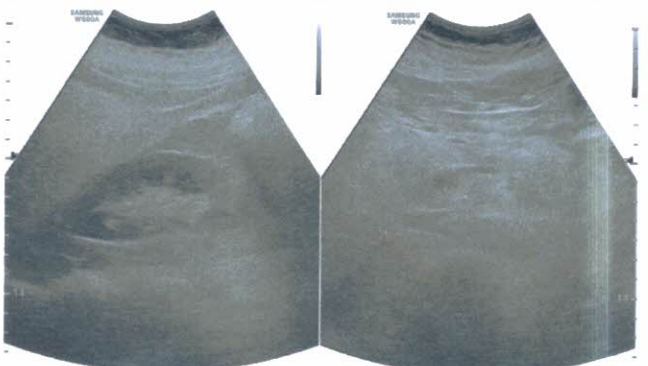WS80A MR SUMIT 39/M OnePlus Ultrasound Lab MI 1.4 08-07-2023
CA1-7A / Abdomen / FR 23Hz Tis 0.1 10:09:34 AM

2D G50 DR135-FAB P90 Frq Pen. 18.0cm

SR CA1

2D G50 DR135-FAB P90 Frq Pen. 18.0cm

SR CA1



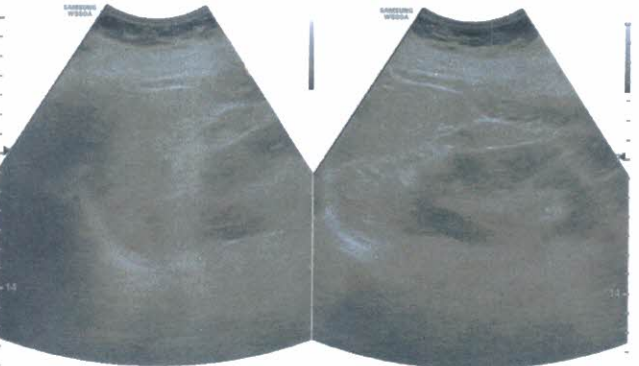
WS80A MR SUMIT 39/M OnePlus Ultrasound Lab MI 1.4 08-07-2023
CA1-7A / Abdomen / FR 23Hz Tis 0.1 10:09:51 AM

2D G50 DR135-FAB P90 Frq Pen. 18.0cm

SR CA1

2D G48 DR135-FAB P90 Frq Pen. 18.0cm

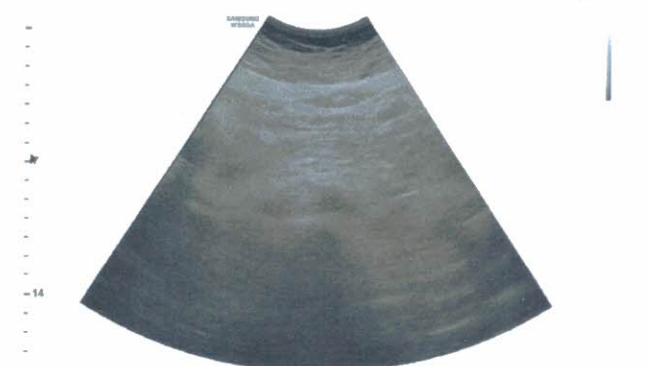SR CA1



WS80A MR SUMIT 39/M OnePlus Ultrasound Lab MI 1.4 08-07-2023
CA1-7A / Abdomen / FR 23Hz Tis 0.1 10:10:01 AM

2D G41 DR135-FAB P90 Frq Pen. 18.0cm

SR CA1

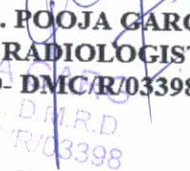


Name	: Mr. SUMIT WADHWA	Age/Sex	: 39 YRS/Male
Ref. By	: Dr. MEDIWHEEL	Lab No	: 012307080005
Date	: 08-Jul-2023	Patient ID	: LSHHI117212

X-ray-Chest PA view

Bony cage and soft tissues are normal.
Cardiothoracic ratio is normal.
Mediastinum is normal.
Both hila are normal.
Both costophrenic angles are clear.
Both domes of diaphragm are normal.
Lung fields are clear. No parenchymal lesion seen.

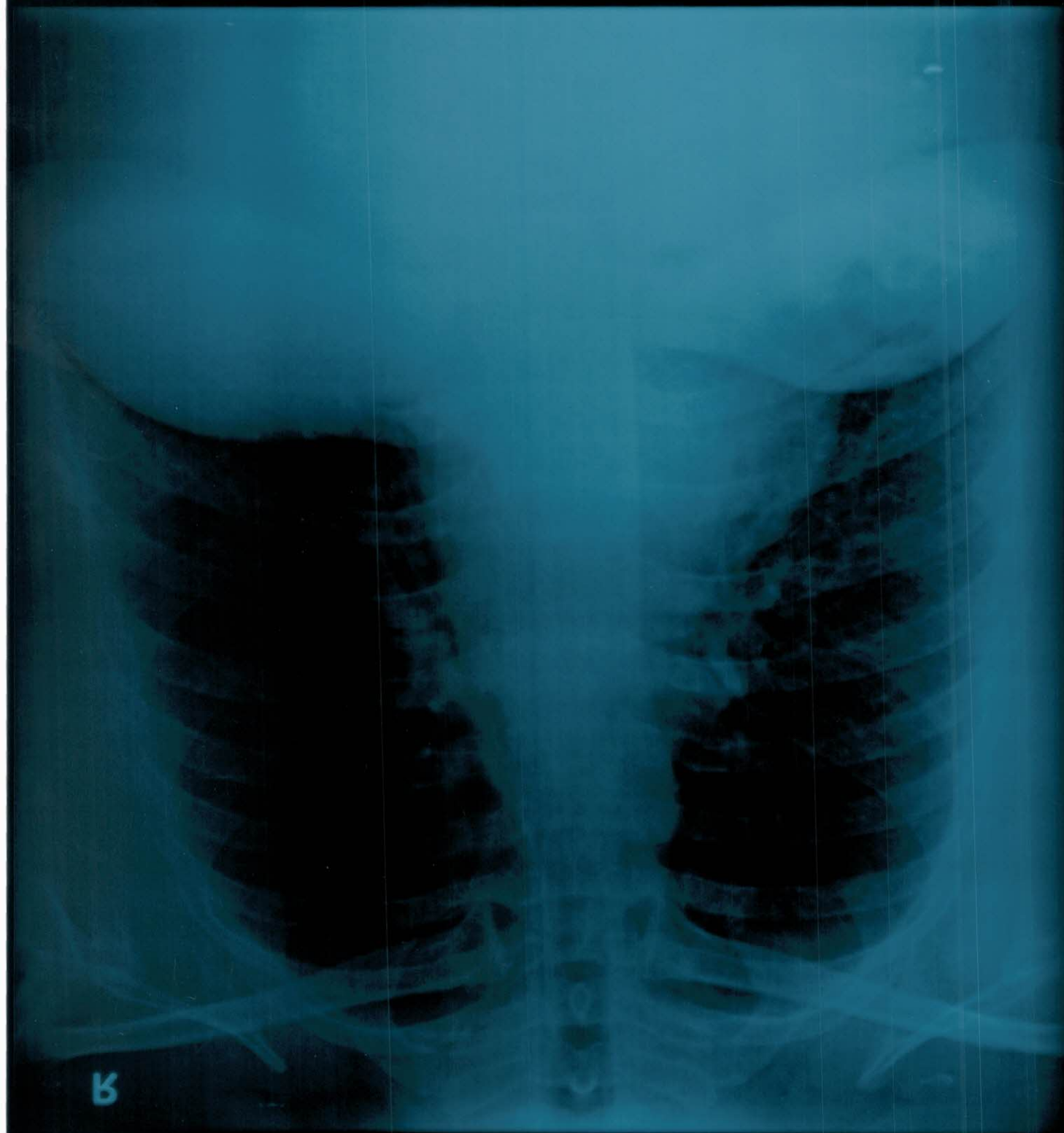IMPRESSION: Normal Study.


DR. POOJA GARG
RADIOLOGIST
REG NO- DMC/R/03398
MBBS, D.M.R.D.
Reg No- DMC/R/03398

Type By : POOJA

47, Harsh Vihar, Pitampura, Delhi-34 ☎ 011-4248 0101, 9599913051
✉ Email: oneplusul@gmail.com 🌐 www.oneplusul.in

ОИЕБГУС УГТРАСОЛИД ГАР АТ-НАРГН АИНАР РИТАМЬУКА
MR SUMIT MADHWA 39YRS 08-01-2020 M CHEST PA VIEW



B

R

MR SUMIT WADHWA 39YRS 08-07-2023 M CHEST PA VIEW
ONEPLUS ULTRASOUND LAB,47-HARSH VIHAR,PITAMPURA