

LETTER OF APPROVAL / RECOMMENDATION

To,

The Coordinator,
Mediwheel (Arcofemi Healthcare Limited)
Helpline number: 011- 41195959

Dear Sir / Madam,

Sub: Annual Health Checkup for the employees of Bank of Baroda

This is to inform you that the following employee wishes to avail the facility of Cashless Annual Health Checkup provided by you in terms of our agreement.

PARTICULARS	EMPLOYEE DETAILS
NAME	MR. BHURIA KUSHAL
EC NO.	113747
DESIGNATION	HEAD CASHIER "E"_II
PLACE OF WORK	INDRAL
BIRTHDATE	13-12-1989
PROPOSED DATE OF HEALTH CHECKUP	11-06-2022
BOOKING REFERENCE NO.	22J113747100020066E

This letter of approval / recommendation is valid if submitted along with copy of the Bank of Baroda employee id card. This approval is valid from **09-06-2022** till **31-03-2023**. The list of medical tests to be conducted is provided in the annexure to this letter. Please note that the said health checkup is a **cashless facility** as per our tie up arrangement. We request you to attend to the health checkup requirement of our employee and accord your top priority and best resources in this regard. The EC Number and the booking reference number as given in the above table shall be mentioned in the invoice, invariably.

We solicit your co-operation in this regard.

Yours faithfully,

Sd/-

**Chief General Manager
HRM Department
Bank of Baroda**

(Note: This is a computer generated letter. No Signature required. For any clarification, please contact Mediwheel (Arcofemi Healthcare Limited).)



भारत सरकार
GOVERNMENT OF INDIA



कुशल भूरिया मीणा
Kushal Bhuria Meena
जन्म तिथि/ DOB: 13/12/1989
पुरुष / MALE



6376 3863 7220

आधार-आम आदमी का अधिकार



भास्तीय विशिष्ट पहचान प्राधिकरण
UNIQUE IDENTIFICATION AUTHORITY OF INDIA

पता:

S/O: लक्ष्मण राम मीणा,
नज़दीक बस स्टेंड,
मानसरोवर कॉलोनी,
राजगढ़, अलवर,
राजस्थान - 301408

Address:

S/O: Laxman Ram Meena, near bus
stand, mansarovar colony, Rajgarh,
Alwar,
Rajasthan - 301408

6376 3863 7220

Aadhaar-Aam Admi ka Adhikar



बैंक ऑफ़ बड़ोदा
Bank of Baroda

नाम कुशल भुरिया
Name KUSHAL BHURIA

कर्मचारी कूट क्र.

E.C. No. 113747



D-K

जायीकर्ता प्राधिकारी
Issuing Authority

धारक के हस्ताक्षर
Signature of Holder



Savita

Superspeciality Hospital
(A Unit of Solace Healthcare Pvt. Ltd.)

Panvar Char Rasta, Waghodia-Dabhoi Ring Road, Vadodara - 390019

☎ 0265 2578844 / 2578849 ✉ mh@savitahospital.com 🌐 savitahospital.com

PHYSICIAN EXAMINATION

Name:- KUSHAL BHURIA

Age: 33/MALE

Reg.No: 20220602241

DOE: 25/06/2022

Physical Examination:

Height:183CM Weight: 110KG PULSE: 82 Temperature: NORMAL
BMI: 32.08 BP: 140/90 SPO2- 99%

Chief Complaint: NAD

Past History: NAD

General Examination: NAD

Systemic Examination: OBESSE+++

INVESTIGATION : FBS & PP2BS HIGH

ADVICE:

- * TO START OHA
- * SUGAR FREE DIET
- * REGULAR EXERCISE
- * REGULAR MONITORING OF FBS & PP2BS

DR HIREN PATEL





Savita
Superspeciality Hospital
(A Unit of Solace Healthcare Pvt. Ltd.)

Parivar Chir. Rm
0265 25731

CANON RK-F2
25/JUN/2022 11:57
No. : 002979

NAME : M/F  savitahospital.com

Examination By Op

<RIGHT>
[REF] VD: 0.C
SPH CYL AX
-0.50 -0.25 90

<LEFT >
[REF]
-0.25 0.00 180

PD : 67 mm

SOLACE HEALTH CARE
WAGHODIA ROAD,
VADODARA.

Name:- KUSHAL BHURIA

Reg.No: 20220602241

Present Complaints: NAD

Medical History: NAD

Examination Of Eye:	<u>Right</u>	<u>Left</u>
External Examination :	NAD	NAD
Ati Seg Examination:	A/S WNL	NAD
Schiotz Tonometry IOP:	RRRL	NAD

Fundus: NILL

Without Glass Distant Vision: 6/6 ___ 6/6

Near Vision: N6 ___ N6

With Glass Distant Vision: _____

Near Vision: _____

Colour Vision (With Ishihara Chart): WNL

Advice:




DR CHETAN CHAUHAN



Savita

Superspeciality Hospital
A Unit of Solace Healthcare Pvt. Ltd.

Panvar Char Rasta, Waghodia Dahhor Ring Road, Vadodara - 390019
0269 2578844 - 2578849 | info@savitahospital.com | savitahospital.com

Patient Name :	KHUSHAL . BHURIA	Sample No. :	20220603593 
Patient ID :	20220602241	Visit No. :	OPD20220606314
Age/Sex :	33y/Male	Call. Date :	25-Jun-2022 10:06
Consultant :	DR HIREN PATEL	S. Coll. Date :	25-Jun-2022 13:21
Ward :	-	Report Date :	25-Jun-2022 14:32

CBC, ESR


Investigation	Result	Normal Value
Hemoglobin :	14.0 gm/dl	13.5 to 18.0 gm/dl
P.C.V. :	42.3 %	42.0 to 52.0 %
M.C.V. :	81.5 fL	78 to 100 fL
M.C.H. :	27.0 pg	27 to 31 pg
M.C.H.C. :	33.1 g/dl	32 to 36 g/dl
RDW :	13.0 %	11.5 to 14.0 %
RBC Count :	5.19 X 10 ⁶ /cumm	4.7 to 6.0 X 10 ⁶ /cumm
Polymorphs :	63 %	38 to 70 %
Lymphocytes :	33 %	15 to 48 %
Eosinophils :	02 %	0 to 6 %
Monocytes :	02 % [L]	3 to 11 %
Basophils :	00 %	0.0 to 1.0 %
Total :	100	< 100 > 100
WBC Count :	9500 /cmm	4000 to 10000 /cmm
Platelets Count :	291000 /cmm	1,50,000 to 4,50,000 /cmm
ESR - After One Hour :	27 mm/hr [H]	1 to 13 mm/hr

P/S :



Dr. Mehul Desai
G-9521



Patient Name : KHUSHAL . BHURIA	Sample No. : 20220603593 
Patient ID : 20220602241	Visit No. : OPD20220606314
Age/Sex : 33y/Male	Call. Date : 25-Jun-2022 10:06
Consultant : DR HIREN PATEL	S. Coll. Date : 25-Jun-2022 13:21
Ward : -	Report Date : 25-Jun-2022 14:32

Blood Group

Investigation	Result	Normal Value
BLOOD GROUP :		
ABO	AB	
Rh	Positive	

RENAL FUNCTION TEST

Investigation	Result	Normal Value
Creatinine :	0.7 mg/dl	0.6 - 1.4 mg/dl
Urea :	15 mg/ dl	13 - 45 mg/dl
Uric Acid :	4.7 mg/dl	3.5 - 7.2 mg/dl
Calcium :	8.1 mg/dl	8.5 - 10.5
Phosphorus :	3.8 mg/dl	1.5 - 6.8



M Desai

Dr. Mehl Desai
G-9521



Patient Name : KHUSHAL BHURIA	Sample No. : 20220603593 
Patient ID : 20220602241	Visit No. : OPD20220606314
Age/Sex : 33y/Male	Call. Date : 25-Jun-2022 10:06
Consultant : DR HIREN PATEL	S. Coll. Date : 25-Jun-2022 13:21
Ward : -	Report Date : 25-Jun-2022 14:32

LFT (Liver Function Test)


Investigation	Result	Normal Value
Total Bilirubin :	0.8 mg/dl	0.2 to 1.0 mg/dl
Direct Bilirubin :	0.4 mg/dl	0.0 to 0.2 mg/dl
Indirect Bilirubin :	0.4 mg/dl	0.0 to 0.8 mg/dl
AST (SGOT) :	48 U/L [H]	5 to 34 U/L
ALT (SGPT) :	78 U/L [H]	0 to 55 U/L
Total Protein (TP) :	6.7 g/dL	6.4 to 8.3, g/dl
Albumin (ALB) :	3.8 g/dl	3.5 to 5.2 g/dl
Globulin :	2.9 g/dl	2.3 to 3.5 g/dl
A/G Ratio :	1.31	
Alkaline Phosphatase (ALP) :	110 U/L	40 to 150 U/L
GAMMA GT. :	27 U/L	7 to 35 U/L



M Desai

Dr. Mehul Desai
G-9521



Patient Name : KHUSHAL . BHURIA	Sample No. : 20220603593 
Patient ID : 20220602241	Visit No. : OPD20220606314
Age/Sex : 33y/Male	Call. Date : 25-Jun-2022 10:06
Consultant : DR HIREN PATEL	S. Coll. Date : 25-Jun-2022 13:21
Ward : -	Report Date : 25-Jun-2022 14:32

Lipid Profile

Investigation	Result	Normal Value
Sample :	Fasting	
Sample Type :	Normal	
Cholesterol (Chol) :	137 mg/dl	Low risk : < 200 Moderate risk : 200 - 239 High risk : > or = 240
Triglyceride :	107 mg/dl	Normal : < 150.0 Borderline high : 150 - 199 High : 200 - 499 Very High : > or = 500
HDL Cholesterol :	43 mg/dl	Low risk : >or = 60 mg/dL High risk : Up to 35 mg/dL
LDL :	72.6 mg/dl [L]	131.0 to 159.0(N) < 130.0(L) > 159.0(H)
VLDL :	21.4 mg/dl	Up to 0 to 34 mg/dl
LDL/HDL Ratio :	1.69	Low risk : 0.5 to 3.0 Moderate risk : 3.0 to 6.0 Elevted level high > 6.0
Total Chol / HDL Ratio :	3.19	Low Risk : 3.3 to 4.4 Average Risk : 4.4 to 7.1 Moderate Risk : 7.1 to 11.0 High Risk : > 11.0
Total Lipids :	587 mg/dl	400 to 700 mg/dl

Note :- Lipemic samples give high triglyceride value and falsely low LDL value.



Dr. Mehul Desai
G-9521



Savita

Superspeciality Hospital
(A Unit of Solace Healthcare Pvt. Ltd.)


Parivar Char Rasta, Waghodia Dabhor Ring Road, Vadodara 390019

☎ 0265 2578844 / 2578849 ✉ mb@savitahospital.com 🌐 savitahospital.com

Patient Name : KHUSHAL . BHURIA	Sample No. : 20220603593 
Patient ID : 20220602241	Visit No. : OPD20220606314
Age/Sex : 33y/Male	Call. Date : 25-Jun-2022 10:06
Consultant : DR HIREN PATEL	S. Coll. Date : 25-Jun-2022 13:21
Ward : -	Report Date : 25-Jun-2022 14:32


Urine R/M

Investigation	Result	Normal Value
Quantity - :	20 ml	
Colour - :	Pale Yellow	
Reaction (pH) :	6.0	4.6-8.0
Turbidity :	Clear	
Deposit :	Absent	Absent
Sp.Gravity :	1.010	1.005-1.010
Protein :	Absent	Absent
Glucose :	Absent	Absent
Bile Salts :	Absent	Absent
Bile pigments :	Absent	Absent
Ketones :	Absent	Absent
Urobilinogen :	Absent	
Blood :	Absent	Absent
Pus Cells :	1-3 /hpf	0-5/hpf
Red Blood Cells :	1-2 /hpf	Absent
Epithelial Cells :	0-1 /hpf	



Dr. Mehul Desai
G-9521



Patient Name : KUSHAL . BHURIA	Sample No. : 20220603593 
Patient ID : 20220602241	Visit No. : OPD20220606314
Age/Sex : 33y/Male	Call. Date : 25-Jun-2022 10:06
Consultant : DR HIREN PATEL	S. Coll. Date : 25-Jun-2022 13:21
Ward : -	Report Date : 25-Jun-2022 17:00

FBS & PPBS

Investigation	Result	Normal Value
Blood Sugar (FBS) :	152 mg/dl [H]	74 - 100 mg/dl
Urine Sugar (FUS) :	Nil	
Blood Sugar (PP2BS) :	267 mg/dl [H]	70 to 120 mg/dl
Urine Sugar (PP2US) :	++	

HBA1C

Investigation	Result	Normal Value
Glycosylated Hb :	8.3 % [H]	Near Normal Glycemia : 6 to 7 Excellent Control : 7 to 8 Good Control : 8 to 9 Fair Control : 9 to 10 Poor Control : > 10
Average Plasma Glucose of Last 3 Months :	191.51	



Mehul Desai

Dr. Mehul Desai
G-9521



Savita
Superspeciality Hospital



Parivar Char Rasta, Waghodia-Dabhoi Ring Road, Vadodara-390019
0265-2578844 / 2578849 | mh@savitahospital.com | savitahospital.com



TEST REPORT

Name : KHUSHAL BHURIYA	Acc. ID : 221010950
Age/Sex : 33 Years / Male	Birthdate : 25-Jun-2022 02:25 PM
Refd. By : SAVITA SUPERSPECIALITY HOSPITAL	Status : Final
Sample : Serum	PassportNo:
Client Details : SAVITA SUPERSPECIALITY HOSPITAL	Mobile :
	Regd. Dt : 25-Jun-2022 02:25 PM
	Coll Dt. TM. : 25-Jun-2022 02:00 PM
	Recd. Dt. Tm. : 25-Jun-2022 02:25 PM
	Report Dt. Tm. : 25-Jun-2022 03:47 PM

IMMUNOLOGY

Test Name	Result	Unit	Biological Ref. Interval
-----------	--------	------	--------------------------

THYROID FUNCTION TEST

T3 (Triiodothyronine) <small>CHEMILUMINESCENT MICROPARTICLE IMMUNOASSAY</small>	1.82	ng/mL	0.97 - 1.69
T4 (Thyroxine) <small>CHEMILUMINESCENT MICROPARTICLE IMMUNOASSAY</small>	10.40	µg/dL	5.5 - 11.0
TSH <small>CHEMILUMINESCENT MICROPARTICLE IMMUNOASSAY</small>	3.610	µIU/ml	0.4 - 4.2

----- End Of Report -----

This is an Electronically Authenticated Report.

Kinjal Patel
Dr. Kinjal Patel
M. D. PATHOLOGY
GMC No. G-33123

Verified By
Auto



Dr. VIRAL A. PATEL
M. D. PATHOLOGY
GMC No. G-22658

Page 1 of 1

20220602241
33 Years

bburia, khusal
Male

25-JUN-22 10:40:34 AM

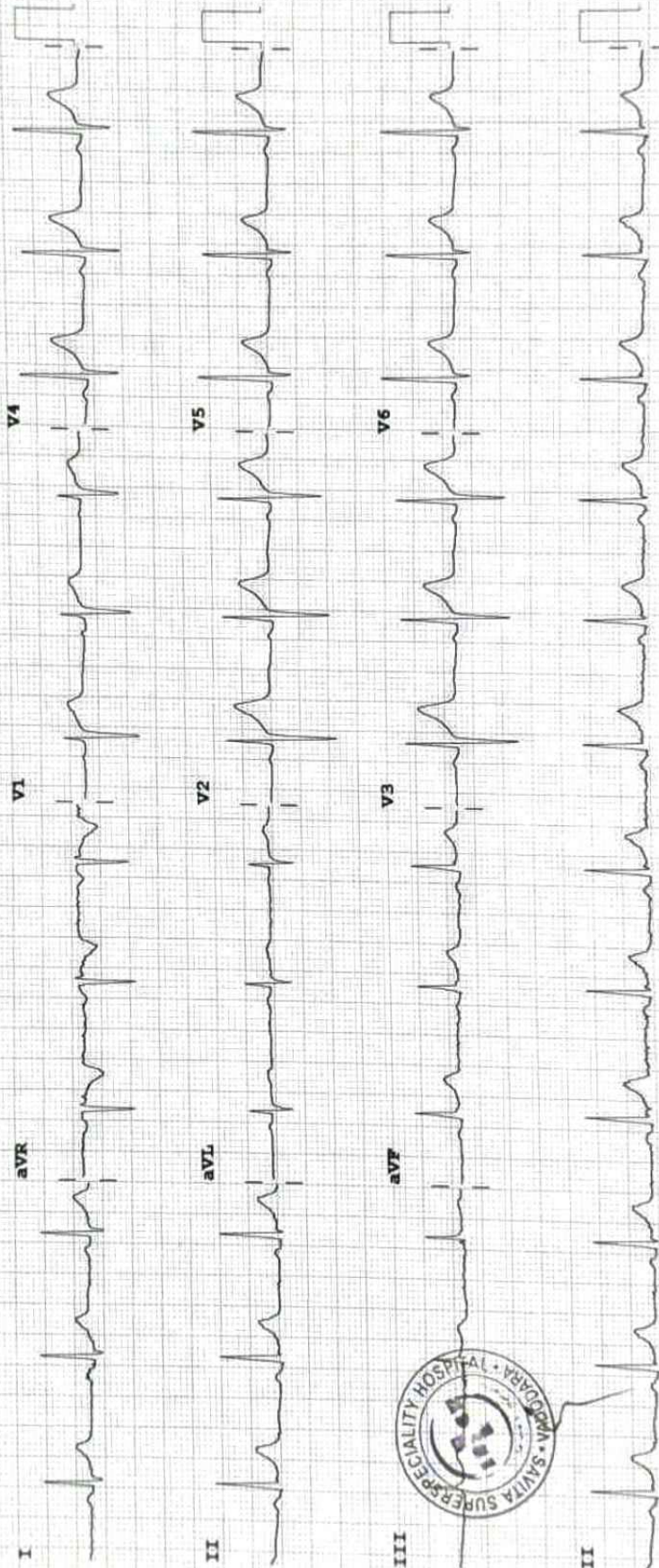
Rate 74

PR 128
QRS 80
QT 348
QTc 386

--AXIS--

P 38
QRS 56
T 44

12 Lead; Standard Placement



Device:

Speed: 25 mm/sec

Limb: 10 mm/mV

Chest: 10.0 mm/mV

F 50~ 0.50-150 Hz W

PH09

P?



Savita

Superspeciality Hospital
(A Unit of Solace Healthcare Pvt. Ltd.)

Parivar Char Rasta, Waghodia-Dabhoi Ring Road, Vadodara-390019

0265-2578844 / 2578849 | mh@savitahospital.com | savitahospital.com

Saturday, June 25, 2022

KUSHAL BHURIA

33 YEARS/MALE

ULTRASONOGRAPHY OF ABDOMEN AND PELVIS SCREENING

Liver shows normal size (14.7) and bright echogenicity. No mass lesion detected.
PV, CBD and intrahepatic biliary radicals shows no dilatation.

The gall bladder is distended and show normal gall bladder wall thickness. There is no evidence of gallstones.

Spleen appears normal in size and echotexture. No evidence of focal lesion.

Pancreas appears normal in size and echotexture. No focal lesion.

Both kidneys show normal size, position and cortical echogenicity.

Right kidney measures 10.0 X 4.8 cm and Left kidney measures 10.1 X 5.1 cm.

Corticomedullary differentiation is preserved bilaterally.

No calculus or hydronephrosis on either side.

The urinary bladder is distended and appears normal. No evidence of any calculus or mass lesion is noted.

No evidence of Lymphadenopathy or ascites seen.

No e/o dilated bowel loops seen.

CONCLUSION:

FATTY LIVER GRADE - I.


DR SARJAN VASAVA, DMRD





Saturday, June 25, 2022
KAUSHAL BHURIA
33 YEARS/MALE

CHEST X RAY PA VIEW

Both the lung fields appear normal.

Both costophrenic angles appear clear.

Cardiac silhouette appear normal.

Both hila appears normal.

Mediastinum and aorta appear normal.

Bony thorax appears normal.

No evidence of free gas seen under dome of diaphragm.

COMMENTS:

- **NORMAL BOTH LUNG FIELDS.**
- **NORMAL CARDIAC SIZE.**



Dr. Sarjen Vasava
DMRD




Saturday, June 25, 2022
KAUSHAL BHURIA
33 YEARS/MALE

CHEST X RAY PA VIEW

Both the lung fields appear normal.
Both costophrenic angles appear clear.
Cardiac silhouette appear normal.
Both hila appears normal.
Mediastinum and aorta appear normal.
Bony thorax appears normal.
No evidence of free gas seen under dome of diaphragm.

COMMENTS:

- **NORMAL BOTH LUNG FIELDS.**
- **NORMAL CARDIAC SIZE.**



Dr. Sarjen Vasava
DMRD



Bill of Supply (Interim Bill)



Patient ID : 20220602241	Visit No. : OPD20220606314(OPD)
Age/Sex : 33y / M	Bill No. : OPD20220606314
Patient Name : KUSHAL . BHURIA	Bill Date : N/A
Dr. Name : DR HIREN PATEL	Speciality : Intensivist
Referred By : self	Company Name : Mediwheel Health Check Up
SAC : 9993 "Service covered under healthcare services"	GSTIN : 24AAQCS5566G2ZW
Class : Contract	City/Village : sankheda
PAN Card : AAQCS5566G	

Expense Details	Qty	Rate	Gross Amount	Waive	Net Amount
Visit Charge					
25-Jun-2022 Physician First Consultation OPD	1.0	0.00	0.0	0.0	0.00
Ophthalmologist First Consultation OPD	1.0	0.00	0.0	0.0	0.00
Visit Charge (Subtotal)			0.0	0.0	0.00
PATHOLOGY					
25-Jun-2022 CBC, ESR	1.0			0.0	
Urine R/M	1.0			0.0	
STOOL EXAMINATION	1.0			0.0	
Blood Group	1.0			0.0	
TFT (Thyroid Function Test)	1.0			0.0	
Lipid Profile	1.0			0.0	
RENAL FUNCTION TEST	1.0			0.0	
LFT (Liver Function Test)	1.0			0.0	
FBS & PPBS	1.0			0.0	
HBA1C	1.0			0.0	
MediWheel Full Body Health Check-Up(Male Below 40)	1.0	2000.00	2000.0	0.0	2000.00
PATHOLOGY (Subtotal)			2000.0	0.0	2000.00
Radiology					
25-Jun-2022 X-RAY CHEST PA	1.0			0.0	
USG WHOLE ABDOMEN SCREENING	1.0			0.0	
Radiology (Subtotal)			0.0	0.0	0.00

Total Bill Amount	2000.00
Net payable amount	2000.00
Bill Outstanding	2000.00

Received With Thanks From KUSHAL . BHURIA of Rs 0.0 /-
(Rs Zero Only)

Printed By : (GAYATRI)
For , Savita Hospital-Live

