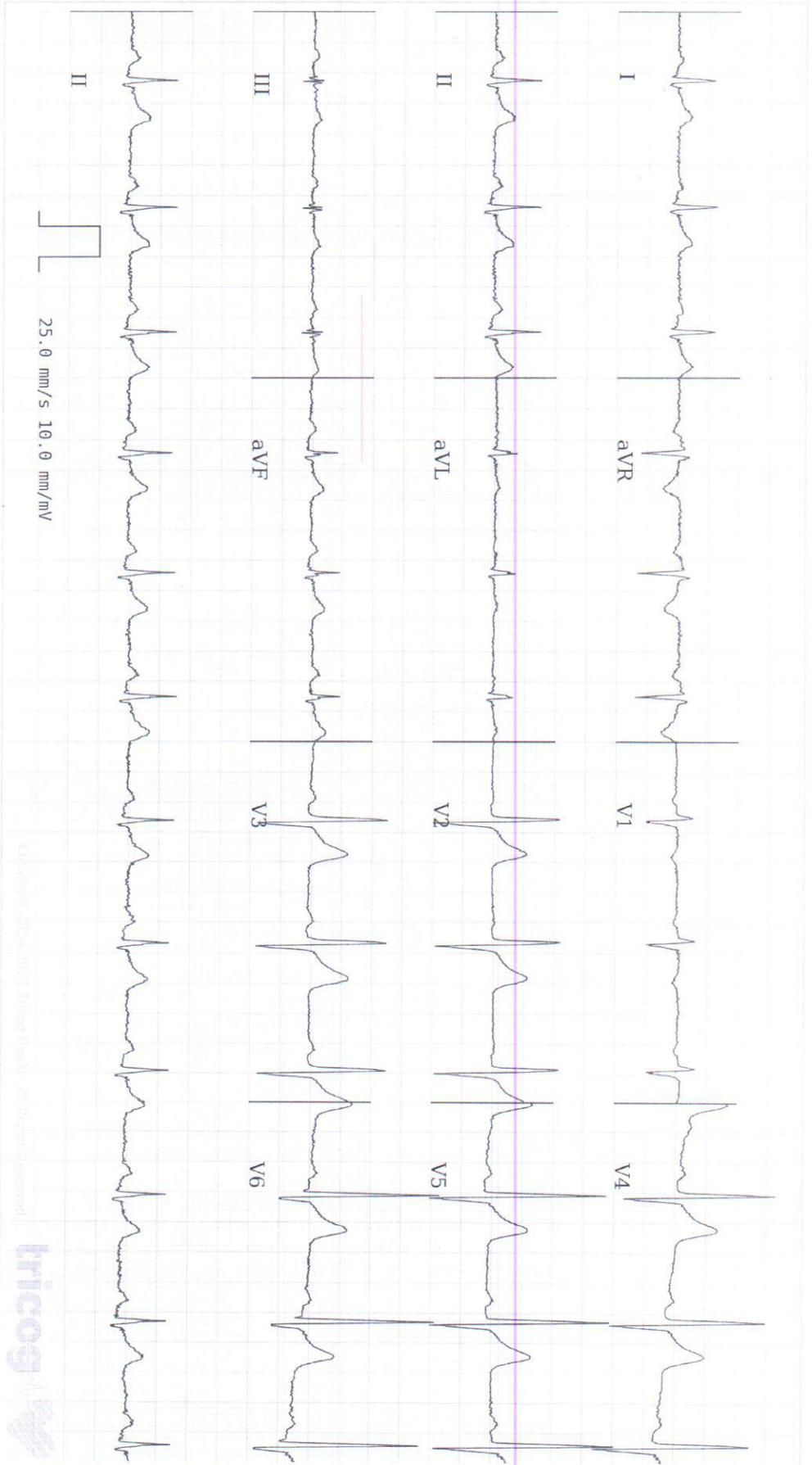

Patient Name: PRASAD SHIVAJIRANE
Patient ID: 2314718145

Date and Time: 27th May 23 10:16 AM



Age 53 5 14
years months days

Gender **Male**

Heart Rate **73bpm**

Patient Vitals

BP: 160/100 mmHg

Weight: 68 kg

Height: 180 cm

Pulse: NA

SpO2: NA

Resp: NA

Others:

Measurements

QRSD: 100ms

QT: 366ms

QTcB: 403ms

PR: 168ms

P-R-T: 57° 35° 50°

ECG Within Normal Limits: Sinus Rhythm. Please correlate clinically.

REPORTED BY

Dr. Gritsh Agarwal
MD Medicine
2002/02/478

Disclaimer: 1) Analysis in this report is based on ECG alone and should be used as an adjunct to clinical history, symptoms, and results of other invasive and non-invasive tests and must be interpreted by a qualified physician. 2) Patient vitals are as entered by the clinician and not derived from the ECG.



Dr. Rafat M Parkar
M.B.S.
Regn. No. 072366

Rafat

Suburban Diagnostics (I) Pvt. Ltd.
6th Floor, Gupta House,
81, S.V. Road, Khar (W), Mumbai - 400 052.
Tel.: 26484805 / 26484807

27/5/2023
Rafat

MAHARASHTRA STATE MOTOR DRIVING LICENCE
THE UNION OF INDIA

DL No: MH02 20090207077
Valid Till: 12-12-2029 (NT)

01-01-2020
FORM 7
RULE 16 (2)

AUTHORISATION TO DRIVE FOLLOWING CLASS
OF VEHICLES THROUGHOUT INDIA

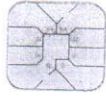


COV
DOI
LMV
03-03-1993
MCWG
26-12-1988

DOB: 13-12-1969 BG: O+

Name: PRASAD SHIVAJI RANE
SDM of SHIVAJI GUNAJI RANE
Add: 5, INDRANEEL, BANDRA RECLAMATION,
BANDRA (W)
GREATER MUMBAI, MUMBAI SUBURBAN
PIN: 400050

Signature & ID of
Issuing Authority: MH02

Signature/Thumb
Impression of Holder



MAHARASHTRA STATE MOTOR DRIVING LICENCE



Use a QR Code Scanner
Application To Scan the Code

CID : 2314718145
Name : Mr Prasad shivajirane
Age / Sex : 53 Years/Male
Ref. Dr :
Reg. Location : Khar West Main Centre

Reg. Date : 27-May-2023
Reported : 29-May-2023 / 2:53

X-RAY CHEST PA VIEW

Both lung fields are clear.

Both costo-phrenic angles are clear.

The cardiac size is within normal limits.

The domes of diaphragm are normal in position and outlines.

The skeleton under review appears normal.

IMPRESSION:

NO SIGNIFICANT ABNORMALITY IS DETECTED.

SUGGEST CLINICAL CORRELATION.

-----End of Report-----

Vishal K. M.

Dr. Vishal Kumar Mulchandani
MD DMRE
REG No : 2006/03/1660
Consultant Radiologist

Click here to view images <http://3.111.232.119/iRISViewer/NeoradViewer?AccessionNo=2023052708572304>

CID : 2314718145
Name : Mr Prasad shivajirane
Age / Sex : 53 Years/Male
Ref. Dr :
Reg. Location : Khar West Main Centre

Reg. Date : 27-May-2023
Reported :

Use a QR Code Scanner
Application To Scan the Code

USG WHOLE ABDOMEN

LIVER:LIVER: Liver is normal in size (measures 13.3 cm). Liver shows normal echotexture. There is no intra-hepatic biliary radical dilatation. No evidence of focal lesion in liver at present scan. The main portal vein and CBD appears normal.

GALL BLADDER: The gall bladder is physiologically distended and appears normal. No evidence of gall stones or mass lesions seen.

CBD:CBD measures 3 mm at porta. Distal CBD is obscured by bowel gases.

PANCREAS: The pancreas is well visualised and appears normal. No evidence of solid or cystic mass lesion.

KIDNEYS: Both the kidneys are normal in size shape and echotexture. No evidence of any calculus, hydronephrosis or mass lesion seen. Right kidney measures 10.5 x 4.6 cm. Left kidney measures 10.7 x 5.9 cm.

SPLEEN: Spleen is normal in size (measures 8.6 cm) and echotexture. No focal lesion is seen. There is no evidence of any lymphadenopathy or ascites.


URINARY BLADDER: The urinary bladder is minimally distended and reveal no intraluminal abnormality.

PROSTATE: Prostate is normal in size. Prostate measures 4.7 x 3.5 x 3.4 cm and prostatic volume is 27.9 cc.

IMPRESSION:

No significant abnormality is detected.

-----End of Report-----


DR. MAHIMA SETHI.
MD RADIOLOGIST
MMC REG NO. 2018126157

Click here to view images <<ImageLink>>

DENTAL CHECK - UP

Name:- Prasad Shivajirane

CID : 2 314718145 Sex / Age : Male / 53

Occupation:- service

Date: 27/05/23

Chief complaints:- Nil

Medical / dental history:- H-T & D.M.

GENERAL EXAMINATION:

1) Extra Oral Examination:

a) TMJ: (M)

b) Facial Symmetry: (M)

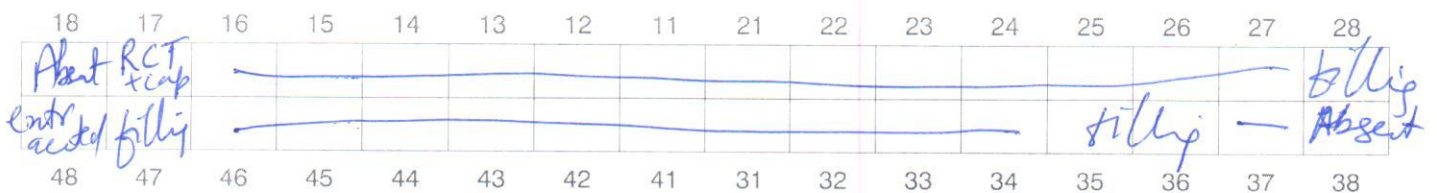
2) Intra Oral Examination:

a) Soft Tissue Examination: (M)

b) Hard Tissue Examination: (M)

c) Calculus: NO

Stains: NO



	Missing	#	Fractured
○	Filled/Restored	RCT	Root Canal Treatment
○	Cavity/Caries	RP	Root Piece

Advised: Nil

Rafat

Provisional Diagnosis:-

Dr. Rafat M Parkar
M.B.B.S.
Regn. No. 072366