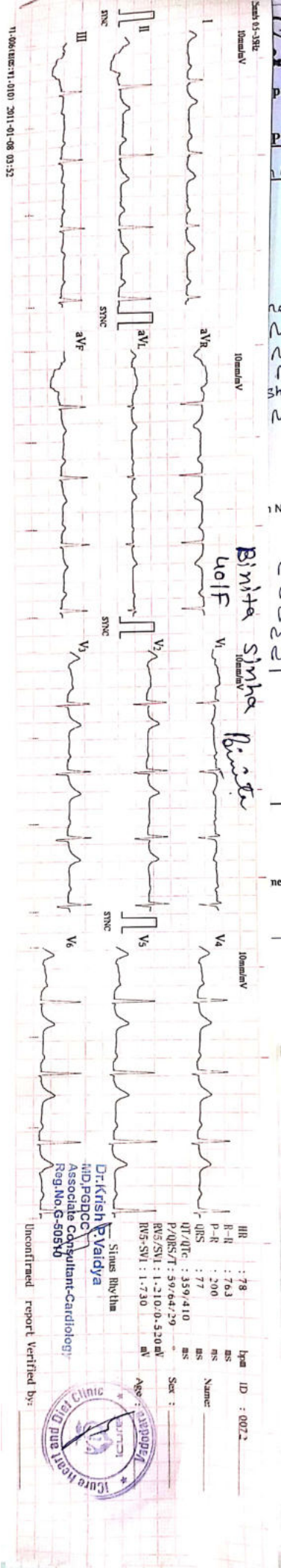


11:06:42 AM 2011-01-08 03:52



Binita Saha  
Wolf  
Binita Saha  
Binita

HR : 78 bpm  
 R-R : 76.3 ms  
 P-R : 200 ms  
 QRS : 77 ms  
 QT/QTc : 359/410 ms  
 P/QRS/T : 59/64/29 ms  
 RM/STV : 1.21/0.0-5.20 mV  
 RM-SVI : 1.730 mV

Dr. Krish P. Vaidya  
 MD, PGDCC  
 Associate Consultant-Cardiologist  
 Reg. No. 9-50510

Unconfirmed report Verified by:



# Heart & General Clinic

Icure Heart & Diet Clinic, 402, Epsilon tower, opp Pasha bhai park, Race course, Vadodara

## :: PERSONAL HEALTH REPORT ::

Biniten sinha		*DATE 8/1/23
		SR. NO. SEX. Female AGE 40 year HEIGHT 161 cm WEIGHT 80 k.g.

### HISTORY

Present History : medicines for thyroid Lethyro + 75 mcg since 3 months  
 Past Illness History : No Diabetes/Hypertension/Tuberculosis/Asthma/Epilepsy  
 Past Occupational History : No  
 Family History : No  
 Personal History : she had c-section in November 2014  
 Addiction : No Tobacco/Gutkha/Smoking/Alcohol

### GENERAL EXAMINATION

T.P.R. : 78/min B.P. : 120/80 mm Hg  
 Pallor/Icterus/Cyanosis/Varicosity/Lymph Nodes/Thyroid/Oedema/NVE/Other :

### SYSTEMIC EXAMINATION

R.S. : MAD  
 C.V.S. : MAD  
 C.N.S. : MAD  
 A.S. : MAD  
 Musculo-skelet System : MAD



E.N.T. Ex. MAD	ACUITY OF VISION		RT EYE		LT EYE	
	Without Glass	DISTANT	6/6	6/6	6/6	6/6
Near		6/6	6/6	6/6	6/6	
Dental Ex. MAD	With Glass	DISTANT	6/6	6/6	6/6	6/6
		Near	6/6	6/6	6/6	6/6
Skin Ex. MAD	COLOUR BLINDNESS MAD					
Psychic Ex. MAD						

### REMARK

### ADVICE

The Worker is FIT/UNFIT for the assigned job.

Dr. Krish P. Vaidya  
 MD, PGCC  
 Associate Consultant-Cardiology  
 Reg. No. G-50510

DR. KRISH VAIDYA

MD G-50510, CIH



भारत सरकार

Government of India



बिनीता सिन्हा

Binita Sinha

जन्म तिथि/DOB: 12/06/1982

महिला/ FEMALE

Mo-9835133065

*Binita Sinha*

6241 1440 7791

VID : 9134 1334 4936 1097

श्री आशार, श्री पहचान





# BARODA DIAGNOSTIC LABORATORY



\* 2 9 3 1 7 \*

Patient's name : Binita Sinha  
Age/Sex : 40 Years/Female  
Referred by : C/o. I Cure Heart & Diet Clinic  
Sample From : LAB  
UHID :

Reg. ID : icure-52-19  
Accession : 29317  
Reg. Date : 08/04/2023  
Collection Time : 08/04/2023 13:23

## COMPLETE BLOOD COUNT

Sample Type: EDTA

Test Name	Result	Units	Biological Reference Interval
<b>Blood Counts</b>			
Haemoglobin :	15.4	Gms%	12.5 - 16.0
Total R.B.C. :	4.92	mill/c.mm	4.2 - 5.4
Total W. B. C. :	6400	/cu mm	4000 - 10500
Platelet Count :	312000	/cu.mm	1,50,000 - 4,50,000
<b>Differential Count</b>			
Neutrophils :	60	%	40 - 70
Lymphocytes :	35	%	20 - 40
Eosinophils :	02	%	1 - 4
Monocytes :	03	%	2 - 6
Basophils :	00	%	0 - 01
<b>Blood Indices</b>			
P. C. V :	44.0	%	37 - 47
M. C. V. :	89.4	fl	78 - 100
M.C.H :	<u>31.3</u>	pg	27 - 31
M. C. H. C :	35.0	%	32 - 36
R.D.W :	<u>15.0</u>	%	11.5 - 14.0

### E.S.R.( Westergren Method )

After one hour : 08 mm 3 - 12



*Dr Harsh Pandya*  
(MD)  
Consultant Pathologist  
Reg. No.: G-32582

*Dr. Priya Kriplani*  
(MD)  
Consultant Pathologist  
Reg. No.: G-46004

302, Trivia Complex, Natubhai Circle, Race Course, Vadodara. ☎ : +91 88660 09950 / 74050 09950 ✉ : bdl95950@gmail.com

Laboratory results serve as an aid to diagnosis & should be interpreted in relation to clinical findings. Please refer back to laboratory in case of any discrepancy.



# BARODA DIAGNOSTIC LABORATORY



Patient's name : Binita Sinha  
Age/Sex : 40 Years/Female  
Referred by : C/o. I Cure Heart & Diet Clinic  
Sample From : LAB  
UHID :

Reg. ID : icure-52-19  
Accession : 29317  
Reg. Date : 08/04/2023  
Collection Time : 08/04/2023 13:23

## RENAL FUNCTION TEST

Test Name	Result	Units	Biological Reference Interval
Urea :	19	mg/dl	10 - 50
Bun (Calculated) :	8.9	mg/dl	0 - 18
Creatinine :	0.73	mg/dl	0.4 - 1.5
Uricacid :	5.21	mg/dl	3.4 - 7.0
BUN CREAT RATIO :			10:1 - 20:1

Done on Fully automated biochemistry analyser - COBAS C 111

Dr. Niti Adhwaryu  
M.D. Pathology  
Reg. No. G-34888

Dr. Priya Kriplani  
M.D. Pathology  
Reg. No. G-46004

LAB

LAB USE ONLY (Entered by :AP Enter Date/Time:08/04/2023 2:00:00 PM) (Verify by :OP1 Verify Date/Time:08/04/2023 2:50:00 PM)

BARODA DIAGNOSTIC LABORATORY



**Dr Harsh Pandya**  
(MD)  
Consultant Pathologist  
Reg. No.: G-32582

**Dr. Priya Kriplani**  
(MD)  
Consultant Pathologist  
Reg. No.: G-46004

302, Trivia Complex, Natubhai Circle, Race Course, Vadodara. ☎ : +91 88660 09950 / 74050 09950 ✉ : bdl95950@gmail.com

Laboratory results serve as an aid to diagnosis & should be interpreted in relation to clinical findings. Please refer back to laboratory in case of any discrepancy.



Scanned with OKEN Scanner



# BARODA DIAGNOSTIC LABORATORY



\* 2 9 3 1 7 \*

Patient's name : Binita Sinha  
Age/Sex : 40 Years/Female  
Referred by : C/o. I Cure Heart & Diet Clinic  
Sample From : LAB  
UHID :

Reg. ID : icure-52-19  
Accession : 29317  
Reg. Date : 08/04/2023  
Collection Time : 08/04/2023 13:23

## LIVER FUNCTION TEST

Sample Type: Serum

Test Name	Result	Units	Biological Reference Interval
S.G.P.T (ALT) :	12	U/L	0 - 40
S.G.O.T (AST) :	17	U/L	0 - 37
ALK.PHOSPHATASE :	79	U/L	35 - 105
G.G.T :	23	U/L	8 - 78
<b><u>Bilirubin</u></b>			
Total :	<b>0.19</b>	mg/dl	0.2 - 1.0
Direct :	0.12	mg/dl	0 - 0.6
Indirect :	0.07	mg/dl	0 - 0.5
<b><u>Serum Proteins</u></b>			
Total Protein :	6.83	gms/dl	6.4 - 8.3
Albumin :	<b>3.72</b>	gms/dl	3.8 - 4.4
Globulins :	3.11	gms/dl	2.3 - 3.5
A/G Ratio :	1.2		0.9 - 2.9


Done on Fully automated biochemistry analyser - COBAS C 111

Dr. Niti Adhwaryu  
M.D. Pathology  
Reg. No. G-34888

Dr. Priya Kriplani  
M.D. Pathology  
Reg. No. G-46004

LAB

LAB USE ONLY (Entered by :AP Enter Date/Time 08/04/2023 2:00:00 PM) 30 Verify by :OP1 Verify Date/Time: 08/04/2023 2:50:00 PM (MD)



**Dr Harsh Pandya**

**Dr. Priya Kriplani**

Consultant Pathologist

Consultant Pathologist

Reg. No.: G-32582

Reg. No.: G-46004

302, Trivia Complex, Natubhai Circle, Race Course, Vadodara. ☎: +91 88660 09950 / 74050 09950 ✉: bdl95950@gmail.com

Laboratory results serve as an aid to diagnosis & should be interpreted in relation to clinical findings. Please refer back to laboratory in case of any discrepancy.



Scanned with OKEN Scanner



# BARODA DIAGNOSTIC LABORATORY



\* 2 9 3 1 7 \*

Patient's name : Binita Sinha  
Age/Sex : 40 Years/Female  
Referred by : C/o. I Cure Heart & Diet Clinic  
Sample From : LAB  
UHID :

Reg. ID : icure-52-19  
Accession : 29317  
Reg. Date : 08/04/2023  
Collection Time : 08/04/2023 13:23

## LIPID PROFILE

Sample Type: Serum

Test Name	Result	Units	Biological Reference Interval
Cholesterol :	159	mg/dl	0 - 200
Triglyceride :	134	mg/dL	0 - 150
HDL - Cholesterol :	42	mg/dL	35 - 65
LDL - Cholesterol :	90	mg/dL	0 - 130
VLDL - Cholesterol :	26.8	mg/dL	0 - 30
Total Cholesterol/HDL Ratio :	3.79		1 - 6
LDL / HDL Cholesterol Ratio :	2.15		0 - 3.5

Done on Fully automated biochemistry analyser - COBAS C 111

Dr. Priya Kriplani  
M.D. Pathology.  
Reg. No. G-46004

Dr. Niti Adhwaryu  
M.D. Pathology  
Reg. No. G-34888

LAB

LAB USE ONLY (Entered by :AP Enter Date/Time:08/04/2023 1:59:00 PM) (Verify by :OP1 Verify Date/Time:08/04/2023 2:50:00 PM)



**Dr Harsh Pandya**  
(MD)  
Consultant Pathologist  
Reg. No.: G-32582

**Dr. Priya Kriplani**  
(MD)  
Consultant Pathologist  
Reg. No.: G-46004

302, Trivia Complex, Natubhai Circle, Race Course, Vadodara. ☎ +91 88660 09950 / 74050 09950 ✉ bdl95950@gmail.com

Laboratory results serve as an aid to diagnosis & should be interpreted in relation to clinical findings. Please refer back to laboratory in case of any discrepancy.



Scanned with OKEN Scanner



# BARODA DIAGNOSTIC LABORATORY



Patient's name : Binita Sinha  
Age/Sex : 40 Years/Female  
Referred by : C/o. I Cure Heart & Diet Clinic  
Sample From : Received from I cure Heart & Diet Clinic  
UHID :

Reg. ID : icure-48-19  
Accession : 29313  
Reg. Date : 08/04/2023  
Collection Time : 08/04/2023 13:20

## HbA1C REPORT

Sample Type: EDTA

Test Name	Result	Units	Biological Reference Interval
HbA1C :	5.90	%	Excellent control: 4.2-6.2 Good Control : 6.3-7.2 Fair Control : 7.3-8.2 Poor Control : >8.3
Mean Blood Glucose levels : of last 03months	122.63	mg/dl	

### NOTE

\*As per the new 2009 update of American Diabetes Association regarding HbA1C & Mean Blood Glucose relationship.

This test is used to monitor diabetic patients compliance with the therapeutic regimen and long term blood glucose control. It's level is proportional to both the average blood glucose concentration and the life span of the red blood cells (RBC) in circulation. HbA1c values are free of day to day glucose fluctuations and are unaffected by exercise or recent food intake.

Dr. Niti Adhwaryu  
M.D. Pathology  
Reg. No. G-34888

Dr. Priya Kriplani  
M.D. Pathology  
Reg. No. G-46004

Received from I cure Heart & Diet Clinic  
LAB USE ONLY (Entered by :OP1 Enter Date/Time:08/04/2023 3:54:00 PM) (Verify by :OP1 Verify Date/Time:08/04/2023 3:54:00 PM)



**Dr Harsh Pandya**  
(MD)  
Consultant Pathologist  
Reg. No.: G-32582

**Dr. Priya Kriplani**  
(MD)  
Consultant Pathologist  
Reg. No.: G-46004

302, Trivia Complex, Natubhai Circle, Race Course, Vadodara. ☎ : +91 88660 09950 / 74050 09950 ✉ : bdi95950@gmail.com

Laboratory results serve as an aid to diagnosis & should be interpreted in relation to clinical findings. Please refer back to laboratory in case of any discrepancy.



Scanned with OKEN Scanner





# BARODA DIAGNOSTIC LABORATORY



Patient's name : Binita Sinha  
Age/Sex : 40 Years/Female  
Referred by : C/o. I Cure Heart & Diet Clinic  
Sample From : Received from I cure Heart & Diet Clinic  
UHID :

Reg. ID : icure-48-19  
Accession : 29313  
Reg. Date : 08/04/2023  
Collection Time : 08/04/2023 13:20

## THYROID FUNCTION

Sample Type: Serum

Test Name	Result	Units	Biological Reference Interval
TOTAL T3 :	1.433	ng/ml	0.84 - 2.0
TOTAL T4 :	6.730	ug/dl	5.1 - 14.0
TSH :	0.825	mIU/L	0.25 - 5.0

Method : CLIA

Dr. Niti Adhwaryu  
M.D. Pathology  
Reg. No. G-34888

Dr. Priya Kriplani  
M.D. Pathology.  
Reg. No. G-46004

Received from I cure Heart & Diet Clinic  
LAB USE ONLY (Entered by :OP1 Enter Date/Time:08/04/2023 3:55:00 PM) (Verify by :OP1 Verify Date/Time:08/04/2023 3:55:00 PM)

BARODA DIAGNOSTIC LABORATORY



**Dr Harsh Pandya**  
(MD)  
Consultant Pathologist  
Reg. No.: G-32582

**Dr. Priya Kriplani**  
(MD)  
Consultant Pathologist  
Reg. No.: G-46004

302, Trivia Complex, Natubhai Circle, Race Course, Vadodara. ☎: +91 88660 09950 / 74050 09950 ✉: bdi95950@gmail.com

Laboratory results serve as an aid to diagnosis & should be interpreted in relation to clinical findings. Please refer back to laboratory in case of any discrepancy.



Scanned with OKEN Scanner

  
**Heart & General Clinic**

iCure Heart& Diet Clinic, 402, Epsil on tower, opp Pasha bhai park, Race course, Vadodara

**Name** : BINITA SINHA  
**Ref By** : ICURE HEART & DIET CLINIC

**Age/Sex** : 40 Yrs./F  
**Date** : 08/04/2023  
**Report ID.** : 3

**HAEMOGRAM PROFILE**

<u>TEST</u>	<u>RESULT</u>
Blood Group	: * AB *
Rh Factor (Anti D.)	: * POSITIVE *

**BIOCHEMISTRY**

**FASTING (FBS)**

Blood Glucose : 92.0 mg/dL 70.00 - 110.00 mg/dL

**POST-PRANDIAL**

Blood Glucose : 107.0 mg/dL 80 - 140 mg/dL

*Done By Fully Auto Analyzer MIURA, A-1004*

END OF REPORT



icure™  
Heart & General Clinic

iCure Heart& Diet Clinic, 402, Epsil on tower, opp Pasha bhai park, Race course, Vadodara

Name : BINITA SINHA  
Ref By : ICURE HEART & DIET CLINIC

Age/Sex : 40 Yrs./F  
Date : 08/04/2023  
Report ID. : 3

**EXAMINATION OF URINE**

<u>TEST</u>	<u>RESULT</u>	<u>UNIT</u>
Sample	: FASTING	
<b><u>PHYSICAL EXAMINATION</u></b>		
Quantity	: 10	mL
Colour	: COLOURLESS	
Transperancy	: CLEAR	
Specific Gravity	: 1.003	
Reaction	: ACIDIC	
Deposits	: ABSENT	
<b><u>CHEMICAL EXAMINATION</u></b>		
Albumin	: NIL	
Sugar	: NIL	
Acetone	: ABSENT	
Bile Salts	: ABSENT	
Bile Pigments	: ABSENT	
Urobilinogen	: NORMAL : ~ < 1.0 mg/dL	
Occult Blood	: ABSENT	
Nitrate	: ABSENT	
<b><u>MICROSCOPIC EXAMINATION</u></b>		
Pus Cells	: 0-1 / hpf	
RBC	: NIL	
Epithelial Cells	: NIL	
Crystals	: NIL	
Amorphous Phosphate	: NIL	
Cast	: NIL	



END OF REPORT

  
**Heart & General Clinic**

icure Heart & Diet Clinic, 402 Epsilon Tower, opp. Pashabhai Park, Nr. Natubhai Circle, Race course, Vadodara, 390007

<b>Name: Binita Sinha</b>	<b>Date: 08/04/2023</b>
<b>Age / Sex : 40yrs/ Female</b>	

**PAP SMEAR CYTOLOGY (CONVENTIONAL)**

**Specimen**

Pap smear for cytology (conventional)

**Gross Description**

Received one unstained smear.  
Smear-1 [PAP]

**Microscopic Description**

See below in diagnosis.

**Diagnosis**

**Satisfactory for evaluation.**  
**PAP Smears is negative for intra-epithelial lesion or malignancy.**  
**Trichomonas or monilia are not seen.**  
**Endo cervical cells are not seen.**

PAP test is a screening test for cervical cancer with inherent false negative results.

----- End Of Report -----

All cytology tests reveal only cytological characteristics of individual cells and not architectural details which are very important in morphological diagnosis. All cytology methods have their own inherent limitations of false positive and false negative results due to variabilities related to sample collection methods, smear preparation, fixation and staining along with microscopic interpretation, hence whenever required tissue diagnosis and/or immunohistochemistry study after correlation with clinical and radiological findings should be done for further confirmation before any definitive medical or surgical treatment.



**Dr. Krish P. Vaidya**  
MD, PGDCC  
Associate Consultant - Cardiology  
Reg. No. G-50510

**Dr. Krish P Vaidya**  
MD G-50510



  
**Heart & General Clinic**

**2D Echocardiography & Color Doppler Report**

iCure Hear care, 402, Epsilon tower, opp Pasha bhai park, Race course, Vadodara

**Patient Name:** Mrs Binita Sinha

**Dates:** 08 / 04 / 2023

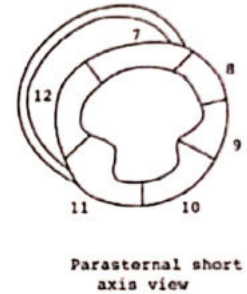
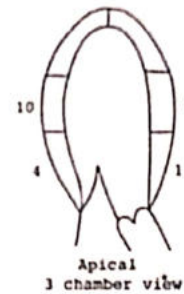
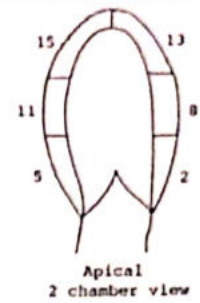
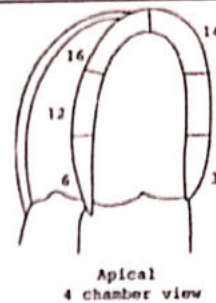
**Age Gender:** female - 40 Years

**M. Mode Study:**

LA	35	IVS	09	PWD	09
AO	28	LVDs	24	LVDD	46

**Doppler Study:**

Mitral Valve	E: 0.72 A: 0.98
Aortic Valve	Normal
Tricuspid Valve	Normal
Pulmonary Valve	Normal



**Conclusion:**

- Normal LV Systolic function
- LVEF: 58 % ,No RWMA
- Cardiac Chambers: Normal
- Diastolic function: Grade I LVDD
- TR: No PAH: No RVSP: 17mmhg
- No Ms , No MR
- No AR , No AS
- ASD/VSD/PDA/Co-A : No
- No Clots or vegetations found
- IVC: 10mm size with Normally collapsive

Dr.Krish P.Vaidya  
 MD,PGDCC  
 Associate Consultant-Cardiology  
 Reg.No.G-50510

**Dr. Krish P Vaidya:**  
 Consultant Cardiologist, Diabetologis  
 & General Physician

**Note:**

Normal 2D echo report does not rule out cardiac diseases  
 this report shall not be used for Medico legal purposes,  
 Clinical Correlation advisable.

  
**Heart & General Clinic**

NAME : Mrs Binita Sinha	AGE : 40 Y/F	DATE : 08/04/2023
-------------------------	--------------	-------------------

**ULTRASONOGRAPHY OF WHOLE ABDOMEN**  
(Screening Only)

**Liver** is normal in size and echotexture and shows normal parenchymal reflectivity. No focal lesion is seen. Hepatic veins appear normal. There is no evidence of any dilated intra hepatic biliary radicals.

**Portal Vein** appears normal in diameter.

**Common Bile Duct** is of normal diameter.

**Gallbladder** is physiologically distended with normal wall thickness. There is no evidence of gallstones. No evidence of peri-cholecystic fluid or probe tenderness.

**Pancreas** is normal in size and shows homogenous reflectivity. There is no evidence of any calcification or ductal dilatation.

**Spleen** is normal size and shows a homogenous echotexture. There is no evidence of any focal lesion.

**Both Kidneys** are normal in position and size. They show normal cortical reflectivity and cortico-medullary distinction. Right kidney measures 94 x36mm. Left kidney measures 89x40mm. There is no evidence of renal calculi, hydronephrosis or mass seen.

**Bladder** is well distended and shows normal wall thickness. No evidence of intra-luminal mass or calculi.

**Uterus** appears normal in size. Uterine myometrial echotexture is homogeneous. No focal lesion is seen. CET measures 5mm.

**Both Ovaries** appears normal in size & reflectivity. No evidence of any adnexal mass.

There is no evidence of ascites.

No evidence of any gross bowel mass seen.

No evidence of any aorto-caval or mesenteric root lymphadenopathy.

No mass or collection in right iliac fossa.

**CONCLUSION:** No sonographic abnormality is seen.

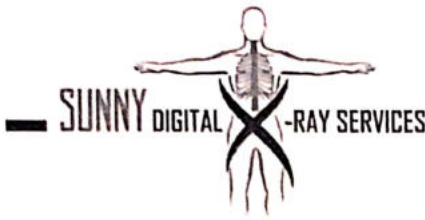

*Mehul Prajapati*

**DR. MEHUL PRAJAPATI**  
**CONSULTANT RADIOLOGIST**

 iCure™  
**Heart & General Clinic**

iCure Heart& Diet Clinic, 402, Epsil on tower, opp Pasha bhai park, Race course, Vadodara



Sunny K. Machhi  
+91 87585 30074  
+91 83205 61551  
sunnydigitalxray@yahoo.com

<b>NAME</b>	BINITA SHARMA	<b>AGE/SEX</b>	FEMALE
<b>REF BY</b>	I CURE HEART & DIET CLINIC	<b>DATE</b>	08-04-2023

**X-RAY CHEST PA VIEW (PORTABLE)**

**FINDING**

BOTH LUNGS FIELDS ARE NORMAL .

REMAINING LUNG FIELDS ARE NORMAL.

BOTH COSTOPHRENIC RECESS ARE CLEAR.

CARDIAC SIZE WITHIN NORMAL LIMITS.

MEDIASTINUM AND BONY THORACIC CAGE REVEAL NO ABNORMALITY.

**IMPRESSION :NORMAL LUNGS HEART AND MEDIASTUINUM..**

**DR.HIMANI VIRAPARA**  
**Regn. No: G.28771**  
**M.D. [Radiodiagnosis]**  
**(CONSULTANT RADIOLOGIST)**

