

CID#	: 2208524799	SID#	: 177401455451
Name	: MRS.KANIKA MANDAL	Registered	: 26-Mar-2022 / 08:45
Age / Gender	: 35 Years/Female	Collected	: 26-Mar-2022 / 08:45
Consulting Dr.	: -	Reported	: 27-Mar-2022 / 08:22
Reg.Location	: Kandivali East (Main Centre)	Printed	: 28-Mar-2022 / 10:20

PHYSICAL EXAMINATION REPORT

History and Complaints:

Adenomyosis 4 yrs.

EXAMINATION FINDINGS:

Height (cms):	157 cms	Weight (kg):	91 kgs
Temp (0c):	Afebrile	Skin:	Normal
Blood Pressure (mm/hg):	130/80	Nails:	Normal
Pulse:	72/min	Lymph Node:	Not palpable

Systems

Cardiovascular: Normal
Respiratory: Normal
Genitourinary: Normal
GI System: Normal
CNS: Normal

IMPRESSION:

*↑ Triglycerides
USA - Hepatomegaly & fatty liver
- Bulky uterus & features of
Adenomyosis*

ADVICE:

*Low fatty diet
Reduce weight
Gynaec opinion*

CID#	: 2208524799	SID#	: 177401455451
Name	: MRS.KANIKA MANDAL	Registered	: 26-Mar-2022 / 08:45
Age / Gender	: 35 Years/Female	Collected	: 26-Mar-2022 / 08:45
Consulting Dr.	: -	Reported	: 27-Mar-2022 / 08:22
Reg.Location	: Kandivali East (Main Centre)	Printed	: 28-Mar-2022 / 10:20

CHIEF COMPLAINTS:


- | | |
|--|--------------------------------|
| 1) Hypertension: | No |
| 2) IHD | No |
| 3) Arrhythmia | No |
| 4) Diabetes Mellitus | No |
| 5) Tuberculosis | No |
| 6) Asthama | No |
| 7) Pulmonary Disease | No |
| 8) Thyroid/ Endocrine disorders | No |
| 9) Nervous disorders | No |
| 10) GI system | No |
| 11) Genital urinary disorder | No |
| 12) Rheumatic joint diseases or symptoms | No |
| 13) Blood disease or disorder | No |
| 14) Cancer/lump growth/cyst | No |
| 15) Congenital disease | No |
| 16) Surgeries | Lap appendectomy 2018,D&C 2017 |
| 17) Musculoskeletal System | No |

PERSONAL HISTORY:

- | | |
|---------------|-------|
| 1) Alcohol | No |
| 2) Smoking | No |
| 3) Diet | Mixed |
| 4) Medication | Yes |

*** End Of Report ***

SUBURBAN DIAGNOSTICS (INDIA) PVT. LTD.
Row House No. 3, Aangan,
Thakur Village, Kandivali (east),
Mumbai - 400101.
Tel : 61700000


Dr. Jagruti Dhale
MBBS
Consultant Physician
Reg. No. 69548

ADDRESS: 2nd Floor, Aston, Sundervan Complex, Above Mercedes Showroom, Andheri West - 400053

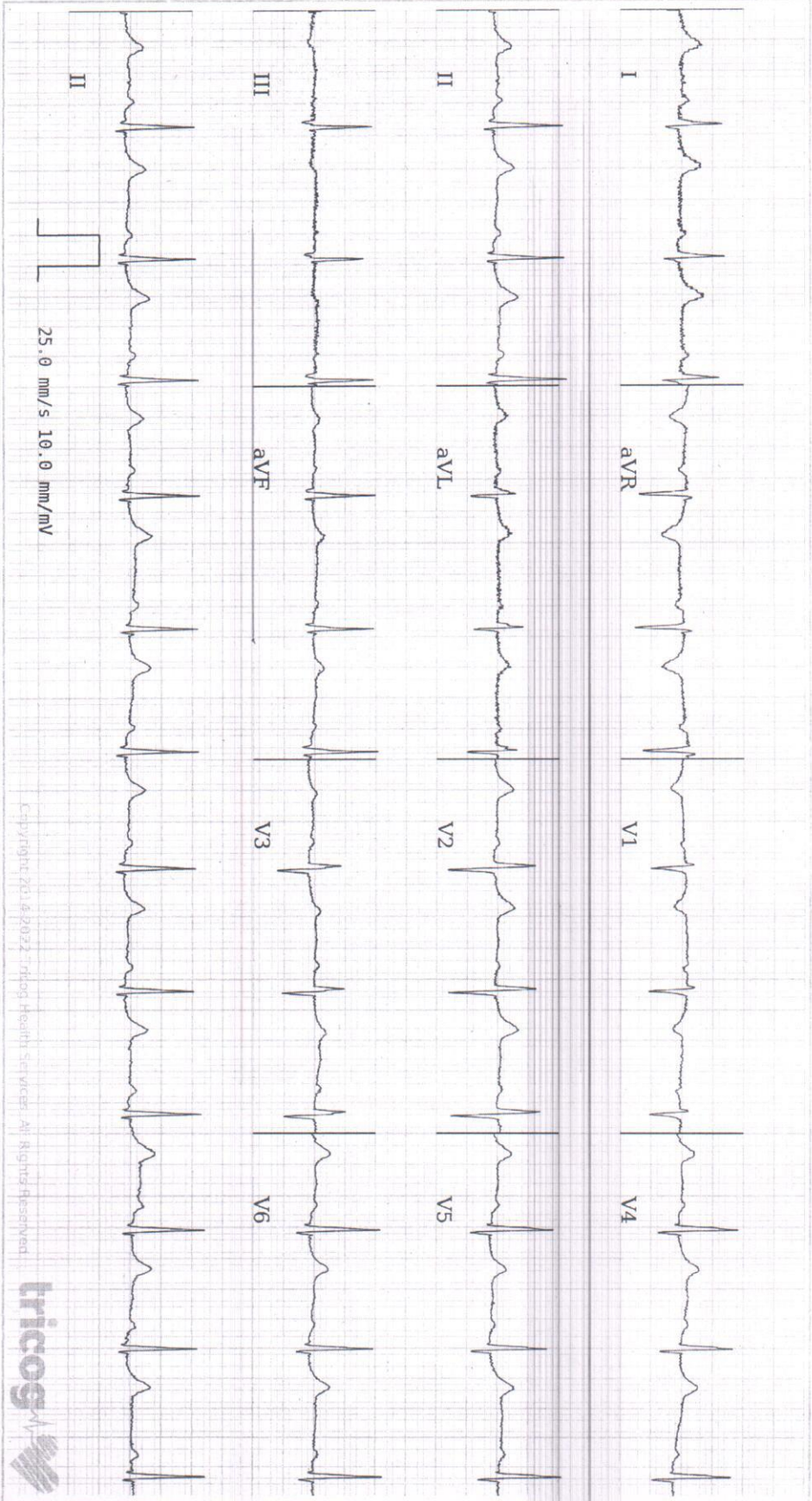
HEALTHLINE - MUMBAI: 022-6170-0000 | OTHER CITIES: 1800-266-4343

Page:2 of 2

For Feedback - customerservice@suburbandiagnosics.com | www.suburbandiagnosics.com

Patient Name: **KANIKA MANDAL**
Patient ID: **2208524799**

Date and Time: **26th Mar 22 9:28 AM**



Age **35** 10 13
years months days

Gender **Female**

Heart Rate **76bpm**

Patient Vitals

BP: **130/80 mmHg**

Weight: **91 kg**

Height: **157 cm**

Pulse: **NA**

Spo2: **NA**

Resp: **NA**

Others: _____

Measurements

OSRD: **74ms**

QT: **390ms**

QTc: **438ms**

PR: **154ms**

P-R-T: **25° 70° 31°**

Copyright 2016-2022 Tricog Health Services. All Rights Reserved.



ECG Within Normal Limits: Sinus Rhythm, Normal Axis. Please correlate clinically.

SUBURBAN DIAGNOSTICS (INDIA) PVT. LTD.

Row House No. 3, Aangan,
Thekur Vhaga, Kandivali (east),
Mumbai - 400101.
Tel : 61700000

REPORTED BY

DR AKHIL PARULEKAR
MBBS, MD. MEDICINE, DNB Cardiology
Cardiologist
2012082483

Disclaimer: 1) Analysis in this report is based on ECG alone and should be used as an adjunct to clinical history, symptoms, and results of other invasive and non-invasive tests and must be interpreted by a qualified physician. 2) Patient vital are as entered by the clinician and not derived from the ECG

DENTAL CHECK - UP

Name:- *Kanika Mandal*

CID : *2265524799* Sex / Age : *F / 35*

Occupation:-

Date: *26/3/2022*

Chief complaints:- *Grossly decayed teeth, Cavities*

Medical / dental history:- *Extraction done*

GENERAL EXAMINATION:

1) Extra Oral Examination:

- a) TMJ: *Normal movements*
- b) Facial Symmetry: *Bilateral symmetrical*

2) Intra Oral Examination:

- a) Soft Tissue Examination: *Normal*
- b) Hard Tissue Examination: *etc Root pieces*
- c) Calculus: *+*
- Stains: *+*

18	17	16	15	14	13	12	11	21	22	23	24	25	26	27	28
48	47	46	45	44	43	42	41	31	32	33	34	35	36	37	38

	Missing	#	Fractured
○	Filled/Restored	RCT	Root Canal Treatment
○	Cavity/Caries	RP	Root Piece

Advised: *a) Extraction & replacement etc*

Provisional Diagnosis:-

Pulp Necrosis etc -

SUBURBAN DIAGNOSTICS (INDIA) PVT. LTD.
Row House No. 3, Aangan,
Thakur Village, Kandivali (east),
Mumbai - 400101
Tel : 61700000

DR. BHUMIK PATEL
(B.D.S) A - 28378
Dr Bhumik Patel

ADDRESS: 2nd Floor, Aston, Sundervan Complex, Above Mercedes Showroom, Andheri West - 400053

HEALTHLINE - MUMBAI: 022-6170-0000 | OTHER CITIES: 1800-266-4343

For Feedback - customerservice@suburbandiagnosics.com | www.suburbandiagnosics.com

Date:- 26/3/22

CID:
2208524799

Name:- Mrs. Kamika Mandar

Sex/Age: F/35

EYE CHECK UP

Chief complaints: Routine ch-up

Systemic Diseases: NO H/O S/I

Past history: NO H/O Ocular surgery

Unaided Vision: 6/6blwr 6/6blwr

Aided Vision:

Refraction: COMB NORMAL

	(Right Eye)				(Left Eye)			
	Sph	Cyl	Axis	Vn	Sph	Cyl	Axis	Vn
Distance	±	0.50	80°	6/6	±	0.50	100	6/6
Near				N/6				N/6

Colour Vision: Normal / Abnormal

Remark: Vm within normal limit

Kajal H.
KAJAL NAGRECHA
 OPTOMETRIST

SUBURBAN DIAGNOSTICS (INDIA) PVT. LTD.
 Row House No. 3, Aangan,
 Thakur Village, Kandivali (east),
 Mumbai - 400101.
 Tel : 61700000

ADDRESS: 2nd Floor, Aston, Sundervan Complex, Above Mercedes Showroom, Andheri West - 400053

HEALTHLINE - MUMBAI: 022-6170-0000 | OTHER CITIES: 1800-266-4343

For Feedback - customerservice@suburbandiagnosics.com | www.suburbandiagnosics.com

CID#	: 2208524799	SID#	: 177401455451
Name	: MRS.KANIKA MANDAL	Registered	: 26-Mar-2022 / 08:45
Age / Gender	: 35 Years/Female	Collected	: 26-Mar-2022 / 08:45
Consulting Dr.	: -	Reported	: 26-Mar-2022 / 12:44
Reg.Location	: Kandivali East (Main Centre)	Printed	: 26-Mar-2022 / 15:30

X-RAY CHEST PA VIEW

The lung fields are clear with no parenchymal lesion.

The cardiothoracic ratio is maintained and the cardiac outline is normal

The domes of the diaphragm are normal.

The cardio and costophrenic angles are clear.

Bony thorax is normal.

IMPRESSION:

No significant abnormality detected.

*** End Of Report ***

Khilji F.R.A

Dr.Faizur Khilji
MBBS, Consultant Radiologist

ADDRESS: 2nd Floor, Aston, Sundervan Complex, Above Mercedes Showroom, Andheri West - 400053

HEALTHLINE - MUMBAI: 022-6170-0000 | **OTHER CITIES:** 1800-266-4343

For Feedback - customerservice@suburbandiagnosics.com | **www.suburbandiagnosics.com**

CID#	: 2208524799	SID#	: 177401455451
Name	: MRS.KANIKA MANDAL	Registered	: 26-Mar-2022 / 08:45
Age / Gender	: 35 Years/Female	Collected	: 26-Mar-2022 / 08:45
Consulting Dr.	: -	Reported	: 26-Mar-2022 / 10:35
Reg.Location	: Kandivali East (Main Centre)	Printed	: 26-Mar-2022 / 10:38

USG WHOLE ABDOMEN

LIVER :

The liver is enlarged in size (18.8 cm), normal in shape and smooth margins. It shows bright parenchymal echo pattern. The intra hepatic biliary and portal radical appear normal. No evidence of any intra hepatic cystic or solid lesion seen. The main portal vein measures 12 mm and CBD appears measures 2.9 mm .The main portal vein and CBD appears normal.

GALL BLADDER :

The gall bladder is physiologically distended and appears normal.No evidence of gall stones or mass lesions seen

PANCREAS :

The pancreas well visualised and appears normal.No evidence of solid or cystic mass lesion.

KIDNEYS :

Right kidney measures 11.1 x 4.9 cm. Left kidney measures 11.1 x 4.5 cm.
Both the kidneys are normal in size shape and echotexture.
No evidence of any calculus,hydronephrosis or mass lesion seen.

SPLEEN :

The spleen is normal in size (11.3 cm) and echotexture.No evidence of focal lesion is noted.
There is no evidence of any lymphadenopathy or ascites.

URINARY BLADDER :

The urinary bladder is well distended and reveal no intraluminal abnormality.

UTERUS :

The uterus is anteverted, Bulky in size and measures 10.2 x 6.8 x 6.2 cm in size. (volume 228 cc).
It shows heterogenous echotexture with mild loss of endometrial-myometrial junction with few myometrial calcifications ----suggestive of Adenomyosis.
The endometrial thickness is 6.2 mm.

ADDRESS: 2nd Floor, Aston, Sundervan Complex, Above Mercedes Showroom, Andheri West - 400053

HEALTHLINE - MUMBAI: 022-6170-0000 | OTHER CITIES: 1800-266-4343

For Feedback - customerservice@suburbandiagnosics.com | www.suburbandiagnosics.com

CID#	: 2208524799	SID#	: 177401455451
Name	: MRS.KANIKA MANDAL	Registered	: 26-Mar-2022 / 08:45
Age / Gender	: 35 Years/Female	Collected	: 26-Mar-2022 / 08:45
Consulting Dr.	: -	Reported	: 26-Mar-2022 / 10:35
Reg.Location	: Kandivali East (Main Centre)	Printed	: 26-Mar-2022 / 10:38


OVARIES :

Both the ovaries are well visualised and appears normal.
There is no evidence of any ovarian or adnexal mass seen.
Right ovary = 3.4 x 1.7 cm. Left ovary = 3.0 x 1.9 cm.

IMPRESSION :

Hepatomegaly with Grade II fatty liver.
BULKY UTERUS WITH FEATURES OF ADENOMYOSIS.

*** End Of Report ***



Dr.Akash Chhari
M.B.B.S, MD.
RADIOLOGIST

ADDRESS: 2nd Floor, Aston, Sundervan Complex, Above Mercedes Showroom, Andheri West - 400053

HEALTHLINE - MUMBAI: 022-6170-0000 | **OTHER CITIES:** 1800-266-4343

For Feedback - customerservice@suburbandiagnosics.com | www.suburbandiagnosics.com