


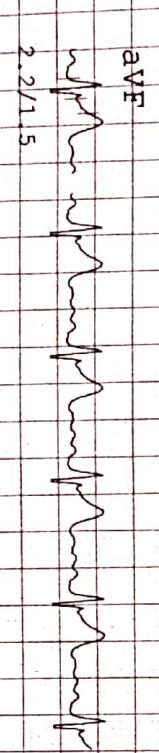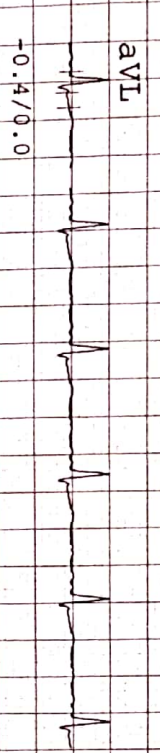



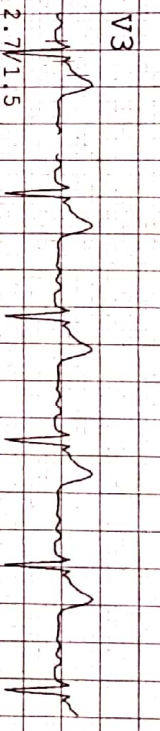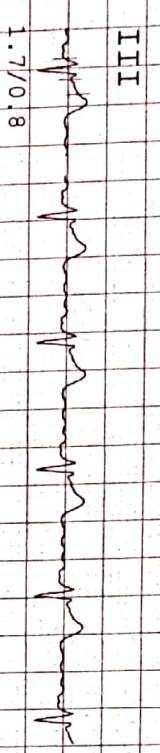


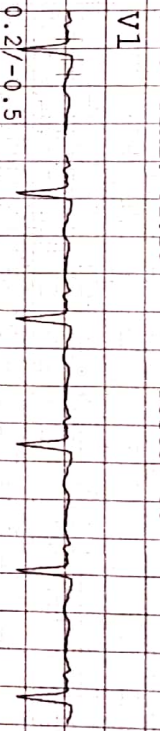
# SHREEJI MULTISPECIALITY HOSPITAL

112/F TOWER A, SENATE SQUARE, VUDA CHOKDI, GOTRI

NAME : VENKATA RAMANA BONPADDEDI.10  
AGE/GENDER : 47/MALE  
DATE/TIME : 30/Aug/2021(09:51)

BP:124/ 88 mmHg  
HR: 89 bpm  
PROTOCOL : Bruce  
STAGE NAME: Recovery  
STAGE TIME: 01:18

ST @ 10 mm/mV  
STL in mm  
STs in mm/sec



II





# SHREEJI MULTISPECIALITY HOSPITAL

112/F TOWER A, SENATE

SQUARE, VUDA CHOKDI, GORRI

Linked Median Report

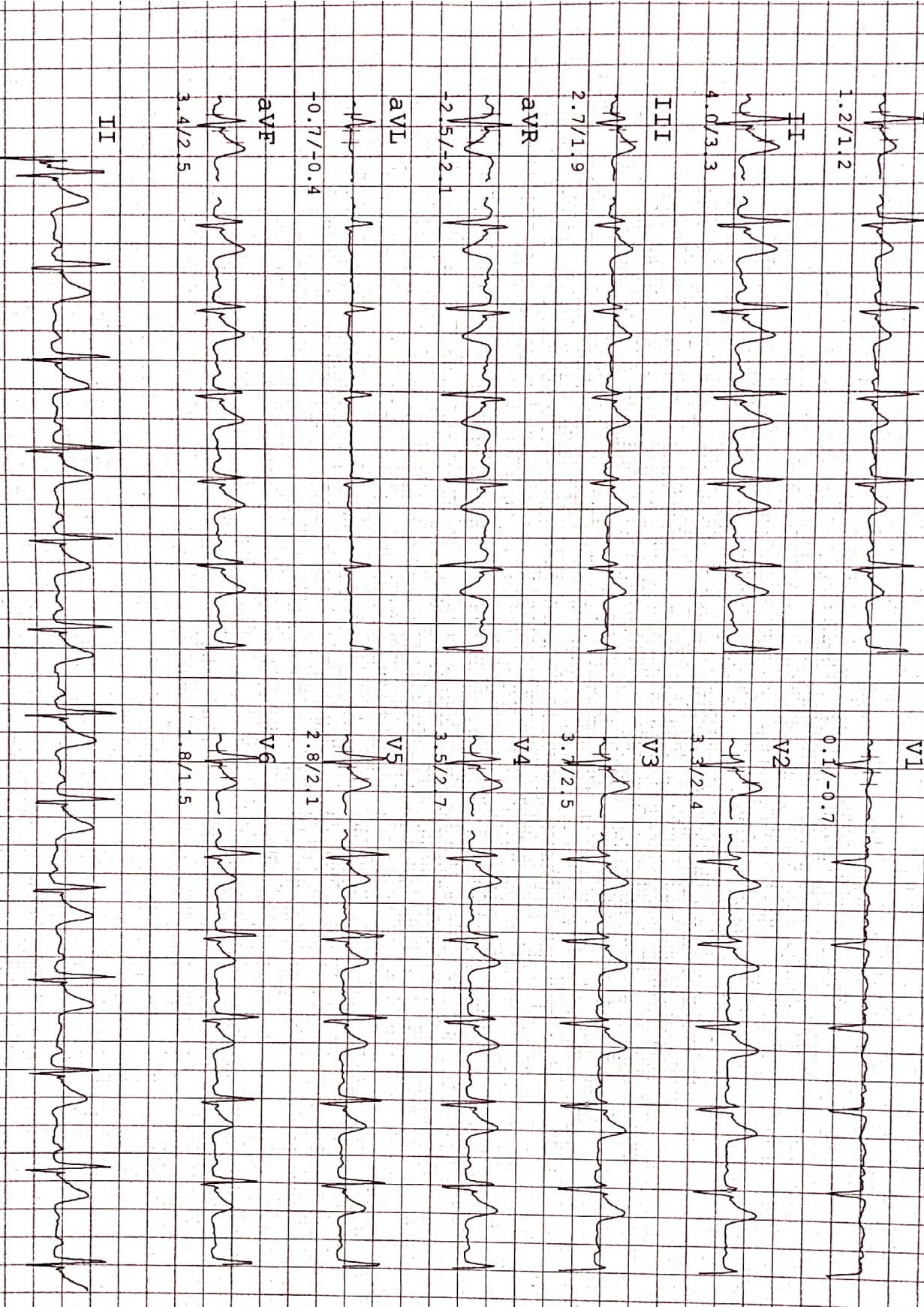NAME : VENKATA RAMANA BONDADID: 10  
 AGE/GENDER : 47/MALE  
 DATE/TIME : 30/Aug/2021(09:51)

BP: 130/ 90 mmHg  
 HR: 102 bpm

PROTOCOL : Bruce  
 STAGE NAME: Recovery  
 STAGE TIME: 01:00

PostJ 80

ST @ 10 mm/mV  
 STL in mm  
 STS in mm/sec





# SHREEJI MULTISPECIALITY HOSPITAL


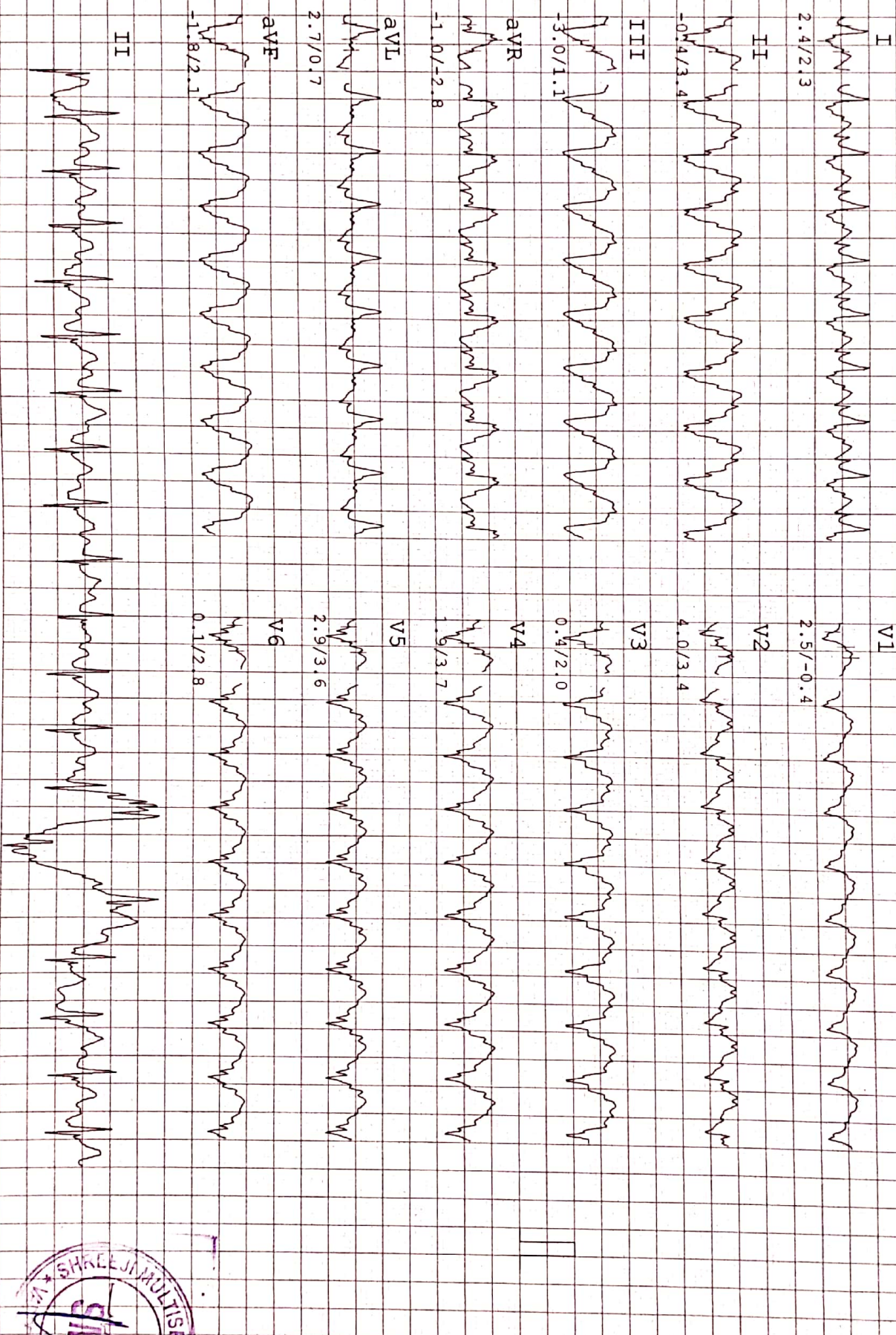
112/F TOWER A, SENATE SQUARE, VUDA CHOKDI, GOTRI  
Linked Median Report

NAME : VENKATA RAMANA BONDADDE: 10  
AGE/GENDER: 47/MALE BP: 150/100 mmHg  
DATE/TIME : 30/Aug/2021 (09:51) HR: 152 bpm

PROTOCOL : Bruce  
STAGE NAME: Peak  
STAGE TIME: 00:06

PostJ 80

ST @ 10 mm/mV  
STL in mm  
STS in mm/sec




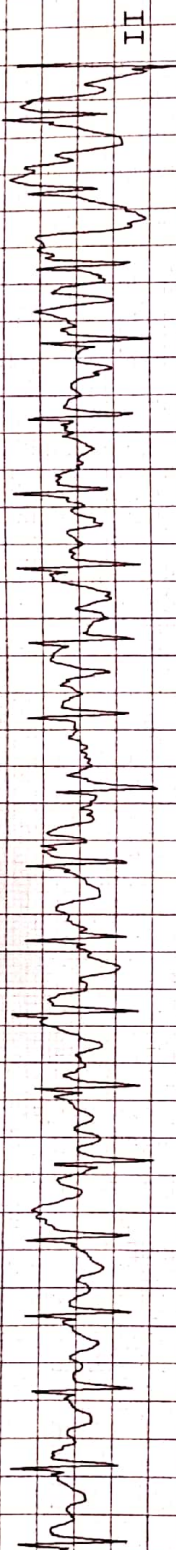
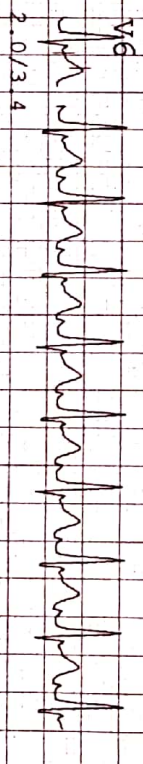
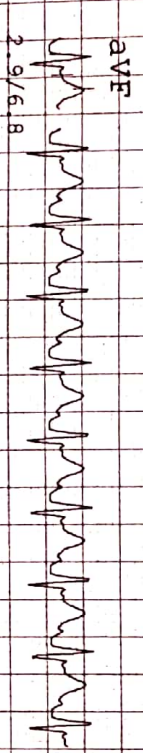
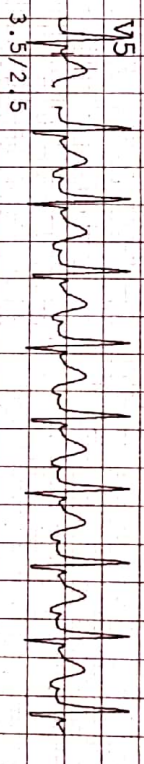
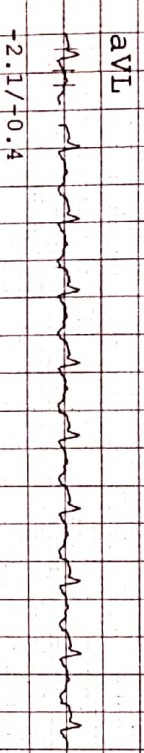
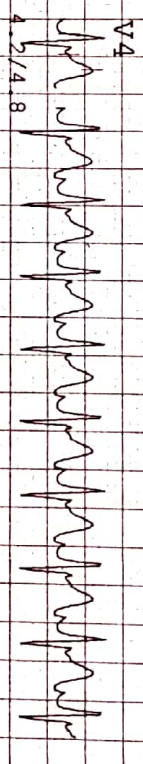

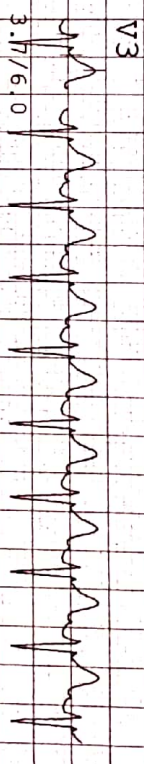
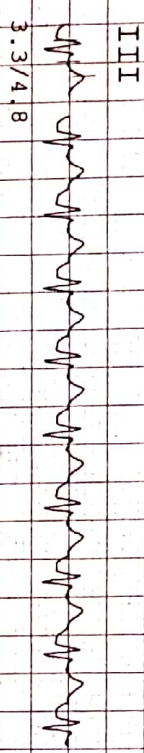
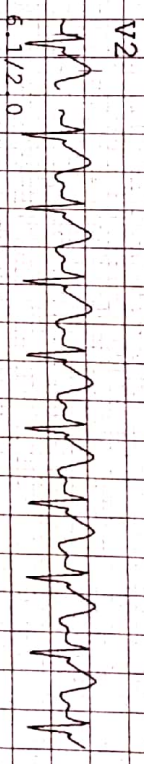
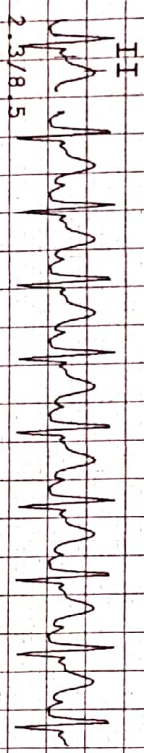
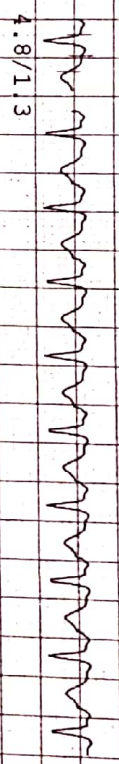
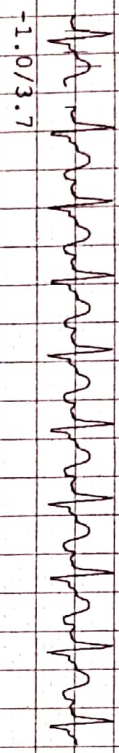


# SHREETI MULTISPECIALITY HOSPITAL

NAME : VENKATA RAMANA BONDADHD: 10  
 AGE/GENDER : 47/MALE  
 DATE/TIME : 30/Aug/2021(09:51) HR:155 bpm

112/F TOWER A, SENATE SQUARE, VUDA CHOKDI, GOTRI  
 PROTOCOL : Bruce  
 STAGE NAME: Exer : 4/7  
 STAGE TIME: 00:12 PostJ 80

ST 0.10 mm/mV  
 STL in mm  
 STS in mm/sec



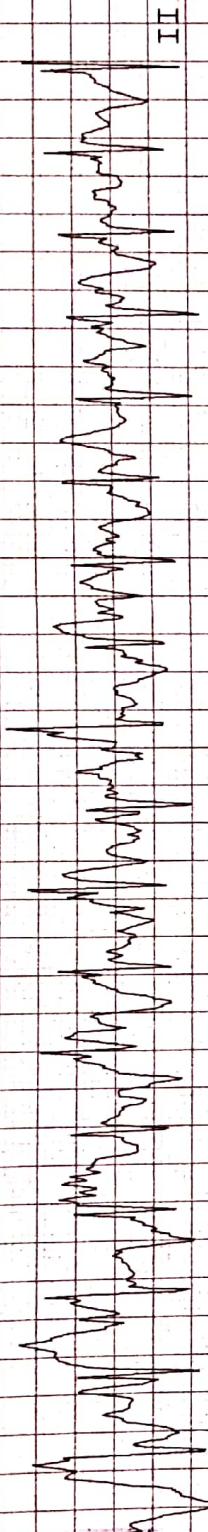
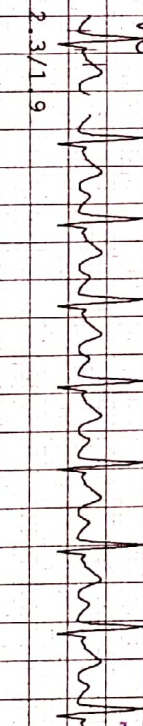
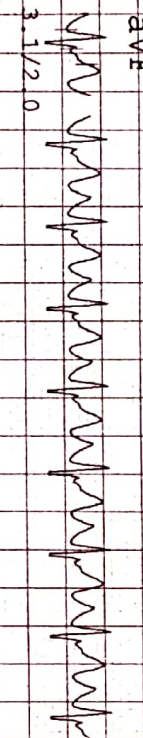
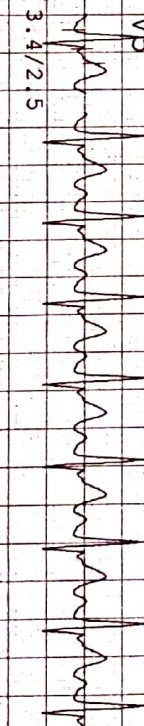
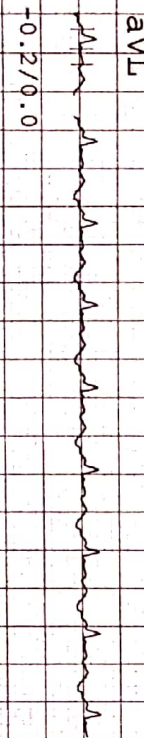
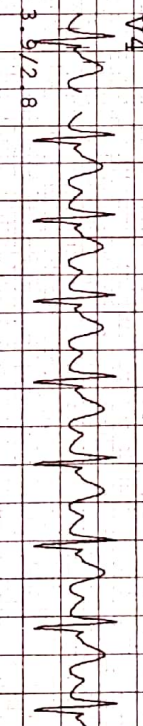

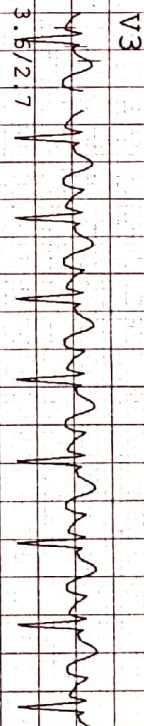
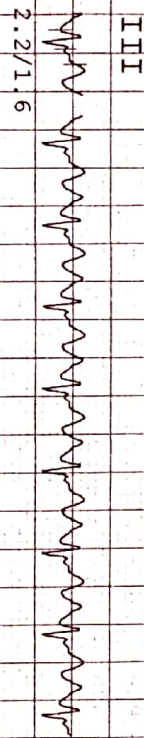
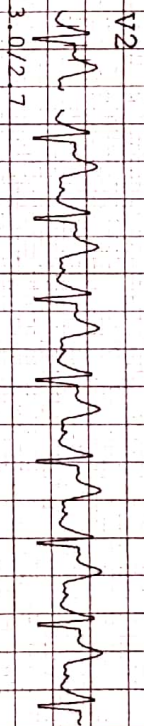
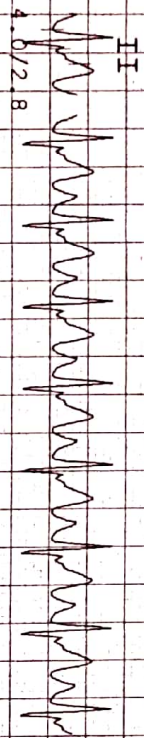




# SHREEJI MULTISPECIALITY HOSPITAL

NAME : VENKATA RAMANA BONDADDE: 10  
AGE/GENDER : 47/MALE  
DATE/TIME : 30/Aug/2021(09:51) HR:138 bpm

112/F TOWER A, SENATE SQUARE, VUDA CHOKDI, GOTRI  
BP:150/100 mmHg  
PROTOCOL : Bruce  
STAGE NAME: Exer : 3/7  
STAGE TIME: 03:00

Linked Median Report  
PostJ 80  
ST @ 10 mm/mV  
STL in mm  
STS in mm/sec





# SHREEJI MULTISPECIALITY HOSPITAL

112/F TOWER A, SENATE SQUARE, VUDA CHOKDI, GOTRI

PROTOCOL : Bruce Linked Median Report

STAGE NAME: Exer : 1/7

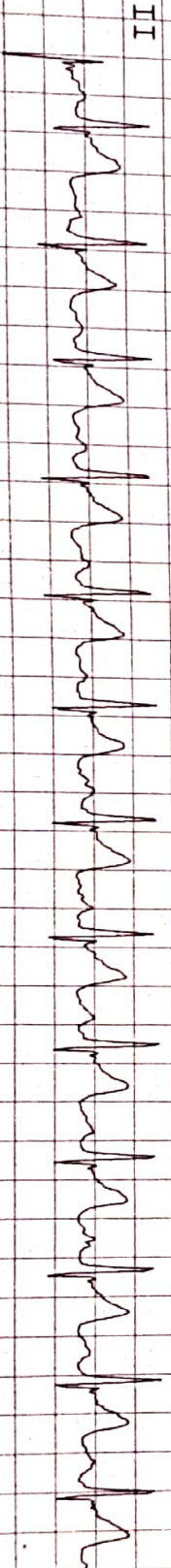

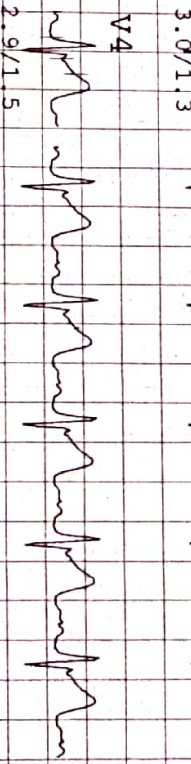
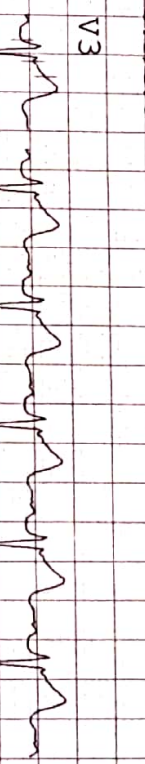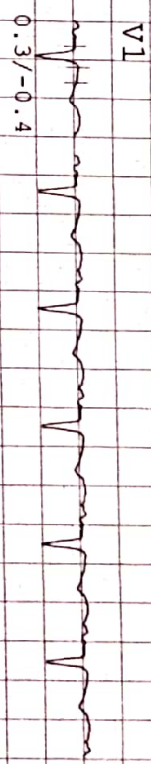
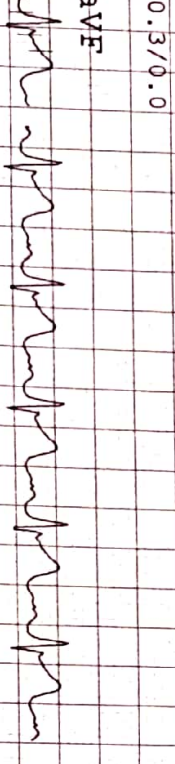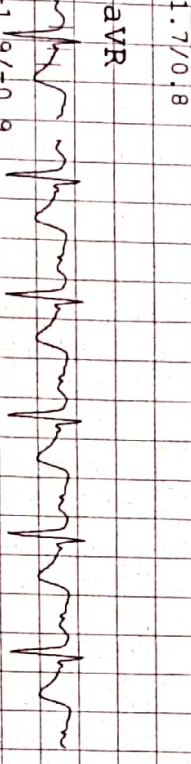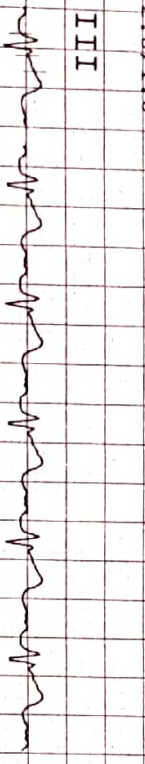

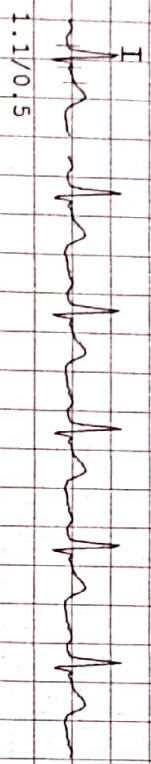
STAGE TIME: 03:00 PostJ 80

ST 0 10 mm/mV

STL in mm

STS in mm/sec

NAME : VENKATA RAMANA BONDADID: 10  
AGE/GENDER: 47/MALE BP: 130/ 84 mmHg  
DATE/TIME : 30/Aug/2021(09:51) HR: 99 bpm




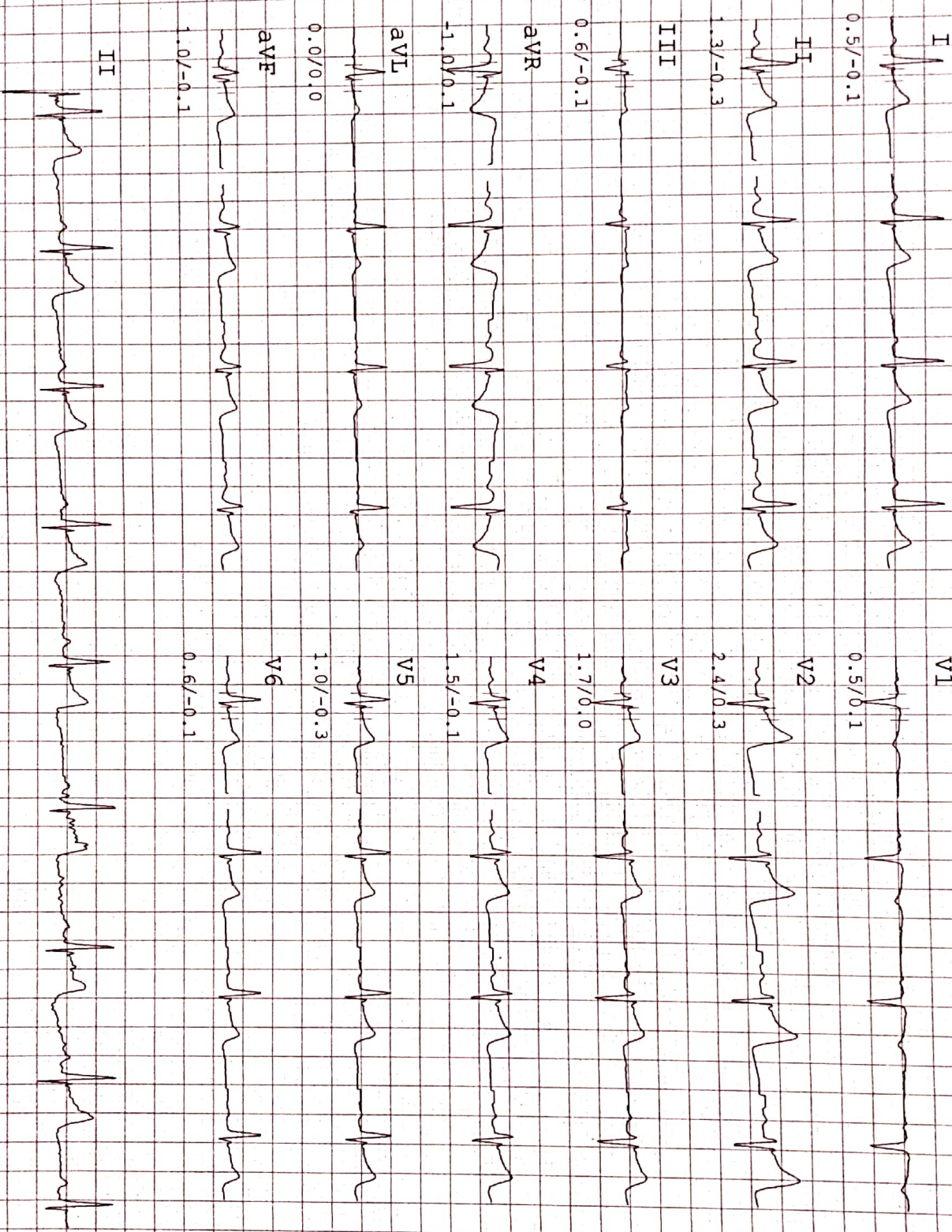


# SHREEJI MULTISPECIALITY HOSPITAL

NAME : VENKATA RAMANA BONDADHD: 10  
 AGE/GENDER: 47/MALE  
 DATE/TIME : 30/Aug/2021(09:51)

112/F TOWER A, SENATE SQUARE, VUDA CHOKDI, GOTRI  
 BP: 118/ 80 mmHg  
 HR: 61 bpm  
 PROTOCOL : Bruce  
 STAGE NAME: Hypertv  
 STAGE TIME: 00:30

Linked Median Report  
 PostJ 80  
 ST @ 10 mm/mv  
 STL in mm  
 STS in mm/sec





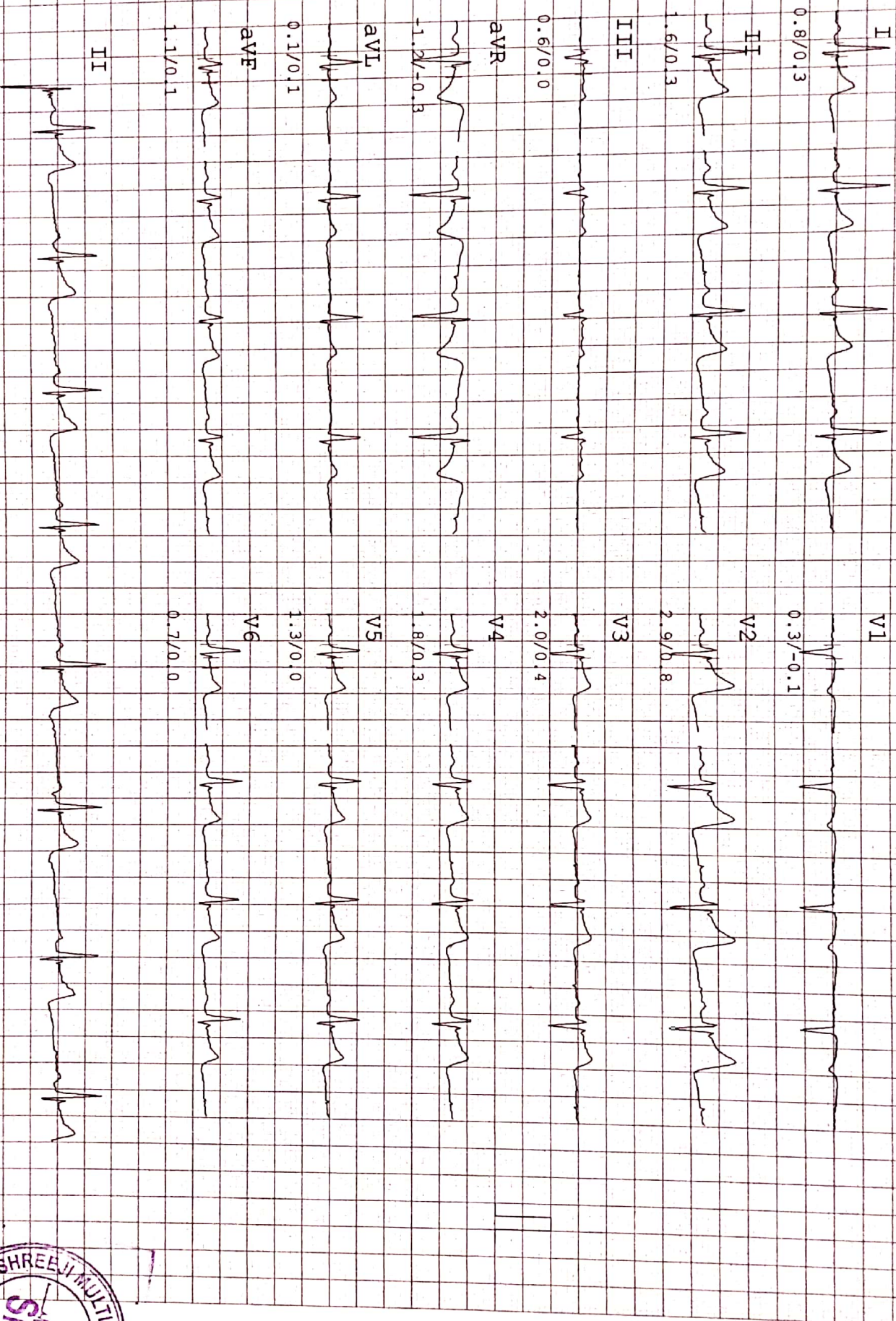
# SHREEJI MULTISPECIALITY HOSPITAL

112/F POWER A, SENATE SQUARE, VUDA CHOKDI, GOTRI

NAME : VENKATA RAMANA BONDADDI: 10  
AGE/GENDER: 47/MALE  
DATE/TIME : 30/Aug/2021(09:51) HR: 67 bpm

PROTOCOL : Bruce  
STAGE NAME: Standing  
STAGE TIME: 00:18  
PostJ 80

ST @ 10 mm/mV  
STL in mm  
STs in mm/sec





# SHREEJI MULTISPECIALITY HOSPITAL

112/F POWER A, SENATE SQUARE, VUDA CHOKDI, GOTRI

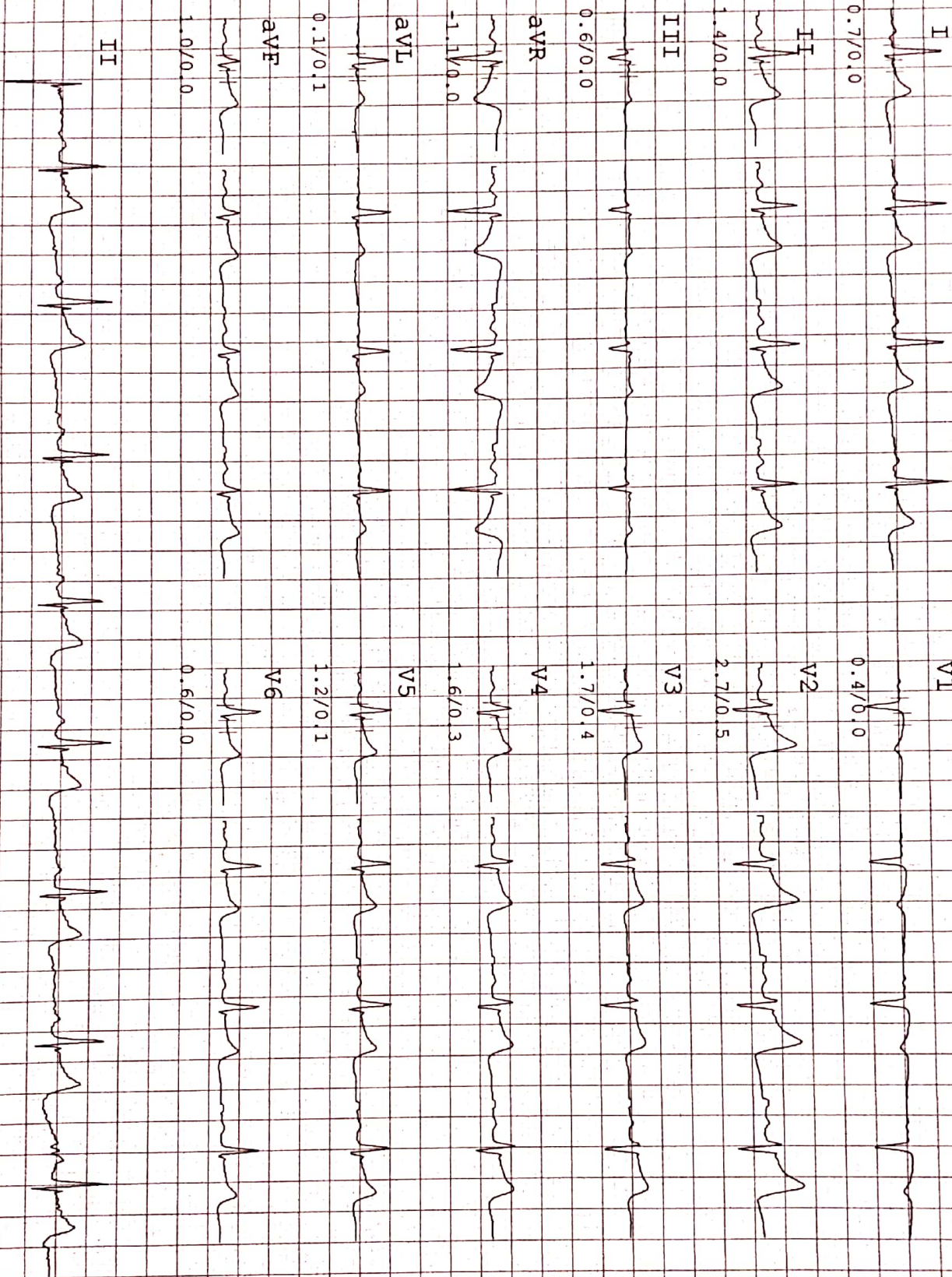
Linked Median Report

NAME : VENKATA RAMANA BONDADHD: 10  
AGE/GENDER: 47/MALE BP: 118/ 80 mmHg  
DATE/TIME : 30/Aug/2021(09:51) HR: 64 bpm

PROTOCOL : Bruce  
STAGE NAME: Supine  
STAGE TIME: 00:30

PostJ 80

ST @ 10 mm/mV  
STL in mm  
STS in mm/sec





# SHREEJI MULTISPECIALITY HOSPITAL

112/F TOWER A, SENATE SQUARE, VUDA CHOKDI, GOTRI

NAME: VENKATA RAMANA BONDADA  
AGE/GENDER: 47 yrs/MALE

ID: 10  
HEIGHT: 158 cm.

PROTOCOL: Bruce  
WEIGHT: 91 Kg.

Summary report  
DATE/TIME: 30-08-2021 09:51

REF. BY:  
SMOKER: Non Smoker

## Test Results

Protocol	: Bruce	Max Work Load	9.52	BMI	: 36
Target HR	: 173(147)bpm	Exer. Time	: 9:12min	Max RPP(1000)	: 22.8
Maximum HR	: 152(88 %) bpm	Recov. Time	: 1:18min	Max BP	: 150/100 mmHg

(1) Reason for termination :  
Target heart rate achieved

(2) Functional Capacity :  
Normal

(3) HR Response to Exercise :  
Appropriate

(4) BP Response to Exercise :  
Normal resting BP - Appropriate response

(5) Overall Impression :  
Normal stress test

(6) Comment :  
Normal ECG

(1) Restraining ECG :  
Normal

(2) Chest Pain :  
None

(3) ST Changes :  
None

(4) Arrhythmias :  
None

(5) History :  
None

(6) Medication :  
, None

**Dr. Krish F. Vaidya**  
MD, PGDD  
Associate Consultant - Cardiology  
Reg. No. G-50510

DR KRISH VAIDYA (MD - G50510)





# SHREEJI MULTISPECIALITY HOSPITAL

112/F TOWER A, SENATE SQUARE, VUDA CHOKDI, GOTRI

NAME: VENKATA RAMANA BONDADA  
AGE/GENDER: 47 yrs/MALE

ID: 10  
HEIGHT: 158 cm.

PROTOCOL: Bruce  
WEIGHT: 91 Kg.

Summary report  
DATE/TIME: 30-08-2021 09:51

REF. BY:  
SMOKER: Non Smoker

Stage	Time Min:Sec	HR bpm	BP mmHg	Speed (mph)/Gr ade (%)	Load METS	RPP 1000	II	V2	V5
Supine	00:30	64	118/80	0.0/0.0	1.0	7.552	1.4/0.0	2.7/0.5	1.2/0.1
Standing	00:18	67	118/80	0.0/0.0	1.0	7.906	1.6/0.3	2.9/0.8	1.3/0.0
HyperV	00:30	61	118/80	0.0/0.0	1.0	7.198	1.3/-0.3	2.4/0.3	1.0/-0.3
Exer : 1/7	03:00	99	130/84	1.7/10.0	4.8	12.87	2.8/1.6	3.1/1.6	2.1/1.1
Exer : 2/7	03:00	114	140/90	2.5/12.0	6.8	15.96	3.2/2.1	3.0/1.9	2.7/1.7
Exer : 3/7	03:00	138	150/100	3.4/14.0	9.3	20.7	4.0/2.8	3.0/2.7	3.4/2.5
Exer : 4/7	00:12	155	150/100	4.2/16.0	9.5	23.25	2.3/8.5	6.1/2.0	3.5/2.5
Peak	09:12	152	150/100	4.2/16.0	9.5	22.8	-0.4/3.4	4.0/3.4	2.9/3.6
Recovery	01:00	102	130/90	0.0/0.0	1.0	13.26	4.0/3.3	3.3/2.4	2.8/2.1
Recovery	01:18	89	124/88	0.0/0.0	1.0	11.036	2.8/1.7	2.7/1.6	1.8/1.1







# Shreeji Multispeciality Hospital

Inspiring better health...

## SHREEJI OCCUPATIONAL CENTRE SHREEJI PATHOLOGY LABORATORY

112F, Tower-A, Senate Square, Opp. Gangotri Apartment, Vuda Char rasta, Gotri, Vadodara-390021.  
M. : 9157022510, Email : shreejihospital19@yahoo.com, smh31082015@gmail.com

### :: PERSONAL HEALTH REPORT ::

NAME <u>venkatesh Boradade</u>		DATE <u>30/08/21</u>
		SR. NO. <u>Cardiology</u>
		SEX. <u>M</u>
		AGE <u>37</u>
		HEIGHT <u>161 cm</u>
		WEIGHT <u>79 kg</u>

### HISTORY

Present History : NAD

Past Illness History : Diabetes/Hypertension/Tuberculosis/Asthma/Epilepsy NO

Past Occupational History : NO

Family History : NO

Personal History : NO

Addiction : Tobacco/Gutkha/Smoking/Alcohol NO

### GENERAL EXAMINATION

T.P.R. : 108/40 B.P. : 124/86 mm Hg

Pallor/Icterus/Cyanosis/Varicosity/Lymph Nodes/Thyroid/Oedema/NVE/Other : NO

### SYSTEMIC EXAMINATION

R.S. : NAD

C.V.S. : NAD

C.N.S. : NAD

A.S. : NAD

Musculo-skelet System : NAD

E.N.T. Ex.	ACUITY OF VISION			RT EYE	LT EYE
	Without Glass	DISTANT	6/ 6	6/ 6	
		Near	6/ 6	6/ 6	
	With Glass	DISTANT	6/ -	6/ -	
Near		6/ -	6/ -		
Dental Ex.	COLOUR BLINDNESS <u>NO</u>				
Skin Ex.					
Psychic Ex.					

REMARK  
ADVICE

The Worker is FIT/UNFIT for the assigned job.



Dr. Krish P. Vaidya  
MD, PCMC  
Associate Consultant-Cardiology  
Reg.No G-50510

DR. KRISH VAIDYA

MD G-50510, CIH



భారత ప్రభుత్వం  
GOVERNMENT OF INDIA  
బొండాడ వెంకట రమణ  
Bondada Venkata Ramana  
పుట్టిన సంవత్సరం/Year of Birth: 1974  
పురుషుడు / Male  
8562 6032 6205  
ఆధార్ - సామాన్యుని హక్కు







# Shreeji Multispeciality Hospital

Inspiring better health...

SHREEJI OCCUPATIONAL CENTRE SHREEJI PATHOLOGY LABORATORY

112F, Tower-A, Senate Square, Opp. Gangotri Apartment, Vuda Char rasta, Gotri, Vadodara-390021.  
M. : 9157022510, Email : shreejihospital19@yahoo.com, smh31082015@gmail.com

Name : VENKATA BONDADA  
Ref By : DR. SMH

Age/Sex : 47 Yrs./M  
Date : 30/08/2021  
Report ID. : 4

## HAEMOGRAM PROFILE

TEST	RESULT	UNIT	METHOD	REFERENCE INTERVAL
<b>BLOOD COUNTS &amp; INDICES</b>				
Haemoglobin	: 15.10	gm%		13.5 - 17.0 gm%
Total RBC	: 4.80	mill/cmm		4.6 - 6.2 mill/cmm
PCV	: 47.00	%		40 - 54 %
MCV	: <b>97.91</b>	fL		80 - 96 fL
MCH	: <b>31.45</b>	pg		27 - 31 pg
MCHC	: 32.12	%		32 - 36 %
Total WBC	: 5,500	/cmm		4,000 - 11,000/cmm
<b>DIFFERENTIAL LEUCOCYTES COUNT</b>				
Band Cells	: 00	%		00 - 06 %
Neutrophils	: 62	%		55 - 70 %
Lymphocytes	: 32	%		20 - 40 %
Eosinophils	: 03	%		01 - 06 %
Monocytes	: 03	%		02 - 08 %
Basophils	: 00	%		00 - 01 %
<b>ERYTHROCYTES SEDIMENTATION RATE</b>				
ESR After 1st Hour	: 4	mm	Westergren	01 - 07 mm
Blood Group	: " B "			
Rh Factor (Anti D.)	: " POSITIVE "			

(By Fully Automated Cell Counter Sysmex KX - 21, Japan)

END OF REPORT



DR KRISH VAIDYA  
MD, PGDCC  
G-50510





# SHREEJI Multispeciality Hospital

Inspiring better health...

SHREEJI OCCUPATIONAL CENTRE SHREEJI PATHOLOGY LABORATORY

112F, Tower-A, Senate Square, Opp. Gangotri Apartment, Vuda Char rasta, Gotri, Vadodara-390021.  
M. : 9157022510, Email : shreejihospital19@yahoo.com, smh31082015@gmail.com

Name : VENKATA BONDADA  
Ref By : DR. SMH

Age/Sex : 47 Yrs./M  
Date : 30/08/2021  
Report ID. : 4

## BIOCHEMISTRY

TEST	RESULT	UNIT	REFERENCE INTERVAL
Blood Urea Nitrogen - BUN	: 11.00	mg/dL	4.5 - 19.0 mg/dL
Serum Creatinine	: 0.80	mg/dL	0.6 - 1.4 mg/dL
Serum Uric Acid	: 4.40	mg/dL	3.4 - 7.0 mg/dL
<b>SERUM PROTEIN</b>			
Serum Protein Total	: 7.40	g/dL	6.6 - 8.3 g/dL
Albumin	: 5.00	g/dL	3.5 - 5.0 g/dL
Globulin	: 2.40	g/dL	2.3 - 3.5 g/dL
A/G Ratio	: 2.1	: 1	1.5 - 2.5 : 1
Bilirubin - Total	: 0.5	mg/dL	0.00 - 1.00 mg/dL
Bilirubin - Direct	: 0.2	mg/dL	Upto 0.30 mg/dL
Bilirubin - Indirect	: 0.3	mg/dL	0.1 - 1.0 mg/dL
SGPT	: 31.0	IU/L	10 - 40 IU/L
SGOT	: 21.0	IU/L	Upto 40 IU/L
Serum Alkaline Phosphatase	: 114.0	U/L	37 - 147 U/L
<b>FASTING (FBS)</b>			
Blood Glucose	: 105.0	mg/dL	70 - 110 mg/dL
<b>SPECIAL TESTS</b>			
GGT	: 48	U/L	05 - 85 U/L
Gamma Glutamyltransferase			

Done By Fully Auto Analyzer MIURA, A-1004

END OF REPORT



DR KRISH VAIDYA  
MD, PGDCC  
G-50510





# SHREEJI Multispeciality Hospital

Inspiring better health...

SHREEJI OCCUPATIONAL CENTRE SHREEJI PATHOLOGY LABORATORY

112F, Tower-A, Senate Square, Opp. Gangotri Apartment, Vuda Char rasta, Gotri, Vadodara-390021.  
M. : 9157022510, Email : shreejihospital19@yahoo.com, smh31082015@gmail.com

Name : VENKATA BONDADA  
Ref By : DR. SMH

Age/Sex : 47 Yrs./M  
Date : 30/08/2021  
Report ID. : 4

## EXAMINATION OF URINE

Sample : RANDOM  
**PHYSICAL EXAMINATION**

Colour	: PALE YELLOW	Quantity	: 10	ml
Specific Gravit	: 1.030	Transparency	: CLEAR	
Deposits	: ABSENT	Reaction	: ACIDIC	

### CHEMICAL EXAMINATION

Sugar	: NIL	Albumin	: NIL
Bile Salts	: ABSENT	Acetone	: ABSENT
Urobilinogen	: NORMAL : ~ < 1.0 mg/dL	Bile Pigments	: ABSENT
Nitrate	: ABSENT	Occult Blood	: ABSENT

### MICROSCOPIC EXAMINATION

RBC	: NIL	Pus Cells	: 0-1 / hpf
Crystals	: NIL	Epithelial Cell	: NIL
		Amorphous Phosp	: NIL

## THYROID FUNCTIONS

TEST	RESULT	UNIT	REFERENCE INTERVAL
Total Triiodothyronine - T3	: 1.50	ng/mL	0.58 - 1.59 ng/mL
Total Thyroxine - T4	: 9.00	ng/mL	4.87 - 11.72 microgram%
Thyroid Sti. Hormone -TSH	: 3.80	ng/mL	0.35 - 4.94 IU/mL

## LIPID PROFILE

Total Lipid (Calculated)	: 589	mg/dL	350 - 750 mg/dL
Serum Cholesterol	: 192.0	mg/dL	130 - 200 mg/dL
Serum Triglyceride	: 118.0	mg/dL	60 - 165 mg/dL
HDL Cholesterol	: 57.0	mg/dL	30 - 70 mg/dL
LDL Cholesterol	: 111.4	mg/dL	Upto 150 mg/dL
CHOL./HDL Chol. Ratio	: 3.36	: 1	Less than 5
LDL Chol/HDL Chol Ratio	: 1.95	: 1	Less than 3.5
VLDL (Calculated)	: 23.60	mg/dL	Upto 30 mg/dL

END OF REPORT



DR KRISH VAIDYA  
MD, PGDCC  
G-50510



# Shreeji Multispeciality Hospital

Inspiring better health...

Shreeji Occupational Centre Shreeji Pathology Laboratory

112F, Tower-A, Senate Square, Opp. Gangotri Apartment, Vuda Char rasta, Gotri, Vadodara-390021.  
M. : 9157022510, Email : shreejihospital19@yahoo.com, smh31082015@gmail.com

Name : VENKATA BONDADA  
Ref By : DR. SMH

Age/Sex : 47 Yrs./M  
Date : 30/08/2021  
Report ID. : 4

## Hb A1C REPORT

<u>TEST</u>	<u>RESULT</u>	<u>UNIT</u>	<u>REFERENCE INTERVAL</u>
Hb A1C - Glycated Hb Glycated Haemoglobin	: 5.4	%	Non Diabetic : 4.3 - 6.3 % Good Control : 6.4 - 7.5 % Moderate Control : 7.5 - 9.0 % Poor Control : 9.0 % & Above
Avg. Blood Glucose Level	: 115	mg/dL	
Estimated Average Glucose eAG	: 108	mg%	

END OF REPORT



DR KRISH VAIDYA  
MD, PGDCC  
G-50510





# SHREEJI Multispeciality Hospital

Inspiring better health...

SHREEJI OCCUPATIONAL CENTRE SHREEJI PATHOLOGY LABORATORY

112F, Tower-A, Senate Square, Opp. Gangotri Apartment, Vuda Char rasta, Gotri, Vadodara-390021.  
M. : 9157022510, Email : shreejihospital19@yahoo.com, smh31082015@gmail.com

NAME : VENKATU BONDADA	AGE : 47 Y/M	DATE : 30/08/2021
------------------------	--------------	-------------------

## ULTRASOUND WHOLE ABDOMEN

**Liver** is normal in size and shows normal parenchymal reflectivity. No focal lesion is seen. Hepatic veins appear normal. There is no evidence of any dilated intra hepatic biliary radicals.

**Portal Vein** appears normal in diameter. **Common Bile Duct** is of normal diameter.

**Gallbladder** is distended with normal wall thickness. There is no evidence of gallstones. No evidence of peri-cholecystic fluid or probe tenderness.

**Pancreas** is normal in size and shows homogenous reflectivity. There is no evidence of any calcification or ductal dilatation.

**Spleen** is normal size and shows a homogenous echotexture. There is no evidence of any focal lesion.

**Both Kidneys** are normal in position and size. They show normal cortical reflectivity and cortico-medullary distinction. Right kidney measures 82x54mm. Left kidney measures 98x46mm.

**There is evidence of simple right renal cyst noted at mid pole measuring 34x6mm.**

**There is evidence of simple left renal cyst noted at mid pole measuring 18x21mm.**

**Bladder** is physiologically distended and shows normal wall thickness. No evidence of intraluminal mass or calculi.

**Prostate gland** is enlarged in size. It shows smooth walls and homogeneous echotexture. Estimated volume is around 33.9cc. (37x40x42mm)


There is no evidence of ascites.

No evidence of any gross bowel mass seen.

No evidence of any aorto-caval or mesenteric root lymphadenopathy.

### CONCLUSION:

- Prostatomegaly
- Bilateral simple renal cysts.

  
DR. HENRY GANDHI  
CONSULTANT RADIOLOGIST





# SHREEJI Multispeciality Hospital

Inspiring better health...

SHREEJI OCCUPATIONAL CENTRE SHREEJI PATHOLOGY LABORATORY

112F, Tower-A, Senate Square, Opp. Gangotri Apartment, Vuda Char rasta, Gotri, Vadodara-390021.

M. : 9157022510, Email : shreejihospital19@yahoo.com, smh31082015@gmail.com

NAME : VENKATU BONDADA

AGE : 47 Y/M

DATE : 30/08/2021

## X RAY CHEST (PA)

### OBSERVATIONS:

Both the lung fields and apices appear clear.

Both the hilar shadow appears normal.

Cardiac silhouette appears normal.

Both the costophrenic sinuses are clear.

Mediastinal and tracheal shadows are normal.

Both the domes of diaphragm are normal.

Visualized rib cage and clavicle are normal.

### COMMENTS:

No significant abnormality is seen.

**DR. HENY GANDHI**

**CONSULTANT RADIOLOGIST**

