



Ms. VAISHALI GOSWAMI (34 /F)

UHID : AHIL.0000862051

AHC No : AHILAH206060

Date : 14/04/2023

MEDIWHEEL-FULL BODY CHK-BELOW40-FEMALE



Namaste Ms. VAISHALI GOSWAMI,

Thank you for choosing Apollo ProHealth, India's first AI-powered health management program, curated to help you make positive health shifts. Being healthy is about making smart choices, and you have taken the first step with this program. We are privileged to be your healthcare partner. Your health is our priority.

We are with you on your path to wellness by:

Predicting your risk: Artificial Intelligence-powered predictive risk scores are generated, based on your personal, medical, and family history and detailed multi-organ evaluation of your body through diagnostic and imaging tests.

Preventing onset or progress of chronic lifestyle diseases: Your Health Mentor is available to help you understand your physician's recommendations and helping you handle any concerns (complimentary service up to one year)

Overcoming barriers to your wellbeing: Your Health Mentor will help you set your health goals and guide you with tips to stay on track. We will also, digitally remind you to proactively prioritize your health.

Through this report, you will be able to understand your overall health status, your health goals and the recommendations for your path to wellness. Your Health Report will include the following:

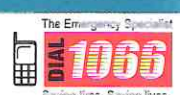- Your medical history and physical examination reports
- Results from your diagnostic and imaging tests
- AI powered health risk scores
- Your physician's impression and recommendations regarding your overall health
- Your personalized path to wellness, including your follow-up assessments and vaccinations

For Enquiry/Appointments Contact +91 76988 15003 / +91 79 66701880

Apollo Hospitals International Limited
Plot No.-1A, Bhat, GIDC, Gandhinagar, Gujarat - 382428, India.
Phone : +91 79 66701800 | Fax No. : +91 79 66701843
E-mail : info@apolloahd.com | www.ahmedabad.apollohospitals.com

Apollo Hospitals - City Centre (NON-MOSH-JOY)
1, Tulsibaug Society, Nr. Parimal Garden, Ahmedabad.
Phone : +91 79 66305800 / 01 or +91 76988 15148
E-mail : info@ahc@apolloahd.com

Regd. Office
19, Bishop Gardens, R.A. Puram, Chennai - 600 028
CIN No. : U85110TN1997PLC039016 | GSTin : 24AABCA4150H225
For online appointment : www.askapollo.com



For online appointment : www.askapollo.com
Keep the records carefully and bring them along during your next visit to our Hospital

We have reviewed the results of the tests and have identified some areas for you to act on. We believe that with focus and targeted interventions, you can be healthier and happier.



Scan the QR code to download the Apollo 247 App

Organization is Accredited
by Joint Commission International



You can visit your proHealth physician in person at this center, or you can book a virtual consultation for review via www.apollo247.com or through the Apollo 24*7 mobile app. You can avail 30% discount on additional tests and follow-up tests at Apollo Hospitals within one week. You may call your Health Mentor on 04048492633 or email at prohealthcare@apollohospitals.com

Stay Healthy and happy! 😊
Apollo ProHealth Care team

Disclaimer: The services offered in the program may vary depending on any prior mutual agreements between guests and the facility/unit.

For Enquiry/Appointments Contact +91 76988 15003 / +91 79 66701880

Apollo Hospitals International Limited
Plot No.-1A, Bhal, GIDC, Gandhinagar, Gujarat - 382428, India.
Phone : +91 79 66701800 | Fax No. : +91 79 66701843
E-mail : info@apolloahd.com | www.ahmedabad.apollohospitals.com

Apollo Hospitals - City Centre (NON NASH-ICU)
1, TulsiBaag Society, Nr. Parnaj Garden, Ahmedabad.
Phone : +91 79 66305800 / 01 or +91 76988 15148
E-mail : infoahcc@apolloahd.com

Regd. Office
19, Bishop Gardens, R.A. Puram, Chennai - 600 026
CIN No. : U85110TN1997PLC039016 | GSTin : 24AABCA4150H2ZG
For online appointment : www.askapollo.com

For online appointment : www.askapollo.com
Keep the records carefully and bring them along during your next visit to our Hospital





Name : Ms. VAISHALI GOSWAMI (34 /F)

Date : 14/04/2023



Address :
Organized & Accredited
by Joint Commission International

UHID : AHIL.0000862051

AHC No : AHILAH206060

Examined by : Dr. SHASHIKANT NIGAM
MEDIWHEEL-FULL BODY CHK-BELOW40-FEMALE



Chief Complaints

For Annual health checkup
Sneezing, Cough

Present Known illness

No history of - Diabetes mellitus, Hypertension, Dyslipidemia, Thyroid disorder, Heart disease, Stroke



Drug Allergy

NO KNOWN ALLERGY :14/04/2023



Systemic Review

Cardiovascular system : - Nil Significant

Respiratory system : - Nil Significant

Oral and dental : - Nil Significant

Gastrointestinal system : - Nil Significant

Genitourinary system : - Nil Significant

Gynaec history : - Nil Significant

Central nervous system : - Nil Significant

Eyes : - Nil Significant

ENT : - Nil Significant

Musculoskeletal system :

Spine and joints
- Nil Significant

Skin : - Nil Significant

General symptoms : - Nil Significant



Past medical history

Do you have any - Yes
allergies?
Past medical history - nil significant



Name Ms. VAISHALI GOSWAMI

UHID : AHIL.0000862051

Date 14/04/2023

AHC No. AHILAH206060



MEDIWHEEL-FULL BODY CHK-BELOW40-FEMALE

Organization is Accredited by Joint Commission International

Covid 19 - Yes
- 2021, 2020

Post detection (3 Weeks) - No

Hospitalization for Covid 19 - No

Surgical history

Caesarian section - 2017

Personal history

Ethnicity - Indian Asian

Marital status - Married

No. of children - 1

Female - 1

Diet - Mixed Diet

Alcohol - does not consume alcohol

Smoking - No

Chews tobacco - No

Physical activity - Mild

Family history

Father - alive

Mother - alive

Brothers - 1

Sisters - 1

Diabetes - father,mother

Hypertension - father,mother

Coronary artery disease - none

Cancer - None

Physical Examination

General

General appearance - normal

Build - normal

Height - 144



Name Ms. VAISHALI GOSWAMI

UHID : AHIL.0000862051

Date : 14/04/2023

AHC No. AHILAH206060



MEDIWHEEL-FULL BODY CHK-BELOW40-FEMALE

Organization is Accredited
by Joint Commission

Weight - 57.7
 BMI - 27.83
 Pallor - No
 Oedema - no



Cardiovascular system

Heart rate (Per minute) - 80
 Rhythm - Regular
 Systolic(mm of Hg) - 100
 Diastolic(mm of Hg) - 60
 - B.P. Sitting
 Heart sounds - S1S2+

Respiratory system

Breath sounds - Normal vesicular breath sounds



Abdomen

Organomegaly - No
 Tenderness - No

Printed By : MUKTA S ADALTI

For Enquiry/Appointments Contact +91 76988 15003 / +91 79 66701880

Apollo Hospitals International Limited
 Plot No.-1A, Bhat, GIDC, Gandhinagar, Gujarat - 382428, India.
 Phone : +91 79 66701800 | Fax No. : +91 79 66701643
 E-mail : info@apolloahd.com | www.ahmedabad.apollohospitals.com

Apollo Hospitals - City Centre (NON NABH-JCI)
 1, TulsiBaag Society, Nr. Parimal Garden, Ahmedabad.
 Phone : +91 79 66305800 / 01 or +91 76988 15148
 E-mail : infoahcc@apolloahd.com

Regd. Office
 19, Bishop Gardens, R.A. Param, Chennai - 600 028
 CIN No. : U85110TN1987PLC039016 | GSTin : 24AAAC44150H225
 For online appointment : www.askapollo.com



For online appointment : www.askapollo.com
Keep the records carefully and bring them along during your next visit to our Hospital



Name Ms. VAISHALI GOSWAMI

UHID : AHIL.0000862051

Date 14/04/2023

MEDIWHEEL-FULL BODY CHK-BELOW40-FEMALE

AHC No. AHILAH206060

APOLLO HOSPITALS

Organization is Accredited by Joint Commission International

COMPLETE BLOOD COUNT WITH ESR

Test Name	Result	Unit	Level	Range
Hemoglobin (Photometric Measurement)	11 *	gm%	●	12-16
Packed cell volume(Calculated)	34.5 *	%	●	36-46
RBC COUNT (Impedance)	4.35	Million/ul	●	3.8-5.2
MCV (From RBC Histogram)	79.3 *	fl	●	80-100
MCH(Calculated)	25.29 *	pg	●	27-32
MCHC(Calculated)	31.9	%	●	31-36
RDW(Calculated)	15.3 *	%	●	11.5-14.5
WBC Count (Impedance)	8370	/cu mm	●	4000-11000
Neutrophils	66	%	●	40-75
Lymphocytes	26	%	●	20-40
Monocytes	07	%	●	2-10
Eosinophils	01	%	●	01-06
Basophils	00	%	●	0-1
Platelet Count (Impedance)	376800	/cu mm	●	150000-450000
MPV (Calculated)	7.5	fl	●	7-11
ERYTHROCYTE SEDIMENTATION RATE (ESR) (Automated/ optic-electronic)	20	mm/1st hr	●	0-20

BLOOD GROUPING AND TYPING (ABO and Rh)

Test Name	Result	Unit	Level	Range
BLOOD GROUP:	B Positive			

LFT (LIVER FUNCTION TEST)

Liver function tests(LFT), are groups of clinical biochemistry blood assays that give information about the state of a patient's liver. These tests can be used to detect the presence of liver disease, distinguish among different types of liver disorders, gauge the extent of known liver damage, and follow the response to treatment.

Test Name	Result	Unit	Level	Range
ALT(SGPT) - SERUM / PLASMA	28	U/L	●	0-35
ALKALINE PHOSPHATASE - SERUM/PLASMA	77	U/L	●	Adult(Female): 35 - 104
AST (SGOT) - SERUM	22	U/L	●	>1 year Female : <32

● Within Normal Range ● Borderline High/Low ● Out of Range



Name : Ms. VAISHALI GOSWAMI

UHID : AHIL.0000862051

Date : 14/04/2023

MEDIWHEEL-FULL BODY CHK-BELOW40-FEMALE

AHC No. AHILAH206060

APOLLO HOSPITALS

Organization is Accredited
by Joint Commission International

Test Name	Result	Unit	Level	Range
Total Bilirubin	0.331	mg/dL	●	0.300-1.200
Direct Bilirubin	0.14	mg/dL	●	Upto 0.3 mg/dl
Indirect Bilirubin	0.191	mg/dL	●	1 Day ≤5.1 mg/dL 2 Days ≤7.2 mg/dL 3-5 Days ≤10.3 mg/dL 6-7 Days ≤8.4 mg/dL 8-9 Days ≤6.5 mg/dL 10-11 Days ≤4.6 mg/dL 12-13 Days ≤2.7 mg/dL 14 Days - 9 Years 0.2-0.8 mg/dL 10-19 Years 0.2-1.1 mg/dL ≥20 Years 0.2-1.2 mg/dL

CREATININE - SERUM / PLASMA

Test Name	Result	Unit	Level	Range
CREATININE - SERUM / PLASMA	0.55	mg/dL	●	Adult Female: 0.5 - 1.2

LFT (LIVER FUNCTION TEST)

Liver function tests(LFT), are groups of clinical biochemistry blood assays that give information about the state of a patient's liver. These tests can be used to detect the presence of liver disease, distinguish among different types of liver disorders, gauge the extent of known liver damage, and follow the response to treatment.

Test Name	Result	Unit	Level	Range
GGTP: GAMMA GLUTAMYL TRANSPEPTIDASE - SERUM	22	U/L	●	Male : 10 - 71 Female : 6 - 42

GLUCOSE - SERUM / PLASMA (FASTING)

Test Name	Result	Unit	Level	Range
Glucose - Plasma (Fasting)	93	mg/dL	●	70 - 100 : Normal 100 - 125 : Impaired Glucose Tolerance ≥ 126 : Diabetes Mellitus

GLUCOSE - SERUM / PLASMA (POST PRANDIAL) - PPBS

Test Name	Result	Unit	Level	Range
Glucose - Plasma (Post Prandial)	103	mg/dL	●	70-140

GLYCOSYLATED HEMOGLOBIN (HBA1C) - WHOLE BLOOD

Test Name	Result	Unit	Level	Range

● Within Normal Range ● Borderline High/Low ● Out of Range



Name Ms. VAISHALI GOSWAMI

UHID : AHIL.0000862051

Date : 14/04/2023

MEDIWHEEL-FULL BODY CHK-BELOW40-FEMALE

AHC No. AHILAH206060



Organization is Accredited
by Joint Commission International

Glycosylated Hemoglobin (HbA1c)

5.5

%



Normal < 5.7

%Increased risk for Diabetes 5.7 - 6.4%

Diabetes >= 6.5%

Monitoring criteria for Diabetes Mellitus
<7.0 : Well Controlled Diabetes
7.1 – 8.0 : Unsatisfactory Control
> 8.0 : Poor Control & Needs Immediate Treatment

Estimated Average Glucose.

111.15

LFT (LIVER FUNCTION TEST)

Liver function tests(LFT), are groups of clinical biochemistry blood assays that give information about the state of a patient's liver. These tests can be used to detect the presence of liver disease, distinguish among different types of liver disorders, gauge the extent of known liver damage, and follow the response to treatment.

Test Name	Result	Unit	Level	Range
PROTEIN TOTAL - SERUM / PLASMA	7.35	g/dL	●	6.00-8.00
PROTEIN TOTAL - SERUM / PLASMA	7.35	g/dL	●	6.00-8.00
ALBUMIN - SERUM	4.54	g/dL	●	Adult(18 - 60 Yr): 3.5 - 5.2
ALBUMIN - SERUM	4.54	g/dL	●	Adult(18 - 60 Yr): 3.5 - 5.2
Globulin-Serum/Plasma	2.81		●	2.20-4.20
Globulin-Serum/Plasma	2.81		●	2.20-4.20
A/G ratio	1.62		●	1.00-2.00
A/G ratio	1.62		●	1.00-2.00

THYROID PROFILE (T3,T4 AND TSH)

Test Name	Result	Unit	Level	Range
TOTAL T3: TRI IODOTHYRONINE - SERUM	1.7	nmol/L	●	Adults(20-120 Yrs): 1.2 - 3.1 Pregnant Female : First Trimester : 1.61 - 3.53 Second Trimester : 1.98 - 4.02 Third Trimester : 2.07 - 4.02
TOTAL T4: THYROXINE - SERUM	82	nmol/L	●	Adults(20-100 Yrs):66 - 181 Pregnant Female : First Trimester : 94.3 - 190 Second Trimester : 102 - 207 Third Trimester : 89 - 202
TSH: THYROID STIMULATING HORMONE - SERUM	1.79	µIU/mL	●	14-120 years : 0.27 - 4.20



Within Normal Range



Borderline High/Low



Out of Range

**URIC ACID - SERUM**

Uric acid is a product of the metabolic breakdown of purine. High blood concentrations of uric acid can lead to gout. It is also associated with other medical conditions including diabetes and the formation of kidney stones.

Test Name	Result	Unit	Level	Range
URIC ACID - SERUM	2.0 *	mg/dL	●	Male : 3.4-7.0 Female : 2.4-5.7

BUN (BLOOD UREA NITROGEN)

Test Name	Result	Unit	Level	Range
BUN (BLOOD UREA NITROGEN)	6	mg/dL	●	6-20
UREA - SERUM / PLASMA	15	mg/dL	●	15 - 50

LIPID PROFILE - SERUM

Test Name	Result	Unit	Level	Range
Total Cholesterol	216 *	mg/dl	●	0 - 200 : Desirable 200 - 240 : Borderline High 240 - 280 : High > 280 : Very High
Triglycerides - Serum	113	mg/dL	●	0-150
HDL CHOLESTEROL - SERUM / PLASMA (Direct Enzymatic Colorimetric)	54 *	mg/dL	●	< 40 : Major risk factor for heart disease 40 - 59 : The higher The better. >=60 : Considered protective against heart disease
LDL Cholesterol (Direct LDL)	169 *	mg/dL	●	100 : Optimal 100-129 : Near Optimal 130-159 : Borderline High 160-189 : High >=190 : Very High
VLDL CHOLESTEROL	23		●	< 40 mg/dl
C/H RATIO	4		●	0-4.5

X-RAY CHEST PA

X-ray imaging creates pictures of the inside of your body. Chest X-ray can reveal abnormalities in the lungs, the heart, and bones that sometimes cannot be detected by examination.

NORMAL STUDY.



Within Normal Range



Borderline High/Low



Out of Range



Name Ms. VAISHALI GOSWAMI

UHID : AHIL.0000862051

Date : 14/04/2023

MEDWHEEL-FULL BODY CHK-BELOW40-FEMALE

AHC No. AHILAH206060



Organization is Accredited
by Joint Commission International

ECHO/TMT

Investigations Not Done / Not Yet Reported

Haematology

STOOL ROUTINE

URINE GLUCOSE(FASTING)

URINE GLUCOSE(POST PRANDIAL)

Histopathology

CONVENTIONAL PAP SMEAR /CERVICAL SMEAR

Haematology

URINE FOR ROUTINE EXAMINATION

CARDIOLOGY

EKG



Within Normal Range



Borderline High/Low



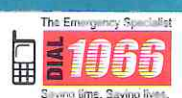Out of Range

For Enquiry/Appointments Contact +91 76988 15003 / +91 79 66701880

Apollo Hospitals International Limited
Plot No.-1A, Bhat, GIDC, Gandhinagar, Gujarat - 382428, India.
Phone : +91 79 66701800 | Fax No. : +91 79 66701843
E-mail : info@apolloahd.com | www.ahmedabad.apollohospitals.com

Apollo Hospitals - City Centre (NON NASH-JCI)
1, TulsiBaag Society, Nr. Pajmal Garden, Ahmedabad.
Phone : +91 79 66305800 / 01 or +91 76988 15148
E-mail : infoahcc@apolloahd.com

Regd. Office
19, Bishop Gardens, R.A. Puram, Chennai - 600 028
CIN No. : U85110TN1997PLC039016 | GSTin : 26AABCA4150H2Z5
For online appointment : www.askapollo.com



For online appointment : www.askapollo.com
Keep the records carefully and bring them along during your next visit to our Hospital



Name Ms. VAISHALI GOSWAMI

UHID : AHIL.0000862051

Date 14/04/2023

MEDIWHEEL-FULL BODY CHK-BELOW40-FEMALE

AHC No - AHILAH206060

APOLLO HOSPITALS

Organization is Accredited by Joint Commission International

Executive Summary



- .BODY WEIGHT 57.7 KG, IDEAL BODY WEIGHT 39-48 KG
- .DYSLIPIDEMIA
- .ECG - NORMAL
- .ECHO - NORMAL
- .USG ABDOMEN -LEFT OVARIAN SIMPLE CYST
- .CHEST X-RAY - NORMAL
- .VISION - NORMAL
- .DENTAL - AS PER DOCTOR ADVICE

Wellness Prescription

Advice On Diet :-



- BALANCED DIET
- LOW FAT DIET

Advice On Physical Activity :-



- REGULAR 30 MINUTES WALK FOR HEALTH AND 60 MINUTES FOR WEIGHT REDUCTION
- PRACTICE YOGA AND MEDITATION
- MAINTAIN WEIGHT BETWEEN 39-48 KG

Printed By : MUKTA S ADALTI

Signature
Dr.SHASHIKANT NIGAM

AHC Physician / Consultant Internal Medicine

Dr. Shashikant Nigam

MBBS, MD, Generalist

Consultant Internal Medicine

Apollo Hospitals International, 19, Bishop Garden, Chennai, Gujarat-382428, INDIA. Regd. No. GZ 1507


Note :- The Health Check-up examinations and routine investigations have certain limitations and may not be able to detect all the diseases. Any new or persisting symptoms should be brought to the attention of the Consulting Physician. Additional tests, consultations and follow up may be required in some cases.



Organization is Accredited
by Joint Commission International



RADIOLOGY

Patient Details : Ms. VAISHALI GOSWAMI | Female | 34Yr 11Mth 27Days
UHID : AHIL.0000862051 **Patient Location:** AHC
Patient Identifier: AHILAH206060 
DRN : 123049723 **Completed on :** 14-APR-2023 10:28
Ref Doctor : DR. SHASHIKANT NIGAM

X-RAY CHEST PA

FINDINGS :

Lung fields are clear.
 Cardio thoracic ratio is normal.
 Both costophrenic angles are clear.
 Domes of diaphragm are well delineated.
 Bony thorax shows no significant abnormality.

IMPRESSION

NORMAL STUDY.

--- END OF THE REPORT ---



AKSHAY SHARMA

Medical Officer

Printed on : 15-Apr-2023 13:01

Printed By : 153182

Reported By : 717876

Page 1 of 1

For Enquiry/Appointments Contact +91 76988 15003 / +91 79 66701880

Apollo Hospitals International Limited
 Plot No.-1A, Bhat, GIDC, Gandhinagar, Gujarat - 382429, India.
 Phone : +91 79 66701800 | Fax No. : +91 79 66701843
 E-mail : info@apolloahd.com | www.ahmedabad.apollohospitals.com

Apollo Hospitals - City Centre (NON NASH-JCI)
 1, Tulsi Bhag Society, Nr. Parnal Garden, Ahmedabad.
 Phone : +91 79 88305800 / 01 or +91 78908 15148
 E-mail : infoahcc@apolloahd.com

Regd. Office
 19, Bishop Gardens, R.A. Puram, Chennai - 600 028
 CIN No. : U85110TN1997PL0039016 | GSTin : 24AAAC44150H2Z5
 For online appointment : www.askapollo.com

The Emergency Specialist



Saving time. Saving lives.


For online appointment : www.askapollo.com
 Keep the records carefully and bring them along during your next visit to our Hospital



Organization is Accredited
by Joint Commission International



CARDIOLOGY

Patient Details : Ms. VAISHALI GOSWAMI | Female | 34Yr 11Mth 27Days
UHID : AHIL.0000862051 **Patient Location:** AHC
Patient Identifier: AHILAH206060 
DRN : 5623035963 **Completed on :** 14-APR-2023 12:38
Ref Doctor : DR. SHASHIKANT NIGAM

ECHO/TMT

FINDINGS :

- Normal cardiac chamber dimensions.
- Normal LV systolic function, LVEF: 60%
- No Regional wall motion abnormalities at rest.
- Normal LV compliance.
- All cardiac valves are structurally normal.
- IAS/ IVS intact.
- No MR, No AR, No PR, Trivial TR.
- No PAH, RVSP:13 mm Hg.
- No clots/ vegetation/ effusion.

MEASUREMENTS (mm) ::

	LVID diastole	LVID systole	IVSd / LVPW	LA Size	AO (Root)
Measurements (mm)	34	18	9/9	26	25

Printed on : 15-Apr-2023 13:00

Printed By : 153182

Reported By : 1120407

Page 1 of 2

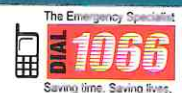For Enquiry/Appointments Contact +91 76988 15003 / +91 79 66701880

Apollo Hospitals International Limited
 Plot No.-1A, Bhat, GIDC, Gandhinagar, Gujarat - 382428, India.
 Phone : +91 79 66701800 | Fax No. : +91 79 66701843
 E-mail : info@apolloahd.com | www.ahmedabad.apollohospitals.com

Apollo Hospitals - City Centre (NON NABH-JCI)
 1, TulsiBaag Society, Nr. Panthal Garden, Ahmedabad.
 Phone : +91 79 66303900 / 01 or +91 76988 15148
 E-mail : infoahcc@apolloahd.com

Regd. Office
 19, Bishop Gardens, R.A. Puram, Chennai - 600 028
 CIN No. : U85110TN1997PLC039016 | GSTin : 24AABC44150H225
 For online appointment : www.askapollo.com

For online appointment : www.askapollo.com
 Keep the records carefully and bring them along during your next visit to our Hospital



Saving time. Saving lives.



Organization is Accredited
by Joint Commission International



Ms. VAISHALI GOSWAMI

AHIL.0000862051

AHILAH206060

ECHO/TMT

PULSED, HPRF, CW AND COLOUR DOPPLER PARAMETERS

	MITRAL	AORTIC	PULMONAR Y
Peak Velocity m/sc.	E:1.10/A: 0.56	1.20	0.71
Peak PR. Gradient mm.Hg.		5.74	1.99

IMPRESSION

— END OF THE REPORT —

DR SAMEER DANI MD.DM

Interventional Cardiologist

DR. CHIRAG PRAHLADBHAI PATEL

MBBS., PGDCC

Printed on : 15-Apr-2023 13:00

Printed By : 153182

Reported By : 1120407

Page 2 of 2

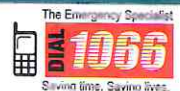For Enquiry/Appointments Contact +91 76988 15003 / +91 79 66701880

Apollo Hospitals International Limited
Plot No.-1A, Bhat, GIDC, Gandhinagar, Gujarat - 382428, India.
Phone : +91 79 66701800 | Fax No. : +91 79 66701843
E-mail : info@apolloahd.com | www.ahmedabad.apollohospitals.com

Apollo Hospitals - City Centre (WOMEN ONLY)
1, TulsiBaag Society, Nr. Pannal Garden, Ahmedabad,
Phone : +91 79 66305800 / 01 or +91 76988 15148
E-mail : infoahcc@apolloahd.com

Regd. Office
19, Bishop Gardens, R.A. Puram, Chennai - 600 028
CIN No. : U85110TN1997PLC039016 | GSTin : 24AARCA4150H225
For online appointment : www.askapollo.com

For online appointment : www.askapollo.com
Keep the records carefully and bring them along during your next visit to our Hospital




Saving time. Saving lives.



Organization is Accredited
by Joint Commission International



RADIOLOGY

Patient Details : Ms. VAISHALI GOSWAMI | Female | 34Yr 11Mth 27Days
UHID : AHIL.0000862051 **Patient Location:** AHC
Patient Identifier: AHILAH206060 
DRN : 223020839 **Completed on :** 14-APR-2023 13:09
Ref Doctor : DR. SHASHIKANT NIGAM

USG WHOLE ABDOMEN

FINDINGS :

Liver appears normal in size and shows uniform normal echotexture. No evidence of focal or diffuse pathology seen. Intra and extra hepatic biliary radicles are not dilated. Portal vein is normal in calibre. Intrahepatic portal radicles appear normal.

Gall bladder appears normal with no evidence of calculus. Wall thickness appears normal. No evidence of pericholecystic collection.

Visualized Head and body of pancreas appear normal in size and echotexture. No focal lesions identified. Pancreatic duct appears normal in caliber.

Spleen measures 8.3 cms and shows uniform echotexture.

Both kidneys are normal in size and show normal echopattern with good corticomedullary differentiation. Cortical outlines appear smooth. No evidence of calculi. Pelvicalyceal system on both sides appear normal.

No evidence of ascites or lymphadenopathy.

Urinary bladder is normal in contour and outline. Wall thickness appears normal. No evidence of any intraluminal pathology seen.

Uterus is anteverted and appears normal in size and echotexture. No focal lesion is seen. Myometrial and endometrial echopattern appear normal. Endometrial thickness is 3 mm.

Both ovaries are normal in size and echopattern.

A simple cyst of approximate size 3 x 2.6 cm is seen in left ovary.

No free fluid is seen in Pouch Of Douglas.

Printed on : 15-Apr-2023 13:01

Printed By : 153182

Reported By : 717876

Page 1 of 2

For Enquiry/Appointments Contact +91 76988 15003 / +91 79 66701880

Apollo Hospitals International Limited
 Plot No.-1A, Bhat, GIDC, Gandhinagar, Gujarat - 382428, India.
 Phone : +91 79 66701800 | Fax No. : +91 79 66701843
 E-mail : info@apoltoahd.com | www.ahmedabad.apollohospitals.com

Apollo Hospitals - City Centre (NON NESH-ICP)
 1, Tulsibaug Society, Nr. Parimal Garden, Ahmedabad.
 Phone : +91 79 66305800 / 01 or +91 76988 15148
 E-mail : info@ahcc@apoltoahd.com

Regd. Office
 19, Bishop Gardens, R.A. Puram, Chennai - 600 028
 CIN No. : U85110TN1997PLC039016 | GSTIn : 24AABCA4150H225
 For online appointment : www.askapollo.com

For online appointment : www.askapollo.com
 Keep the records carefully and bring them along during your next visit to our Hospital





Organization is Accredited
by Joint Commission International



Ms. VAISHALI GOSWAMI

AHIL.0000862051

AHILAH206060

USG WHOLE ABDOMEN

No definite evidence of adnexal/pelvic mass is seen.

IMPRESSION :

Left ovarian simple cyst.
Rest unremarkable study.

--- END OF THE REPORT ---

SIDDHARTH S PARMAR

Printed on : 15-Apr-2023 13:01

Printed By : 153182

Reported By : 717876

Page 2 of 2

For Enquiry/Appointments Contact: +91 76988 15003 / +91 79 66701880

Apollo Hospitals International Limited
Plot No.-1A, Bhat, GIDC, Gandhinagar, Gujarat - 382428, India.
Phone : +91 79 66701800 | Fax No. : +91 79 66701843
E-mail : info@apolloahd.com | www.ahmedabad.apollohospitals.com

Apollo Hospitals - City Centre (INDIA) (MUMBAI-JC)
1, Tulsibaug Society, Nr. Pannal Garden, Ahmedabad.
Phone : +91 79 66305800 / 01 or +91 76988 15148
E-mail : infoahcc@apolloahd.com

Regd. Office
19, Bishop Gardens, R.A. Puram, Chennai - 600 028
CIN No. : U85110TN1997PLC039016 | GSTin : 24AABCA4150H2Z5
For online appointment : www.askapollo.com

For online appointment : www.askapollo.com
Keep the records carefully and bring them along during your next visit to our Hospital



Saving time. Saving lives.

Rate 80

PR 175

QRSD 93

QT 369

QTc 426

--AXIS--

P 71

QRS 48

T 32

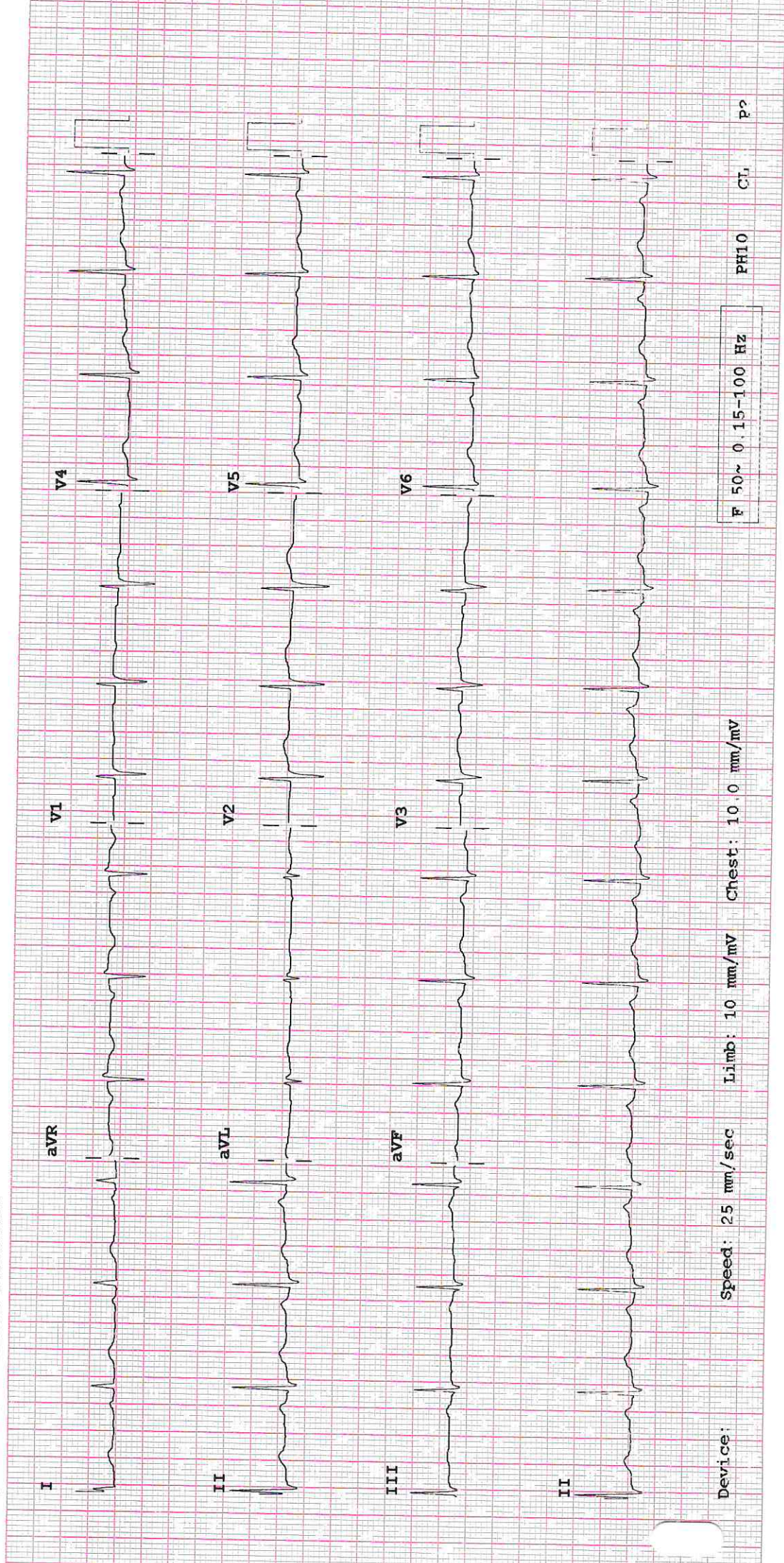
12 Lead; Standard Placement

AHIL.0000862051

Ms. VAISHALI

GOSWAMI

35 Year(s) / Female



Device: Speed: 25 mm/sec Limb: 10 mm/mV Chest: 10.0 mm/mV

F 50~ 0.15-100 HZ

PH10 CI1 P?



DENTISTRY

Name : Date : 14/4/23 Unit No. :

Occupation : Ref. Physician :

Age : Sex : Male Female Copies to :

DENTAL RECORD

ALLERGIES : N/A

PAIN : Score (0-10) 0 Location : - Character : -

DENTAL CLEANING HABIT Once Twice Occasionally

Brush Finger Stick Any other

Tooth Paste Powder Any other

DO THE GUMS BLEED WHEN YOU BRUSH YOUR TEETH? Yes No

ARE YOUR TEETH SENSITIVE TO HEAT / COLD? Yes No

ORAL HYGIENE Good Fair Poor

ORAL TISSUE EXAMINATION	PERIODONTAL EXAMINATION	OCCLUSION
NORMAL FINDINGS IN DISEASE	MILD MOD SEV	CLASS I II III CROSSBITE
Lips : <u>N/A</u>	Gingivitis <input type="checkbox"/> <input checked="" type="checkbox"/> <input type="checkbox"/>	Hypoplasia
Cheeks : <u>N/A</u>	Calculus <input type="checkbox"/> <input checked="" type="checkbox"/> <input type="checkbox"/>	Impaction
Tongue : <u>N/A</u>	Recession <input type="checkbox"/> <input type="checkbox"/> <input type="checkbox"/>	Non-vital
Floor of the mouth : <u>N/A</u>	Periodontal Pockets <input type="checkbox"/> <input type="checkbox"/> <input type="checkbox"/>	Fracture
Palate : <u>N/A</u>	Attrition <input type="checkbox"/> <input type="checkbox"/> <input type="checkbox"/>	Abcess
Tonsillar Area : <u>N/A</u>	Erosion <input type="checkbox"/> <input type="checkbox"/> <input type="checkbox"/>	Ulcers <u>N/A</u>
Any other : <u>N/A</u>	Mobility <input type="checkbox"/> <input type="checkbox"/> <input type="checkbox"/>	Caries <u>N/A</u>
		Missing Teeth
		Supernumerary
		Others

PRESENT COMPLAINT : tooth decay

PRE-MEDICAL HISTORY: DM HTN Thyroid Acidity Pregnancy
 Anticoagulant Under Drug Therapy

N/A

OPHTHALM

AHIL.0000862051

RECORDS

Name :

Ms. VAISHALI
GOSWAMI

Date :

16/6/23

UHID :



Distance Vision :

Right Eye - 6/6
Left Eye - 6/6
E glasses

Near Vision :

Right Eye : NG
Left Eye : NG

APLN.TN - Right Eye

12

Left Eye -

13

mmHg

Normal

Both Eye - Colour Vision

Normal

Both Eye - Anterior Segment Examinations -

Normal

Both Eye Posterior Segment Examinations -

Normal

Put us get and can do
her duty

Place Label Here

If label not available, write Pt. Name, IP No/UHID, Age, Sex, Date, Name of Treating Physician

OBSTETRICS & GYNAECOLOGY - AHC

AHIL.0000862051

N Ms. VAISHALI
GOSWAMI

C 35 Year(s) / Female



Female

Date : 11/11/23 Unit No. :

Ref. Physician : Dr. Usha Bohra

Copies to :

GYNAEC CHECK UP

Chief Complaint:

None. Menstrual Cramps

Children: 2 ♀

Deliveries: 1 LSCS

Last Child: 2c / 5 years / LSCS

Abortions: None

Periods: Regular 5 days
23-25

LMP: 13/11/23

Menopause: -

G. Condition: Fit

P/A: Soft

S/E: -

P/V: -

P/R: ✓

Weight:

BP:

Breasts: Normal

PAP Smear: Not taken (Menstrual Cycle +)

Previous Medical H/O:

None

PH/O: DM, HTN.

Previous Surgical H/O:

No Piles surgery
1 year ago

Impression:

[Signature]
Doctor Signature
Date & Time
11/11/23
1:20 PM