

Varanasi, Uttar Pradesh, India

B36/44B-3, Padampuri Colony, Durgakund,
Nagwa, Varanasi, Uttar Pradesh 221005, India

Lat 25.289172°

Long 82.993416°

27/10/22 09:39 AM GMT +05:30

GPS Map Camera



भारतीय विशिष्ट ओळख प्राधिकरण


Unique Identification Authority of India

पत्ता:

सदामा सिंग, प्लॉट न. 142, मुगलसारय रस्ता, मा
शीतला मंदिर के पास, पञ्चवटी, रामनगर, कबीरपुर,
चंदौली,
उत्तर प्रदेश - 221009

Address:

S/O, Sudama Singh, Plot No. 142,
Mughalsarai Road, Near Maa Shitla
Mandir, Panchvati, Ramnagar, Kabirpur,
Chandauli,
Uttar Pradesh - 221009



QR Code with F11000000000

8756 7833 6526

VID : 9196 3951 7757 8016



https://uidai.gov.in

www.uidai.gov.in

GPS Map Camera

Varanasi, Uttar Pradesh, India

B36/44B-3, Padampuri Colony, Durgakund,

Nagwa, Varanasi, Uttar Pradesh 221005, India

Lat 25.289184°

Long 82.993414°

27/10/22 09:39 AM GMT +05:30



भारत सरकार
Government of India

सुनील कुमार
Sunil Kumar
जन्म तारीख/DOB: 20/01/1983
पुरुष/ MALE

8756 7833 6526
VID : 9196 3951 7757 8016

माझे आधार, माझी ओळख



Facilities:
 All clinical Biomedical & Hematology Investigations
 including Bone Marrow Examination
 VPT, Podiascan & Complete Foot Care (First Time in Purvanchal)
 All Hormonal Investigation by Chemiluminescent Method
 Visceral Fat by (AB-140) Ambulatory BP Monitoring
 CGMS & Insulin Pump Available
 PFT, 2D-ECHO (Color Doppler), Holter, TMT, Cardiac-3 available
 VIA, VILI, Colposcopy available
 Special Endocrinological Investigation Protocols.

ISO 9001:2008 Certified
 Mobile: 9389994334, 9554572190, 9453837595



Panacea Pathology

Clinical Reference Lab

Persistence, Preparedness and Precision
 EQAS (CMC Vellore Attached) & IQAS System
 पूर्वांचल की सर्वोत्तम गुणवत्ता वाली पैथोलॉजी

PATIENT NAME : SUNIL KUMAR	AGE/GENDER : 39 YRS/MALE
REFD BY DR. : ARCO FEMI HEALTHCARE LTD.	RECEIVED DATE : 27-10-2022 (10:28 AM)
SAMPLE : BLOOD & URINE	REPORT DATE : 27-10-2022 (07:15 PM)

PATHOLOGY REPORT

COMPLETE BLOOD COUNT (CBC)

TEST	LAB TEST VALUES	NORMAL RANGE
HEMOGRAM		
HEMOGLOBIN (FLOW CYTOMETRY)	12.4	13 – 16 gm/dl
TOTAL LEUCOCYTE COUNT (TLC)	8,700	4000 – 11000
RBC COUNT	4.44	3.5 – 5.5
PCV (HCT)	38.2	37 – 47
MCV	101.6	80 – 95
MCH	32.9	28 – 34
MCHC	32.9	30 – 36
PLATELET COUNT	1,02,000	1,50,000 – 4,00,000
E.S.R. (WINTROBE FIRST HOURS)	12.0	20 mm/1 st hr
DIFFERENTIAL LEUCOCYTE		
NEUTROPHILS	45	40 – 75%
LYMPHOCYTES	49	20 – 45%
EOSINOPHILS	03	1 – 6%
MONOCYTES	03	2 – 8%
BASOPHILS	00	< 2%

RENAL & KIDNEY PROFILE, SERUM

TEST	LAB TEST VALUES	NORMAL RANGE
RENAL FUNCTION TESTS		
BLOOD UREA NITROGEN (BUN)	13.4	10 – 50 mg/dl
SERUM CREATININE	1.19	0.60 – 1.60 mg/dl
URIC ACID	4.16	3.60 – 7.70 mg/dl
ALKALINE PHOSPHATASE (ALP)	110.0	142 – 353 mg/dl
TOTAL PROTIENS	7.25	0 – 39 mg/dl
ALBUMIN	4.00	3.8 – 5.4 mg/dl
SERUM GLOBULIN	3.25	2.1 – 3.5 mg/dl
CALCIUM	9.8	8.80 – 10.20
PHOSPHORUS	3.92	2.50 – 5.00
SERUM SODIUM NA+	139.8	135.00 – 155.00 mEq/Ltr
SERUM POTASIAM K+	4.28	3.60 – 5.50 mEq/Ltr
ICALCIUM	1.25	1.10 – 1.35 mmol/L
SERUM CHLORIDE CL+	103.3	98.00 – 110.00 mEq/Ltr

PAGE 1

Lab Technician

PANACEA HOSPITAL
 UNIT OF AAROHA HEALTH CARE PVT. LTD.
 REG. NO.: AL-1500
 3.36/44 B-4, KABIR NAGAR
 DURGAKUND, VARANASI

Timing : 8.00 a.m. to 9.00 p.m. (Sunday 8.00 a.m. to 3.00 p.m.)

This Report is not valid for medico legal purpose

Note: These tests have technical limitations. Clinico-pathological interpretation is necessary. In case of any disparity test may be repeated immediately.

Address : 36/44 FK Kabir Nagar, Durgakund, Varanasi – 221005

Email: dramishra@gmail.com, drpallaviojha@gmail.com Website: panaceahospital.org

Facilities:
 All clinical Biomedical & Hematology Investigations
 including Bone Marrow Examination
 VPT, Podiascan & Complete Foot Care (First Time in Purvanchal)
 All Hormonal Investigation by Chemiluminescent Method
 Visceral Fat by (AB-140) Ambulatory BP Monitoring
 CGMS & Insulin Pump Available
 PFT, 2D-ECHO (Color Doppler), Holter, TMT, Cardiac-3 available
 VIA, VILI, Colposcopy available
 Special Endocrinological Investigation Protocols.

ISO 9001:2008 Certified
 Mobile: 9389994334, 9554572190, 9453837595



Panacea Pathology

Clinical Reference Lab

Persistence, Preparedness and Precision
 EQAS (CMC Vellore Attached) & IQAS System
 पूर्वांचल की सर्वोत्तम गुणवत्ता वाली पैथोलॉजी

PATIENT NAME : SUNIL KUMAR	AGE/GENDER : 39 YRS/MALE
REFD BY DR. : ARCO FEMI HEALTHCARE LTD.	RECEIVED DATE : 27-10-2022 (10:28 AM)
SAMPLE : BLOOD & URINE	REPORT DATE : 27-10-2022 (07:15 PM)

PATHOLOGY REPORT

LIPID PROFILE, SERUM

TEST	LAB TEST VALUES	NORMAL RANGE
BLOOD CHEMISTRY		
TOTAL CHOLESTEROL (SERUM)	148.0	Desirable:- < 200 mg/dl Borderline:- 200 – 239 mg/dl High:- > 240 mg/dl
TRIGLYCERIDES (SERUM)	138.0	35 – 170 mg/dl
HDL CHOLESTEROL (SERUM)	36.0	35.30 – 79.50 mg/dl
LDL CHOLESTEROL (SERUM)	84.4	< 130 mg/dl
VLDL	27.60	< 40 mg/dl
NON HDL	72.0	0.00 – 100.00 mg/dl
CHOLESTROL/HDL RATIO	4.27	< 3.0 Low Risk Ratio 3.0 – 5.0 Avg Risk < 5.0 High Risk
LDL/HDL RATIO	2.47	< 3 Ratio

ESR

TEST	LAB TEST VALUES
BLOOD GROUP ABO & RH FACTOR	
BLOOD GROUP	"B"
RH FACTOR	POSITIVE

GLYCOSYLATED HEMOGLOBIN (HBA1C)

TEST	LAB TEST VALUES	NORMAL RANGE
HBA1C	5.4	Normal : <5.97 % Good Control : 5.97 – 6.81% Fair Control : 6.81 – 7.65% Poor Control : >7.65%

THYROID PROFILE (T3, T4, TSH)

TEST	LAB TEST VALUES	NORMAL RANGE
THYROID FUNCTION TEST		
T3	1.19	0.60 – 1.81 ng/ml
T4	8.0	4.50 – 10.90 ug/dl
TSH	2.15	0.39 – 6.10 uIU/mL

PAGE 2

Lab Technician

PANACEA HOSPITAL
 UNIT OF AAROA HEALTH CARE PVT. LTD
 REG. NO.: AL-1500
 B.36/44 B-4, KABIR NAGAR
 DURGAKUND, VARANASI
 M.D. Pathology

Timing : 8.00 a.m. to 9.00 p.m. (Sunday 8.00 a.m. to 3.00 p.m.)

This Report is not valid for medico legal purpose

Note: These tests have technical limitations. Clinico-pathological interpretation is necessary. In case of any disparity test may be repeated immediately.

Address : 36/44 FK Kabir Nagar, Durgakund, Varanasi – 221005

Email: dramishra@gmail.com, drpallaviojha@gmail.com Website: panaceahospital.org

Facilities:

All clinical Biomedical & Hematology Investigations including Bone Marrow Examination VPT, Podiascan & Complete Foot Care (First Time in Purvanchal) All Hormonal Investigation by Chemiluminescent Method Visceral Fat by (AB-140) Ambulatory BP Monitoring CGMS & Insulin Pump Available PFT, 2D-ECHO (Color Doppler), Holter, TMT, Cardiac-3 available VIA, VILI, Colposcopy available Special Endocrinological Investigation Protocols.

ISO 9001:2008 Certified
Mobile: 9389994334, 9554572190, 9453837595



Panacea Pathology

Clinical Reference Lab

Persistence, Preparedness and Precision
EQAS (CMC Vellore Attached) & IQAS System
पूर्वांचल की सर्वोत्तम गुणवत्ता वाली पैथोलॉजी

PATIENT NAME : SUNIL KUMAR

AGE/GENDER : 39 YRS/MALE

REFD BY DR. : ARCO FEMI HEALTHCARE LTD.

RECEIVED DATE : 27-10-2022 (10:28 AM)

SAMPLE : BLOOD & URINE

REPORT DATE : 27-10-2022 (07:15 PM)

PATHOLOGY REPORT

LIVER PROFILE TEST, SERUM

TEST	LAB TEST VALUES	NORMAL RANGE
BIO CHEMISTRY		
TOTAL BILIRUBIN	0.72	0.0 – 1.1 mg/dl
DIRECT BILIRUBIN	0.22	0.0 – 0.2 mg/dl
INDIRECT BILIRUBIN	0.50	< 0.90 mg/dl
SGOT (AST)	24.6	0 – 52 mg/dl
SGPT (ALT)	28.2	0 – 39 mg/dl
GGT (GYT)	21.0	< 55 U/L
AG RATIO	1.96	-

PSA, TOTAL

TEST	LAB TEST VALUES	NORMAL RANGE
PSA	0.93	0.00 – 4.00 mg/dl

URINE ROUTINE EXAMINATION

TEST	LAB TEST VALUES	NORMAL RANGE
PHYSICAL EXAMINATION		
QUANTITY	25	ML
COLOUR	STRAW	PALE YELLOW
APPEARANCE	CLEAR	CLEAR
SPECIFIC GRAVITY	1.010	1.01 – 1.03
PH	5.5	4.7 – 7.5
CHEMICAL EXAMINATION		
GLUCOSE	Not Detected	Not Detected
PROTEIN	NIL	Not Detected
MICROSCOPIC EXAMINATION		
PUS CELLS	1-2	0-5
RBC	Not Detected	Not Detected
EPITHELIAL CELLS	1-2	0-5
CASTS	Not Detected	Not Detected
CRYSTALS	Not Detected	Not Detected
BACTERIA	Not Detected	Not Detected

PAGE 3

Lab Technician

PANACEA HOSPITAL
UNIT OF AAROHA HEALTHCARE PVT. LTD.
REG. NO.: AL-1500
B.36/44,B-4, KABIR NAGAR
DURGAKUND, VARANASI
M.D., Pathology

Timing : 8.00 a.m. to 9.00 p.m. (Sunday 8.00 a.m. to 3.00 p.m.)

This Report is not valid for medico legal purpose

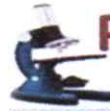Note: These tests have technical limitations. Clinico-pathological interpretation is necessary. In case of any disparity test may be repeated immediately.

Address : 36/44 FK Kabir Nagar, Durgakund, Varanasi – 221005

Email: dramishra@gmail.com, drpallaviojha@gmail.com **Website:** panaceahospital.org

Facilities:
All clinical Biomedical & Hematology Investigations
including Bone Marrow Examination
VPT, Podiascan & Complete Foot Care (First Time in Purvanchal)
All Hormonal Investigation by Chemiluminescent Method
Visceral Fat by (AB-140) Ambulatory BP Monitoring
CGMS & Insulin Pump Available
PFT, 2D-ECHO (Color Doppler), Holter, TMT, Cardiac-3 available
VIA, VILI, Colposcopy available
Special Endocrinological Investigation Protocols.

ISO 9001:2008 Certified
Mobile: 9389994334, 9554572190, 9453837595



Panacea Pathology

Clinical Reference Lab

Persistence, Preparedness and Precision
EQAS (CMC Vellore Attached) & IQAS System
पूर्वांचल की सर्वोत्तम गुणवत्ता वाली पैथोलॉजी

PATIENT NAME : SUNIL KUMAR	AGE/GENDER : 39 YRS/MALE
REFD BY DR. : ARCO FEMI HEALTHCARE LTD.	RECEIVED DATE : 27-10-2022 (10:28 AM)
SAMPLE : BLOOD & URINE	REPORT DATE : 27-10-2022 (07:15 PM)

RANDOM BLOOD SUGER

TEST	LAB TEST VALUES	NORMAL RANGE
RBS		
RANDOM BLOOD SUGER	70.3	110-125 mg/dl

----- End of Report -----

Lab Technician

PANACEA HOSPITAL
UNIT OF AAROH HEALTH CARE PVT. LTD.
REG. NO.: AL-1500
B.36/44, B-4, KABIR NAGAR
DURGAKUND, VARANASI
M.D., Pathology

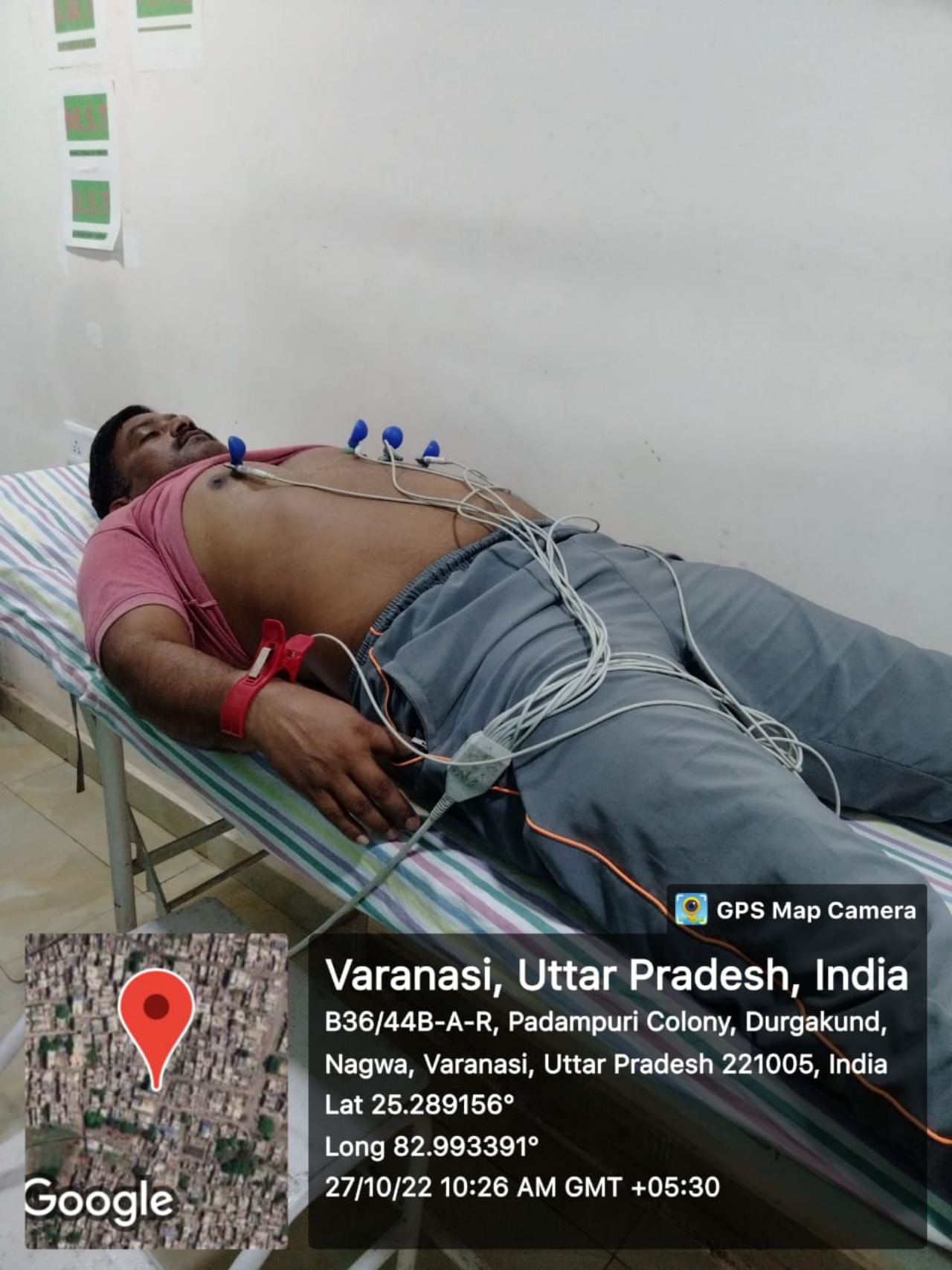Timing : 8.00 a.m. to 9.00 p.m. (Sunday 8.00 a.m. to 3.00 p.m.)


This Report is not valid for medico legal purpose

Note: These tests have technical limitations. Clinico-pathological interpretation is necessary. In case of any disparity test may be repeated immediately.

Address : 36/44 FK Kabir Nagar, Durgakund, Varanasi – 221005

Email: dramishra@gmail.com, drpallaviojha@gmail.com Website: panaceahospital.org



 GPS Map Camera



Varanasi, Uttar Pradesh, India

B36/44B-A-R, Padampuri Colony, Durgakund,

Nagwa, Varanasi, Uttar Pradesh 221005, India

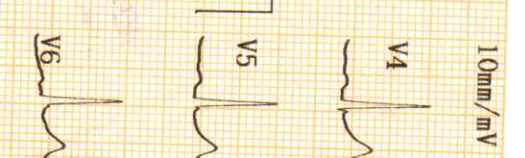
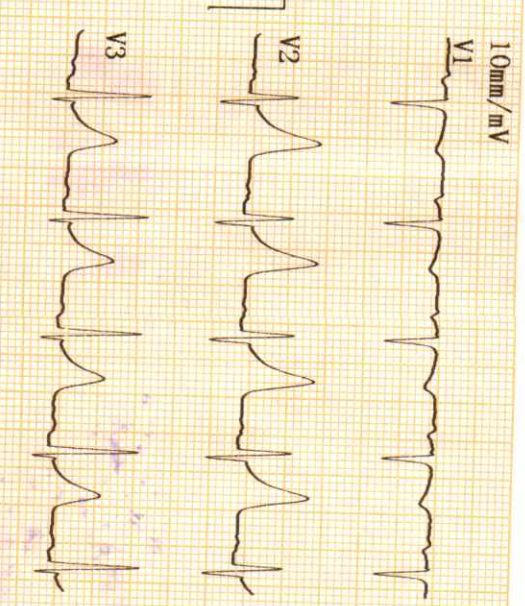
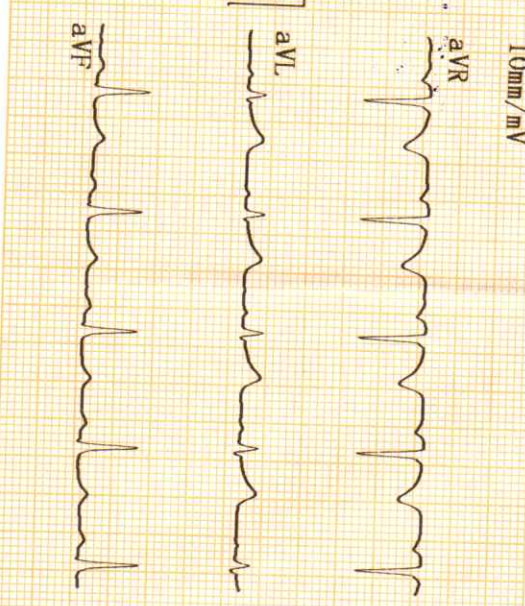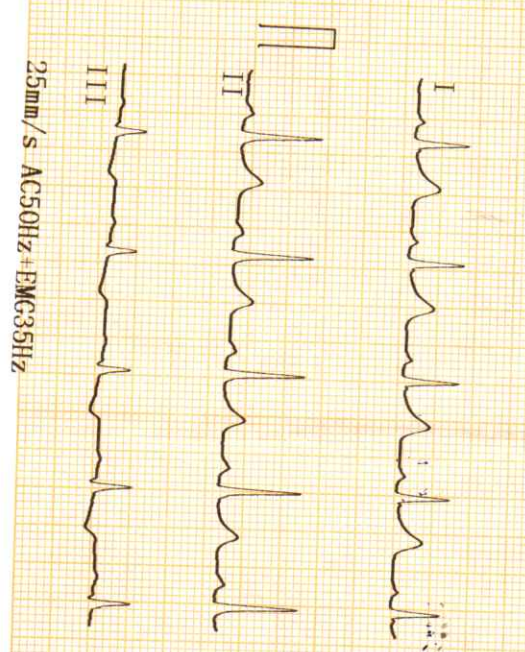
Lat 25.289156°

Long 82.993391°

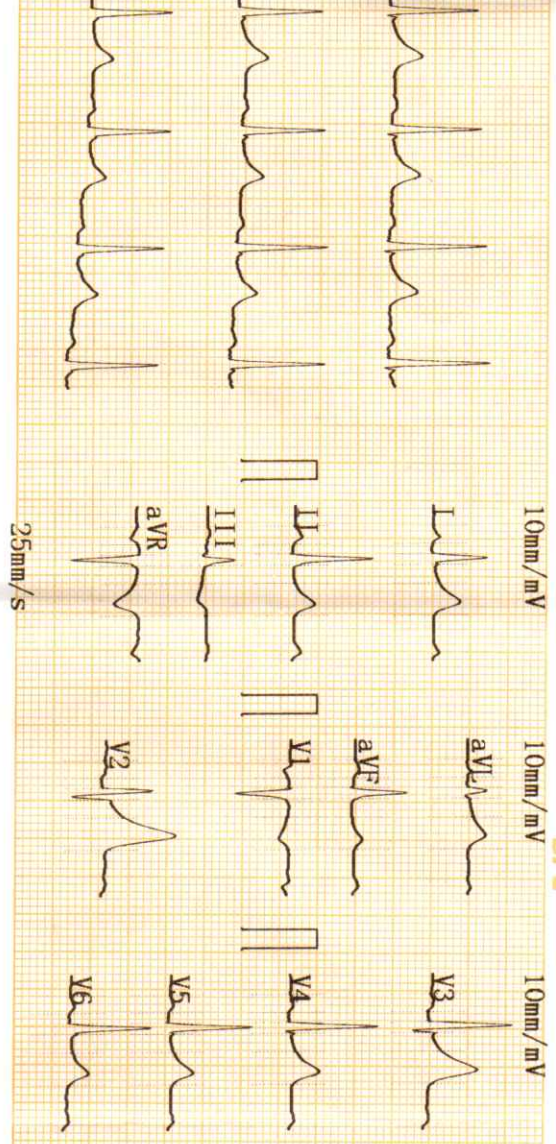
27/10/22 10:26 AM GMT +05:30

2017-07-07
10:00

AUTO 1.0mm/mV
BPL



CARDIART



2022-10-27 10:44

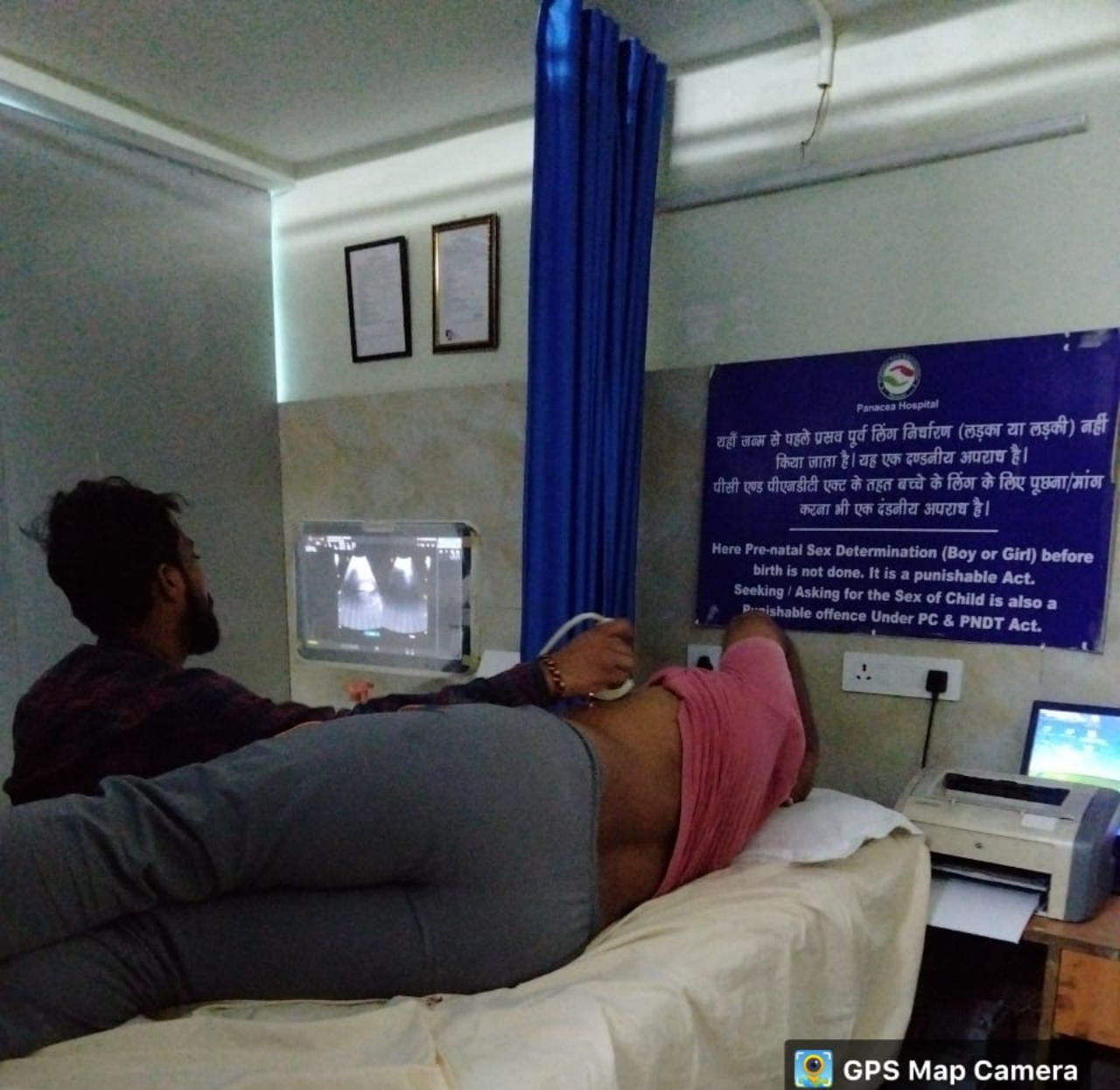ID :
 Name : Sahil Kumar
 Sex : M
 Height :
 SYS :
 DIA :
 HR : 95 bpm
 PR Interval : 154 ms
 P Duration : 98 ms
 QRS Duration : 61 ms
 T Duration : 175 ms
 QT/QTc : 335/421 ms
 P/QRS/T Axis : 52.8/47.0/14.1 deg
 R(V5)/S(V1) : 1.10/0.71 mV
 R(V5)+S(V1) : 1.80 mV


<< Conclusions >>

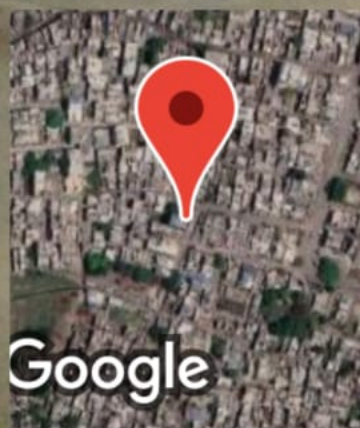Normal Sinus Rhythm;
 Cardiac electric axis normal;
 Report need physician confirm

DR. PALLAVI MISHRA
 MBBS, MD(GENERAL (FEDICINE))
 MCI Reg. No. 52033

Physician



 GPS Map Camera



Google

Varanasi, Uttar Pradesh, India
B36/44B-3, Padampuri Colony, Durgakund,
Nagwa, Varanasi, Uttar Pradesh 221005, India
Lat 25.289202°
Long 82.993448°
27/10/22 09:46 AM GMT +05:30



PANACEA HOSPITAL

A shelter for many hearts A Home for many lives

(An ISO 9001:2008 Certified Organisation)

Lab Attached with CMC Vellore Under EQAS Scheme

Name	MR.SUNIL KUMAR	Sex /Age	39/M	Date	27/10/2022
Ref. by	SELF	BSA - m ²		Echo window	fair

Echo - Cardiography

MITRAL VALVE Doppler	AML - normal morphology MV Flow - E - 0.6 A-0.4 E/A=1.44	PML - normal morphology MVA - 3.0 cm ² Mitral Regurgitation - No
TRICUSPID VALVE Doppler	Normal TV Flow -No	Tricuspid Regurgitation - No
PULMONARY VALVE Doppler	Normal PV Flow -No	Pulmonary Regurgitation - No
AORTIC VALVE Doppler	Trileaflet-No AV Flow - no	Aortic Regurgitation - no
MEASUREMENT	Aorta - 33.1 (20-38) mm IVS ed -9.7 (6-12) mm LVID ed - 44.5 (35 - 55) mm LVPW ed - 14.8 (6-12) mm OA - 7 (> 5) mm	LA - 34.8 (24-32) mm IVS es -11.4 (6 - 12) mm LVID es - 30.3 (24 - 40) mm LVPW es - 21.1 (6-12) mm EPSS -9 (< 9) mm

CONCLUSION

All cardiac chamber dimensions are WNL.
No valvular abnormalities
No diastolic dysfunction present (E/A = 1.44) by tissue Doppler (E/e' = 5.8)
Good LV systolic function present Modified Simpson's method (4C, 2C) (LVEF-60%)
No RWMA
No pericardial effusion.
Intact IAS / IV
No PAH
No intra cardiac mass /thrombus /vegetation

IMPRESSION

Normal Echocardiogram


Niraj Mishra
Physician Assistant
(PIIRE)

PANACEA HOSPITAL
(A UNIT OF AAROH HEALTH CARE PVT. LTD.,
REG. NO.: AL-1500
B.36/44, B-4, KABIR NAGAR
DURGAKUND, VARANASI

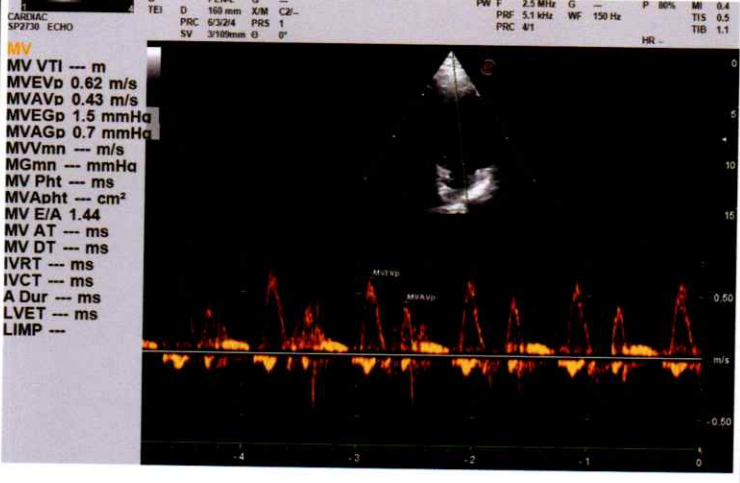
Dr. Pallavi Mishra
MBBS, MD (MED) Lucknow
Echocardiography Specialist, MIAE
Non-invasive cardiologist
Women Cardiologist
Diabetocardiologist

Address : Kabir Nagar (Near Sanjay Shiksha Niketan), Durgakund, Varanasi

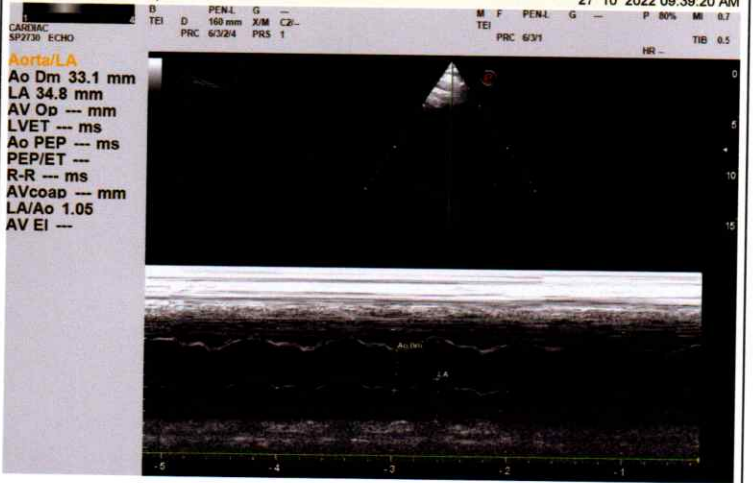
Mobile : 9554572190 / 9453837595 / Recpn. 9389994334

E-mail : dramishra@gmail.com, drpallaviojha@gmail.com, Website: www.piire.org

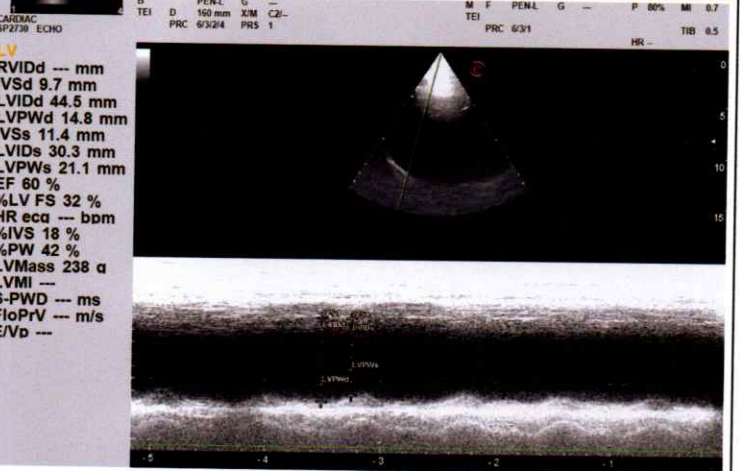
SUNIL KUMAR 39Y/M,F 27 10 2022 09:39:20 AM



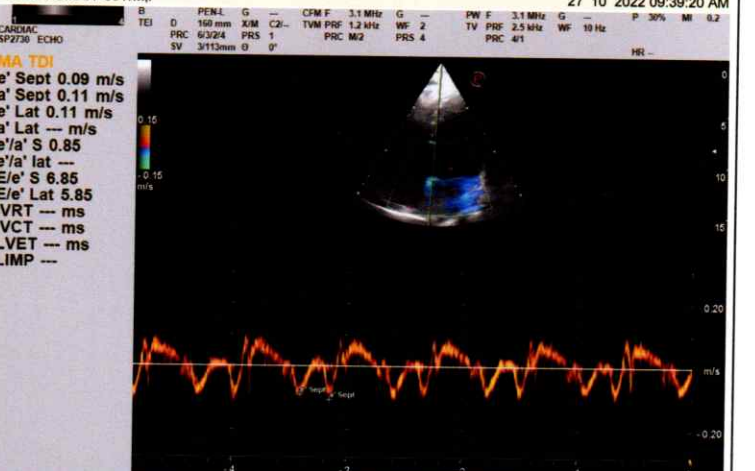
SUNIL KUMAR 39Y/M,F 27 10 2022 09:39:20 AM



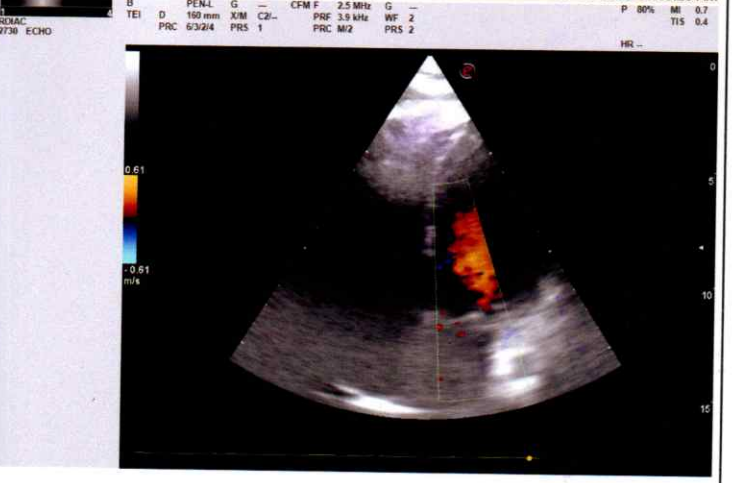SUNIL KUMAR 39Y/M,F 27 10 2022 09:39:20 AM




SUNIL KUMAR 39Y/M,F 27 10 2022 09:39:20 AM

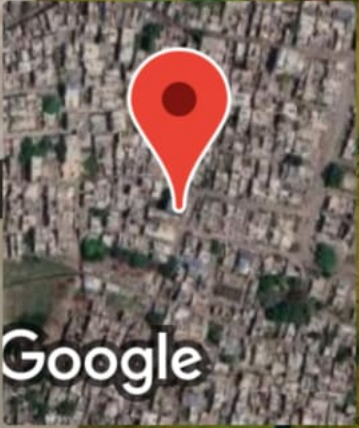

SUNIL KUMAR 39Y/M,F 27 10 2022 09:39:20 AM





 GPS Map Camera



Varanasi, Uttar Pradesh, India

B36/44B-A-R, Padampuri Colony, Durgakund,
Nagwa, Varanasi, Uttar Pradesh 221005, India

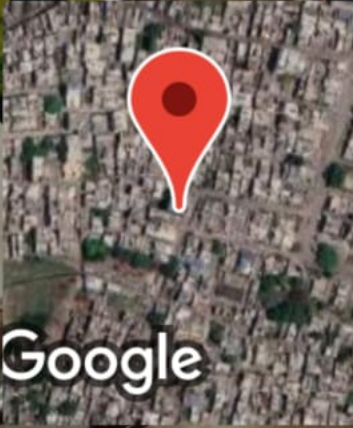Lat 25.289147°

Long 82.993407°

27/10/22 10:34 AM GMT +05:30



GPS Map Camera



Google

Varanasi, Uttar Pradesh, India

B36/44B-A-R, Padampuri Colony, Durgakund,

Nagwa, Varanasi, Uttar Pradesh 221005, India

Lat 25.289143°

Long 82.993398°

27/10/22 10:35 AM GMT +05:30



PANACEA HOSPITAL

B 36/44 F.K KABIR NAGAR, DURGAKUND
TOLLFREE NO-18001233070.
Whatsapp No - 8795832852
www.piire.org



OP Slip

Print Date : 27-Oct-2022 11:36AM



UHID No	:- UD-22230002320	OP No	:- OP-22230008901	OP Date	:- 27 Oct 2022 11:36AM
Patient Name	:- Mr SUNIL KUMAR	Age/Sex	:- 39 Y/Male	Mobile No	:- 7021244917
Father	:- SADAMA SINGH	Department	:- OPHTHALMOLOGY		
Pay Type	:- Cash	Consultant	:- Dr SUNNY GUPTA (MBBS,MS)		
Token No	:- NOR. - 2	Paid/Bal	:- 0.00 /30.00		
Patient Type	:- Normal				
Address	:- PANCHWATI RAMNAGAR, varanasi				

BP :-
height :-
Weight (kg) :-
BMI :-

Rx

Ch: Came for Regular
Eye checkup.

09/1

R/E → W/R

✓ 6/6
6/6

NU = NB

Printed By : Mr NITIN YADAV

Created By : Mr NITIN YADAV


Panacea HOSPITAL
 Regd. No. AL-1500
 and Diabetes Care Organization
 an ISO 9001-2008 Certified Organization

The Patient Loyalty Card


Name _____
 UHID/ IP No. _____ Age/Sex _____
 Address _____ Date _____

Card Benefit & Cash Back for Regular Patients

- 10% discount on medicine
- 15000 INR discount over 207.
- Regular Patient support VC, diet, camp benefit)


(Near Sanjay Siksha Niketa)
 panaceainquiry@gmail.com
 www.paire.org

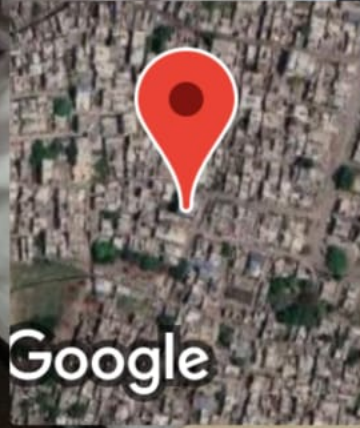SCOPE OF LABORATORY SERVICES
 हमारी और प्रयोगशाला सेवाएं

TEST NAME	TEST NAME
HEMATOLOGY	HEMATOLOGY
COAGULATION TEST	COAGULATION TEST
BIOCHEMISTRY	BIOCHEMISTRY
BIOCHEMISTRY	BIOCHEMISTRY
BIOCHEMISTRY	BIOCHEMISTRY
MICROBIOLOGY	MICROBIOLOGY

Healthy...




GPS Map Camera



Varanasi, Uttar Pradesh, India

B36/44B-3, Padampuri Colony, Durgakund,
 Nagwa, Varanasi, Uttar Pradesh 221005, India
 Lat 25.28917°

Long 82.993373°
 27/10/22 09:42 AM GMT +05:30

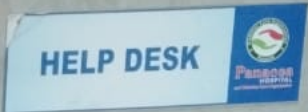


Penacee Hospital

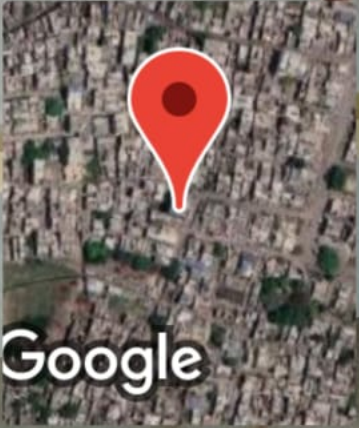Helter For Many Hearts

Home For Many Lives

Penacee Care Organisation



 GPS Map Camera



Google

Varanasi, Uttar Pradesh, India


B36/44B-3, Padampuri Colony, Durgakund,
Nagwa, Varanasi, Uttar Pradesh 221005, India

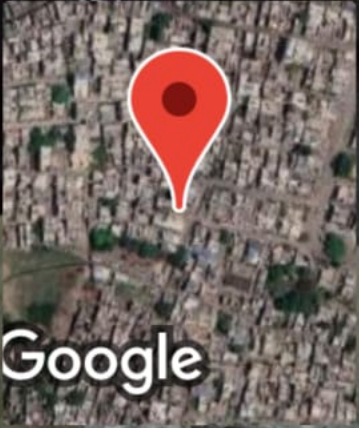Lat 25.289166°

Long 82.993386°

27/10/22 09:38 AM GMT +05:30



 GPS Map Camera



Varanasi, Uttar Pradesh, India

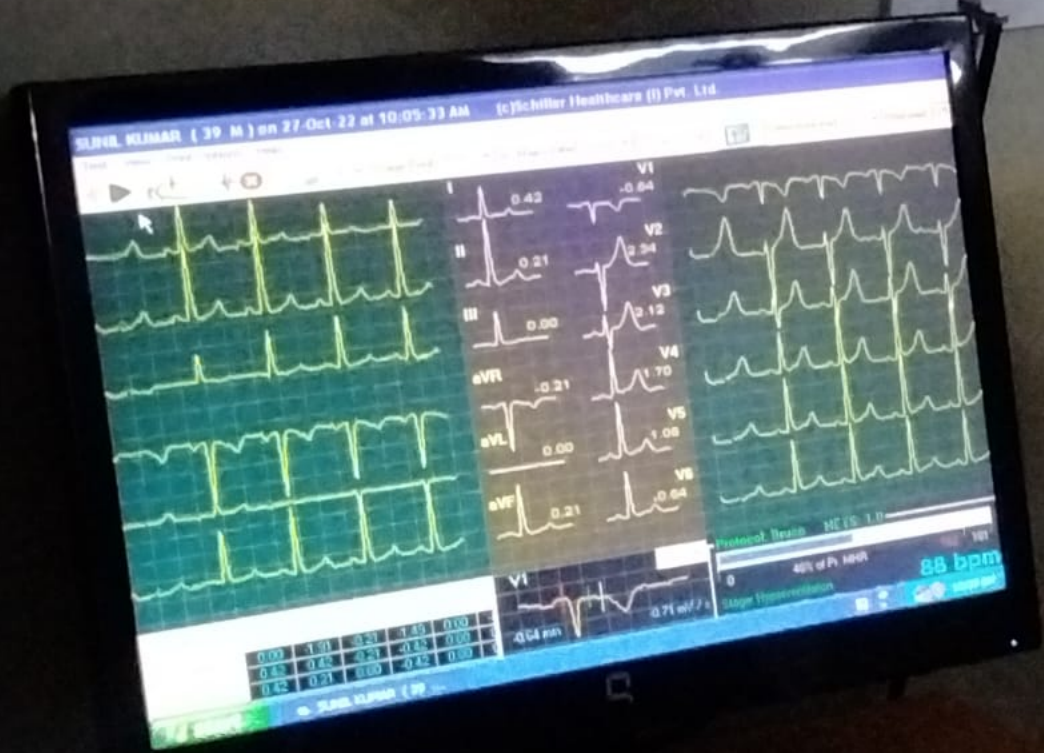
B36/44BA-4, Durgakund, Bhelupur,

Varanasi, Uttar Pradesh 221001, India

Lat 25.289041°

Long 82.993317°

27/10/22 10:04 AM GMT +05:30



GPS Map Camera



Varanasi, Uttar Pradesh, India

B36/44BA-4, Durgakund, Bhelupur,

Varanasi, Uttar Pradesh 221001, India

Lat 25.289116°

Long 82.993407°

27/10/22 10:04 AM GMT +05:30

Google



PANACEA HOSPITAL

A shelter for many hearts A Home for many lives

(An ISO 9001:2008 Certified Organisation)

Lab Attached with CMC Vellore Under EQAS Scheme

NAME: MR.SUNIL KUMAR

AGE/SEX: 39 YRS / MALE

REF BY: DR. ASHUTOSH MISHRA (MD)

DATE: 27/10/2022

ULTRA SOUND WHOLE ABDOMEN REPORT

Liver: Normal in shape and size(11.5 cm) and shows smooth and regular margin.
No diffuse/focal lesion seen.

Gall bladder: Normal distended with normal wall thickness and echo-free lumen.

CBD diameter Visualized part normal in course & caliber.

Pancreas: Normal in size, shape & echogenicity.
Margins are smooth & regular.
No diffuse/ focal lesion seen. Pancreatic tail obscured.

Spleen: Normal in siz(10.8 cm), shape & echogenicity.
Margins are smooth & regular. No diffuse / focal lesion seen.
Splenic vessels at hilum is normal.

Kidney: Right kidney: 9.6 X 5.2 cm
Left kidney: 10.9 X 6.8 cm
Both normal in size, shape, echogenicity & position.
Cortical-medullary differentiation is maintained.
Pelvicalyceal system normal.
No calculus/mass lesion seen.
No hydronephrosis/ hydroureter seen.
No suprarenal mass lesion.

Address : Kabir Nagar (Near Sanjay Shiksha Niketan), Durgakund, Varanasi

Mobile : 9554572190 / 9453837595 / Recpn. 9389994334

E-mail : dramishra@gmail.com, drpallaviojha@gmail.com, **Website:** www.piire.org



PANACEA HOSPITAL

A shelter for many hearts A Home for many lives

(An ISO 9001:2008 Certified Organisation)

Lab Attached with CMC Vellore Under EQAS Scheme

Urinary bladder: Normally distended, wall thickness is normal.
No echogenic foci lumen or diverticula seen.
Both VUJ appears normal.
No E.R. calculus / mass lesion seen.

Prostate: Normal in size, shape, & echogenicity.
No calcification or focal cystic lesion seen.
Capsular margins are smooth and regular.
Seminal vesicles appear normal in size, shape & echogenicity.
No diffuse /focal lesion seen.

Others: No free fluid in peritoneal cavity.
No free fluid in bilateral pleural cavity.

IMPRESSION:


- **NO SIGNIFICANT SONOLOGICAL ABNORMALITY DETECTED.**

Please correlate clinically and further investigations.

DR. PALLAVI MISHRA
MBBS MD(MED) Lucknow
Echocardiography specialist, MIAE
Non invasive cardiologist
Women cardiologist


Radiologist

Dr. Tusharika Rai
MBBS MS

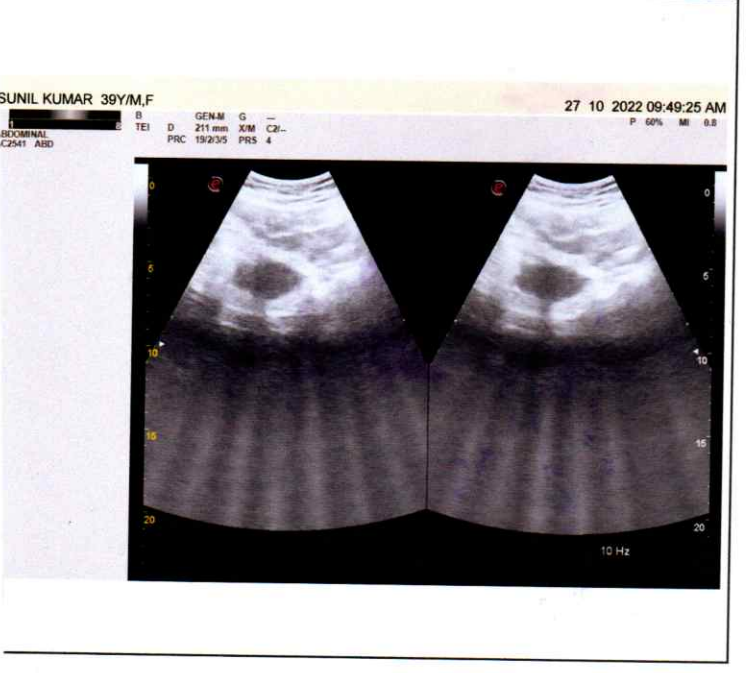
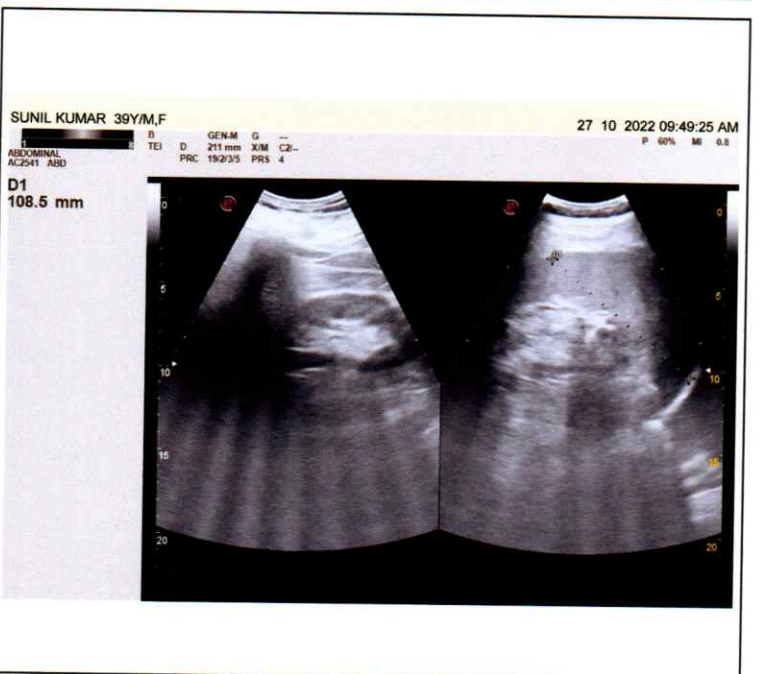
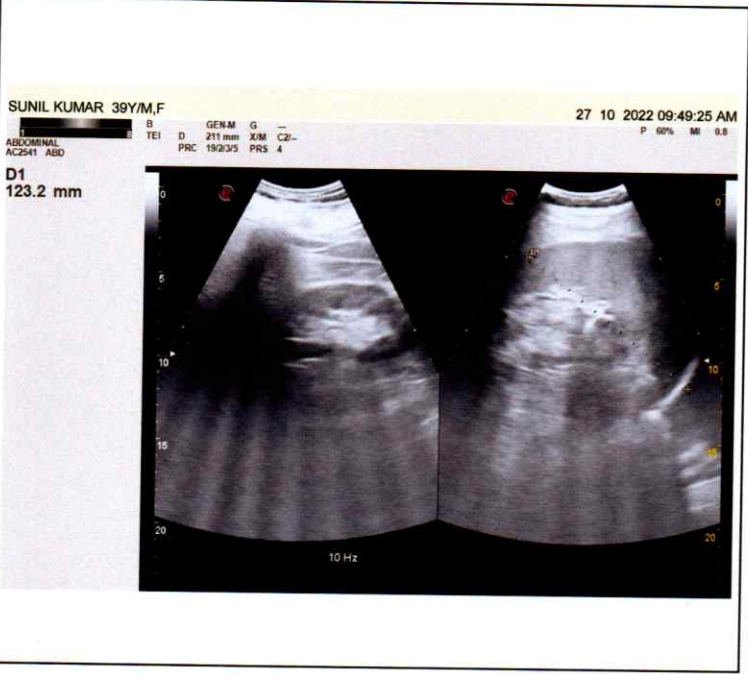
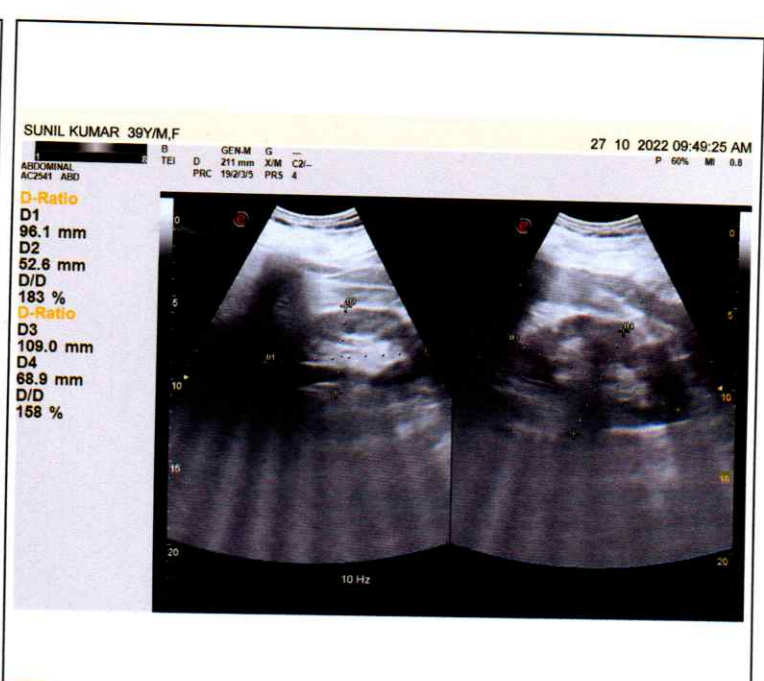
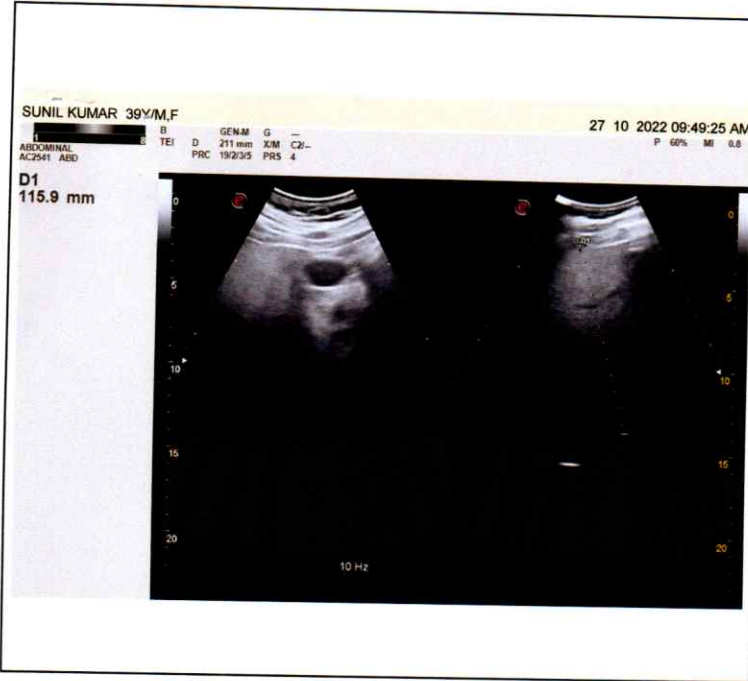
NIRAJ MISHRA
(Physician Assistant)
(PIIRE)

PANACEA HOSPITAL
(A UNIT OF AAROHA HEALTH CARE PVT. LTD.)
REG. NO.: AL-1500
B.36/44, B-4, KABIR NAGAR
DURGAKUND, VARANASI

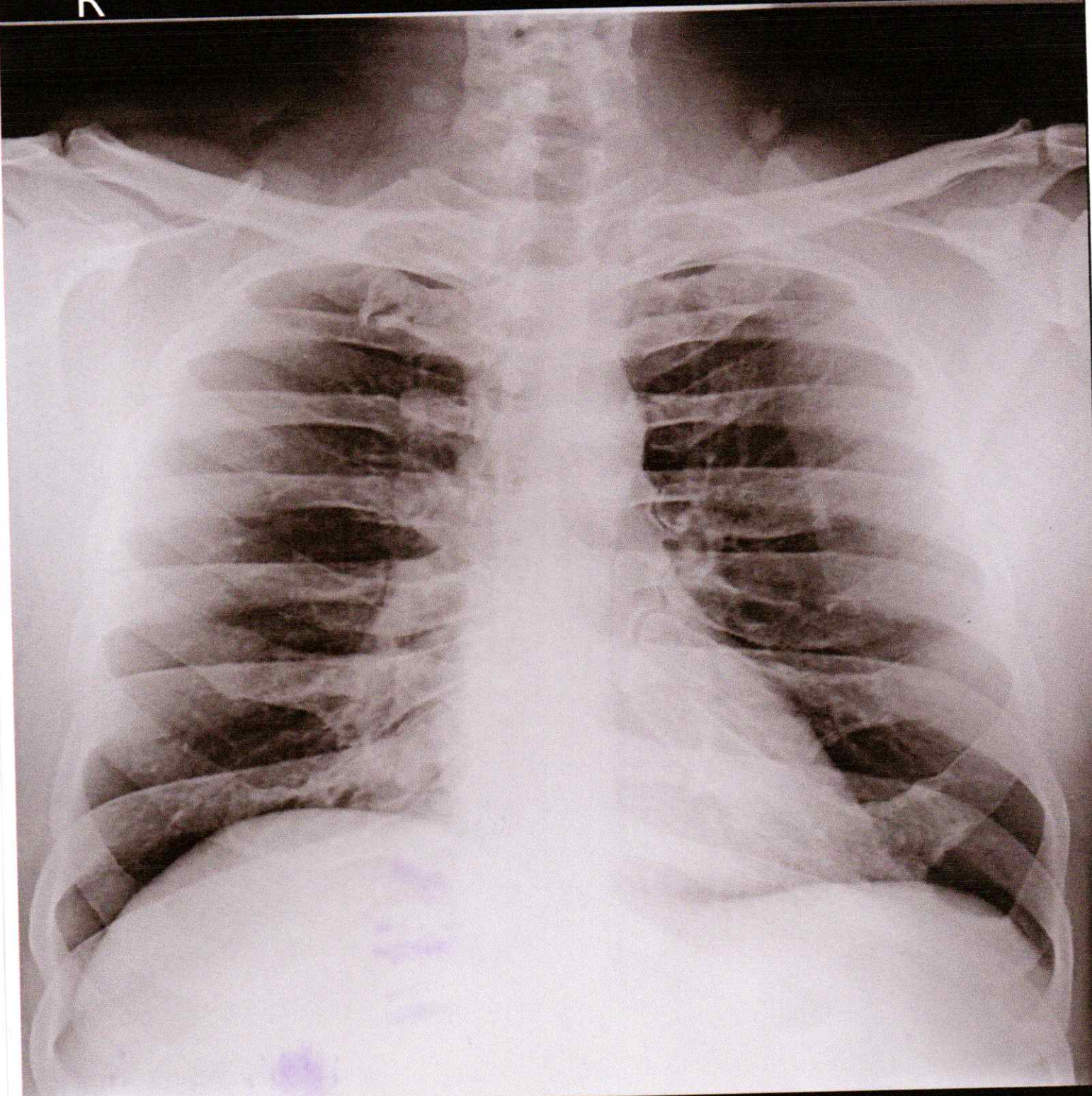
Address : Kabir Nagar (Near Sanjay Shiksha Niketan), Durgakund, Varanasi

Mobile : 9554572190 / 9453837595 / Recpn. 9389994334

E-mail : dramishra@gmail.com, drpallaviojha@gmail.com, Website: www.piire.org



R



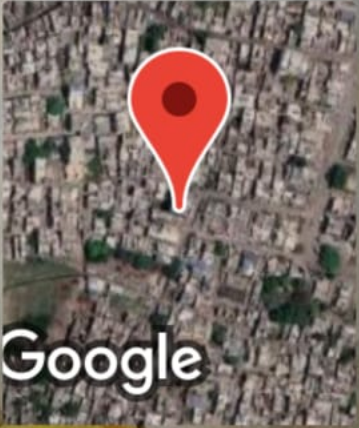
SUNIL KUMAR 39Y/M 1236 O CHEST P.A. 27-Oct-22 10:21 AM

PANACEA HOSPITAL, KABIR NAGAR, DURGAKUND, VARANASI

TAT IN HOURS*
20 Min.
20 Min.
20 Min.
20 Min.
25 Min.
20 Min.
20 Min.
20 Min.
20 Min.
20 Min.
25 Min.
20 Min.
20 Min.
15 Min.
15 Min.
20 Min.
60 Min.
45 Min.
45 Min.
2 Hours
1 Hrs. 30 Min.
45 Min.
30 Min.
60 Min.
20 Min.



 GPS Map Camera



Google

Varanasi, Uttar Pradesh, India

B36/44B-A-R, Padampuri Colony, Durgakund,
Nagwa, Varanasi, Uttar Pradesh 221005, India

Lat 25.289153°

Long 82.993373°

27/10/22 10:32 AM GMT +05:30