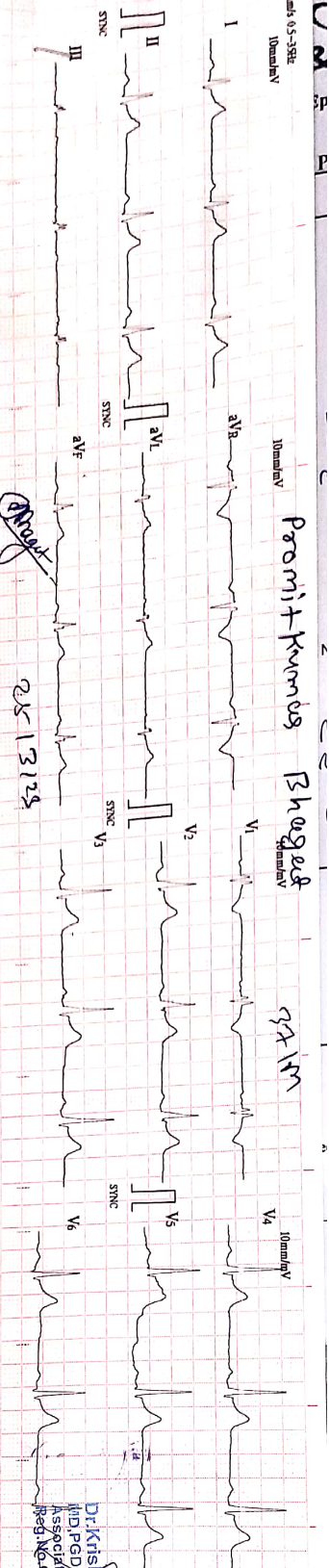

Premi Kumar Bhagat

27/11

Dr. Krish P. Vaidya
 MD, PGDCC
 Consultant-Cardiology
 Reg. No. G-50510

Unconfirmed report. Verified by:



HR : 59 bpm
 R-R : 1009 ms
 P-R : 186 ms
 QRS : 100 ms
 QT/QTc : 364/36.2 ms
 P/QTs/T : 65/56/30 ms
 RV5/SVL : 1.240/0.250 mV
 RV5+SVL : 1.490 mV

Age : 33
 Sex : M
 ID : 0157
 Name :
 Address :
 Phone :
 Email :
 Date : 27/11/2011

Heart & General Clinic

Icure Heart & Diet Clinic, 402, Epsilon tower, opp Pasha bhai park, Race course, Vadodara

:: PERSONAL HEALTH REPORT ::

Promit Kumar Bheget

*DATE 25/3/23

SR. NO.
SEX. Male
AGE 37yrs
HEIGHT 176cm
WEIGHT 74 K.G.

HISTORY

Present History : No
Past Illness History : No Diabetes/Hypertension/Tuberculosis/Asthma/Epilepsy
Past Occupational History : No
Family History : mother diabetic
Personal History : No
Addiction : No Tobacco/Gutkha/Smoking/Alcohol

GENERAL EXAMINATION

T.P.R. : 68/min B.P. : 126/82 mm Hg :

Pallor/Icterus/Cyanosis/Varicosity/Lymph Nodes/Thyroid/Oedema/NVE/Other :

SYSTEMIC EXAMINATION

R.S. : NAD
C.V.S. : NAD
C.N.S. : NAD
A.S. : NAD
Musculo-skelet System : NAD



| | | ACUITY OF VISION | | RT EYE | LT EYE |
|-------------|-----|----------------------|---------|--------|--------|
| | | Without Glass | DISTANT | 6/6 | 6/6 |
| E.N.T. Ex. | NAD | | Near | 6/6 | 6/6 |
| Dental Ex. | NAD | | DISTANT | 6/ | 6/ |
| Skin Ex. | NAD | With Glass | Near | 6/ | 6/ |
| Psychic Ex. | NAD | | | | |
| | | COLOUR BLINDNESS NAD | | | |

REMARK

ADVICE

The Worker is FIT/UNFIT for the assigned job.

Dr. Krish P. Vaidya
MD, PGCC
Associate Consultant-Cardiology
Reg. No. G-50510 DR. KRISH VAIDYA

MD G-50510, CH

भारत सरकार
GOVERNMENT OF INDIA

प्रोमित कुमार भगत
Promit Kumar Bhagat
जन्म तिथि/ DOB: 18/01/1986
पुरुष / MALE

5975 6040 5161

आधार-आम आदमी का अधिकार

Handwritten signature





BARODA DIAGNOSTIC LABORATORY



* 2 8 3 5 1 *

Patient's name : Promitkumar Bhagat
Age/Sex : 38 Years/Male
Referred by : C/o. I Cure Heart & Diet Clinic
Sample From : LAB
UHID :

Reg. ID : icure-887-19
Accession : 28351
Reg. Date : 25/03/2023
Collection Time : 25/03/2023 14:20

COMPLETE BLOOD COUNT

Sample Type: EDTA

| Test Name | Result | Units | Biological Reference Interval |
|---------------------------|-------------|-----------|-------------------------------|
| Blood Counts | | | |
| Haemoglobin : | 13.0 | Gms% | 13.5 - 18.0 |
| Total R.B.C. : | 4.42 | mill/c.mm | 4.7 - 6.0 |
| Total W. B. C. : | 7800 | /cu mm | 4000 - 10500 |
| Platelet Count : | 315000 | /cu.mm | 1,50,000 - 4,50,000 |
| Differential Count | | | |
| Neutrophils : | 62 | % | 40 - 70 |
| Lymphocytes : | 35 | % | 20 - 40 |
| Eosinophils : | 01 | % | 1 - 4 |
| Monocytes : | 02 | % | 2 - 6 |
| Basophils : | 00 | % | 0 - 01 |
| Blood Indices | | | |
| P. C. V : | 36.9 | % | 42 - 52 |
| M. C. V. : | 83.5 | fl | 78 - 100 |
| M.C.H : | 29.4 | pg | 27 - 31 |
| M. C. H. C : | 35.2 | % | 32 - 36 |
| R.D.W : | 12.1 | % | 11.5 - 14.0 |

E.S.R.(Westergren Method)

After one hour : **8** mm 1 - 7

Remark : Sample received from I cure Heart & Diet Clinic

LAB

LAB USE ONLY (Entered by :AP

Enter Date/Time:25/03/2023 2:04:11 PM) (Verify by :
24/7 365 DAYS

Dr Harsh Rautya (MD)

Dr. Priya Kriplani (MD)

Consultant Pathologist
Reg. No.: G-32582

Consultant Pathologist
Reg. No.: G-46004

302, Trivia Complex, Natubhai Circle, Race Course, Vadodara. ☎: +91 88660 09950 / 74050 09950 ✉: bdl95950@gmail.com

Laboratory results serve as an aid to diagnosis & should be interpreted in relation to clinical findings. Please refer back to laboratory in case of any discrepancy.



Scanned with OKEN Scanner



BARODA DIAGNOSTIC LABORATORY



* 2 8 3 5 1 *

Patient's name : Promitkumar Bhagat
Age/Sex : 38 Years/Male
Referred by : C/o. I Cure Heart & Diet Clinic
Sample From : LAB
UHID :

Reg. ID : icure-887-19
Accession : 28351
Reg. Date : 25/03/2023
Collection Time : 25/03/2023 14:20

THYROID FUNCTION

Sample Type: Serum

| Test Name | Result | Units | Biological Reference Interval |
|------------|---|-------|-------------------------------|
| TOTAL T3 : | 1.59 | ng/ml | 0.84 - 2.0 |
| TOTAL T4 : | 8.09 | ug/dl | 5.1 - 14.0 |
| TSH : | 2.45 | mIU/L | 0.25 - 5.0 |
| Remark : | Sample received from I cure Heart & Diet Clinic | | |

Method : CLIA

RENAL FUNCTION TEST

| Test Name | Result | Units | Biological Reference Interval |
|--------------------|--------|-------|-------------------------------|
| Urea : | 20 | mg/dl | 10 - 50 |
| Bun (Calculated) : | 9.3 | mg/dl | 0 - 18 |
| Creatinine : | 0.95 | mg/dl | 0.4 - 1.5 |
| Uricacid : | 4.29 | mg/dl | 3.4 - 7.0 |
| BUN CREAT RATIO : | | | 10:1 - 20:1 |

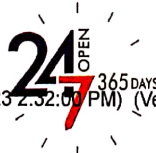Remarks : Sample received from I cure Heart & Diet Clinic

Done on Fully automated biochemistry analyser - COBAS C 111

LAB

LAB USE ONLY (Entered by : AP

Enter Date/Time: 25/03/2023 2:32:00 PM)



(Verify by : OP1

Verify Date/Time: 25/03/2023 2:33:00 PM)

Dr Harsh Pandya

Consultant Pathologist

Reg. No.: G-32582

Dr. Priya Kriplani

Consultant Pathologist

Reg. No.: G-46004





BARODA DIAGNOSTIC LABORATORY



* 2 8 3 5 1 *

Patient's name : Promitkumar Bhagat
Age/Sex : 38 Years/Male
Referred by : C/o. I Cure Heart & Diet Clinic
Sample From : LAB
UHID :

Reg. ID : icure-887-19
Accession : 28351
Reg. Date : 25/03/2023
Collection Time : 25/03/2023 14:20

LIVER FUNCTION TEST

Sample Type: Serum

| Test Name | Result | Units | Biological Reference Interval |
|------------------------------|--------|--------|-------------------------------|
| S.G.P.T (ALT) : | 10 | U/L | 0 - 40 |
| S.G.O.T (AST) : | 28 | U/L | 0 - 37 |
| ALK.PHOSPHATASE : | 50 | U/L | 40 - 130 |
| G.G.T : | 18.9 | U/L | 8 - 78 |
| <u>Bilirubin</u> | | | |
| Total : | 0.50 | mg/dl | 0.2 - 1.0 |
| Direct : | 0.20 | mg/dl | 0 - 0.6 |
| Indirect : | 0.30 | mg/dl | 0 - 0.5 |
| <u>Serum Proteins</u> | | | |
| Total Protein : | 6.99 | gms/dl | 6.4 - 8.3 |
| Albumin : | 4.09 | gms/dl | 3.8 - 4.4 |
| Globulins : | 2.9 | gms/dl | 2.3 - 3.5 |
| A/G Ratio : | 1.41 | | 0.9 - 2.9 |

Done on Fully automated biochemistry analyser - COBAS C 111

Dr. Priya Kriplani

LAB
LAB USE ONLY (Entered by :OP1 Enter Date/Time:25/03/2023 2:53:00 PM) (Verify by :OP1 Verify Date/Time:25/03/2023 2:53:00 PM)



Dr Harsh Pandya
(MD)
Consultant Pathologist
Reg. No.: G-32582

Dr. Priya Kriplani
(MD)
Consultant Pathologist
Reg. No.: G-46004

302, Trivia Complex, Natubhai Circle, Race Course, Vadodara. ☎: +91 88660 09950 / 74050 09950 ✉: bdl95950@gmail.com

Laboratory results serve as an aid to diagnosis & should be interpreted in relation to clinical findings. Please refer back to laboratory in case of any discrepancy.



Scanned with OKEN Scanner



BARODA DIAGNOSTIC LABORATORY



Patient's name : Promitkumar Bhagat
Age/Sex : 38 Years/Male
Referred by : C/o. I Cure Heart & Diet Clinic
Sample From : LAB
UHID :

Reg. ID : icure-887-19
Accession : 28351
Reg. Date : 25/03/2023
Collection Time : 25/03/2023 14:20

HbA1C REPORT

Sample Type: EDTA

| Test Name | Result | Units | Biological Reference Interval |
|---|--------|-------|---|
| HbA1C : | 5.19 | % | Excellent control: 4.2-6.2 Good Control : 6.3-7.2 Fair Control : 7.3-8.2 Poor Control : >8.3 |
| Mean Blood Glucose levels : of last 03months | 102.0 | mg/dl | |

NOTE


*As per the new 2009 update of American Diabetes Association regarding HbA1C & Mean Blood Glucose relationship.

This test is used to monitor diabetic patients compliance with the therapeutic regimen and long term blood glucose control. It's level is proportional to both the average blood glucose concentration and the life span of the red blood cells (RBC) in circulation. HbA1c values are free of day to day glucose fluctuations and are unaffected by exercise or recent food intake.

Dr. Priya Kriplani

LAB

LAB USE ONLY (Entered by : AP Enter Date/Time:25/03/2023 2:33:00 PM) (Verify by : OP1 Verify Date/Time:25/03/2023 2:33:00 PM)



Dr Harsh Pandya
(MD)
Consultant Pathologist
Reg. No.: G-32582

Dr. Priya Kriplani
(MD)
Consultant Pathologist
Reg. No.: G-46004

302, Trivia Complex, Natubhai Circle, Race Course, Vadodara. ☎ +91 88660 09950 / 74050 09950 ✉ bd195950@gmail.com

Laboratory results serve as an aid to diagnosis & should be interpreted in relation to clinical findings. Please refer back to laboratory in case of any discrepancy.



Scanned with OKEN Scanner



BARODA DIAGNOSTIC LABORATORY



* 2 8 3 5 1 *

Patient's name : Promitkumar Bhagat
Age/Sex : 38 Years/Male
Referred by : C/o. I Cure Heart & Diet Clinic
Sample From : LAB
UHID :

Reg. ID : icure-887-19
Accession : 28351
Reg. Date : 25/03/2023
Collection Time : 25/03/2023 14:20

LIPID PROFILE


Sample Type: Serum

| Test Name | Result | Units | Biological Reference Interval |
|-------------------------------|--------|-------|-------------------------------|
| Cholesterol : | 141 | mg/dl | 0 - 200 |
| Triglyceride : | 116 | mg/dL | 0 - 150 |
| HDL - Cholesterol : | 43 | mg/dL | 35 - 65 |
| LDL - Cholesterol : | 74.8 | mg/dL | 0 - 130 |
| VLDL - Cholesterol : | 23.2 | mg/dL | 0 - 30 |
| Total Cholesterol/HDL Ratio : | 3.28 | | 1 - 6 |
| LDL / HDL Cholesterol Ratio : | 1.74 | | 0 - 3.5 |

Remarks : Sample received from I cure Heart & Diet Clinic

Done on Fully automated biochemistry analyser - COBAS C 111

LAB
LAB USE ONLY (Entered by :AP Enter Date/Time:25/03/2023 2:33:00 PM) (Verify by :OP1 Verify Date/Time:25/03/2023 2:33:00 PM)



Dr Harsh Pandya
(MD)
Consultant Pathologist
Reg. No.: G-32582

Dr. Priya Kriplani
(MD)
Consultant Pathologist
Reg. No.: G-46004

302, Trivia Complex, Natubhai Circle, Race Course, Vadodara. ☎: +91 88660 09950 / 74050 09950 ✉: bdl95950@gmail.com

Laboratory results serve as an aid to diagnosis & should be interpreted in relation to clinical findings. Please refer back to laboratory in case of any discrepancy



Scanned with OKEN Scanner


Heart & General Clinic

iCure Heart& Diet Clinic, 402, Epsil on tower, opp Pasha bhai park, Race course, Vadodara

Name : PROMITKUMAR BHAGAT
Ref By : ICURE HEART & DIET CLINIC

Age/Sex : 38 Yrs./M
Date : 25/03/2023
Report ID. : 24

HAEMOGRAM PROFILE

| <u>TEST</u> | <u>RESULT</u> |
|------------------------|----------------|
| Blood Group | : * A * |
| Rh Factor (Anti D.) | : * POSITIVE * |

BIOCHEMISTRY

FASTING (FBS)

Blood Glucose : 100.0 mg/dL 70 - 110 mg/dL

POST-PRANDIAL

Blood Glucose : 108.0 mg/dL 80 - 140 mg/dL

Done By Fully Auto Analyzer MIURA, A-1004

END OF REPORT




Heart & General Clinic

iCure Heart& Diet Clinic, 402, Epsil on tower, opp Pasha bhai park, Race course, Vadodara

Name : PROMITKUMAR BHAGAT
Ref By : ICURE HEART & DIET CLINIC

Age/Sex : 38 Yrs./M
Date : 25/03/2023
Report ID. : 24

EXAMINATION OF URINE

| <u>TEST</u> | <u>RESULT</u> | <u>UNIT</u> |
|---------------------------------------|--------------------------|-------------|
| Sample | : FASTING | |
| <u>PHYSICAL EXAMINATION</u> | | |
| Quantity | : 20 | mL |
| Colour | : COLOURLESS | |
| Transperancy | : CLEAR | |
| Specific Gravity | : 1.003 | |
| Reaction | : ACIDIC | |
| Deposits | : ABSENT | |
| <u>CHEMICAL EXAMINATION</u> | | |
| Albumin | : NIL | |
| Sugar | : NIL | |
| Acetone | : ABSENT | |
| Bile Salts | : ABSENT | |
| Bile Pigments | : ABSENT | |
| Urobilinogen | : NORMAL : ~ < 1.0 mg/dL | |
| Occult Blood | : ABSENT | |
| Nitrate | : ABSENT | |
| <u>MICROSCOPIC EXAMINATION</u> | | |
| Pus Cells | : 0-1 / hpf | |
| RBC | : NIL | |
| Epithelial Cells | : NIL | |
| Crystals | : NIL | |
| Amorphous Phosphate | : NIL | |
| Cast | : NIL | |



END OF REPORT



 icure™
Heart & General Clinic

| | | |
|-------------------------|-------------|-------------------|
| NAME : Mr Promit Bhagat | AGE : 37Y/M | DATE : 25/03/2023 |
|-------------------------|-------------|-------------------|

ULTRASONOGRAPHY OF WHOLE ABDOMEN
(Screening Only)

Liver is normal in size and echotexture and shows normal parenchymal reflectivity. No focal lesion is seen. Hepatic veins appear normal. There is no evidence of any dilated intra hepatic biliary radicals.

Portal Vein appears normal in diameter.

Common Bile Duct is of normal diameter.

Gallbladder is physiologically distended with normal wall thickness. There is no evidence of gallstones. No evidence of peri-cholecystic fluid or probe tenderness.

Pancreas is normal in size and shows homogenous reflectivity. There is no evidence of any calcification or ductal dilatation.

Spleen is normal size and shows a homogenous echotexture. There is no evidence of any focal lesion.

Both Kidneys are normal in position and size. They show normal cortical reflectivity and cortico-medullary distinction. Right kidney measures 96x41mm. Left kidney measures 95x46mm. There is no evidence of calculi, hydronephrosis or mass seen.

Bladder is well distended and shows normal wall thickness. No evidence of intra-luminal mass or calculi.

Prostate gland is normal in size . it has smooth outlines and normal reflectivity


There is no evidence of ascites.

No evidence of any gross bowel mass seen.

No evidence of any aorto-caval or mesenteric root lymphadenopathy.

No mass or collection in right iliac fossa.

Conclusion : No Sonographic abnormality seen.


Dr. Krish P. Vaidya
MD, PGDCC
Associate Consultant-Cardiology




DR. MEHUL PRAJAPATI
CONSULTANT RADIOLOGIST




Heart & General Clinic

2D Echocardiography & Color Doppler Report

iCure Hear care, 402, Epsilon tower, opp Pasha bhai park, Race course, Vadodara

Patient Name: Mr Promit Bhagat

Dates: 25 / 03 / 2023

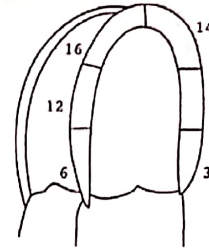
Age Gender: male - 37 Years

M. Mode Study:

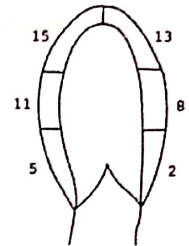
| | | | | | |
|-----------|-----------|-------------|-----------|-------------|-----------|
| LA | 36 | IVS | 10 | PWD | 10 |
| AO | 25 | LVDs | 26 | LVDd | 48 |

Doppler Study:

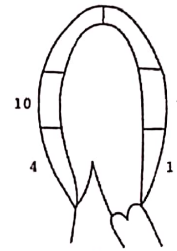
| | |
|------------------------|------------------------|
| Mitral Valve | E: 0.85 A: 0.62 |
| Aortic Valve | Normal |
| Tricuspid Valve | Normal |
| Pulmonary Valve | Normal |



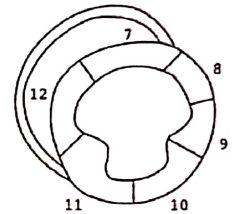
Apical
4 chamber view



Apical
2 chamber view



Apical
3 chamber view



Parasternal short
axis view

Conclusion:

- Normal LV Systolic function
- LVEF: 60 % ,No RWMA
- Cardiac Chambers: Normal
- Diastolic function: Normal
- TR: No PAH: No RVSP: 15mmhg
- No Ms , No MR
- No AR , No AS
- ASD/VSD/PDA/Co-A : No
- No Clots or vegetations found
- IVC: 09mm size with Normally collapsive



Dr. Krish P. Vaidya
MD, PGDCC

Associate Consultant-Cardiologist

Dr. Krish P Vaidya

**Consultant Cardiologist, Diabetologist
& General Physician**

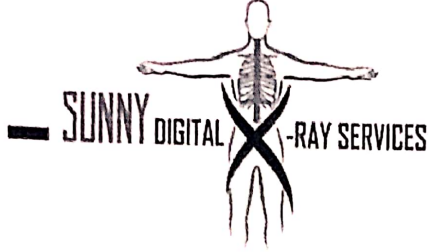
Note:

Normal 2D echo report does not rule out cardiac diseases
this report shall not be used for Medico legal purposes,
Clinical Correlation advisable.



 **icure™**
Heart & General Clinic

iCure Heart& Diet Clinic, 402, Epsil on tower, opp Pasha bhai park, Race course, Vadodara



Sunny K. Machhi
+91 87585 30074
+91 83205 61551
sunnydigitalxray@yahoo.com

| | | | |
|---------------|----------------------------|----------------|------------|
| NAME | PROMITKUMAR BHAGAT | AGE/SEX | MALE |
| REF BY | I CURE HEART & DIET CLINIC | DATE | 25-03-2023 |

X-RAY CHEST PA VIEW

BOTH LUNG FIELDS ARE NORMAL.

BOTH COSTOPHRENIC RECESS ARE CLEAR.

CARDIAC CONFIGURATION IS NORMAL.

MEDIASTINUM AND BONY THORACIC CAGE REVEAL NO ABNORMALITY.

IMPRESSION : NORMAL LUNGS HEART AND MEDIASTINUM



DR.HIMANI VIRAPARA
Regn. No: G.28771
M.D. [Radiodiagnosis]
(CONSULTANT RADIOLOGIST)

