



A.L.C. Advance Imaging Dignostics

(A Unit of Subham Imaging P.K. Arogyam Health & Wellness Center)

E-95, P.C. Colony, Near Sai Netryalaya Transformer, Kankarbagh, Patna - 20

alcingnastics@gmail.com

www.pkarogyamhealthcheckup.com

7880027494, 9277206174

OPINION MUST BE CORRELATES WITH CLINICALLY & OTHER INVESTIGATION FOR FINAL DIAGNOSIS. NOT FOR MEDICO LEGAL PURPOSE

Pt. Name :- **SANJEEV KUMAR**
Ref. By :- **DR. MEDIWHEEL**

Date:- **8-Oct-22**
Age / Sex - **35 Yrs. M.**

REAL TIME U.S.G. OF WHOLE ABDOMEN

Thanks for your kind referral

(Report.)

- LIVER** :- Measures 14.54 cm. Mild Enlarged in shape , size and echo texture fatty change seen in liver parenchyma .I.H.B.R. are not dilated.
Hepatic veins are normal. No SOL seen.
- G.BL** :- Lumen is echo free. Wall thickness appears normal.
- C.B.D.** :- Measures 3.5 mm in diameter with echo free lumen. No calculi or mass seen.
- P.V.** :- Measures 7.7 mm in diameter. Appears normal. No thrombus seen.
- PANCREAS** :- Normal in shape, size and echo texture. No calcification mass seen.
- SPLEEN** :- Measures 11.18 cm. Normal in shape, size and echo texture.
No SOL seen.
- KIDNEY** :- Both kidney shows normal shape, size & echotexture. C.M.D.intact.
P.C.S.is not dilated.
Right Kidney :- Measures 9.50 X 3.50 cm.
Left Kidney :- Measures 9.60 X 3.50 cm.
- URETER** :- Not dilated. No apparent calculi seen.
- U.BLADDER**:- Shows normal in outline with echo free lumen. No calculi or mass seen.
Pre void - ml. Post void - is in significant
- PROSTATE** :- Measures 15 gms.(approx). Appears Normal in size, shape, and echo texture.
No calcification , mass ,growth seen. capsule is intact.
- R.I.F.** :- Son graphically no appendicular mass or collection seen.
- OTHERS** :- No Ascites . no Lymph Adenopathy. No pleural effusion seen on either side .

IMPRESSION

- *Mild Hepatomegaly With fatty liver G-I*
- *Adv:- Further work up other investigation*
- *Otherwise son graphically normal scan. of rest organs*



S/10/22

Consultant Radiologist

ESTD BY:

Dr. P. K. Tiwari
MD, M.Sc (Radio Imaging)
Ph.D (AS Nuclear Medicine)
Consultant Imaging Radiologist & Sonologist

Dr. S. Kumar
MD (P&E)
Consultant Pathologist

Dr. Abhishek Kumar
MBBS, MD
Consultant Neuropatho Physiologist

Dr. Kumari Suman
MBBS, DGO, MD
Consultant (TVS & HSG Specialist)

Dr. A. K. Singh
MBBS, PGDMCH
Consultant Radiologist

PRINTING MISTAKE SHOULD BE REPORTED BACK IMMEDIATELY/ यहाँ जन्म से पहले भुण का लिए जाँच नहीं है



A.L.C. Advance Imaging Dignostics

(A Unit of Subham Imaging P.K. Arogyam Health & Wellness Center)

E-95, P.C. Colony, Near Sai Netryalaya Transformer, Kankarbagh, Patna - 20

alcdiagnostics@gmail.com

www.pkarogayamhealthcheckup.com

7030037494 8271206196

OPINION MUST BE CORRELATES WITH CLINICALLY & OTHER INVESTIGATION FOR FINAL DIAGNOSIS. NOT FOR MEDICO LEGAL PURPOSE

PATIENT NAME : Mr. SANJEEV KUMAR

PATIENT ID: 2056

COL DATE : 08/10/2022

REPORTING DATE: 08/10/2022

AGE SEX : 35 YRS/M

REF.BY : DR. / MEDIWHEEL

TEST NAME	RESULT	Unit	REF.RANGE
BLOOD SUGAR (F)	130.0	mg/dl	70 -110 mg/dl
LIPID PROFILE:-			
TOTAL CHOLESTROL	170.6	mg/dl	130 -250 mg/dl
TRIGLYCERIDE	175.2	mg/dl	50 -160 mg/dl
HDL CHOLESTROL	42.0	mg/dl	30 - 60 mg/dl
LDL CHOLESTROL	93.6	mg/dl	80 -130 mg/dl
VLDL CHOLESTROL	35.0	mg/dl	15 - 40 mg/dl
T.CH./HDL RATIO	4.0 : 1		Upto 5 :1
LDL /HDL RATIO	2.2 : 1		2 - 4:1

Dr. Anshu K
Consultant Radiologist

ESTD BY:-

Dr. P. K. Tiwari

MD, M.Sc (Radio Imaging)
Ph.D (Air Nuclear Medicine)

Consultant Imagingologist & Sonologist

Dr. S. Kumar

MD (Pat)
Consultant Pathologist

Dr. Abhishek Kumar

MBBS, MD
Consultant Neuropathology Physiologist

Dr. Kumari Suman

MBBS, DGO, MD
Consultant (TVS & HSG Specialist)

Dr. A. K. S

MBBS, PGDMCH
Consultant Radiologist

PRINTING MISTAKE SHOULD BE REPORTED BACK IMMEDIATELY/ यहाँ जन्म से पहले भ्रूण का लिंग जो



A.L.C. Advance Imaging Dignostics

(A Unit of Subham Imaging P.K. Arogyam Health & Wellness Center)

E-96, P.C. Colony, Near Sai Netryalaya Transformer, Kankarbagh, Patna - 20

alcdiagnostics@gmail.com

www.pkarogyaanhealthcheckup.com

734007744 427128194

OFFICE HOURS: 9 AM TO 6 PM (MON-SAT) MEDICO LEGAL PURPOSE

PATIENT NAME: MR. SANJEEV KUMAR OTHER INVESTIGATION FOR FINAL (PATIENT ID: 7056)

COL DATE: 08/10/2022 REPORTING DATE: 08/10/2022 AGE SEX:- 35 YRS/M

REF. BY: DR. / MEDIWHEEL

TEST NAME	RESULT	Unit	REF. RANGE
-----------	--------	------	------------

LFT:-

SGPT	97.4	IU/L	5 - 40 IU/L
S G O T	51.7	IU/L	5 - 40 IU/L
ALKALINE PHOSPHATASE	101.3	IU/L	M - 53 - 165 IU/L F - 42 - 136 IU/L
TOTAL PROTIN	7.9	g/dl	6.0 - 8.7 g/dl
SERUM ALBUMIN	4.8	g/dl	3.5 - 5.4 g/dl
SERIUM GLUBLINE	3.1	g/dl	2.3 - 3.6 g/dl
AG RATIO	1.5:1		1.0 - 2.3 g/dl
BILIRUBIN			
TOTAL	0.77	mg/dl	0.1 - 1.1 mg/dl
DIRECT	0.30	mg/dl	0.0 - 0.32 mg/dl
INDIRECT	0.47	mg/dl	0.0 - 0.78 mg/dl
GGTP(GGT)	23.6	iu/L	8 - 38 iu/L

KFT/RFT

URIC ACID	5.1	mg/dl	3.2 - 7.0 mg/dl
SERUM CREATNINE	1.1	mg/dl	0.6 - 1.5 mg/dl
BLOOD URIA	33.4	mg/dl	5 - 45 mg/dl
BLOOD URIA NITROZEN(BUN).	15.1	mg/dl	5 - 23 mg/dl

Dr. A. K. Singh
Consultant Radiologist

ESTD BY:-

Dr. P. K. Tiwari

MD, M.Sc (Radio Imaging)

Ph.D (In Nuclear Medicine)

Consultant Imagingologist & Sonologist

Dr. S. Kumar

MD (Pat)

Consultant Pathologist

Dr. Abhishek Kumar

MBBS, MD

Consultant Neuropatho Physiologist

Dr. Kumari Suman

MBBS, DGO, MD

Consultant (TVS & HSG Specialist)

Dr. A. K. Singh

MBBS, PGD&CH

Consultant Radiologist

PRINTING MISTAKE SHOULD BE REPORTED BACK IMMEDIATELY/ यहाँ जन्म से पहले बुन का लिग जाँच नहीं



A.L.C. Advance Imaging Dignostics

(A Unit of Saksham Imaging P.K. Ayngam Health & Wellness Center)

E-95, P.C. Colony, Near Sai Netryalaya Transformer, Kankarbagh, Patna - 20
www.patnagymnashowbackup.com

COMMON MUST BE CORRELATED WITH CLINICAL & OTHER INVESTIGATION FOR FINAL DIAGNOSIS. NOT FOR MEDICAL LEGAL PURPOSE

PATIENT NAME : Mr. SANJEEV KUMAR PATIENT ID: 2056
 COL DATE : 08/10/2022 REPORTING DATE: 08/10/2022 AGE SEX : 35 YRS/M
 REF BY : DR./ MEDIWHEEL

GLYCOSYLATED HEMOGLOBIN

TEST NAME	RESULT	Unit	REF RANGE
HbA1c	5.8 %		Below 5.7 % : Normal 5.7 – 6.4 % : Prediabetic > = 6.5 % : Diabetic
AVERAGE PLASMA GLUCOSE	129.0 mg/dl		90 – 120 mg/dl : Good Control 121 – 150 mg/dl : Fair Control 151- 180 mg/dl : Unsatisfactory Control >180 mg/dl : Poor Control

Dr. Ankur Kumar
 MBBES, MD
 Consultant Radiologist
 Reg. No. 12540
 8/10/22
 Consultant Radiologist

ESTD BY:-

Dr. P. K. Tiwari
 MD, M.Sc (Radio Imaging)
 F.R.D (As Nuclear Medicine)
 Consultant Imaging & Sonologist

Dr. S. Kumar
 MD (Pat)
 Consultant Pathologist

Dr. Abhishek Kumar
 MBBES, MD
 Consultant Neurophysiologist

Dr. Kumari Suman
 MBBES, DGO, MCh
 Consultant (TVS & MHC Specialist)

Dr. A. K. Singh
 MBBES, PGDMCH
 Consultant Radiologist (Sonologist)

PRINTING MISTAKE SHOULD BE REPORTED BACK IMMEDIATELY/ वहाँ जन्म से पहले मुण का तिग जाँच नहीं होता ।



A.L.C. Advance Imaging Diagnostics

(A Unit of Subham Imaging P.K. Arogyam Health & Wellness Center)

E-95, P.C. Colony, Near Sai Netryalaya Transformer, Kankarbagh, Patna - 20
www.pkarogyamhealthcheckup.com

OPINION MUST BE CORRELATES WITH CLINICALLY & OTHER INVESTIGATION FOR FINAL DIAGNOSIS - NOT FOR MEDICO LEGAL PURPOSE

PATIENT NAME : Mr. SANJEEV KUMAR
PATIENT ID: 2056
COL DATE : 08/10/2022 REPORTING DATE: 08/10/2022 AGE SEX : 35 YRS/M
REF.BY : DR. / MEDIWHEEL

Investigation	Result	Normal Range
Total Triiodothyronin T3	1.37 ng/mL	0.80 - 2.00 μ ng/mL
Total Thyroxin T4	9.02 ug/mL	5.10 - 14.10 ug/dl
Serum TSH	1.34 μ g/mL	0.27 - 4.20 μ g/mL

THYROID DISORDER (>: Increase: < Decrease: n Normal

1. T3(n) T4(n) TSH(n) : EUTHYROID STATE:
2. T3(>) T4(>) TSH(<): HYPERTHYROIDISM:
3. T3(<)T4(<) TSH(>): HYPOTHYROIDISM:
4. T3(n)T4(n) TSH(>) : SUB-CLINICAL HYPO-THYROIDISM:
5. T3(n)T4(n) TSH(<): SUB-CLINICAL HYPER-THYROIDISM:
6. T3(>) T4(n) TSH(<): T3 THYROTOXICOSIS:

Total T3/T4 level is dependent on Level:

So determination of free T3/T4 is a better MARKER of Thyroid Function.

*FREE T3/T4 ESTIMATION FACILITY IS AVAILABALE ON REQUEST.:

Dr. Anand Kumar
Consultant Radiologist
Reg No. 5330
8/10/22
Consultant Radiologist

ESTD BY-

Dr. P. K. Tiwari
MD, M.Sc (Radio Imaging)
B.D (Ab Nuclear Medicine)
Consultant Imagingologist & Sonologist

Dr. S. Kumar
MD (Pat)
Consultant Pathologist

Dr. Abhishek Kumar
MBBS, MD
Consultant Neuropatho Physiologist

Dr. Kumari Suman
MBBS, DGO, MD
Consultant (TVS & HSG Specialist)

Dr. A. K. Singh
MBBS, PGDMCH
Consultant Radiologist Endocrinologist

PRINTING MISTAKE SHOULD BE REPORTED BACK IMMEDIATELY/ यहाँ जन्म से पहले धुण का लिंग जाँच नहीं होता है ।



A.L.C. Advance Imaging Dignostics

(A Unit of Subham Imaging P.K. Arogyam Health & Wellness Center)
E-95, P.C. Colony, Near Sai Hridayalaya Transformer, Konkarbagh, Patna - 20

advancemagnetics@gmail.com

www.patnagayamhealthcheckup.com

Phone: 9771001786

OPINION MUST BE CORRELATES WITH CLINICALLY & OTHER INVESTIGATION FOR FINAL DIAGNOSIS. NOT FOR MEDICO LEGAL PURPOSE

PATIENT NAME : Mr. SANJEEV KUMAR
COL DATE : 08/10/2022 REPORTING DATE: 08/10/2022 AGE SEX : 35 YRS/M
REF. BY : DR. / MEDIWHEEL

PATIENT ID: 2056

TEST NAME	RESULT	Unit	REF RANGE
-----------	--------	------	-----------

BLOOD GROUP : ' O '

Rh Typing : POSITIVE

Note: Do always cross - matching before blood transfusion

Dr. Anur Kumar
MBBS, MD
Consultant Pathologist
39540
8/10/22
Consultant Radiologist

ESTD BY-

Dr. P. K. Tiwari
MD, M.Sc (Radio Imaging)
M.D (Ab Nuclear Medicine)
Consultant Imagingologist & Sonologist

Dr. S. Kumar
MD (PWI)
Consultant Pathologist

Dr. Abhishek Kumar
MBBS, MD
Consultant Neurospinec Physiologist

Dr. Kumari Suman
MBBS, DGO, MD
Consultant (TVS & HSC Specialist)

Dr. A. K. Singh
MBBS, FCIMCH
Consultant Radiologist, Endocrinologist

PRINTING MISTAKE SHOULD BE REPORTED BACK IMMEDIATELY/यहाँ जन्म से पहले भुल का त्रिग जीव नहीं होता है ।

Handwritten signature and date: 8/10/22

A.L.C. Advance Imaging Dignostics

(A Unit of Subham Imaging P.K. Arogyam Health & Wellness Center)

E-95, P.C. Colony, Near Sai Netryalaya Transformer, Kankarbagh, Patna - 20
www.pkarogayamhealthcheckup.com

PATIENT NAME : Mr. SANJEEV KUMAR

COL DATE : 08/10/2022

REF.BY : DR. / MEDIWHEEL..

PATIENT ID: 2056

REPORTING DATE: 08/10/2022

AGE SEX : 35 YRS/M

ROUTINE EXAMINATION OF URINE

PHYSICAL EXAMINATION

Quantity	40 ml	Colour....	Strow
Appearance...	Clear	Sediment ...	Nil
Specific gravity....	1.010		

CHEMICAL EXAMINATION

Reaction	6.0	Nitrite.....	Not done
Sugar	Nil	Bile Pigment ...	Not done
Albumin	Nil	Urobilinogen....	Not done
Excess of Phosphate....	Nil	Chile.....	Not done
Bile Salt	Not Done	Acetone...	Not done

MICROSCOPIC EXAMINATION

Erythrocytes....	Nil	Casts	Nil
Leucocytes	1-4 / HPE	Crystals....	Nil
Epith. Cell	A, Few	Others	Nil

[Handwritten Signature]
8/10/22

Consultant Radiologist

ESTD BY:

Dr. P. K. Tiwari
MD, M.Sc. (Radio Imaging)
M.D. (AB Nuclear Medicine)
Consultant Radiologist & Sonologist

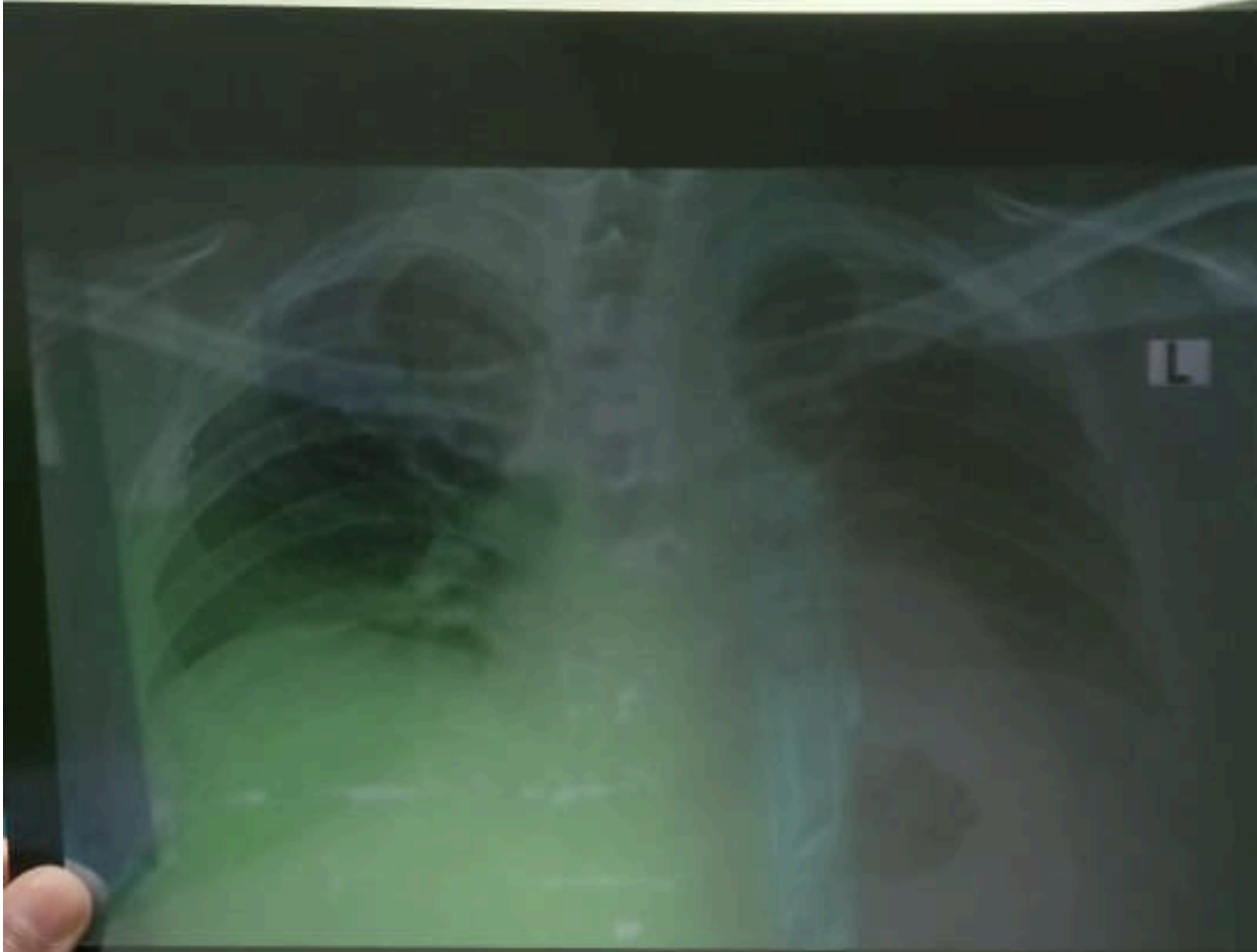
Dr. S. Kumar
MD (PUC)
Consultant Pathologist

Dr. Abhishek Kumar
MBBS, MD
Consultant Neuropatho Physiologist

Dr. Kumari Suman
MBBS, DGO, MD
Consultant (TVS & HSG Specialist)

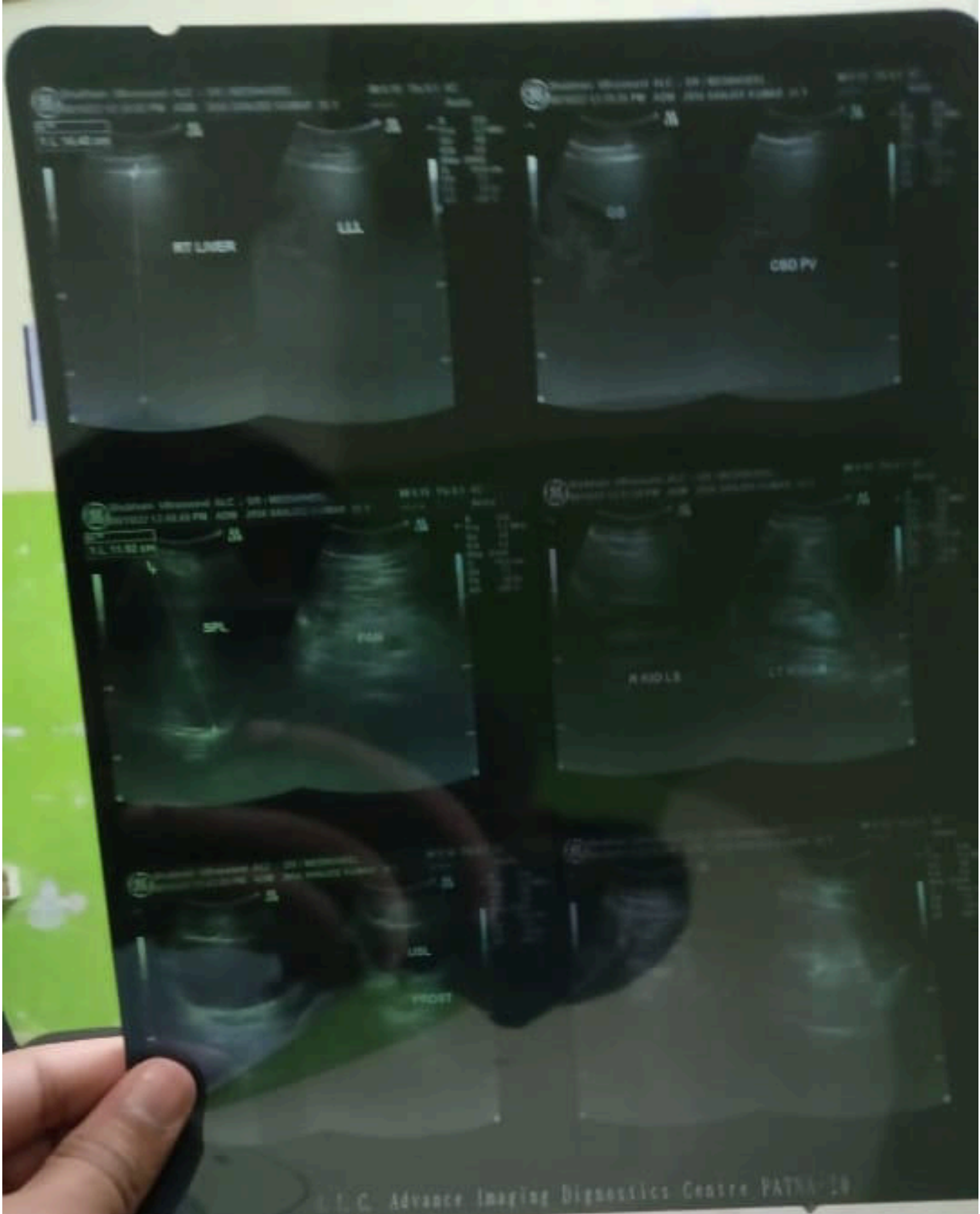
Dr. A. K. Singh
MBBS, PCDMCH
Consultant Radiologist / Sonologist

PRINTING MISTAKE SHOULD BE REPORTED BACK IMMEDIATELY/ यहाँ जन्म से पहले भ्रम का लिए जीव नहीं होता है ।



SANJEEV KUMAR AGE 35 YEARS 2556 BY DR. MEDWHEEL CHEST XRAY-14 000000
A.L.C. Advance Imaging Diagnostics Centre PATNA - 20





ANCE IMAGING DIGNOSTICS

ANJEEV KUMAR / 34 YRS / M / 166 Cms / 66 Kg / HR 187

2022 01 18 05 PM





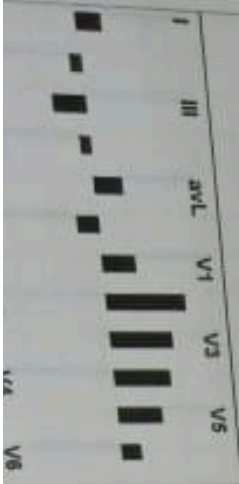
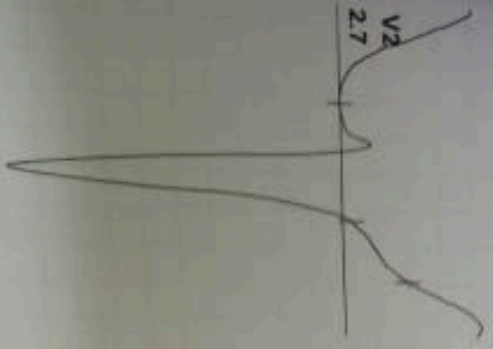
60 MB Post J

MEETS: 8.2/187 bpm 100% of THR BP 120/88 mmHg New ECG/RLD On Narda On/HR 9.95 HOLD 20 NY

BRUCE : Stage 3 (01:09)

K.S.D.

ECG Time: 05:37 3.4 rpm 14.8%
28 Leads: 1.4 Channel



(GEN13180725)(A)shengm



L.C. ADVANCE IMAGING DIAGNOSTICS

1077 / MR SANJEEV KUMAR / 34 Yrs / M / 166 Cms / 66 Kg / HR : 110

Date: 09-Oct-2022 01:18:55 PM

MEETS: 1.0/ 110 bpm 59% of THR BP- 120/80 mmHg

RR- 12/Min SpO2 96% HF 0.05 HOLD 20 Hz




EstStn



ESTIME: 00:00 63 BPM 15%
28 minutes 13 Counts

4X

00 mds Post J



REMARKS:

(GEN13180720)Aphengara

ADVANCE IMAGING DIAGNOSTICS

L.C. ADVANCE IMAGING DIAGNOSTICS

4077 / MR SANJEEV KUMAR / 34 Yrs / M / 166 Cms / 66 Kg / HR : 84

Date: 08-Oct-2022 01:18:55 PM METS: 1.0/ 84 bpm 45% of Thyr BP: 120/80 mmHg

4X 80 ms Post J

Flow ECG/ ECG On/ Hold/ On/ Hr 0.05 HALF 30 Hz

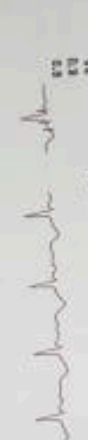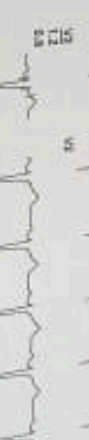STANDING



WARM UP



Expiry: 09/11/2024 18:00:00
24 Months, 10:00am



(GEN213180725)/A/Myr/qm/s

4077 / MR SANJEEV KUMAR / 34 YRS / M / 160 Cms / 66 Kg / HR 140

Date: 08 Oct 2022 01:18:35 PM

4X 40 mS Panel 1

MEETS: 4.27:150 Hz - 72% of 3000 BP: 130/85 mmHg

Flow: ECCO-BLC-Gal-Heads-Up-Dr-Dr-0.05-Half-20 Hz

BRUCE : Stage 1 (03:00)


STANDING

KLJ





KLJ

Screen: 03:00 1.7 mS / 60.9%

20 seconds / 1.82 mS



REMARKS:



026K21180780134848908

ADVANCE IMAGING DIAGNOSTICS

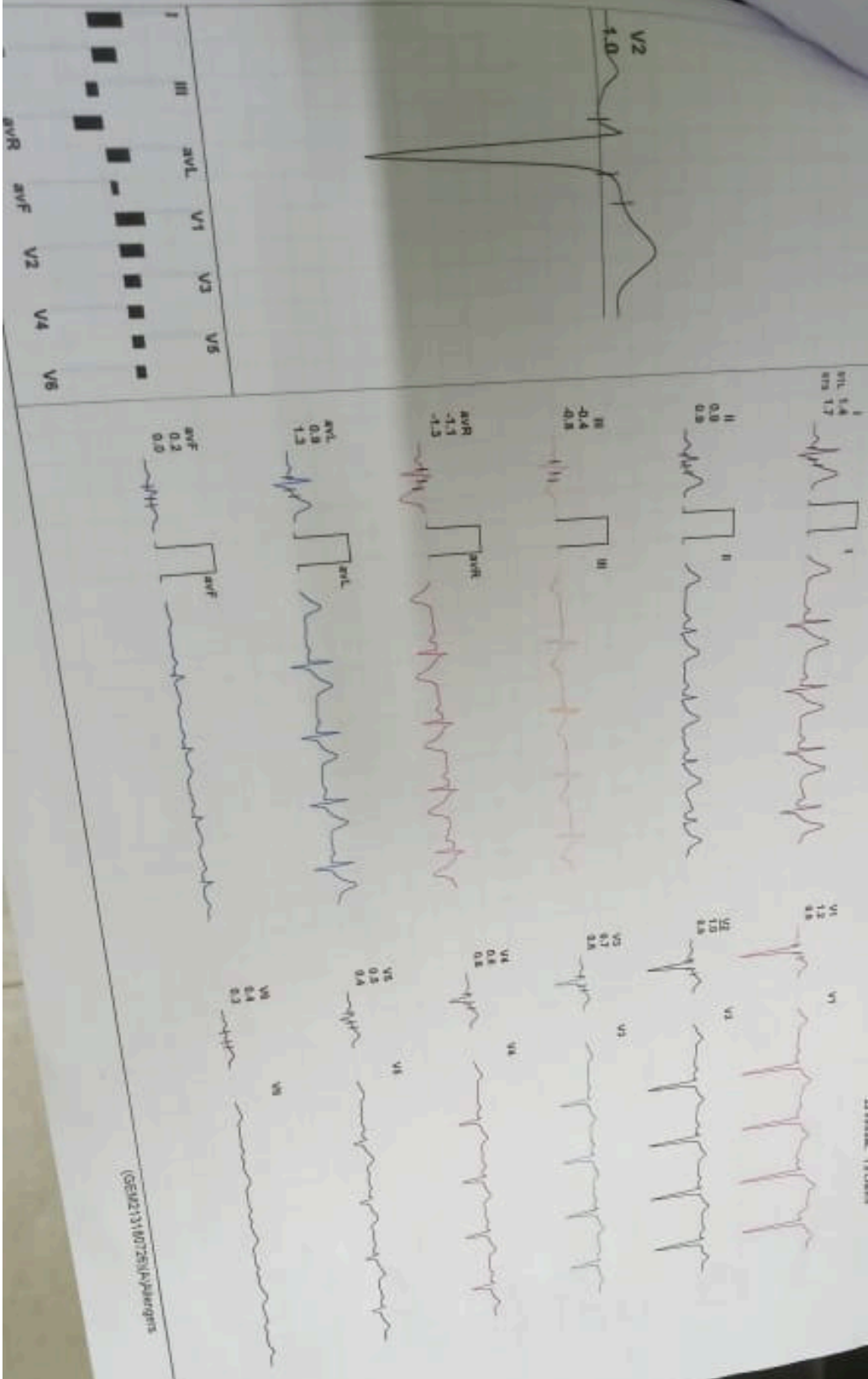
SAHJEEV KUMAR / 34 Yrs / M / 166 Cms / 66 Kg / HR: 180

DATE: 2022 01 18 05 PM METRS: 140/ 100 bpm 96% of T1-99 BP: 110/70 mmHg RR: 12/min SpO2: 98%
Raw ECG/ BLC ON MONO QULHE 0.05/HALF 20 Hz

STANDING



EXTR: 90.08 58.00% 95%
25mm/50 130mmV



(GEM1310725/A)Paparigms