

## HEALTH CHECKUP REPORT

Patient Name: MR.GOUTAM PRATEEK  
Age/Gender: 33/M  
Reg. No: 376714  
Package: BOB

DATE: 30/07/2022

### COMPLAINTS (IF ANY):

- Asymptomatic

HISTORY OF HEALTH STATUS: No

PRESENT MEDICATIONS: No

HYPERSENSITIVITY TO ANY DRUG: No

### PERSONAL HISTORY:

- Bowel : Regular
- Micturition : Normal
- Sleep : Disturb
- Appetite : Adequate

Diet : both  
Habits : alcohol  
Physical Activity/Exercise: Walking

HISTORY OF ILLNESS (WITH PAST MEDICATIONS): NAD

### FAMILY HISTORY:

- Father Hypertension

### VITAL SIGNS:

- Height : 172 cms
- Weight : 86.9 Kgs

Pulse : 77/min.  
B.P: 132/80mmHg

FOR OFFICE USE ONLY

FOR OFFICE USE ONLY

**PHYSICIAN CONSULTATION:**

**1) Recommendations**

- 1 hour walk daily
- Diet modification
- Lipid profile
- Healthy life style

**(Dr. Rashmi chovatiya)**

**OPHTHALMO CONSULTATION:**

- Best corrected visual acuity

RE  
6/6

LE  
6/6

**DENTAL CONSULTATION:**

Adv:

- Cleaning

**(Dr. Parvin Chandarana)**

**Please take regular medicine as prescribed by the Doctor. (If given)**

Reg. No : CIMS/A/2022/376714	Visit No : HC/300722/4 [HCV]
Patient Name : MR. GOUTAM PRATEEK	Age(Y-M-D)/Sex : 33 Y 9 M 9 D. / Male
Referring Doctor : Dr. CIMS DOCTOR	Doctor
Ward/Room	Bed

ORD/300722/354 Lab No : 2022115788 LSN : 904825 ( Whole Blood ) Sample Quality : Normal  
 Collection Time : 30/07/2022 8:50:02 Arrival : 30/07/2022 9:19:02 Validation Time : 30/07/2022 11:09:16AM

FOR PATHOLOGY REPORTS ONLY

	Result	Unit	Reference Range
<b>CBC With ESR</b>			
<b>TOTAL COUNT</b>			
Hemoglobin <i>(SLS Hemoglobin Detection method)</i>	14.4	g/dl	13.5 - 18.0 g/dl
Total RBC Count <i>(Hydro Dynamic Focusing Method)</i>	5.74	mill/Cmm	4.7 - 6.0 mill/Cmm
HCT <i>(Hydro Dynamic Focusing Method)</i>	45.2	%	42 - 52 %
Total WBC Count <i>(Flow Cytometry)</i>	8340	/Cmm	4000 - 10500 /Cmm
Platelet Count <i>(Hydro Dynamic Focusing Method)</i>	282000	/Cmm	150000 - 450000 /Cmm
<b>DIFFERENTIAL COUNT (by Flow Cytometry)</b>			
Polymorphs	55	%	40 - 70 %
Lymphocytes	30	%	22 - 45 %
Eosinophils	09	%	01 - 04 %
Monocytes	06	%	01 - 06 %
Basophils	00	%	00 - 01 %
Immature Granulocytes	00	%	0 - 2 %
Smear Study			
<p>RBCs are Normochromic &amp; Normocytic.            WBCs shows Mild Eosinophilia.            Platelets are adequate in number.            Malarial Parasites are not seen.            No Premature cells are seen.</p>			
<b>BLOOD INDICES (by Calculated Method)</b>			
M.C.V	78.7	fl	78 - 100 fl
M.C.H	25.1	pg	27 - 31 pg
M.C.H.C.	31.9	gm/dl	32 - 36 gm/dl
RDW-CV	13	%	11.5 - 14.0 %



**Dr. Shreya Patel**  
MD(Path)  
Consultant Pathologist

Dr. Manisha Shah  
MD (Path & Bact)  
Consultant Pathologist  
Reg. No. : G-15496

Dr. Jitendra Nayak  
MD (Path)  
Consultant Pathologist  
Reg. No. : G-14786

Print By : namrataparekh





Reg. No : CIMS/A/2022/376714	VisitNo : HC/300722/4 [HCV]
Patient Name : MR. GOUTAM PRATEEK	Age(Y-M-D)/Sex : 33 Y 9 M 9 D. / Male
Referring Doctor : Dr. CIMS DOCTOR	Doctor :
Ward/Room :	Bed :

ORD/300722/354 Lab No : 2022115788 LSN : 904825 ( Whole Blood ) Sample Quality : Normal  
 Collection Time : 30/07/2022 8:50:02 Arrival : 30/07/2022 9:19:02 Validation Time: 30/07/2022 11:09:16AM

FOR PATHOLOGY REPORTS ON

**ESR (Red Cell Aggregation)**

After One Hour **24** mm 0 - 10 mm

**Blood Group Rh**

ABO "O"  
Rh POSITIVE

**HbA1c (Glycosylated Haemoglobin.)**

**TEST**

HbA1c (Glyoco Hb) **6.03** %  
 (Immuno Turbidimetric)

4.8-5.9% Normal  
 5.9-7.0% Good diabetic control  
 7.0-10.0% Fair diabetic control  
 >10.0% Poor diabetic control

Mean Plasma Glucose **137.2** mg/dL 80 - 140 mg/dL

\*\*\* END OF REPORT \*\*\*

**Dr. Shreya Patel**  
MD(Path)  
Consultant Pathologist

Dr. Manisha Shah  
MD (Path & Bact)  
Consultant Pathologist  
Reg. No. : G-15496

Dr. Jitendra Nayak  
MD (Path)  
Consultant Pathologist  
Reg. No. : G-14786

Print By : namrataparekh



Reg. No : CIMS/A/2022/376714	Visit No : HC/300722/4 [HCV]
Patient Name : MR. GOUTAM PRATEEK	Age(Y-M-D)/Sex : 33 Y 9 M 9 D. / Male
Referring Doctor : Dr. CIMS DOCTOR	Doctor :
Ward/Room :	Bed :

ORD/300722/354 Lab No : 2022115789 LSN : 904825 ( SERUM ) Sample Quality : Normal  
 Collection Time : 30/07/2022 8:50:02 Arrival : 30/07/2022 9:19:02 Validation Time : 30/07/2022 11:46:22AM

**Liver Function Test**

	<u>Result</u>	<u>Unit</u>	<u>Reference Range</u>
Alkaline Phosphatase (PNPP, AMP Buffer Method, Colorimetric)	98.8	U/L	40 - 129 U/L
<b>Billirubin</b>			
Total Billirubin (Diazospecial Iazonium Iron with Blank)	0.63	mg/dL	0.0 - 1.0 mg/dL
Direct Billirubin (Diazo, (Evelyn Malloy) with Blank)	0.22	mg/dL	0.0 - 0.2 mg/dL
Indirect Billirubin (Calculated from Total and Direct Billirubin)	0.41	mg/dL	0.0 - 0.8 mg/dL
SGPT (ALT) (IFCC without pyridoxal phosphate)	52.3	U/L	0 - 41 U/L
SGOT (AST) (IFCC without pyridoxal 5 phosphate)	34.8	U/L	0 - 40 U/L
<b>Total Protein</b>			
Total Proteins (Biuret Method)	8.24	gm/dl	6.4 - 8.3 gm/dl
Albumin (Bromocresol Green Colorimetric)	5.08	gm/dl	3.97 - 4.95 gm/dl
Globulin	3.16	gm/dl	2.2 - 3.5 gm/dl
A/G Ratio	1.61		0.9 - 2.1



**Dr. Shreya Patel**  
MD(Path)  
Consultant Pathologist

Dr. Manisha Shah  
MD (Path & Bact)  
Consultant Pathologist  
Reg. No. : G-15496

Dr. Jitendra Nayak  
MD (Path)  
Consultant Pathologist  
Reg. No. : G-14786

Print By : namrataparekh





**Marengo CIMS  
Hospital**

cims.org

Reg. No : CIMS/A/2022/376714	Visit No : HC/300722/4 [HCV]
Patient Name : MR. GOUTAM PRATEEK	Age(Y-M-D)/Sex : 33 Y 9 M 9 D. / Male
Referring Doctor : Dr. CIMS DOCTOR	Doctor :
Ward/Room :	Bed :

ORD/300722/354 Lab No : 2022115789 LSN : 904825 ( SERUM ) Sample Quality : Normal  
 Collection Time : 30/07/2022 8:50:02 Arrival : 30/07/2022 9:19:02 Validation Time: 30/07/2022 11:46:19AM

FOR PATHOLOGY REPORTS ON

	Result	Unit	Reference Range
Creatinine (Buffered Jaffe Reaction Kinetic Compensated)	0.86	mg/dL	0.7 - 1.2 mg/dL
Estimated GFR	-	mL/min/1.73m2	59 - 137 mL/min/1.73m2
Fasting Glucose (Hexokinase)	93.5	mg/dL	70 - 100 mg/dL
<b>Thyroid Function Test</b>			
TOTAL T3 (T3) * (Electrochemiluminescence Assay)	1.2	ng/ml	0.846 - 2.02 ng/ml
TOTAL T4 (T4) * (Electrochemiluminescence Assay)	8.6	µgm/dl	5.13 - 14.06 µgm/dl
TSH (Electrochemiluminescence Assay)	2.47	µIU/ml	0.27 - 4.20 µIU/ml
Uric Acid (Uricase Colorimetric Enzymatic)	6.03	mg/dL	3.4 - 7.0 mg/dL

\*\*\* END OF REPORT \*\*\*

**Dr. Shreya Patel**  
MD(Path)  
Consultant Pathologist

Dr. Manisha Shah  
MD (Path & Bact)  
Consultant Pathologist  
Reg. No. : G-15496

Dr. Jitendra Nayak  
MD (Path)  
Consultant Pathologist  
Reg. No. : G-14786

Print By : namrataparekh

Print Date/Time : 30/07/2022 11:46:19AM





**Marengo CIMS  
Hospital**

cims.org

Reg. No : CIMS/A/2022/376714	VisitNo : HC/300722/4 [HCV]
Patient Name : MR. GOUTAM PRATEEK	Age(Y-M-D)/Sex : 33 Y 9 M 9 D. / Male
Referring Doctor : Dr. CIMS DOCTOR	Doctor :
Ward/Room :	Bed :

ORD/300722/354 Lab No : 2022115791 LSN :904825 ( SERUM ) Sample Quality : Normal  
 Collection Time :30/07/2022 8:50:02 Arrival : 30/07/2022 9:19:02 Validation Time: 30/07/2022 11:44:06AM

FOR PATHOLOGY REPORTS ONLY

	<u>Result</u>	<u>Unit</u>	<u>Reference Range</u>
BUN * (Ureas with UV)	8.2	mg/dL	6 - 20 mg/dL

\*\*\* END OF REPORT \*\*\*

**Dr. Shreya Patel**  
MD(Path)  
Consultant Pathologist

Dr. Manisha Shah  
MD (Path & Bact)  
Consultant Pathologist  
Reg. No. : G-15496

Dr. Jitendra Nayak  
MD (Path)  
Consultant Pathologist  
Reg. No. : G-14786

Print By : namrataparekh





Reg. No : CIMS/A/2022/376714	VisitNo : HC/300722/4 [HCV]
Patient Name : MR. GOUTAM PRATEEK	Age(Y-M-D)/Sex : 33 Y 9 M 9 D. / Male
Referring Doctor : Dr. CIMS DOCTOR	Doctor
Ward/Room :	Bed
ORD/300722/354 Lab No : 2022115790 LSN : 904825 ( Urine )	Sample Quality : Normal
Collection Time : 30/07/2022 8:50:02 Arrival : 30/07/2022 9:19:02	Validation Time : 30/07/2022 11:09:24AM

FOR PATHOLOGY REPORTS ON

	Result	Unit	Reference Range
<b>Urine R &amp; M</b>			
<b>PHYSICAL EXAMINATION</b>			
Quantity	20 cc		
Colour	Pale Yellow		
Transparency	Clear		
Reaction (QDS-10 Strip)	6.0		
Sp. Gravity (QDS-10 Strip)	1.015		1.005 - 1.035
<b>CHEMICAL EXAMINATION</b>			
U. Albumin (QDS-10 Strip/Manual)	Nil		
U. Glucose (QDS-10 Strip/Manual)	Nil		
U. Acetone (QDS-10 Strip/Manual)	Absent		
BS/BP (QDS-10 Strip/Manual)	Absent		
<b>MICROSCOPIC EXAMINATION</b>			
Pus Cell	Occasional		
Red Blood Cell	Nil	/H.P.F.	/H.P.F.
Epithelial Cell	1-2	/H.P.F.	/H.P.F.
Cast	Not Seen	/H.P.F.	/H.P.F.
Crystals	Not Seen		
Amorphous	Absent		
Monilia	Absent		

\*\*\* END OF REPORT \*\*\*

**Dr. Shreya Patel**  
MD(Path)  
Consultant Pathologist

Dr. Manisha Shah  
MD (Path & Bact)  
Consultant Pathologist  
Reg. No. : G-15496

Dr. Jitendra Nayak  
MD (Path)  
Consultant Pathologist  
Reg. No. : G-14786

Print By : namrataparekh







MARENGO ASIA NETWORK HOSPITAL



Certificate No. MC-3049

www.cims.org

CIMS Hospital

Name : MR. GAUTAM PRATEEK

Reg No : CIMS/A/2022/376714

DoB /Sex: 24/11/1988 / Male

### ECHO Report

#### Patient Details

Patient ID 314478  
Name Mr. GAUTAM PRATEEK  
Age 33 Years  
Gender Male  
Blood Group  
Referral Doctor

Dt : 30/07/2022

#### ECHO Identification Detail

Doctor Incharge Dr. VIPUL KAPOOR

Clinical Status Of Patient

ECHO Code JP

Finding Description

1. Normal cardiac chambers dimensions.
2. Normal LV systolic function, LVEF: 60%.
3. No RWMA.
4. Normal LV diastolic function.
6. All cardiac valves are structurally normal.
7. Trivial MR, Trivial TR, Trivial PR, No AR.
8. No PAH, RVSP: 30 mmHg.
9. Normal RV systolic function.
10. No clot/vegetation/pericardial effusion.
11. No coarctation of aorta.

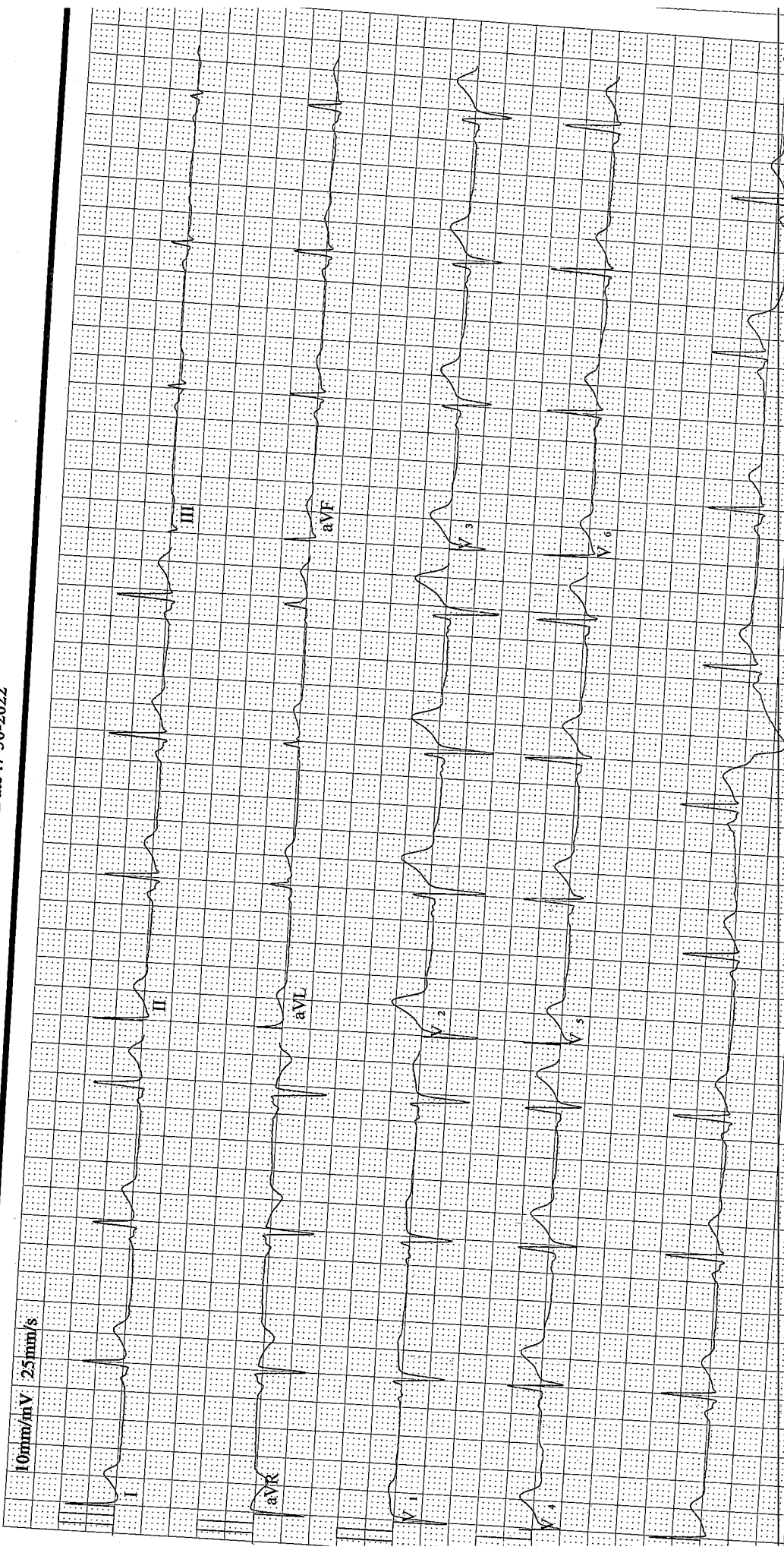
FOR ECHO / TMT REPORTS ONLY

Dr. VIPUL KAPOOR

Name : GAUTAM PRATEEK:376714

Sex : Male

Age : 33 Date : 7-30-2022



Frequency :	1000 Hz	PR Interval :	110 ms
Sample Time :	15 s	QT Interval :	402 ms
Heart Rate :	61 bpm	QTc Interval :	405 ms
P Duration :	90 ms	P Axis :	49.7°
QRS Duration :	108 ms	QRS Axis :	31.8°
T Duration :	264 ms	T Axis :	32.9°

Name : MR. GAUTAM PRATEEK  
Reg No : CIMS/A/2022/376714  
DoB /Sex : 24/11/1988 / Male

*NSR / wnl*

Physician Signature:

Patient's Name : GAUTAM PRATEEK	Age, Sex : 33Y/M
Reg. No. (IP/OP): HC-376714	Date : 30/07/2022
Referred By Dr. : CIMS	

**USG OF ABDOMEN & PELVIS**

**LIVER:** Liver is enlarged with increased parenchymal echogenicity. Right lobe measures 17cm in craniocaudal length. No evidence of focal SOL or dilatation of IHBR seen. Porta hepatis appear normal.

**GALLBLADDER:** Gallbladder is well distended and shows multiple calculi, largest one measures app. 13mm size. No evidence of wall thickening or pericholecystic collection.  
**CBD:** Appears normal in diameter in proximal part, distally obscured by bowel gases. No evidence of calculus or mass lesion in visualized CBD.

**PANCREAS:** Visualised pancreas appeared normal in size and echotexture. No focal lesion, mass or pancreatitis.

**SPLEEN:** Spleen appears normal in size and echotexture.

**PARAAORTIC REGION:** Aorta grossly appeared normal. No paraaortic lymphnodes seen.

**KIDNEYS:** Both kidneys appear normal in size, shape and in position. Cortex and collecting system of both kidneys appeared normal. No evidence of calculus or obstructive uropathy on either side. Right kidney: 101x46mm. Left kidney: 105x50mm.

**URINARY BLADDER:** Bladder appeared normal. No calculus or mass lesion is seen.

**PROSTATE:** Prostate appears normal in size and echotexture and shows 6mm utricle cyst within it.  
Size of prostate: 28x43x36mm. Volume: 23cc.

No evidence of free fluid or collection is seen in peritoneal spaces.  
Normal small bowel peristalsis noted.

**COMMENTS:** Appearance suggests

- Cholelithiasis.
- Hepatomegaly with fatty changes (grade II).
- Small prostatic utricle cyst.

Kindly correlate clinically.

DR KIRTAN SHAH  
M.D. RADIODIAG.  
CONS. RADIOLOGIST

DR DEEPA SHAH  
M.D., D.M.R.E  
CONS. RADIOLOGIST

DR UMA MEHTA  
D.M.R.D. F.R.C.R  
CONS. RADIOLOGIST

DR NIMISH SHARMA  
D.M.R.D. (D.N.B.)  
CONS. RADIOLOGIST

DR RAVINA CHAUHAN  
M.D. RADIODIAG.  
CONS. RADIOLOGIST

DR YASH PATEL  
M.D., D.N.B.  
CONS. RADIOLOGIST

Note: This is only a radiological impression and not the final diagnosis. All diagnostic modalities have their own limitations. Therefore radiological modality report should be interpreted in correlation with clinical and pathological findings.

FOR RADIOLOGY REPORTS ONLY



Patient's Name : GAUTAM PRATEEK	Age, Sex : 33Y/M
Reg. No. (IP/OP): HC-376714	Date : 30/07/2022
Referred By Dr. : CIMS	

**Plain Skiagram of Chest PA Standing View:**  
(Serial No-3751)

Both lung fields appear normal.

No evidence of pleural effusion or pneumothorax is seen on either side.

Mediastinal shadow appears normal.

Heart size and aorta appear normal.

Domes of diaphragm appear normal.

Bones under view appears normal.

Kindly correlate clinically.



DR KIRTAN SHAH  
M.D. RADIOLOG.  
CONS. RADIOLOGIST

DR DEEPA SHAH  
M.D., D.M.R.E  
CONS. RADIOLOGIST

DR UMA MEHTA  
D.M.R.D. F.R.C.R  
CONS. RADIOLOGIST

DR NIMISH SHARMA  
D.M.R.D. (D.N.B.)  
CONS. RADIOLOGIST

DR RAVINA CHAUHAN  
M.D. RADIOLOG.  
CONS. RADIOLOGIST

DR YASH PATEL  
M.D., D.N.B.  
CONS. RADIOLOGIST

Note: This is only a radiological impression and not the final diagnosis. All diagnostic modalities have their own limitations. Therefore radiological modality report should be interpreted in correlation with clinical and pathological findings.

FOR RADIOLOGY REPORTS ONLY