

HEALTH CHECK REPORT

CONSULTANTS		
Dr. MAHAVIR MODI M. D., D.N.B. (Chest Medicine) CHEST PHYSICIAN & INTENSIVIST	Dr. GOPAL AGRAWAL M. D., F.A.C.C. (USA) CARDIOLOGIST & PHYSICIAN	Dr. SANMAY S. CHOWDHARY DNB (Medicine) FCPS (Medicine) I.D.C.C.M. (Intensive Care Medicine)

1

NAME : MRS. RASHMI DILIP BORSE **OPD Reg. No. :** OPR00098907
AGE/SEX : 31.3.23 / F **DATE :** 31/01/2023
ADDRESS : 501 A WING MANGAL WISHWA **REP. NO. :** 40625
KIWALE RAVET, PUNE 412101
TEL. NO. : 8010306647 **EMAIL ID :** RASHMIBORSE10@GMAIL.COM

Marital Status : Married **Periods :** REGULAR
No. Of Children : 1 **LMP :** 23/12/2022
Diet : Veg **Pregnant (If Pregnant no X-Ray) :** NO
Cigarettes / Tobacco / Alcohol : -
Referred By : Arcofemi Healthcare Ltd.
Chief Complaints : NIL SIGNIFICANT ACTIVE
Present Medication : NO
Past History : NIL

Family History :

Relation	Description
Father :	-
Mother :	-
Other :	-

Mrs. KOMAL NAIR
Tel. : 66455630 / 66455385

Mrs. NISHA NANAWARE
Email ID : health@rubyhall.com

Mrs. LEENA GAIKWAD
Visit us at : www.rubyhall.com



HEALTH CHECK REPORT

DATE : 31/01/2023

2

NAME : MRS. RASHMI DILIP BORSE OPD Reg. No. : OPR00098907

General Examination :

Examination	Description
Height (cm) :	153
Weight (kg) :	61
Lymphnodes :	Nothing particular
Anaemia :	Nil
Oedema :	Nil

Systemic Examination

Cardio Vascular System :

Examination	Description
BP :	120/90 mmhg
Heart Rate & Rhythm :	82/min regular
Heart Sounds :	NORMAL

Respiratory System :

Examination	Description
Breath Sounds :	Normal
Shape of Chest :	Normal

Mrs. KOMAL NAIR
Tel. : 66455630 / 66455385

Mrs. NISHA NANAWARE
Email ID : health@rubyhall.com

Mrs. LEENA GAIKWAD
Visit us at : www.rubyhall.com



HEALTH CHECK REPORT

3

DATE : 31/01/2023

NAME : MRS. RASHMI DILIP BORSE OPD Reg. No. : OPR00098907

Abdominal System :

Examination	Description
Appearance :	Normal
Liver :	Not enlarged
Kidney :	Not palpable
Spleen :	Not palpable
Tenderness :	Nil
Fluid :	Nil
Bowel Sounds :	Nil
Hernia :	Nil

Central Nervous System And Spine :

Examination	Description
ENT :	Normal
Dental :	Normal
Eyes :	Normal
Joints :	Normal
Extremities :	Normal
Urinary Tract :	Normal
Skin :	Normal

Mrs. KOMAL NAIR
Tel. : 66455630 / 66455385

Mrs. NISHA NANAWARE
Email ID : health@rubyhall.com

Mrs. LEENA GAIKWAD
Visit us at : www.rubyhall.com



HEALTH CHECK REPORT

4

DATE : 31/01/2023

NAME : MRS. RASHMI DILIP BORSE OPD Reg. No. : OPR00098907

Review Of The Reports & Advice

Laboratory :

Test Name /s	Description	Remarks
Glucose (Fasting) :	NORMAL	-
Urine Routine :	PUS CELLS - 4-6 /HPF, BACTERIA - PRESENT - +	-
Lipid Profile :	TRIGLYCERIDES - 162 mg/dl } HIGH, HDL CHOLESTEROL - 34 mg/dl } LOW	-
T3 T4 TSH :	NORMAL	-
Glucose (PP) :	NORMAL	-
ESR :	NORMAL	-
LFT :	TOTAL BILIRUBIN - 0.2 mg/dl } LOW	-
Haemogram :	NORMAL	-
Stool Routine :	NOT GIVEN	-
Blood Group :	'A' POSITIVE	-
Glycocolated HB(HBA1C) :	5.2 %	-
LBC-PAP Smear :	NEGATIVE FOR INTRAEPITHELIAL LESION / MALIGNANCY(NILM)	-
UREA :	12 mg/dl } LOW	-
CREATININE :	NORMAL	-
URIC ACID :	NORMAL	-
PHOSPHORUS :	NORMAL	-
ELECTROLYTES :	NORMAL	-

Mrs. KOMAL NAIR
Tel. : 66455630 / 66455385

Mrs. NISHA NANAWARE
Email ID : health@rubyhall.com

Mrs. LEENA GAIKWAD
Visit us at : www.rubyhall.com



HEALTH CHECK REPORT

DATE : 31/01/2023

5

NAME : MRS. RASHMI DILIP BORSE OPD Reg. No. : OPR00098907

Radiology :

Test Name /s	Description	Remarks
Chest PA View 1 F :	NORMAL	-

Other :

Test Name /s	Description	Remarks
2-D Echo :	NORMAL, LVEF - 60%	-
E.C.G. :	NORMAL	-
Ophthal Assessment :	NORMAL	-
Stress Test :	NOT DONE	-
USG :	GRADE I FATTY INFILTRATION IN THE LIVER. CHOLELITHIASIS WITH NO IMAGING SIGNS OF ACUTE CHOLECYSTITIS.	-
DENTAL :	NORMAL	-
ENT :	NORMAL	-

REVIEW OF THE REPORTS & ADVICE :

ADVISED -

- LOW FAT DIET.
- REGULAR EXERCISE.
- DRINKS PLENTY OF WATER.
- TAB. NORFLOX 400 mg 1-0 1 FOR 5 DAYS FOR URINARY TRACK INFECTION.
- REPEAT URINE ROUTINE AFTER 5 DAYS.


DR. GOPAL AGRAWAL

RC

Mrs. KOMAL NAIR
Tel. : 66455630 / 66455385

Mrs. NISHA NANAWARE
Email ID : health@rubyhall.com

Mrs. LEENA GAIKWAD
Visit us at : www.rubyhall.com





THE A. H. WADIA BLOOD CENTRE

F.D.A. Licence No. : PD / 15

GRANT MEDICAL FOUNDATION, RUBY HALL CLINIC

40, Sassoon Road, Pune - 411 001.

Phone : 66455100 (60 Lines), 26163391 (8 lines)

Blood Centre Tel. : 020-66455264 (Direct) Fax : 020 - 26164529

E-mail : bloodbank@rubyhall.com

Dr. Mrs. S.S. Mujumdar

MBBS CTM

Director - Transfusion Medicine

Date : 28/01/2023

Name : **MRS. RASHMI DILIP BORSE (OB431037)**


C/O : **HOSPITAL CASE.**

BLOOD GROUP : A POSITIVE

Email ID : bloodbank@rubyhall.com

Visit us at : www.rubyhall.com


Technician


Blood Centre Officer

Give More to Life... Donate Blood

40, Sassoon Road, Pune - 411 001 (INDIA). Tel. : 020 - 6645 5253 / 6645 5297 / 6645 5152
• E-mail : labreports@rubyhall.com • Website : www.rubyhall.com

DEPARTMENT OF HAEMATOLOGY

Patient Name	: MRS.. RASHMI DILIP BORSE	Bill Date	: 28-Jan-2023 12:45 pm
Age / Gender	: 31.3.18/Female	Sample Collected Date	: 28-Jan-2023 01:11 pm
Bill No./UHID No	: OB431037 / P00000478617	Report Date	: 28-Jan-2023 3:04 pm
Lab No./Result No	: 230108748 / RES4394513	Specimen	:
Referred By	: Dr. HOSPITAL CASE.		

<u>Investigation</u>	<u>Result</u>	<u>Reference Range</u>	<u>Method</u>
HAEMOGRAM REPORT			
W.B.C.COUNT	: 7,550	4000 - 10000 /uL	Fluorescence flow cytometry
Differential Count			
NEUTROPHILS	: 58.7	40-75 %	Fluorescence flow cytometry
LYMPHOCYTES	: 33.6	20-40 %	Fluorescence flow cytometry
MONOCYTES	: 5.4	2-10 %	Fluorescence flow cytometry
EOSINOPHILS	: 1.5	1.0 - 6.0 %	Fluorescence flow cytometry
BASOPHILS	: 0.8	0.0 - 1.0 %	Fluorescence flow cytometry
ABSOLUTE NEUTROPHIL COUNT	: 4.43	2 - 7 x10 ³ cells/ul	Derived from WBC histogram
ABSOLUTE LYMPHOCYTE COUNT	: 2.54	1 - 3 x10 ³ cells/ul	Derived from WBC histogram
ABSOLUTE MONOCYTE COUNT	: 0.41	0.2-1.0 x10 ³ cells/ul	Derived from WBC histogram
ABSOLUTE EOSINOPHIL COUNT	: 0.11	0.02-0.5 x10 ³ cells/ul	Derived from WBC histogram
ABSOLUTE BASOPHIL COUNT	: 0.06	0.0 - 0.1 x10 ³ cells/ul	Derived from WBC histogram
R.B.C COUNT	: 4.5	3.8 - 5.8 million/ul	Hydrodynamic focussing DC(impedence)
HAEMOGLOBIN	: 12.6	12 - 15.0 g/dl	Sodium lauryl sulphate method
HAEMATOCRIT	: 39.1	36-46 %	Cumulative pulse height
MCV	: 86.9	83 - 99 fL	Calculated parameter
MCH	: 28.0	27-32 pg	Calculated parameter
MCHC	: 32.2	31.5-34.5 g/dL	Calculated
RDW	: 13.6	11.6-14.0 %	Calculated parameter
PLATELET COUNT	: 403	150 - 450 x10 ³ /ul	Impedence and hydrodynamic focussing
MPV	: 8.6	7.8-11 fl	Calculated parameter

Kindly note change in reference range.

Note: This test is performed on automated HAEMATOLOGY analyzer - SYSMEX_XN1000

*** End Of Report ***

Verified By

VKT1

NOTE:

- * Clinically correlate, Kindly discuss if necessary.
- * This report relates only to the item received.



P. Mahalle

Dr. PUJA GAJANAN MAHALLE, MD

Sr.Registrar





DEPARTMENT OF HAEMATOLOGY

Patient Name	: MRS.. RASHMI DILIP BORSE	Bill Date	: 28-Jan-2023 12:45 pm
Age /Gender	: 31.3.18/Female	Sample Collected Date	: 28-Jan-2023 01:11 pm
Bill No/UHID No	: OB431037 / P00000478617	Report Date	: 28-Jan-2023 4:29 pm
Lab No/Result No	: 230108748 / RES4394831	Specimen	:
Referred By	: Dr. HOSPITAL CASE.		

<u>Investigation</u>	<u>Result</u>	<u>Reference Range</u>	<u>Method</u>
ESR at 1 Hour	: 16	0 - 20 mm/hr	Modified Westergren Method

=====

INTERPRETATION :

ESR is a screening test to detect presence of systemic disease;however a normal result does not rule out a systemic disease.

ESR is also used to monitor course of disease or response to therapy if initially elevated.

*** End Of Report ***

Verified By

RAJ

NOTE:

- * Clinically correlate, Kindly discuss if necessary.
- * This report relates only to the item received.



MC-2680

Dr. PUJA GAJANAN MAHALLE, MD

Sr.Registrar





40, Sassoon Road, Pune - 411 001 (INDIA). Tel. : 020 - 6645 5253 / 6645 5297 / 6645 5152
• E-mail : labreports@rubyhall.com • Website : www.rubyhall.com

DEPARTMENT OF BIOCHEMISTRY

Patient Name	: MRS.. RASHMI DILIP BORSE	Bill Date	: 28-Jan-2023 12:45 pm
Age /Gender	: 31.3.18/Female	Sample Collected Date	: 28-Jan-2023 01:12 pm
Bill No/UHID No	: OB431037 / P00000478617	Report Date	: 28-Jan-2023 2:57 pm
Lab No/Result No	: 230108751 / RES4394492	Specimen	:
Referred By	: Dr. HOSPITAL CASE.		

<u>Investigation</u>	<u>Result</u>	<u>Reference Range</u>	<u>Method</u>
GLYCOSYLATED HAEMOGLOBIN (HBA1c)	: 5.2	Therapeutic Target : < 7.0 % Diabetic : >= 6.5 % Prediabetic : 5.7 - 6.4 %	HPLC

REFERENCE : ADA 2022 GUIDELINES

Kindly note the change in method.

Note: This test is performed on automated BIO CHEMISTRY analyzer - BIORAD VARIANT II TURBO

*** End Of Report ***

Verified By

DSM

NOTE:

- * Clinically correlate, Kindly discuss if necessary.
- * This report relates only to the item received.

Dr. PUJA GAJANAN MAHALLE, MD

Sr.Registrar





DEPARTMENT OF BIOCHEMISTRY

Patient Name	: MRS.. RASHMI DILIP BORSE	Bill Date	: 28-Jan-2023 12:45 pm
Age /Gender	: 31.3.18/Female	Sample Collected Date	: 28-Jan-2023 01:11 pm
Bill No/UHID No	: OB431037 / P00000478617	Report Date	: 28-Jan-2023 5:35 pm
Lab No/Result No	: 230108748 / RES4395054	Specimen	: SERUM
Referred By	: Dr. HOSPITAL CASE.		

<u>Investigation</u>	<u>Result</u>	<u>Reference Range</u>	<u>Method</u>
GLUCOSE (FASTING)	: 78	Gestational diabetes mellitus : >= 92 mg/dL Diabetic : >= 126 mg/dL Prediabetic : 100 - 125 mg/dL Normal : 60.0 - 99.0 mg/dL	GOD-POD

REFERENCE : ADA 2018 GUIDELINES

UREA	: 12	17.1-49.2 mg/dL	Urease
CREATININE	: 0.5	0.5 - 1.2 mg/dL	Enzymatic
ELECTROLYTES (Na & K)			
SODIUM	: 142.0	136.0 - 145.0 mmol/L	Direct ISE
POTASSIUM	: 4.9	3.5 - 5.1 mmol/L	Direct ISE
PHOSPHORUS	: 3.8	2.7-4.5 mg/dL	Phospho Molybdate
URIC ACID	: 3.5	2.6 - 6.0 mg/dL	Uricase/Peroxidase

Note: This test is performed on automated BIO CHEMISTRY analyzer - 7600IM

*** End Of Report ***

Verified By

7600IM

NOTE:

- * Clinically correlate, Kindly discuss if necessary.
- * This report relates only to the item received.



MC-2680

Prashant Mahalle

Dr. PUJA GAJANAN MAHALLE, MD

Sr.Registrar



40, Sassoon Road, Pune - 411 001 (INDIA). Tel. : 020 - 6645 5253 / 6645 5297 / 6645 5152
• E-mail : labreports@rubyhall.com • Website : www.rubyhall.com

DEPARTMENT OF BIOCHEMISTRY

Patient Name	: MRS.. RASHMI DILIP BORSE	Bill Date	: 28-Jan-2023 12:45 pm
Age /Gender	: 31.3.18/Female	Sample Collected Date	: 28-Jan-2023 01:11 pm
Bill No/UHID No	: OB431037 / P00000478617	Report Date	: 28-Jan-2023 5:35 pm
Lab No/Result No	: 230108748 / RES4395055	Specimen	:
Referred By	: Dr. HOSPITAL CASE.		

<u>Investigation</u>	<u>Result</u>	<u>Reference Range</u>	<u>Method</u>
CALCIUM	: 8.8	8.6 - 10.2 mg/dL	Arsenazo dye
LIVER FUNCTION TEST			
TOTAL BILIRUBIN	: 0.2	0.3 - 1.2 mg/dL	Diazo
DIRECT BILIRUBIN	: 0.1	0.0 - 0.4 mg/dL	Diazo
INDIRECT BILIRUBIN	: 0.1	0.0 - 0.8 mg/dL	Diazo
ALANINE TRANSAMINASE	: 22.0	10 - 40 U/L	Kinetic
ASPARTATE TRANSAMINASE	: 24.0	10.0 - 40.0 U/L	Kinetic
ALKALINE PHOSPHATASE	: 72.0	30.0 - 115.0 U/L	4 NPP/AMP Buffer
TOTAL PROTEIN	: 7.3	6.0 - 8.0 g/dL	Biuret
ALBUMIN	: 4.5	3.5 - 4.8 g/dl	BCG
GLOBULIN	: 2.9	2.3-3.5 gm/dL	Calculated
A/G RATIO	: 1.56	1.0-2.1	Calculated

LIPID PROFILE

CHOLESTEROL	: 194.0	130.0 - 200.0 mg/dL	Enzymatic
TRIGLYCERIDES	: 162	< 150.0 mg/dL	Enzymatic with peroxidase
HDL CHOLESTEROL	: 34	35 - 65 mg/dL	Phosphotungstic
LDL CHOLESTEROL	: 128	10.0 - 130.0 mg/dL	Calculated
VLDL CHOLESTEROL	: 32	5.0 - 36.0 mg/dL	Calculated
CHOL/HDL RATIO	: 6.00	2.0 - 6.2	Calculated

ATP III NCEP GUIDELINES FOR INTERPRETATION OF FASTING LIPID PROFILE

PARAMETER	DESIRABLE	BORDERLINE	REQUIRES TREATMENT
Total Cholesterol	Below 200	200 -239	>240
HDL Cholesterol	Above 60	40 - 59	< 40
LDL Cholesterol	Below 130	130-159	>160
Triglycerides	Below 150	150-199	> 200

T3-T4-TSH

Tri-iodothyronine (T3).	: 1.31	1.07 - 1.86 ng/mL	Enhanced Chemiluminescence
THYROXINE (T4), TOTAL.	: 8.63	6.53 - 13.21 ug/dL	Enhanced Chemiluminescence
THYROID STIMULATING HORMONE (TSH)..	: 1.11	0.86 - 4.81 uIU/mL	CMIA





40, Sassoon Road, Pune - 411 001 (INDIA). Tel. : 020 - 6645 5253 / 6645 5297 / 6645 5152
• E-mail : labreports@rubyhall.com • Website : www.rubyhall.com

DEPARTMENT OF BIOCHEMISTRY

Patient Name	: MRS.. RASHMI DILIP BORSE	Bill Date	: 28-Jan-2023 12:45 pm
Age / Gender	: 31.3.18/Female	Sample Collected Date	: 28-Jan-2023 01:11 pm
Bill No/UHID No	: OB431037 / P00000478617	Report Date	: 28-Jan-2023 5:27 pm
Lab No/Result No	: 230108748 / RES4395011	Specimen	:
Referred By	: Dr. HOSPITAL CASE.		

Investigation **Result** **Reference Range** **Method**
Note: This test is performed on automated BIO CHEMISTRY analyzer - 7600IM

*** End Of Report ***

Verified By

RITA

NOTE:

- * Clinically correlate, Kindly discuss if necessary.
- * This report relates only to the item received.



MC-2680

Dr. SUDHARANI HANUMANTHU, MD

Sr.Registrar





DEPARTMENT OF BIOCHEMISTRY

Patient Name	: MRS.. RASHMI DILIP BORSE	Bill Date	: 28-Jan-2023 12:45 pm
Age /Gender	: 31.3.18/Female	Sample Collected Date	: 28-Jan-2023 01:13 pm
Bill No/UHID No	: OB431037 / P00000478617	Report Date	: 28-Jan-2023 2:52 pm
Lab No/Result No	: 230108753 / RES4394442	Specimen	:
Referred By	: Dr. HOSPITAL CASE.		

<u>Investigation</u>	<u>Result</u>	<u>Reference Range</u>	<u>Method</u>
GLUCOSE (POST PRANDIAL)	: 97.0	Normal : 70.0 - 139.0 mg/dl Prediabetic : 140.0 - 199.0 mg/dl Diabetic : >= 200.0 mg/dl ADA 2016 guidelines	Hexokinase

Note: This test is performed on automated BIO CHEMISTRY analyzer - Alinityci_AMS

*** End Of Report ***

Verified By

Alinityci_AMS

NOTE:

- * Clinically correlate, Kindly discuss if necessary.
- * This report relates only to the item received.



Prashale

Dr. PUJA GAJANAN MAHALLE, MD

Sr.Registrar





DEPARTMENT OF CLINICAL PATHOLOGY

Patient Name : MRS.. RASHMI DILIP BORSE	Bill Date : 28-Jan-2023 12:45 pm
Age /Gender : 31.3.18/Female	Sample Collected Date : 28-Jan-2023 01:11 pm
Bill No/UHID No : OB431037 / P00000478617	Report Date : 28-Jan-2023 3:05 pm
Lab No/Result No : 230108748 / RES4394522	Specimen : URINE
Referred By : Dr. HOSPITAL CASE.	

URINE ROUTINE

<u>Investigation</u>	<u>Result</u>	<u>Reference Range</u>	<u>Method</u>
COLOUR..	: Dark Yellow	Colourless	Colourometry
APPEARANCE..	: Turbid	Colourometry	Colourometry
PH..	: 5.0	5.0 - 7.0	Indicator Principle
SPECIFIC GRAVITY..	: 1.023	1.015 - 1.030	Indicator Reaction
PROTEIN...	: Absent	Absent	Protein error of Indicator
SUGAR..	: Absent	Absent	GOD POD
KETONE BODIES..	: Absent	Absent	Nitruoprusside
BILE PIGMENTS / BILIRUBIN	: Absent	Absent	Azo Coupling
UROBILINOGEN..	: Normal	Normal	Azo Coupling
BLOOD..	: Absent	Absent	Peroxidase
NITRITES..	: Absent	Absent	Griess method
LEUCOCYTE ESTERASE	: Trace	Absent	Photometric measurement of LE activity
PUS CELLS (WBC)	: 4-6	0 - 5 /HPF	Fluorescence Flowcytometry
RED BLOOD CELLS (RBC)	: Absent	0 - 2 /HPF	Fluorescence Flowcytometry
EPITHELIAL CELLS..	: 2-4	0 - 5 /HPF	Fluorescence Flowcytometry
Squamous Epithelial Cells	: 2-4	Absent/HPF	Fluorescence Flowcytometry
Non-Squamous Epithelial Cells	: Absent	Absent/HPF	Fluorescence Flowcytometry
Transitional epithelial cells	: Absent	Absent/HPF	Fluorescence Flowcytometry
Renal Tubular Epithelial Cells	: Absent	Absent/HPF	Fluorescence Flowcytometry
BACTERIA..	: Present(+)	Absent/HPF	Fluorescence Flowcytometry
CAST			
Hyaline Cast	: Absent	Absent/LPF	Fluorescence Flowcytometry
Pathological cast	: Absent	Absent/LPF	Fluorescence Flowcytometry
YEAST CELLS (YLC)	: Absent	Absent/HPF	Fluorescence Flowcytometry
CRYSTALS (XTAL)	: Amorphous urate seen	Absent/LPF	Fluorescence Flowcytometry

*** End Of Report ***

Note: This test is performed on automated CLINICAL PATHOLOGY analyzer - UC3500 & UF 4000

Verified By
SCM

NOTE:

- * Clinically correlate, Kindly discuss if necessary.
- * This report relates only to the item received.

DR. PUJA GAJANAN MAHALLE, MD
Sr.Registrar





OPHTHALMOLOGY

NAME :

MRS. RASHMI DILIP BORSE
Ref: OB431637- Reg: OPR00098907
31.3.18/F - NH - 28/01/2023
P00000478617 -

AGE :


- | | | | | | | | | | | | |
|---------------------|---|---------|---|-----|---|-----|-----------|--|--|--|--|
| 1) Vision | <table border="0"> <tr> <td>unaided</td> <td>R</td> <td>6/6</td> <td>L</td> <td>6/6</td> </tr> <tr> <td>c glasses</td> <td></td> <td></td> <td></td> <td></td> </tr> </table> | unaided | R | 6/6 | L | 6/6 | c glasses | | | | |
| unaided | R | 6/6 | L | 6/6 | | | | | | | |
| c glasses | | | | | | | | | | | |
| 2) Near Vision | <table border="0"> <tr> <td>unaided</td> <td>R</td> <td>26</td> <td>L</td> <td>26</td> </tr> <tr> <td>c glasses</td> <td></td> <td></td> <td></td> <td></td> </tr> </table> | unaided | R | 26 | L | 26 | c glasses | | | | |
| unaided | R | 26 | L | 26 | | | | | | | |
| c glasses | | | | | | | | | | | |
| 3) Binocular Vision | Normal | | | | | | | | | | |
| 4) Colour Vision | | | | | | | | | | | |
| 5) Tension | <table border="0"> <tr> <td></td> <td>R</td> <td>14</td> <td>L</td> <td>16</td> </tr> </table> | | R | 14 | L | 16 | | | | | |
| | R | 14 | L | 16 | | | | | | | |
| 6) Anterior Segment | Normal | | | | | | | | | | |
| 7) Pupils | Normal | | | | | | | | | | |
| 8) Lens | | | | | | | | | | | |
| 9) Media & Fundus | 2780 (L) (R) | | | | | | | | | | |
| 10) Remarks | normal | | | | | | | | | | |

Date :

(Signature)


(Dr. S. Wagh / Dr. D. Venkatramani / Dr. S. Bhide / Dr. H. Todkar / Dr. N. F. Irani / Mr. Sanjeev Singh)

DENTAL & MAXILLO-FACIAL DEPT.

NAME : **MRS. RASHMI DILIP BORSE**

Ref: OB431037- Reg: OPR00098907
31.3.18/F - NH - 28/01/2023
P00000478617 -

AGE :

Following Dental treatment is advised :

Caries in :
Restoration :
Extraction :
Prophylaxis : 
Any other findings :

DATE :

28/1/23

SIGNATURE



PS-35-449

Mrs. Rashmi. Borse

31/F.

Q.

SOLUWAX EAR DROPS

3d

1 ————— 1 — 1

x 3d

J. J. Rai

Mrs. Rashmi. Rorve

ofc.


Cases $\left\{ \begin{array}{l} \textcircled{1} \text{ B/L. Impacted} \\ \textcircled{2} \text{ Cerumen } \oplus \\ \text{T.m not seen} \end{array} \right.$

Nose & PNS
Throat $\left. \vphantom{\begin{array}{l} \text{Nose \& PNS} \\ \text{Throat} \end{array}} \right\} \text{NAD}$

ENT WNL

J. Rai

40, Sassoon Road, Pune - 411 001 (INDIA). Tel. : 020 - 6645 5100 (60 Lines), 2616 3391 (8 Lines)
Fax : 020 - 2616 4529 • F-mail : info@rubyhall.com • Website : www.rubyhall.com

MRS. RASHMI DILIP BORSE

 Ref: OB431037 - Reg: OPR00088907
 31.3.18/F - NH - 28/01/2023
 ADD P00000478617 -

NAME

DATE - 28/01/23.

ADDRESS

PHONE

OCCUPATION

Working

AGE - 31 years

CHIEF COMPLAINT

- Health check up

M.H.:

Reg. ✓

Irreg.

LMP : 23/12/2022

Menarche :

Contraception : -

Infertility:

O.H.:

PL1

M.S. : 5 1/2 years.

Consanguinity :

Para : 1

Living : 1

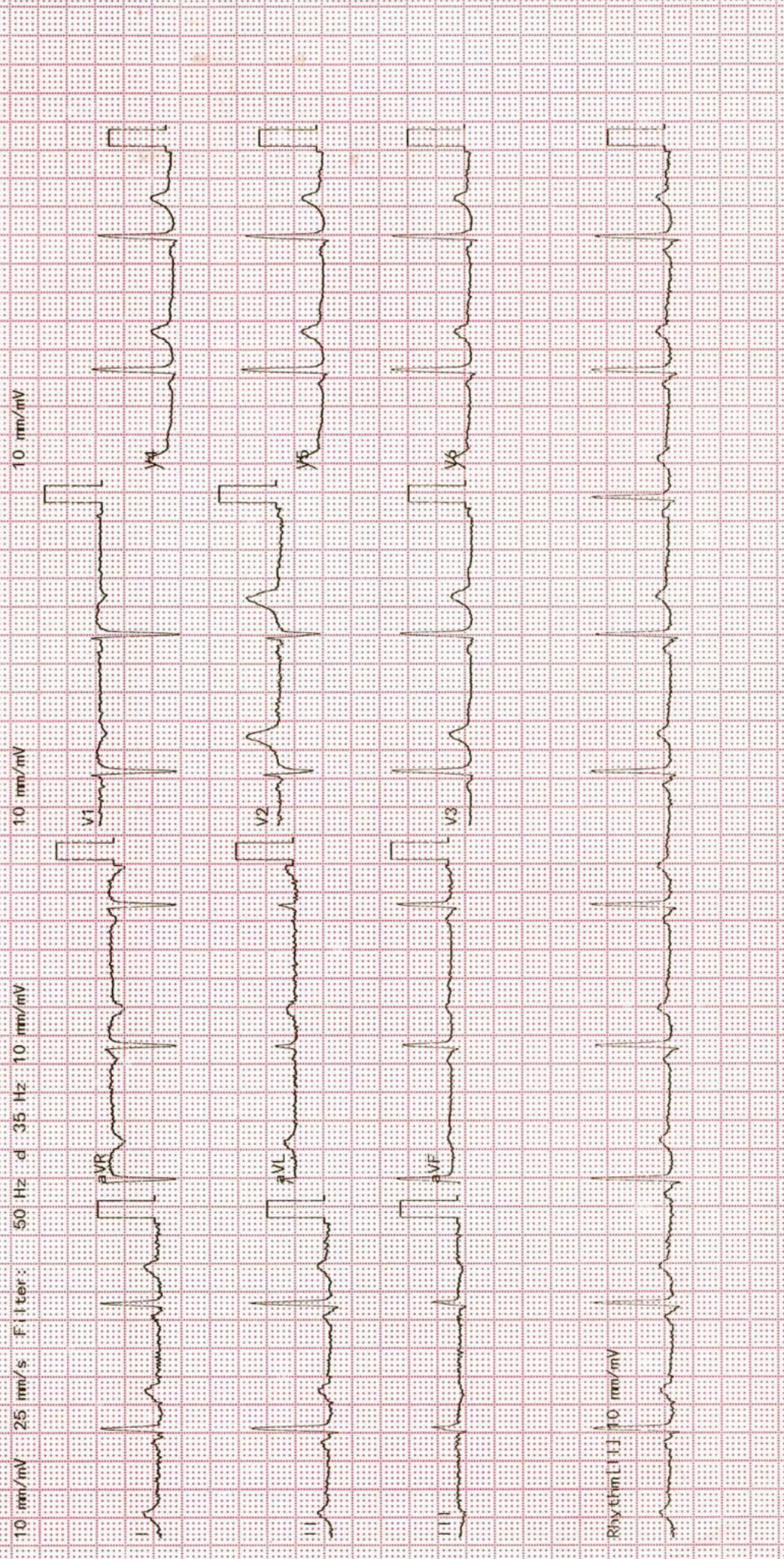
PATIENT & FAMILY HISTORY	PH.	F.H.	DETAILS
1. Diabetes			
2. Hypertension			
3. Congenital Malformations			
4. Multiple Gestation			
5. T. B. & Respiratory Disease			
6. Anaemia & Haemoglobinopathy			
7. Cardiovascular Disease			
8. Renal Disease			
9. Psychiatric Disorder			
10. Liver Disease			
11. Sexually Transmitted Disease			
12. Epilepsy/ Convulsions			
13. Rheumatic Fever			
14. Fibromyoma Uteri			
15. Uterine Abnormality			
16. Operations			
17. Smoking / Addiction			
18. Blood Transfusion			
19. Other			
20. Cancer			

ID: 383-B
 Name: MRS RASHMI BORSE
 Sex: F
 Birth date: / /
 cm kg
 mmHg

31 years
 1100 Sinus rhythm
 2210 Short PR interval
 0102 ARTIFACT PRESENT
 9150 ** abnormal ECG **

Unconfirmed Report
 Reviewed by:

Vent. rate 64 bpm
 PR int 118 ms
 QRS dur 88 ms
 QT/QTc (E) int 388/397 ms
 P/QRS/T axis 41/42/21 °
 RV5/SV1 amp 1.45/1.41 mV
 RV5+SV1 amp 2.86 mV
 10 mm/mV 25 mm/s Filter: 50 Hz d 35 Hz 10 mm/mV





DEPARTMENT OF PATHOLOGY
CYTOPATHOLOGY REPORT

Patient Name : MRS.. RASHMI DILIP BORSE	Bill Date : 28-Jan-2023 12:45 pm
Age /Gender : 31.3.20/Female	Sample Collected Date : 28-Jan-2023 01:11 pm
Bill No/UHID No : OB431037 / P00000478617	Report Date : 30-Jan-2023 2:23 pm
Lab No/Result No : C-217-23 / RES4397579	Specimen :
Referred By : Dr. HOSPITAL CASE.	

CYTOLOGY REPORT

LAB NO : C-217-23

CLINICAL DETAILS:

P1L1

SPECIMEN TYPE-

Cervical cytology, Liquid based preparation

ADEQUACY -

Satisfactory for evaluation

INTERPRETATION-

Negative for intraepithelial lesion/ malignancy (NILM)
(The Bethesda System for reporting cervical cytology 2014)

OTHERS -

Moderate inflammation seen

*** End Of Report ***

Verified By

DR BHUMESHOWRI

NOTE:

- * Clinically correlate, Kindly discuss if necessary.
- * This report relates only to the item received.

Bhumeshowri

Dr. LOITONGBAM BHUMESHOWRI DEVI, MD
Sr.Registrar



Name: RASHMI DILIP BORSE .
Age : 31 Years
Gender: F
PID: P00000478617
OPD :

Exam Date : 28-Jan-2023 12:59
Accession: 1639913124913
Exam: CHEST
Physician: HOSPITAL CASE.

Radiograph Chest PA View

- Soft tissues of the chest wall are normal.
- Bony cage of the thorax is normal.
- Trachea is central.
- Cardiac size and silhouette is normal.
- Both hila are normal in size and position.
- Costophrenic angles are clear
- Both hemidiaphragms are normal in position and contour.
- Lung fields are clear bilaterally.

Impression Normal Radiograph Chest



DR. SAMARESH SAHU
MD, DNB (RADIOLOGY); FRCR (UK)
SENIOR CONSULTANT & HOD (RADIOLOGY)

Date: 28-Jan-2023 14:35:52



Name:	RASHMI DILIP BORSE.	Exam Date :	28-Jan-2023 13:26
Age :	031Y	Accession:	1639952132916
Gender:	F	Exam:	ABDOMEN AND PELVIS
PID:	P00000478617	Physician:	HOSPITAL CASE.^^^^
OPD :			

Ultrasound of abdomen and pelvis has been performed :

Liver is normal in size, shape and shows grade I fatty infiltration in the liver. No intra hepatic biliary dilatation noted. No focal lesion seen.

Gall bladder is well distended with evidence of multiple 5.6 mm dependent calculi within. No evidence of wall thickening or pericholecystic collection noted.

Visualised part of CBD, portal vein, aorta and IVC appear normal.

Pancreas head and body visualized, appears normal.

Spleen is normal in size and shows homogeneous parenchymal texture.

Right kidney measures 10.3 x 4.6 cm, left kidney measures 9.3 x 4.7 cm. Both kidneys are normal in size, shape and echoanatomy. No evidence of hydronephrosis / hydroureter or calculus seen.

Urinary bladder is partially distended.

Uterus is normal in size and measures 7.0 x 3.8 cm. Endometrium measures 1.2 cm (Thickened). No focal lesion noted.

Right ovary measures 3.2 x 1.5 x 2.9 cm with a volume of 7.8 cc and left ovary measures 2.4 x 1.5 x 2.2 cm with a volume of 4.6 cc. Both the ovaries appear normal in size and shows multiple small follicles.

No ascites / pleural effusion seen.

IMPRESSION :

- **Grade I fatty infiltration in the liver.**
- **Cholelithiasis with no imaging signs of acute cholecystitis.**



DR. GAURAV PAWAR
CONSULTANT RADIOLOGIST

Date: 28-Jan-2023 15:18:38



Name:	RASHMI DILIP BORSE.	Exam Date :	28-Jan-2023 14:07
Age :	031Y	Accession:	1639975140924
Gender:	F	Exam:	2-D ECHO (592)
PID:	P00000478617	Physician:	HOSPITAL CASE.^^^^
OPD :			

2D ECHOCARDIOGRAPHY

Normal LV and RV systolic function, LVEF=60%.

All cardiac chambers are normal sized.

No segmental wall motion abnormality.

Mitral valve is thin. Trivial mitral regurgitation.

Mitral diastolic flows are normal.

Aortic valve is trileaflet .

No aortic regurgitation. No aortic stenosis/coarctation of aorta.

Trivial tricuspid regurgitation, PG = 16mmHg.

Estimated PA systolic pressure = 26mmHg.

No pulmonary hypertension.

Intact IAS and IVS.

No intracardiac clots, vegetations, pericardial effusion.

IVC normal, collapsible.

IMPRESSION

NORMAL LV SYSTOLIC AND DIASTOLIC FUNCTION, LVEF 60%.

NO SEGMENTAL WALL MOTION ABNORMALITY.

NORMAL PA PRESSURE.

NO CLOTS, VEGETATIONS, PERICARDIAL EFFUSION.



DR GOPAL AGRAWAL
CARDIOLOGIST



Name:	RASHMI DILIP BORSE.	Exam Date :	28-Jan-2023 14:07
Age :	031Y	Accession:	1639975140924
Gender:	F	Exam:	2-D ECHO (592)
PID:	P00000478617	Physician:	HOSPITAL CASE.^^^^
OPD :			

MEASUREMENTS	M- MODE	NORMAL RANGE
RVDd	22	(7-23 mn)
IVSd	10	(6-11 mn)
LVIDd	44	(35-55 mn)
LVPWDd	10	(6-11 mn)
LVIDs	19	(24-42mn)
MVE-F-Slope		(70-150 mn/sec)
MV Excursion		(15 mn)
EPSS		(<3 mn)
Aortic Root Diam	21	(25-37 mn)
LA Dimension	30	(19-40 mn)
FS		(28-41 %)
EF (Teich)		(50-70 %)
ESV (Teich)		
LV Mass		
SV (Teich)		
EDV (Teich)		
2DEF	60	(50-70 %)
MV Area		(3 Sq. Cm.)

DOPPLER STUDIES	MITRAL VALVE	TRICUSPID VALVE	AORTIC VALVE	PULMONARY VALVE
Peak Velocity		2	1.5	1
Peak Pr. Gradient		16	11.5	4
Mean Pr. Gradient				
Regurgitation	TRIV	TRIV	NIL	NIL
RV Systolic Pres.	26			
PA Acc. Time				
Area				
E =	0.80			
A =	0.55			
E/A				



Allergies: NOT KNOWN

B/M:

Sleep: Adequate

Medication: -

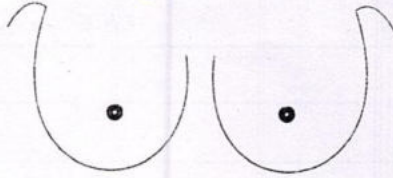
General Examination

P: 120/80 mmHg

TPR: 80bpm

WT: 61kg

Breasts:



B/L - Breast soft
no lumps.

Thyroid

Pallor:

Oedema:

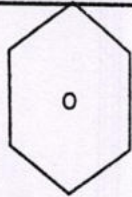
Lymphadenopathy

Examination

CVS:

RS:

A.:



PLA - soft - non-tender
no organomegaly.

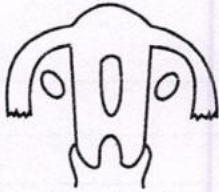Masses:

Uterus:

Ascites:

Tenderness:

E.:



Pap smear - cont

PAP Smear / HVS:

PLS - CX }

- P3005

Provisional Diagnosis:

no white discharge

PLA

Investigation:

review with reports.

Plant: