



Medicheel.

'DR. PLUS HEALTHCARE CENTRE'  
NATHANI HEIGHTS', B-WING,  
42, MUMBAI CENTRAL (EAST)


**DR. HARI CHHABLANI**  
M.D. - SEC. C.P. (RESP. MEDICINE) PGDIP, PGDMLS  
FELLOW INTENSIVE CARE  
MMC REG. NO. - 91702

54/M

 **MAHARASHTRA STATE MOTOR DRIVING LICENCE** 

THE UNION OF INDIA  
DL No : UP93 19880002412  
Valid Till : 01-06-2022 (NT) DOI : 19-12-1988

**DLR 28-09-2017**  
AUTHORISATION TO DRIVE FOLLOWING CLASS  
OF VEHICLES THROUGHOUT INDIA




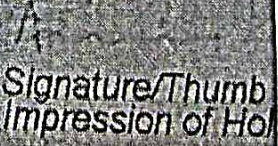
COV	DOI
LMV	19-12-1988
MCWG	19-12-1988

FORM 7  
RULE 16 (2)

DOB : 14-03-1967 - BG

Name : LT ANIRUDDHA SOHONI  
S/DW of M Y SOHONI  
Add : 29/8, PILOT BUNDER,  
BEHIND RAJNA HOUSE,  
COLABA, MUMBAI  
PIN : 400005

Signature & ID of Issuing Authority:  MH01 2017383

Signature/Thumb Impression of Holder: 



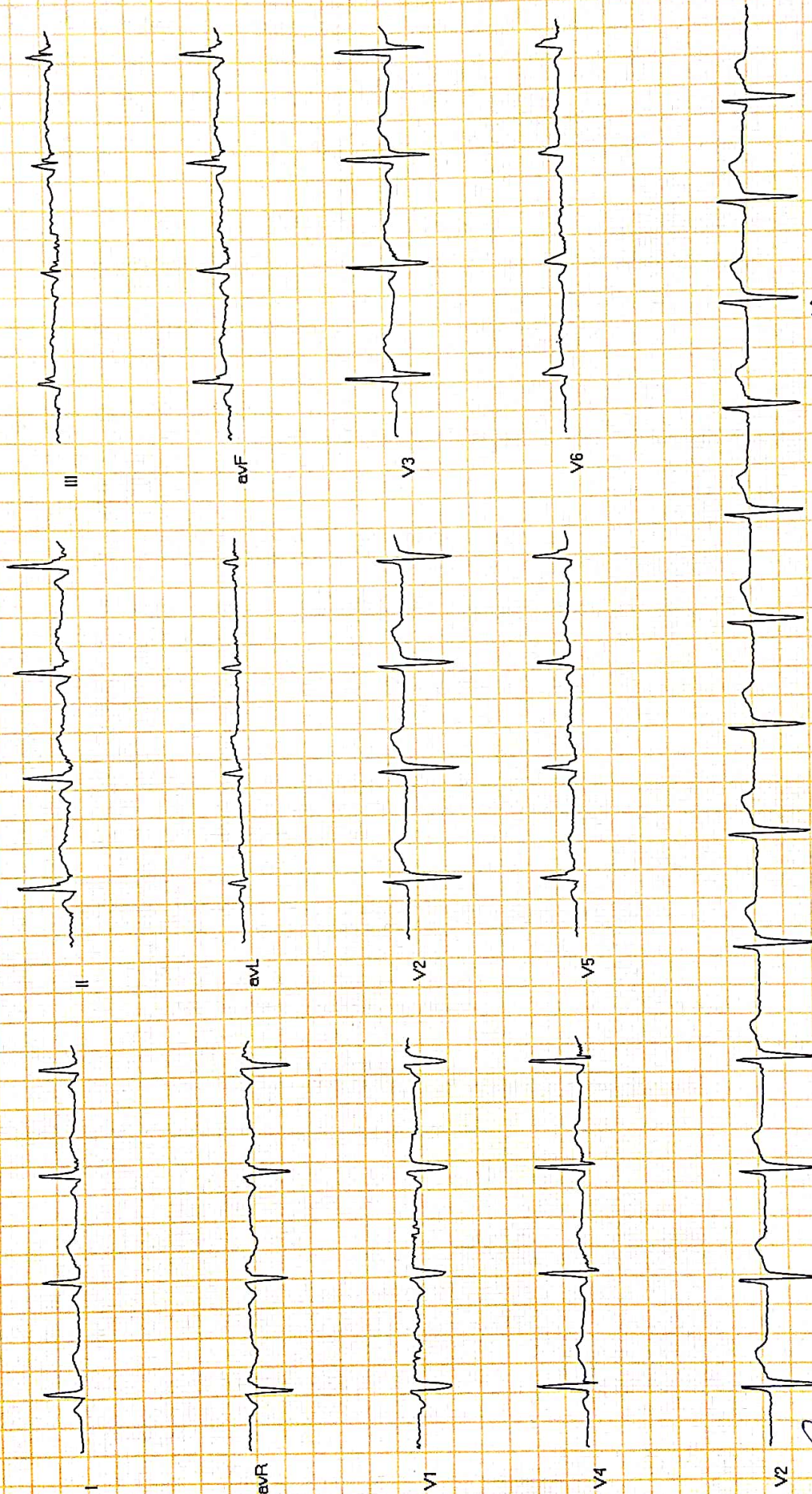
ECG

DR PLUS HEALTHCARE CENTRE - MUMBAI CENTRAL

969 / LT ANIRUDDHA SOHONI / 54 Yrs / M

Heart Rate : 82 bpm / Tested On : 16-Aug-21 12:48:45 / HF 0.05 Hz - LF 100 Hz / Notch 50 Hz / Sn 1.00 Cm/mV / Sw 25 mm/s

/ Retd By : DR. HARI CHHABLANI



*[Handwritten Signature]*

*[Handwritten Signature]*

**DR. PURVI CHHABLANI**  
Reported By: DR. PURVI CHHABLANI (Cardiologist)  
Consultant Physician And Intensive Care  
Reg No 77696





# Dr-Plus Healthcare Centre

NATHANI HEIGHTS, B-Wing, Shop No. 42, Ground Floor, Opp. Mumbai Central Station (East), Mumbai - 400 008.

Patient Name	: LT ANIRUDDHA SOHONI	Sex	: Male
Doctor's Name	: SELF	Age	: 54 Years
Date	: 16/08/2021		

## ULTRASONOGRAPHY OF THE ABDOMEN AND THE PELVIS:

The relevant sonographic findings include the following:

### HEPATOBIILIARY APPARATUS

The liver is normal in size and echogenicity. No obvious focal parenchymal lesion is seen. Extrahepatic biliary radicals are not dilated.

The portal vein and the common bile duct are normal.

### GALL BLADDER

The gall bladder is adequately distended. The wall thickness is normal.

No echogenic contents are noted in its lumen. There is no pericholecystic collection noted.

### PANCREAS

The pancreas shows normal echogenicity and size. No focal or diffuse lesions are noted.

No evidence of calcification is noted.

### SPLEEN

The spleen appears normal in size and echogenicity. No focal or diffuse lesions are noted.

No evidence of calcification is noted.

### KIDNEYS

Right Kidney measure: 11.4 x 4.7cm, Left kidney measure: 12.0 x 5.1 cm

Both the kidneys appear normal in size, shape and echogenicity. Both the pelvicalyceal system is normal and both corticomedullary differentiations are well maintained. There is no obvious focal or diffuse lesion noted.

No evidence of any calculus seen in either kidney.

### URINARY BLADDER

The urinary bladder shows anechoic contents. Its wall thickness appears normal.

Pre void volume = 327 cc. No significant post void residue.

### PROSTATE


Prostate measures: 4.91 x 3.73 x 3.80 cm. Volume = 17.54cc

The Prostate appears normal and shows a normal echogenicity.

No evidence of calcification is seen.

There is no obvious evidence of abdominal or pelvic lymphadenopathy or ascites noted.

**IMPRESSION: No significant abnormality is detected.**

  
Dr. Parag Jhaveri  
MBBS (BOM), DMRE (BOM)  
Radio-Sonologist

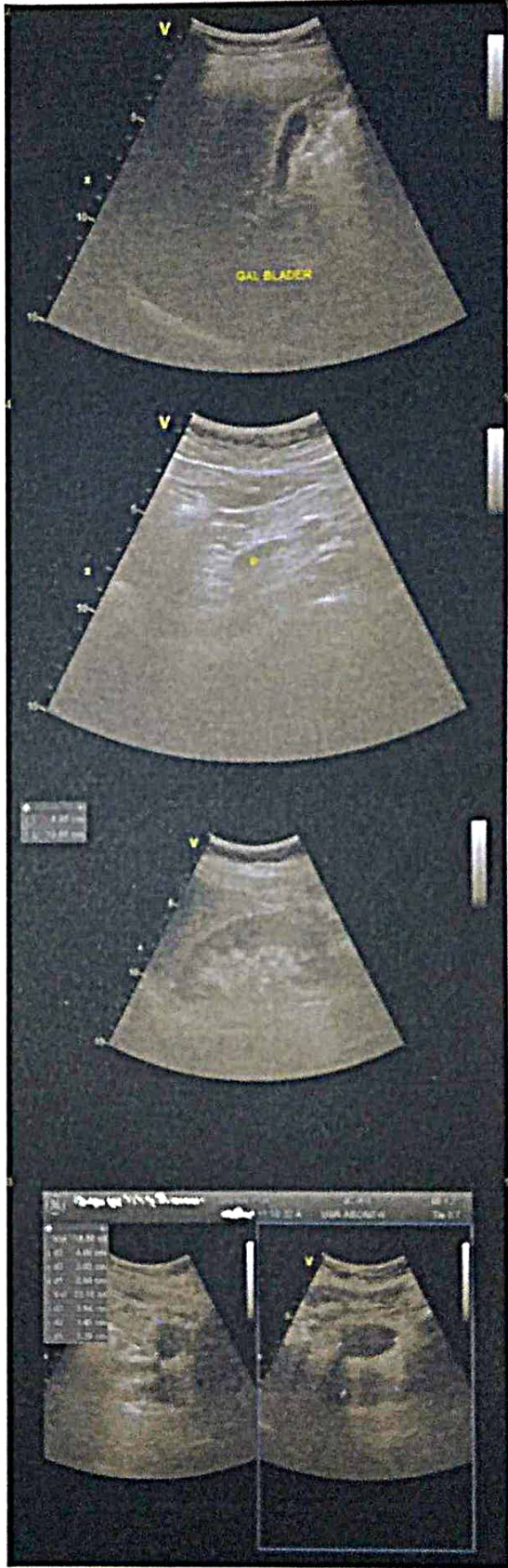
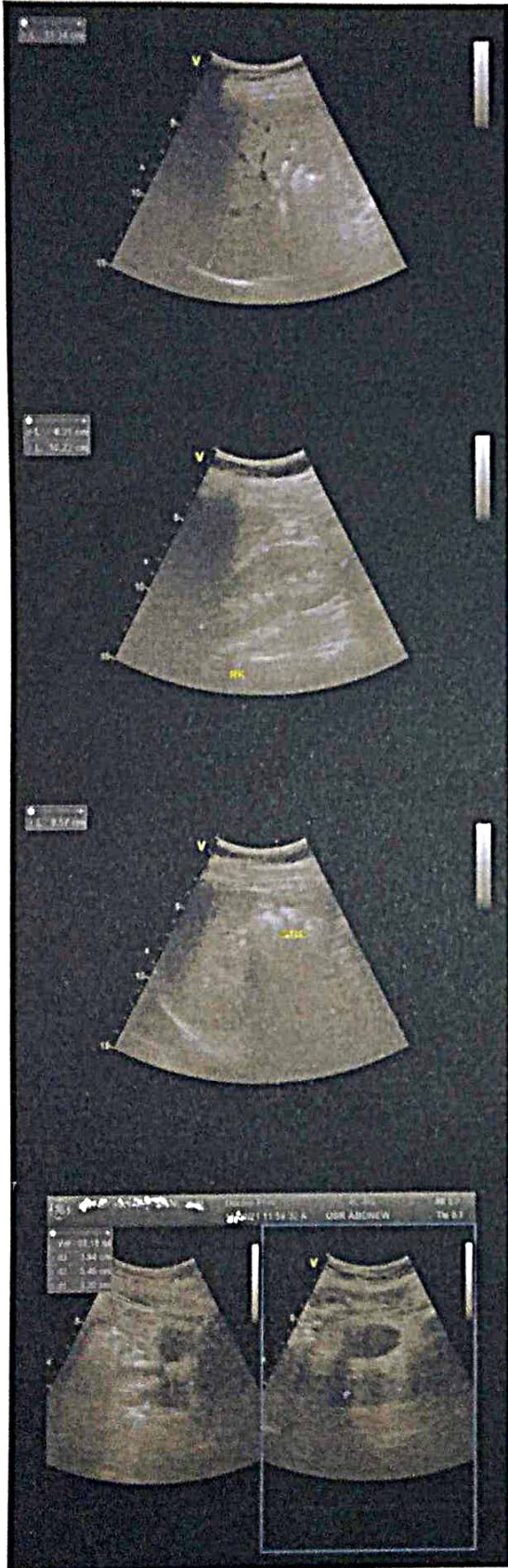DR. PLUS HEALTHCARE CENTRE  
NATHANI HEIGHTS, B-WING  
42, MUMBAI CENTRAL (EAST)



Name LT ANIRUDDHA SOHONI

Sex Male

Age 54







# Dr-Plus Healthcare Centre

NATHANI HEIGHTS, B-Wing, Shop No. 42, Ground Floor, Opp. Mumbai Central Station (East), Mumbai - 400 008.

Full Name LT ANIRUDDHA SOHONI 54/M 16/08/2021  
Life to be assured:

	Type of Test	Actual Reading	Normal Range
1	Fasting Blood Sugar	96	70-100 mg%
2	PPBS	132	110 TO 140 mg%
3	Total Cholesterol	192	120-200 mg%
4	VERY LOW DENSINTY LEVEL(VLDL)	23	10-30 mg/dl
5	High Density Lipid (HDL)	47	40-60 mg%
6	Low Density Lipid (LDL)	145	Upto 150
7	S. Triglycerides	137	50-150 mg%
8	CHOL/HDL	4.0	Upto 5
9	HDL/LDL	0.3	
10	S. Creatinine	0.8	0.5-1.2 mg%
11	Blood Urea Nitrogen (BUN)	13	7-21 mg%
12	BUN/CREAT RATIO	16	
13	S. Proteins	6.5	6.0-7.9 mg%
14	(a) Albumin	3.5	3.5-5.5 mg%
15	(b) Globulin	3.0	2.0-3.5 mg%
16	A/G RATIO	1.16	
17	S. Bilirubin	0.7	0.3-1.3mg%
18	(a) Direct	0.4	0.0-0.8 mg%
19	(b) Indirect	0.3	0.0-0.5 mg%
20	SGOT (AST)	28	05-34 IU
21	SGPT (ALT)	33	05-40 IU
22	GGTP (GGT)	41	05-50 IU
23	SGOT/SGPT	0.8	
24	HBA1C	5.7	UPTO 6.5
25	S. Alkaline Phosphatase	98	30-115 IU
26	T3	114	80-180ng/dl
27	T4	11.1	4.6-12 ug/dl
28	TSH	3.7	0.4-4.0 mIU/L
29	SERUM URIC ACID	5.8	2.5-7.2mg/dl
30	URINE SUGAR PP	ABSENT	
31	URINE SUGAR FASTING	ABSENT	
32	BLOOD GROUP	"O"POSITIVE"	

DR. PRAKESH PATKAR  
M.D. (M.B. (Gen. Med.))  
Reg. No. 2019/05/1660



# Dr-Plus Healthcare Centre

NATHANI HEIGHTS, B-Wing, Shop No. 42, Ground Floor, Opp. Mumbai Central Station (East), Mumbai - 400 008.

Full Name of life to be assured:

LT ANIRUDDHA SOHONI

54/M

DATE:16/08/2021

## HAEMOGRAM

### Normal Range

1.	Red Blood Cell Count	4.8	[M : 4.5 - 5.6 / F : 3.5 - 5.5/cu.mm]
2.	Hb%	14.0	[M: 14-18 / F : 11-16 gm%]
3.	Hematocrit	47	[M : 40-53 / F : 30-47 %]
4.	Indices:		
(a)	MCV(Mean Corpuscular Volume)	94	[79-101 cu.mi.]
(b)	MCH(Mean Corpuscular Hb)	27	[27-32 pg]
(c)	MCHC(Mean Corpuscular Hb Concentration)	34	[32-38%]
5.	Morphology		
	Macrocytes :	--	Microcytes: -- Hypochromia: --
	Poikilocytosis:	--	Anisocytosis: --
6.	Target cells:	--	
	Spherocytes:	--	Elliptocytes: --
7.	<b>TOTAL W.B.C.Count</b>	7,600	{4000-11000/cu.mm}
Differential Count			
a)	Neutrophils :	63	[45 - 70%] c) Eosinophils: 05 [01 - 06%]
b)	Lymphocytes :	29	[20 - 45%] d) Monocytes: 06 [00 - 08%]
e)	Basophils :	00	[00 - 01%]
8.	<b>Platelets :4.0</b>	1.5-4.5 Lacks/cu.mm	
9.	<b>Erythrocyte Sedimentation Rate:11</b>	20 mm at end of 1 hour	Method : Westergrens

## ROUTINE URINE EXAMINATION (RUA)

### 1. Physical Examination:

(i)	Colour:	PLAN YELLOW	(ii)	Sediment:	CLEAR
(iii)	Transparency:	ABSENT	(iv)	Reaction:	ACIDIC
(v)	Specific gravity	1.010			

### 2. Chemical Examination:

(i)	Protein :	ABSENT	(ii)	Sugar:	ABSENT
(iii)	Bile salt:	ABSENT	(iv)	Bile pigment:	ABSENT

### 3. Microscopic Examination:

(i)	Red Blood Cells:	ABSENT	(ii)	Epithelial Cells:	ABSENT
(iii)	Crystals:	ABSENT	(iv)	Pus Cells:	02 TO 03/HPF
(v)	Casts:	ABSENT	(vi)	Deposits:	ABSENT
(vii)	Bacteria's :	ABSENT			

**DR. RAKESH PATKAR**  
M.D., D.N.B. (Pathology)  
Reg. No. 2013/05/1660





# Dr-Plus Healthcare Centre

NATHANI HEIGHTS, B-Wing, Shop No. 42, Ground Floor, Opp. Mumbai Central Station (East), Mumbai - 400 008.

Patient's Name : LT ANIRUDDHA SOHONI

Report Date : 16/08/2021

Referred By : DR.HARI CHHABLANI

Age : 54 Years

Sex : MALE

## X- RAY CHEST PA

- No active pulmonary lesion seen.
- Trachea and mediastinum are in midline .
- Cardiac size and configuration are within normal limits .
- Pleural cavities are clear .
- Domes of diaphragm are smooth in outline.
- Bony thorax is normal .

  
Radlologist

DR. A. J. MAZUMDAR

MD. DMRE,MDRD

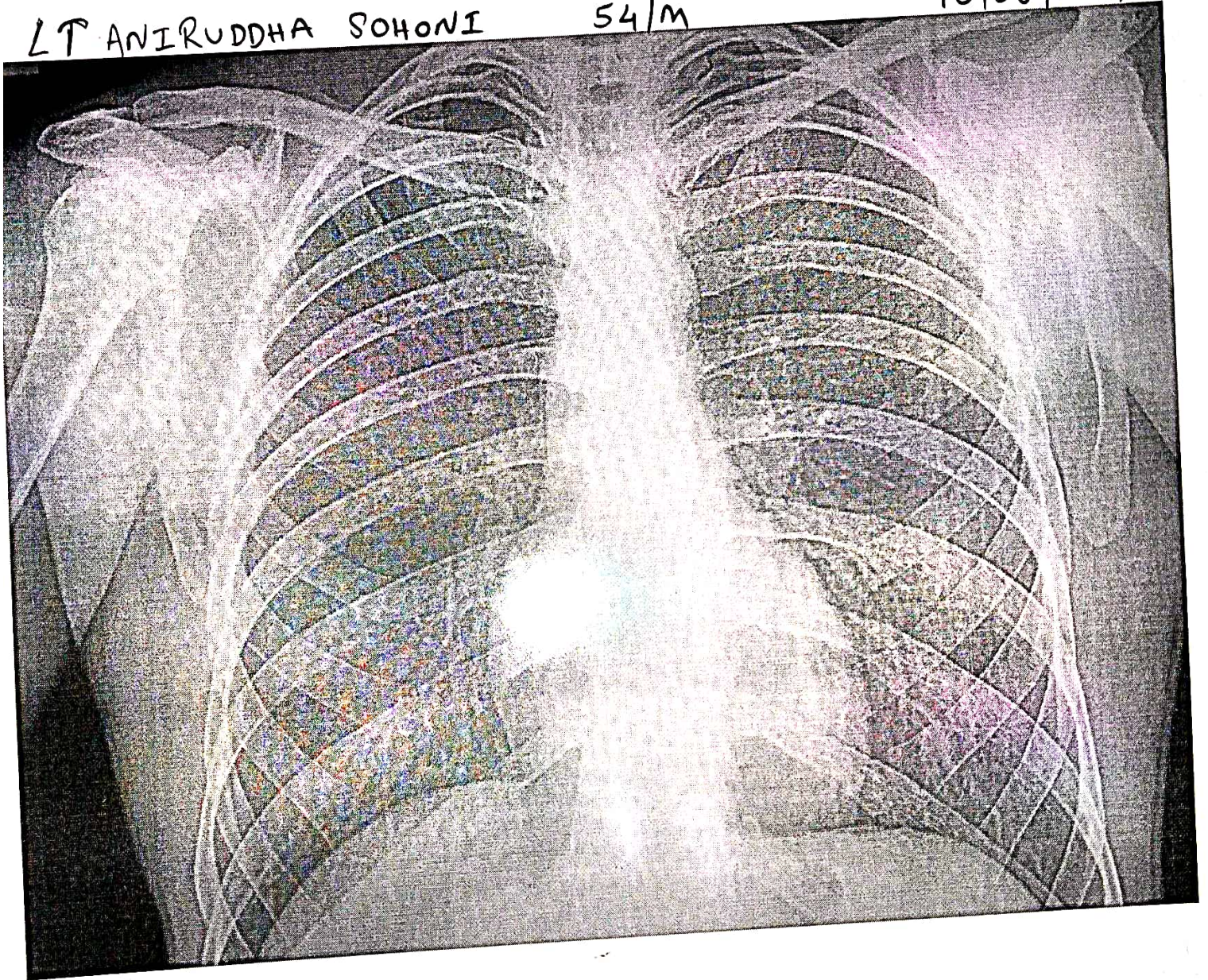
'DR. PLUS HEALTHCARE CENTRE'  
NATHANI HEIGHTS', B-WING,  
#2, MUMBAI CENTRAL (EAST)



LT ANIRUDDHA SOHONI

54/M

16/08/2021







**Dr. Hari Chhablani**

Cardiometabolic Physician & Intensivist  
M.B.B.S., F.C.C.P. (RESP. MED.), PGDHHM,  
PGDMLS, FELLOW INTENSIVE CARE MED.

ATTACHED TO: Wockhardt Hospital • Saifee Hospital • Apollo Spectra Hospital

NATHANI HEIGHTS, B-Wing, Shop No. 42, Ground Floor, Opp. Mumbai Central Station (East),  
Mumbai - 400 008. • Cell : 98206 46163 • E : drharichhablani@gmail.com

## PHYSICIAN REPORT

31/07/2021

NAME : LT ANIRUDDHA SOHONI

AGE/SEX: 54/M

PRESENTING COMPLAINS: K/C/O: HTN SINCE 3 YEARS ON TELMA-40 AND METOPROLOL -50.

K/C/O : GOUT SINCE 3 YEARS ON FEBUXOSTAT-40.

PAST HISTORY: H/O L4-5-S1 DECOMPRESSION--2001

FAMILY HISTORY: NOT SIGNIFICANT

ADDICTION: NIL

P: 82

BP: 110/70

RS: CLEAR

CVS: S1,S2 REGULAR

PA: SOFT

CNS: CLINICALLY NAD

ECG: WNL

CXR: WNL

LABS: ATTACHED

USG ABDO-PELVIS: WNL

EYE CHECKUP: WNL

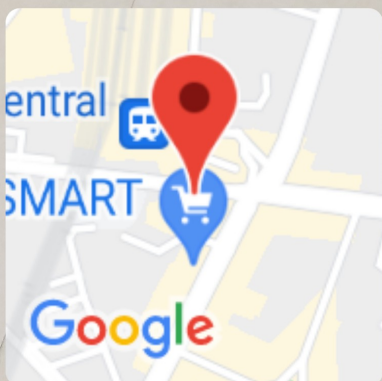
IMPRESSION : FIT ON CLINICAL MEDICAL EXAMINATION.

DR. HARI CHHABLANI

**DR. HARI CHHABLANI**

M.B.B.S., F.C.C.P. (RESP. MEDICINE), PGDHHM, PGDMLS,  
FELLOW INTENSIVE CARE  
MMC REG. NO. - 91702





## Mumbai, Maharashtra, India

Shop No. - 3, Akhil Bharti Bhavan, Belasis Road, Tardeo, Mumbai - 400034,  
Marzban Parsi Colony, Dalal Estate, Mumbai Central, Mumbai, Maharashtra 400008,  
India

Lat 18.968757°

Long 72.819994°

16/08/21 09:17 AM