

**Diwakar Diagnostic Centre
E-7/636, Arera Colony, Bhopal**

822 / MITESH LOKHANDE / 36 Yrs / M / 0 Cms / 0 Kg Date: 08-Oct-2022 Refd By : BOB

Report

ACHPL

(GEM213180307)(R)Allengers

Report :

TEST OBJECTIVE : ROUTINE CHECK UP
RISK FACTOR : MALE
ACTIVITY : MODERATE ACTIVE
MEDICATION : NONE
REASON FOR TERMINATION : TEST COMPLETE, HEART RATE ACHIEVED
EXERCISE TOLERANCE : GOOD
EXERCISE INDUCED ARRHYTHMIAS : NO
HAEMODYNAMIC RESPONSE : NORMAL
CHRONOTROPIC RESPONSE : NORMAL
FINAL IMPRESSION : STRESS TEST IS NEGATIVE FOR EXERCISE INDUCED ISCHAEMIC HEART DISEASE

M



डिवाकर डायग्नोस्टिक सेंटर



E-7/636, पंजाब नगरातील बँक कॅम्पस, मंगल रोड, अहमदाबाद (ग.प.)
 फोन: 0755-2465288, 0755-3520545 मो: 9826340190

Pt Name :- Mr. Mithlesh Lokhande
 Age :- 36/M
 Lab. No. :- 01
 Date :- 08/10/2022

EXAMINATION OF BLOOD

TEST	RESULT	NORMAL VALUE
Haemoglobin	11.3gms%	Female 12-16gms%, Male 14-18gms%
Red Cell count	5.54	4.5-5.6 million /cumm
Platelete Count	3.35	1.5-5.6 Lac/cumm
Leucocytes per.cumm	5300/cumm	5000-11000/cumm
Neutrophils	60%	50-70%
Lymphocytes	32%	20-40%
Eosinophils	04%	0-7%
Monocytes	04%	2-8%
PCV	38.0	37-47
MCV	68.7	76-96
MCH	20.3	27-32
MCHC	29.7	31-35
ESR	10	Male 0-9, Female 0-20mm/FHR
Blood Group	"B" Positive	By slide method
Total Serum Cholesterol	178.0	100-250 mg%
Serum Triglyceride	148.0	Up to 150 mg%
Serum Cholesterol HDL	51.0	Up to 65 mg%
Serum Cholesterol LDL	97.4	Up to 125 mg%
LDL	29.6	Up to 30 mg%
S.Bilirubin(Total)	0.9	0.2-1.0mg/dl
Direct	0.5	0.0-0.25mg/dl
Indirect	0.4	
SGOT	26.0	5-35U/L
SGPT	30.0	8-40U/L
Alk Phosphatase	8.9	3-13 KA units
S. Protein(Total)	7.0	6.0-8.0mg%
Albumin	4.9	3.7-5.3mg%
Globulin	2.4	1.5 to 3.5 mg%
Blood Urea	22.0	Up to 40 mg%
S.Creatine	0.98	0.5-1.4mg/dl
S. Uric Acid	6.0	3.5-7.5mg%
GGT	24.0	5-35 U/L/dl
Fasting Blood Sugar	96.2	Up to 110 mg%
PP Blood Sugar	120.0	Up to 125 mg%
Glycosylated Hemoglobin	5.6	Below - 6.0 % -Non Diabetic control 6-7 % -Excellent control Above- 8 % -Poor control
Thyrod Stimulating Hormone(TSH)	2.9	0.27-4.2

Pathologist

All test have technical limitation. Collaborative clinic pathological interpretation is mandatory. In case of disparity test may be repeated immediately. Typographical mistakes should be get correct instantly. This report is not valid for medico legal purpose



Dr. B.M. Agarwal
 MBBS, DCP
 Consultant Pathologist



822 / MITESH LOKHANDE / 36 Yrs / M / 0 Cms / 0 Kg Date: 08-Oct-2022 Refd By : BOB

Stage	Time	Duration	Belt Speed (mph)	Elevation	METs	Rate	% THR Achieved	BP	RPP	PVC	Comments
Supine	00:12	0:01	00.0	00.0	01.0	74	40 %	120/80	088	00	
Standing	00:30	0:01	00.0	00.0	01.0	76	41 %	120/80	091	00	
HV	00:47	0:01	00.0	00.0	01.0	079	43 %	120/80	094	00	
Warm Up	01:00	0:01	01.0	00.0	01.0	081	44 %	120/80	097	00	
ExStart	01:16	0:06	01.7	10.0	01.1	073	40 %	120/80	087	00	
BRUCE Stage 1	04:16	3:00	01.7	10.0	04.7	088	48 %	126/82	110	00	
BRUCE Stage 2	07:16	3:00	02.5	12.0	07.1	099	54 %	130/84	128	00	
BRUCE Stage 3	10:16	3:00	03.4	14.0	10.2	118	64 %	140/90	165	00	
PeakEx	10:29	0:13	04.2	16.0	10.5	120	65 %	140/90	168	00	
Recovery	11:28	1:00	00.0	00.0	04.3	086	47 %	136/84	116	00	
Recovery	12:28	2:00	00.0	00.0	01.0	071	39 %	120/80	085	00	
Recovery	12:48	2:19	00.0	00.0	01.0	071	39 %	120/80	085	00	

Findings :

- Exercise Time : 09:14
- Max HR Attained : 120 bpm 65% of Target 184
- Max BP Attained : (Sys) 140/90
- Max WorkLoad Attained : 10.5 Good response to induced stress
- Test End Reasons : Test Complete, Heart Rate Achieved



Dr. B. M. Agarwal
MBBS, DCP
Pathologist
Consultant Pathologist

A. PHYSICAL EXAMINATION	
1. Colour	Pale Yellow
2. Appearance	Clear
3. Specific Gravity	Q.N.S.
B. CHEMICAL EXAMINATION	
1. Reaction	Acidic
2. Albumin	Nil
3. Sugar	Nil
4. Bile Salts	Absent
C. MICROSCOPIC EXAMINATION	
Pus Cells	2-3/HPF
R.B.C.	Nil
Epithelial Cell	2-3/HPF
Cast	Nil
Crystals(Cal.Oxa)	Nil
Bacteria	Nil
Amorphous	Nil
T. Vaginatis	Nil

URINE ANALYSIS

Pt Name :- Mr. Mithlesh Lohande
Age :- 36/M
Lab. No. :- 01
Date :- 08/10/2022

फोन: 0755-2465288, 0755-3520545 फा: 9826340190

E-7/636, पंजाब रोड, अरुण कालोनी भीमल (म.प.)

डिवाकर डायग्नोस्टिक सेंटर





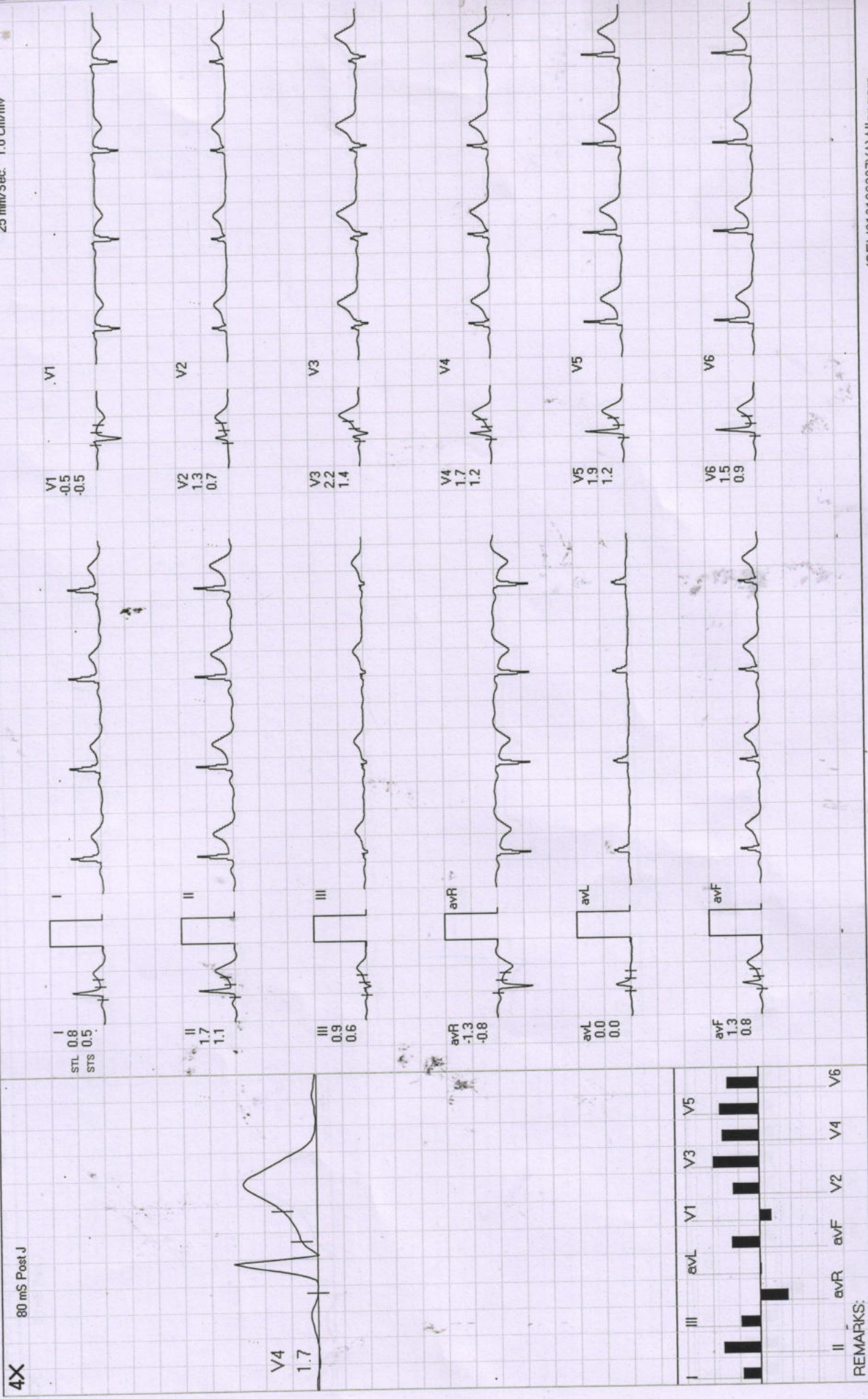
SUPINE

Diwakar Diagnostic Centre

822 / MITESH LOKHANDE / 36 Yrs / M

Date: 08-Oct-2022 10:27:09 AM METS: 1.0/74 bpm 40% of THR BP: 120/80 mmHg Raw ECG/BLC On/ Natch On/ HF 0.05 Hz/LF 20 Hz

ExTime: 00:11 0.0 mph, 0.0%
25 mm/Sec. 1.0 Cm/mV



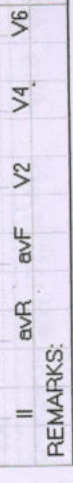
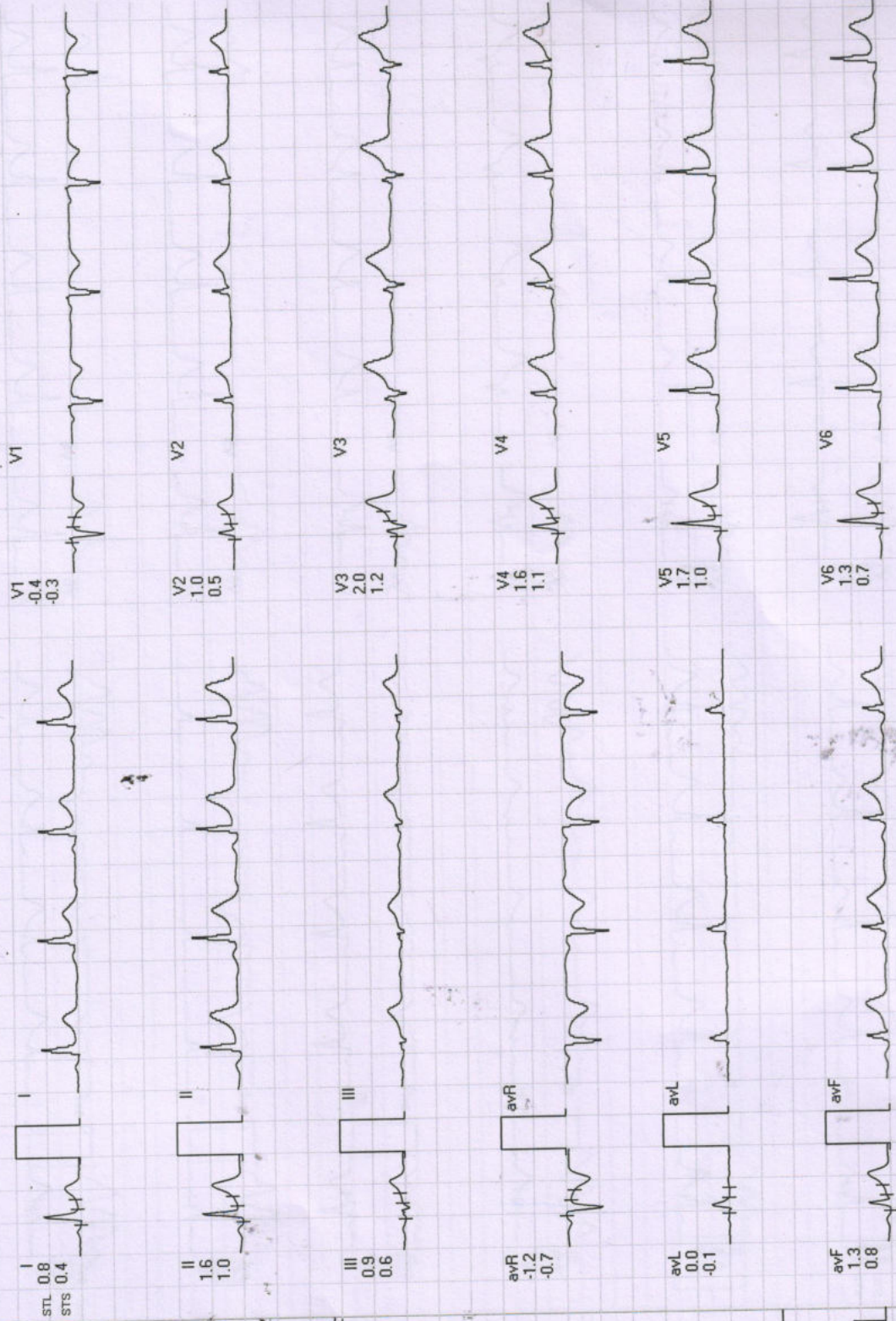(GEM213180307)(A)Allengers

ExTime: 00:29 0.0 mph, 0.0%

Date: 08-Oct-2022 10:27:09 AM METS: 1.0/76 bpm 41% of THR BP: 120/80 mmHg Raw ECG/BLC On/ Notch On/ HF 0.05 Hz/LF 20 Hz

25 mm/Sec. 1.0 Cm/mV

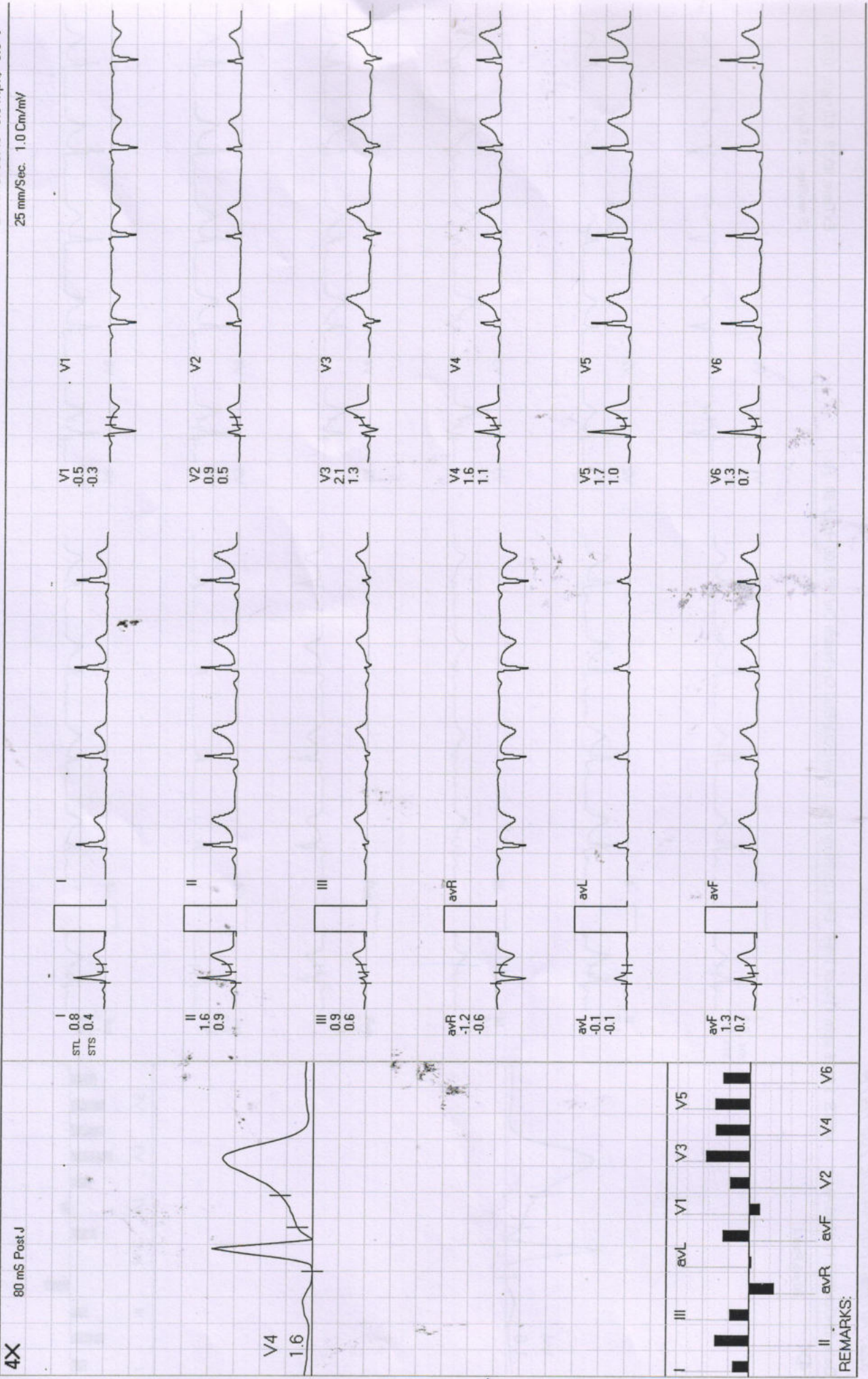
4X 80 mS Post J



REMARKS:

Date: 09-Oct-2022 10:27:09 AM METS: 1.0/ 79 bpm 42% of THR BP: 120/80 mmHg Raw ECG/BLC On/ Natch On/ HF 0.05 Hz/LF 20 Hz

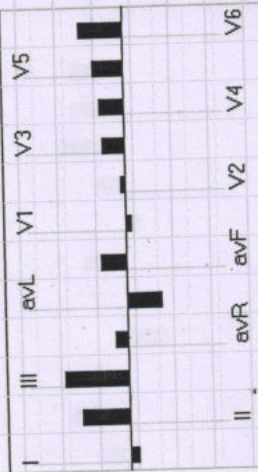

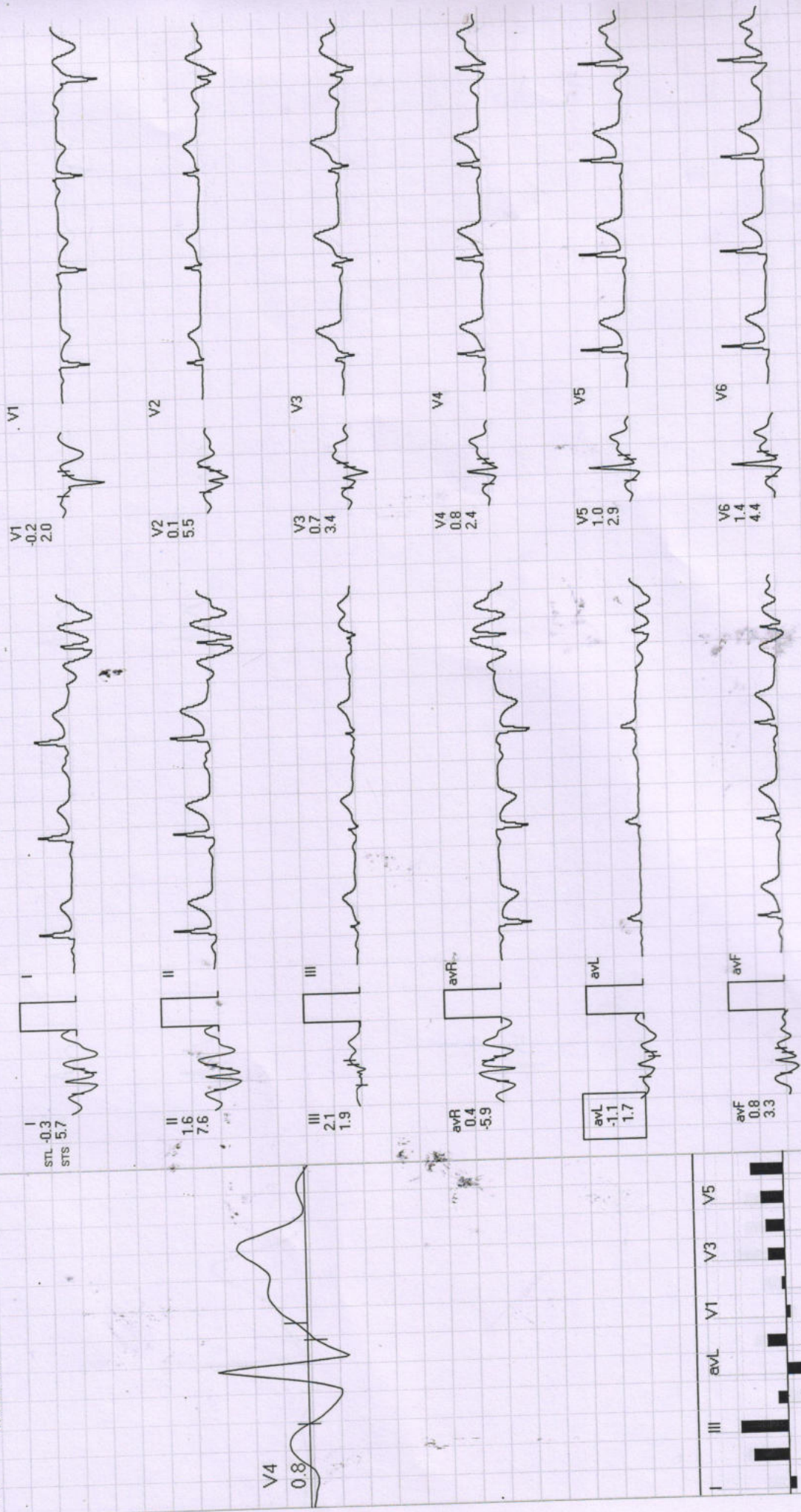
ExTime: 00:46 0.0 mph, 0.0%



EXTime: 00:00 0.0 mph. 0.0%
25 mm/Sec. 1.0 Cm/mV

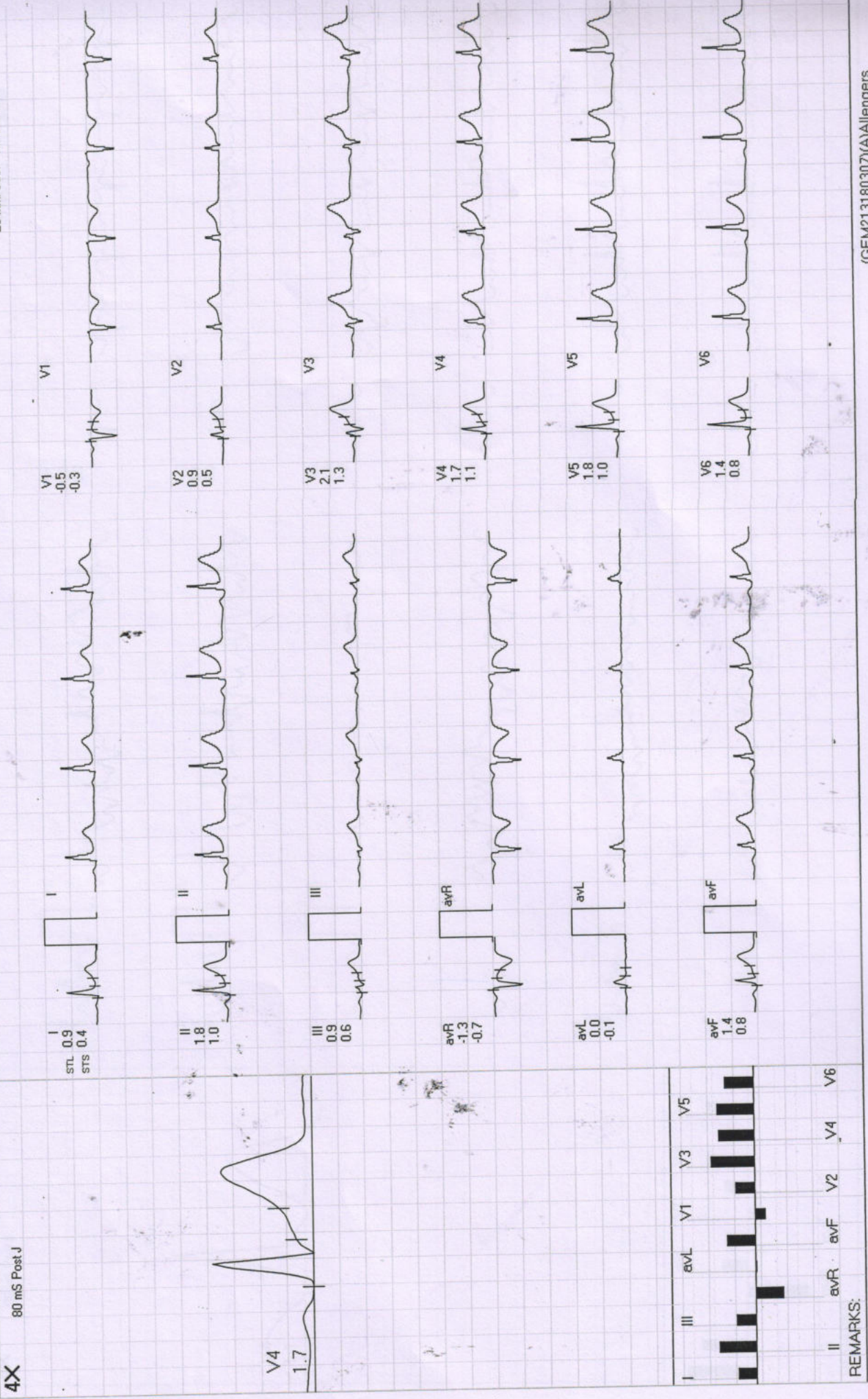
Date: 08-Oct-2022 10:27:09 AM METS: 1.0/73 bpm 39% of THR BP: 120/80 mmHg Raw ECG/BLC On/ Natch On/ HF 0.05 Hz/LF 20 Hz

4X 40 mS Post J



Date: 08-Oct-2022 10:27:09 AM METS: 1.0/81 bpm 44% of THR BP: 120/80 mmHg Raw ECG/BLC On/ Natch On/ HF 0.05 Hz/LF 20 Hz

ExTime: 00:59 1.0 mph. 0.0%
25 mm/Sec. 1.0 Cm/mV

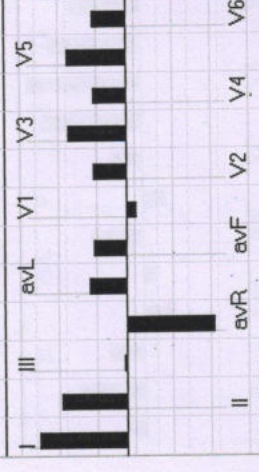
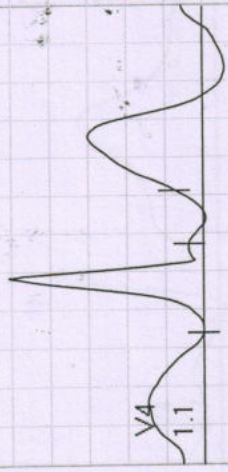
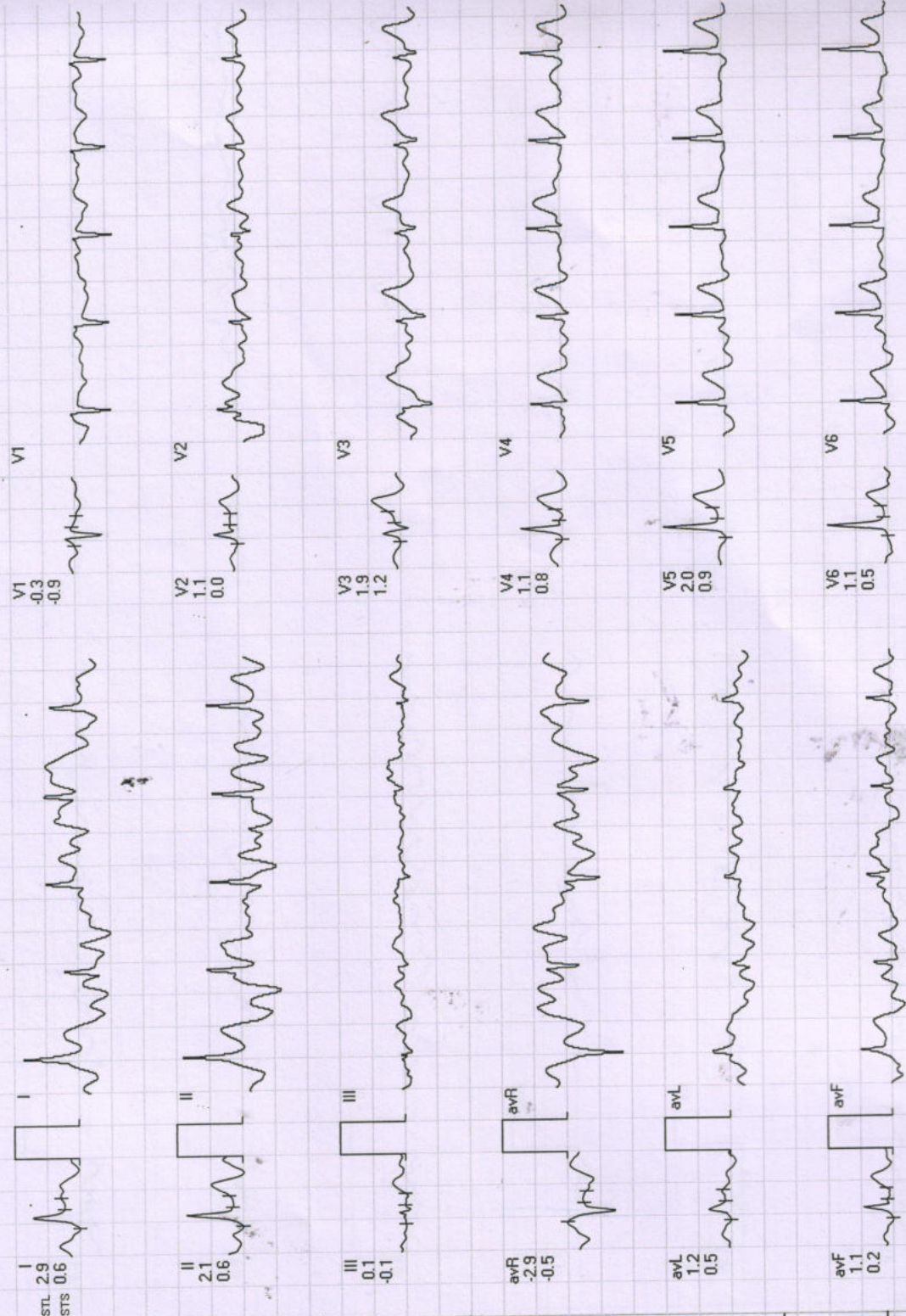


REMARKS:



Date: 08-Oct-2022 10:27:09 AM METS: 4.7/88 bpm 47% of THR BP: 126/82 mmHg Rew ECG/ BLC On/ Notch On/ HF 0.05 Hz/LF 20 Hz ExtTime: 03:00 1.7 mph, 10.0%

4X 80 mS Post J 25 mm/Sec. 1.0 Cm/mV



REMARKS:

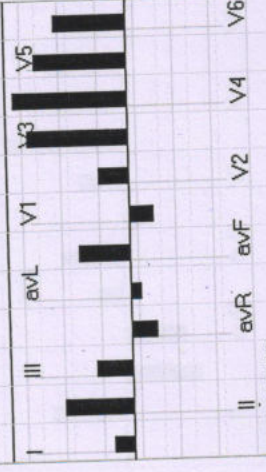

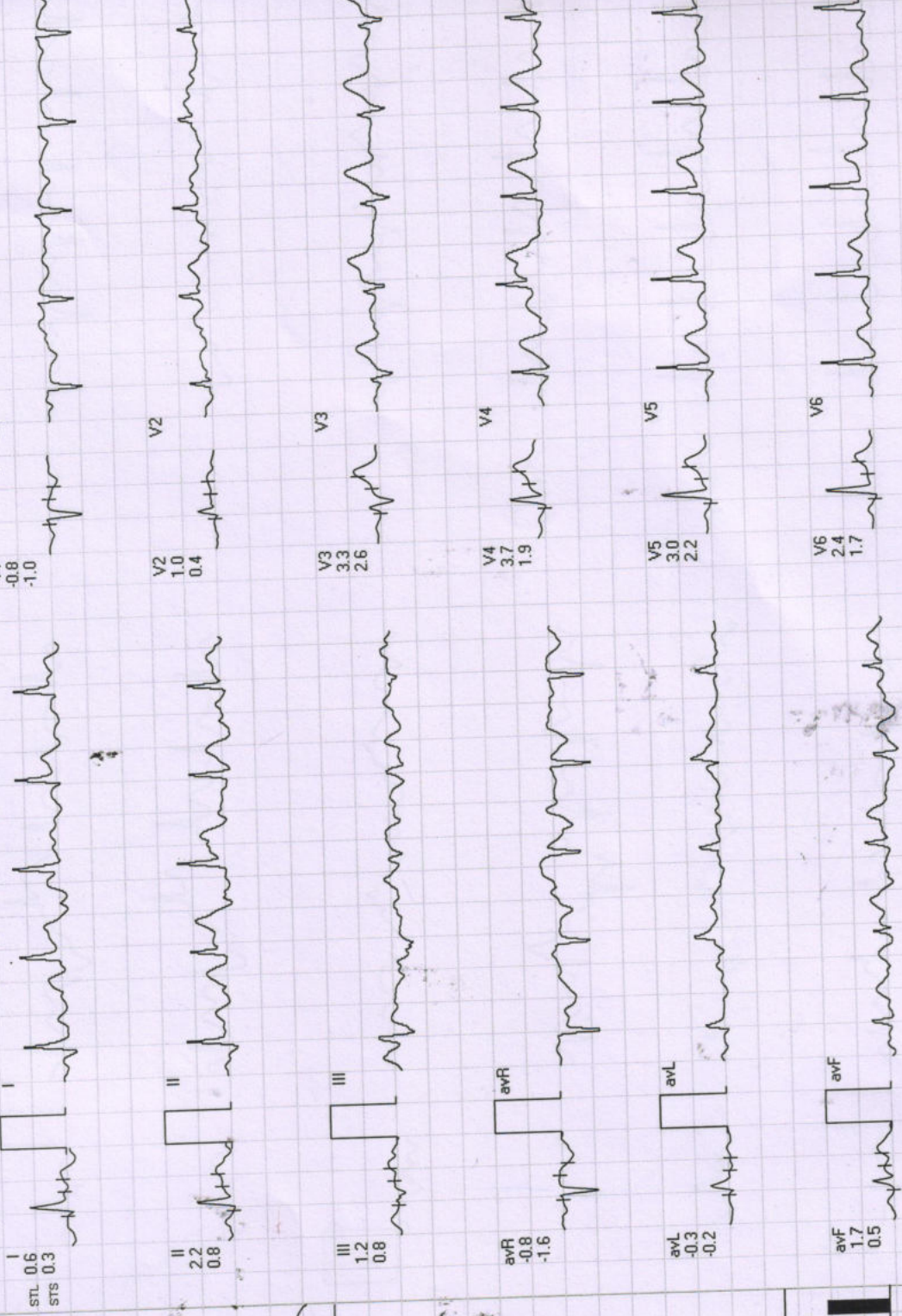


ExTime: 06:00 2.5 mph. 12.0%
25 mm/Sec. 1.0 Cm/mV

Date: 08-Oct-2022 10:27:09 AM METS: 7.1/99 bpm 53% of THR BP: 130/84 mmHg Raw ECG/ BLC On/ Notch On/ HF 0.05 Hz/LF 20 Hz

4X

80 mS Post J

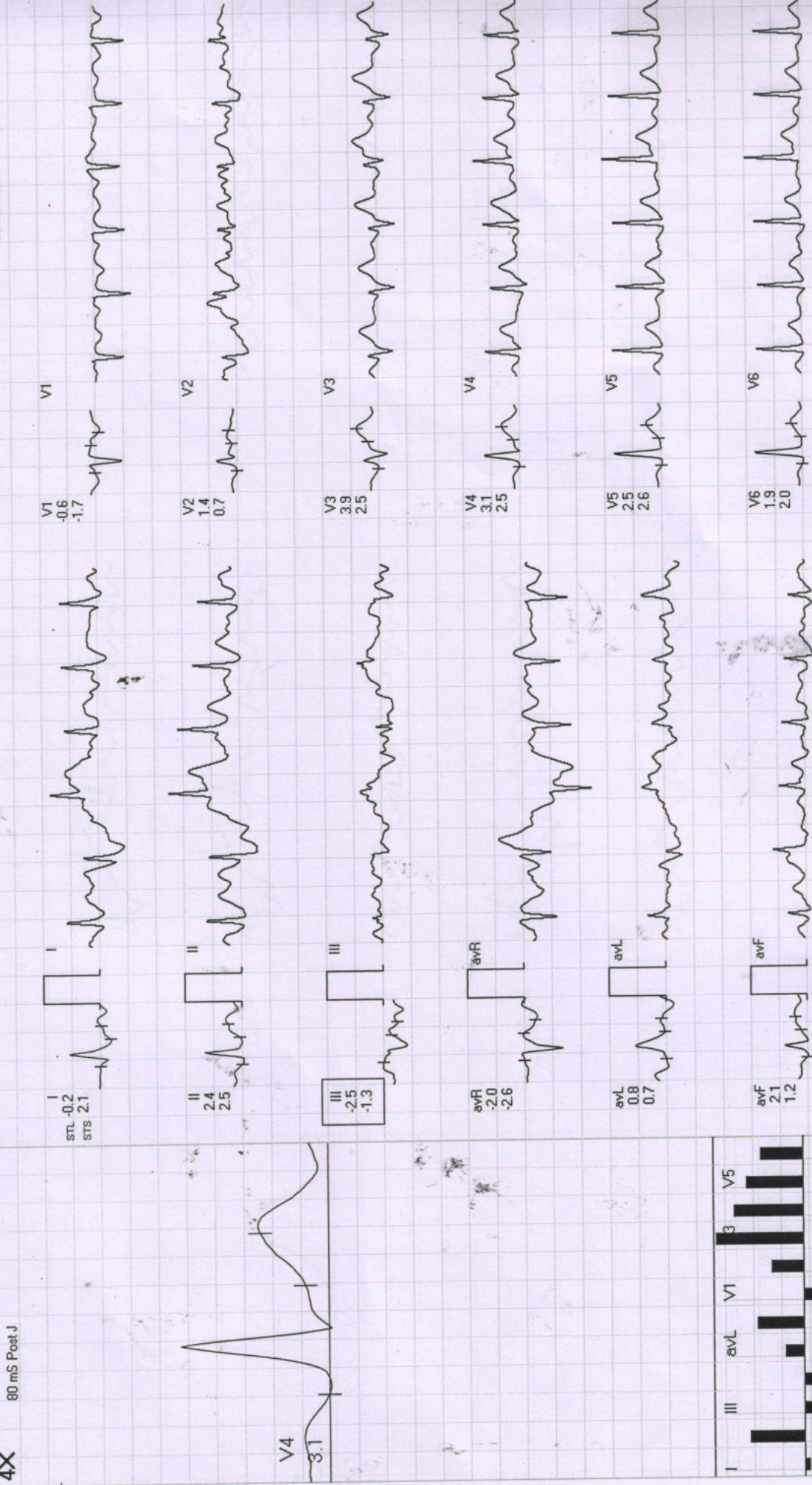


REMARKS:

Date: 08-Oct-2022 10:27:09 AM METS: 10.2/118 bpm 64% of THR BP: 140/90 mmHg Raw ECG/BLC On/ HF 0.05 Hz/LF 20 Hz

ExTime: 09:00 3.4 mph, 14.0%
25 mm/Sec. 1.0 Cm/mV

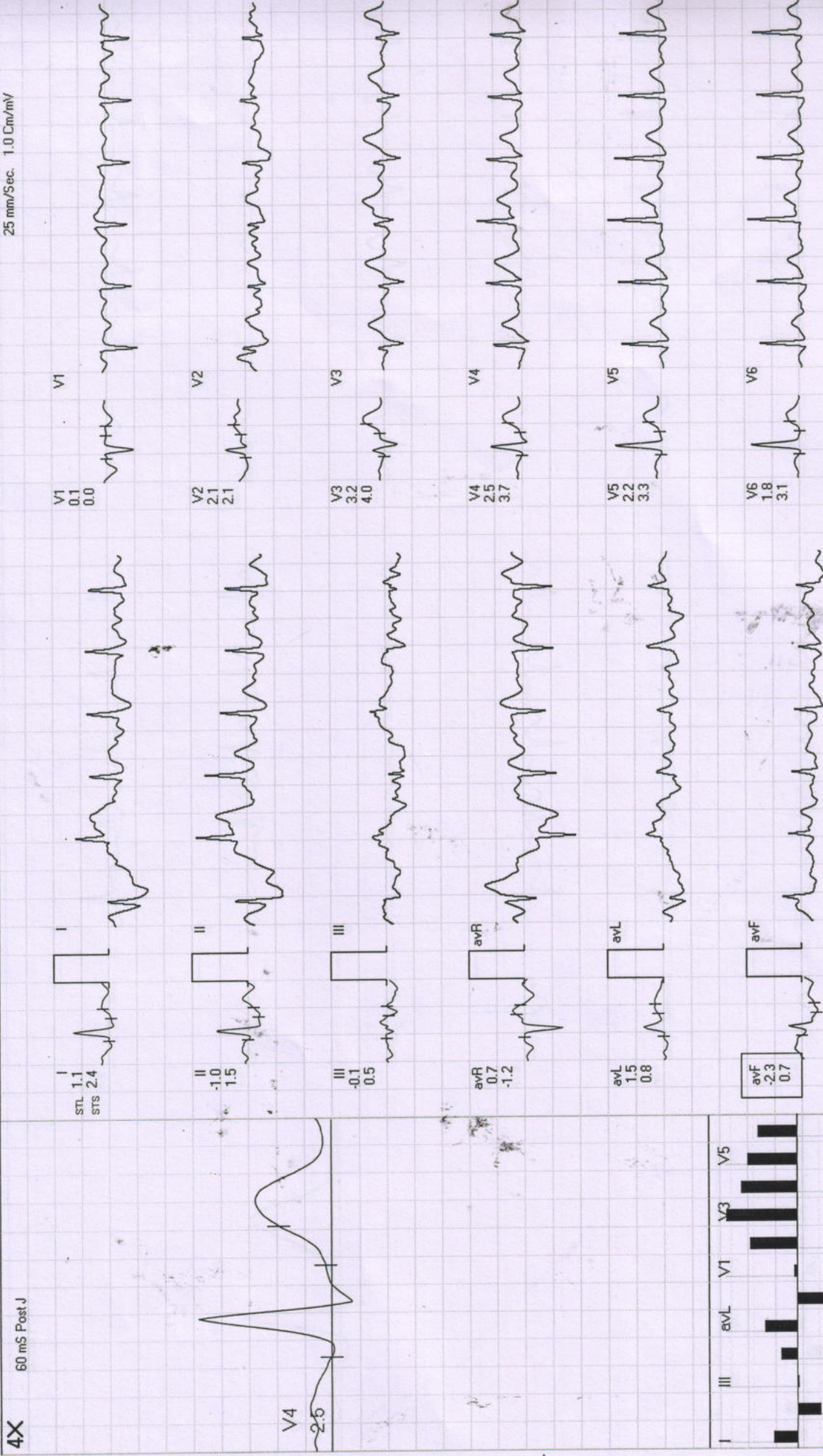
4X



REMARKS:

Date: 08-Oct-2022 10:27:09 AM METS: 10.5/120 bpm 65% of THR BP: 140/90 mmHg Rew ECG/BLC On/Notch On/HF 0.05 Hz/LF 20 Hz ExTime: 09:13 4.2 mph, 16.0%

4X 60 mS Post J



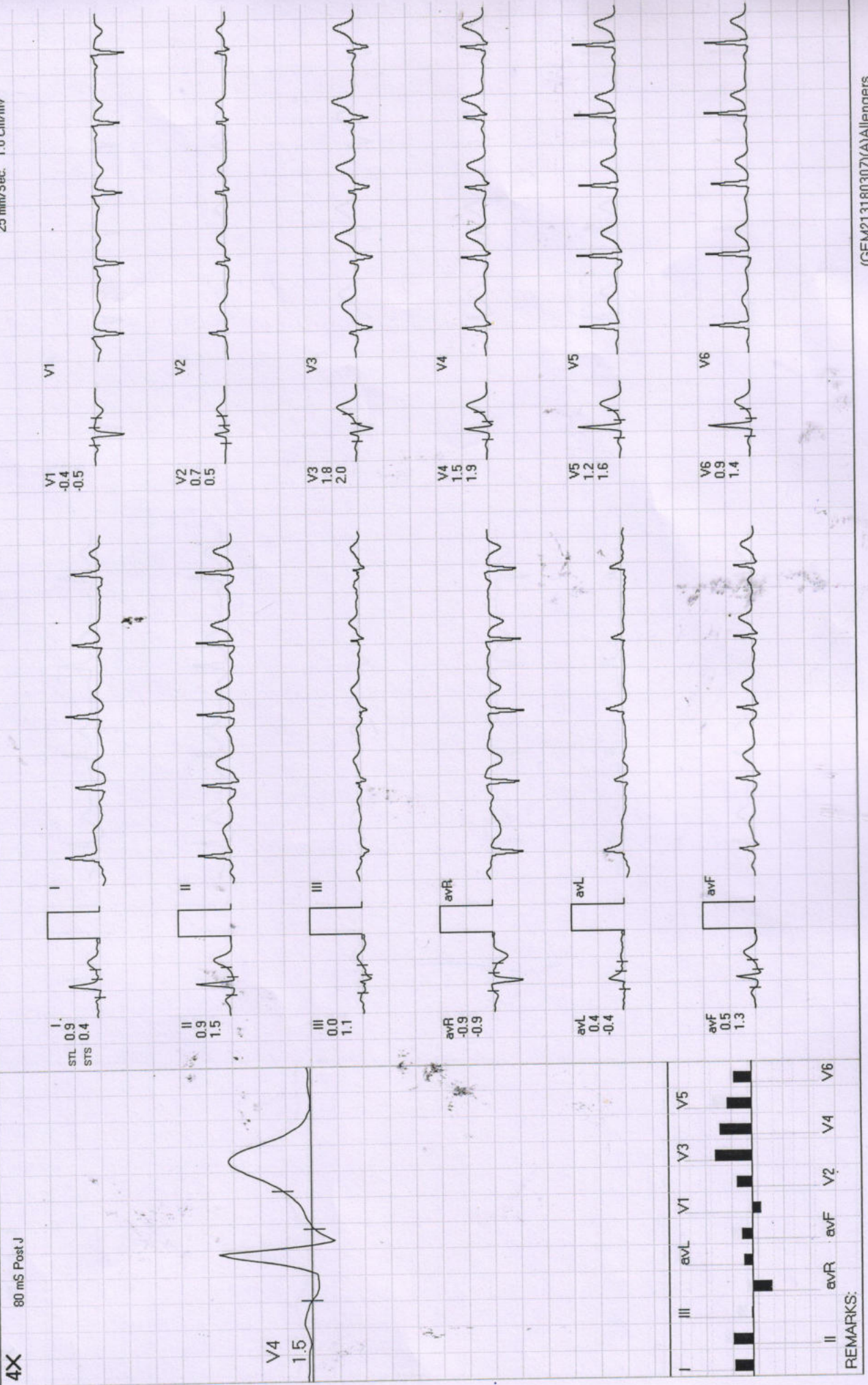
REMARKS:



Date: 08-Oct-2022 10:27:09 AM METS: 4.2 / 86 bpm 46% of THR BP: 136/84 mmHg Rew ECG/BLC On/ Notch On/ HF 0.05 Hz/LF 20 Hz

ExTime: 09:13 0.0 mph, 0.0%

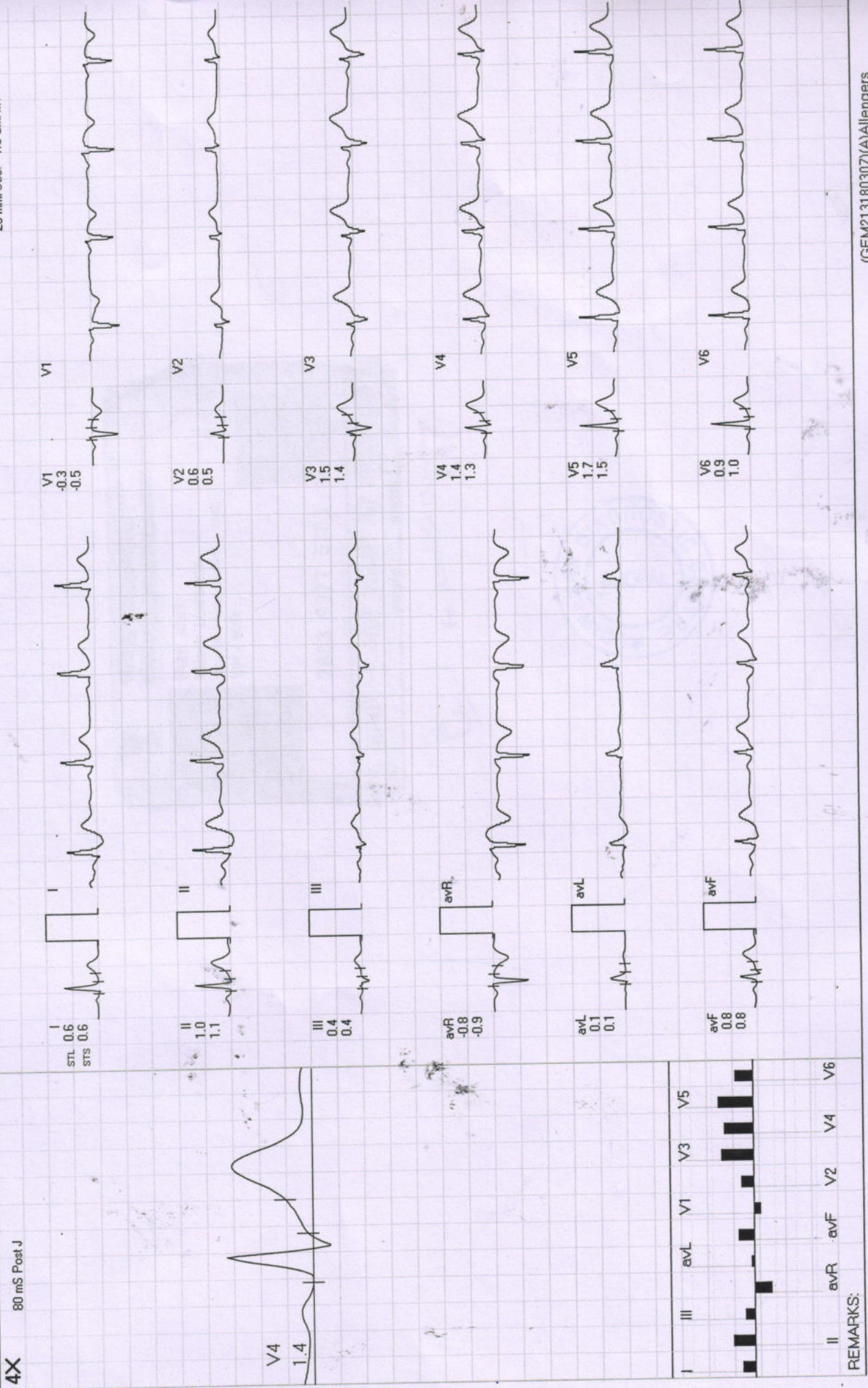
25 mm/Sec. 1.0 Cm/mV





Date: 08-Oct-2022 10:27:09 AM METS: 1.0 / 71 bpm 38% of THR BP: 120/80 mmHg Raw ECG/BLC On/ Natch On/ HF 0.05 Hz/LF 20 Hz

ExTime: 09:13 0.0 mph, 0.0%
25 mm/Sec. 1.0 Cm/mV



भारत सरकार
GOVERNMENT OF INDIA

मितेश लोखंडे
Mitesh Lokhande
जन्म वर्ष / Year of Birth : 1986
पुरुष / Male

7883 9377 5783

आधार - आम आदमी का अधिकार



For Health Checkup

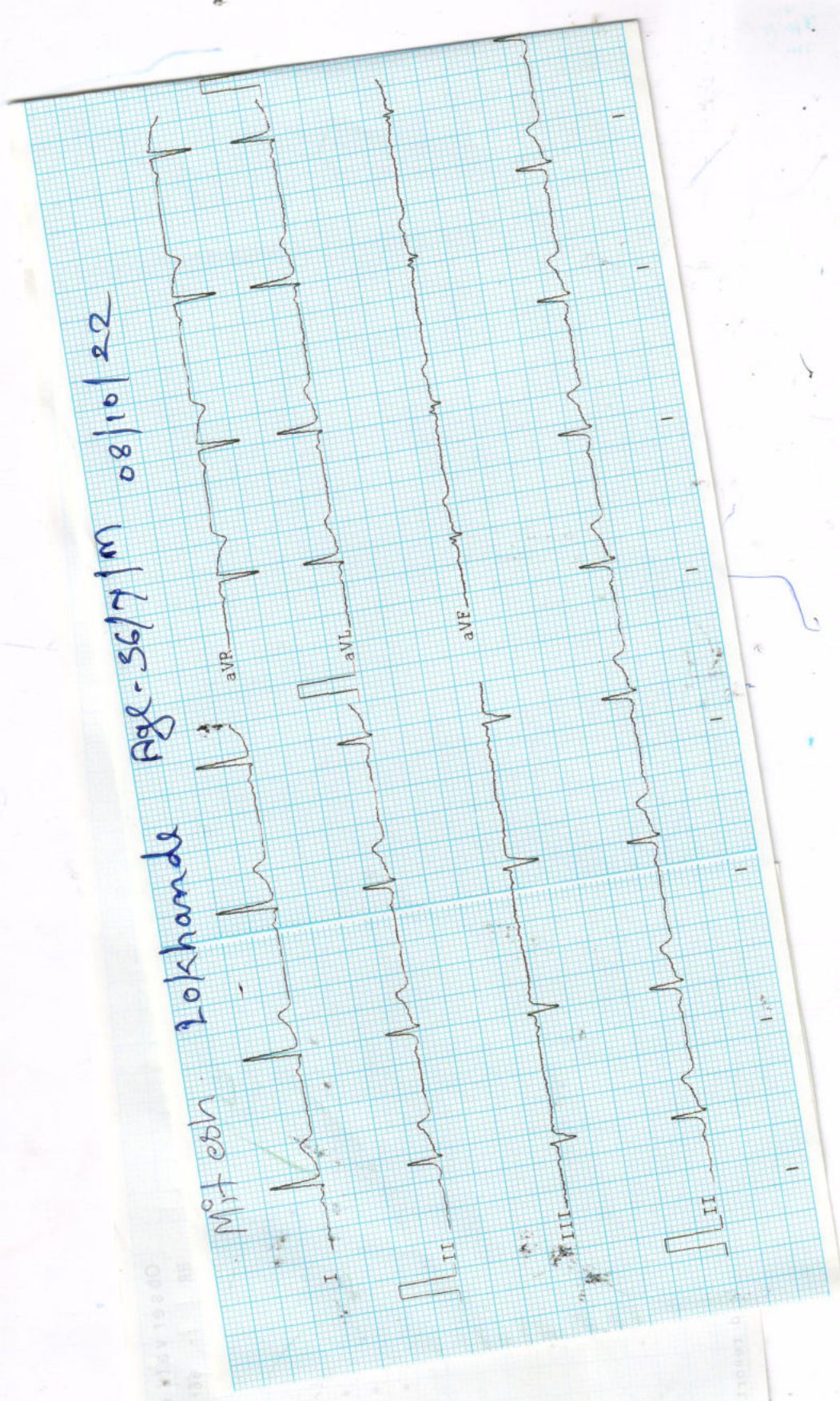


Agg-56/71m 08/10/22

Lokharade

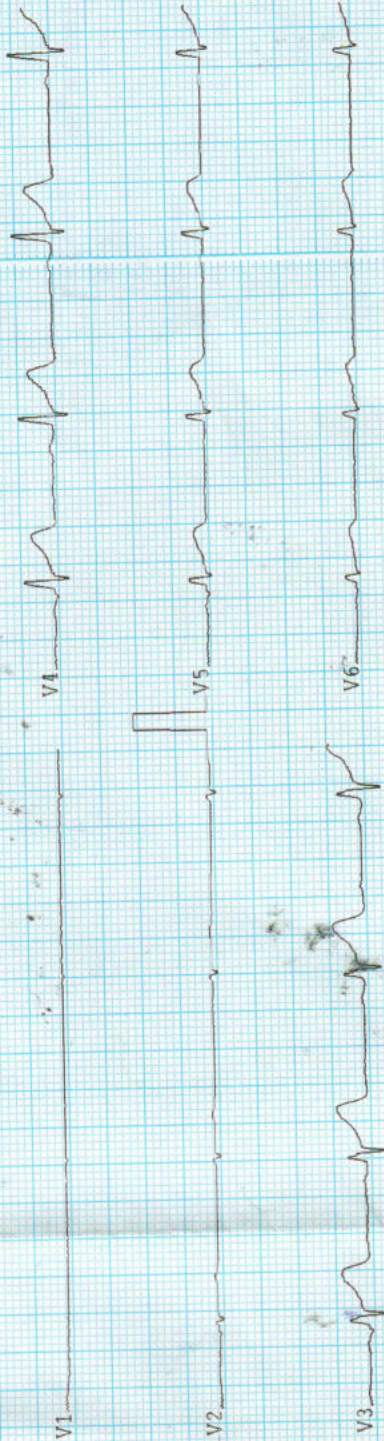
Mit ebn

210 x 150 x 1580
200 100 50
25 50 100 150



Observations :-

HR :- 66 bpm
R-R :- 898 ms
P-R :- 881 ms
QRS :- 70 ms
QT/QTc :- 341/359 ms
P Axis :- 47 °
R Axis :- 37 °
T Axis :- 56 °



Remarks :-

Unconfirmed report

ARROW CE

ALLENGERS PISCES-A-103 (Ver-2.09)

ARROW CE

PTO

Right Kidney is normal in size, shape and position. Corticomedullary differentiation (CMD) is well maintained. Normal cortical thickness is noted. No E/O hydronephrosis or calculus is noted.

Pancreas appear normal in size, shape and echo texture with smooth contour. No peripancreatic pathology seen. (Not seen due to gases) Spleen is normal / enlarged in size and normal in echo texture. IVC and aorta appear to be normal. No evidence of lymphadenopathy is noted. No evidence of free fluid is noted.

Gall Bladder is physiologically well distended / collapsed. No E/O echogenic foci in GB lumen. GB wall is normal / thickened. No E/O pericholecystic collection. common duct reveals normal course and caliber.

Liver appears normal / enlarged in size and shape with smooth in outline. Normal / increased parenchymal echogenicity is noted. No E/O focal lesion / IHR dilatation is seen. Hepatic veins and portal veins appear normal. *gs I fatty livers*
No E/O Subdiaphragmatic Collection.

WHOLE ABDOMEN ULTRASOUND REPORT

Indication :

Name : Mrs. *Mitlesh Kulkarni* 36/male
R/B *Health Check-up*
Date *8/10/22*
Age *36* YRS./F

श्री. सविता रडियोलॉजिक
34, पंतल, माहिती अदिति आर्कड, शाहपुरा मस्जिद के पास
भरत नगर रोड, ई-7/194, अररा कॉलोनी, भीपाल - 462038
Mob. : 8989649694, 9516333619
Clinic Registration : CL/5392/Jun/2017
PNDT Registration : MPPCPNDT/BPL/2017/206



Left Kidney is normal in size, shape and position. CMD is well maintained. Normal cortical thickness is noted. No E/O hydronephrosis or calculus is noted.

Urinary Bladder is well distended (physiological) / collapsed. Its contents are echo free. No E/O bladder wall thickening is noted. Post-void residue is insignificant.

Prostate is normal in size, shape and echo texture with smooth outline. No E/O focal lesion is noted.

Uterus is ante/retroverted and normal in size, shape and echotexture with smooth outline. No E/O focal lesion is noted, endometrial echo appear normal. Cervical and vaginal shadows appear normal.

Right Ovary appears Enlarged / Normal in size, shape and echo texture.

Left Ovary appears Enlarged / Normal in size, shape and echo texture.

Impression : Normal study.

Grade I Fatty liver.

[Handwritten signature]

Advised clinical Correlation.

