

Dr. Vaibhav Agrawal

Consultant- Internal Medicine and Critical Care
MD (Medicine), PGDC, PGDD & RD
Regd. No. - 2008/09/3399



26/3/22

Mrs. Susita Ji Nazareth

31/8/15

Came for routine
health CIP

- Family H/O DM & HT

- T2H - 4.2

- H/O Migraine

}
cup Beta cup Plus
→

x 1 month

↓
Sed



WOCKHARDT HOSPITALS, NAGPUR

1643, North Ambazari Road, Nagpur - 440 033. Tel : (0712) 6624444, 6624100

Fax : (0712) 2261286 Website : www.wockhardthospitals.com

Registered Office Address :- Wockhardt Towers, BKC, Bandra (East) Mumbai 400051

CIN: U85100MH1991PLC063096

Dr. Dipti Shende

MS (Obstetrics & Gynecology)

DNB (Obstetrics & Gynecology)

Consultant - Obstetrics & Gynaecology

Regd. No.: 2009031429

WOCKHARDT
HOSPITALS

LIFE
WINS

9022052483

Sanita Nazareh

Age: 31y

PNC by gynth

LMP: 15/2/22

Adv

P/S: - cx
vg (u)

- for pap smear

white
disch

- T. Fluconazole
200y

- An T - 3/5

- 2y - 3mth

- Tablet

- condom

H/V after Dg of
menstr

x 3 day



WOCKHARDT HOSPITALS, NAGPUR

1643, North Ambazari Road, Nagpur - 440 033. Tel : (0712) 6624444, 6624100

Fax : (0712) 2261266 Website : www.wockhardthospitals.com

Registered Office Address : Wockhardt Towers, BKC, Bandra (East) Mumbai 40005

CIN: U85100MH1991PLC063096

Blood Pressure : mm of Hg

Height : cm

Weight : Kg

Body Mass Index :

EMERGENCY

ACCIDENT & TRAUMA LINE



Medicine Delivery at Your Doorstep Call.:
07720965555

Sample Collection No.:

Home Physiotherapy No.:

DEPARTMENT OF RADIOLOGY

| | | |
|----------------------------------|------------------------|---------------------------|
| UHID : WHN2.0000320196 | Age/Sex : 31 Year(s)/F | Order Date : 26-Mar-2022 |
| Name : Mrs SARITA NAZARETH | | Order No. : OPD455585 |
| Ref. Doctor : WOCKHARDT HOSPITAL | | Report Date : 26-Mar-2022 |

BOB ANNUAL HCUFOR FEMALE 2020
USG ABDOMEN WITH PELVIS

Liver is normal in size shape and echogenicity. No e/o any obvious focal lesion. IHBR not dilated. CBD & PV are normal in caliber.

Gall bladder is well distended and appear clear with normal wall thickness. No e/o sludge or calculus.

Spleen is normal in size shape and echogenicity.

Pancreas is normal in size shape and echogenicity.

Right Kidney: 11.1 cm

Left Kidney: 10 cm

Both kidneys normal in size shape and echogenicity. CMD well maintained.

No e/o hydronephrosis or calculus. Ureters are not dilated.

Bowel loops are normally peristaltic. No e/o any wall thickening or mass lesion.

Both iliac fossae are unremarkable. No e/o any probe tenderness in RIF at present.

Urinary bladder is well distended and appear clear with normal wall thickness.

Uterus is anteverted and shows normal shape and echogenicity. No e/o any focal lesion or fibroid.


Endometrium shows normal thickness and appear clear.

Both ovaries appear normal in size & shape and show few follicles of varying sizes.

No e/o any lymphadenopathy. No free fluid in POD.

IMPRESSION:

NORMAL ABDOMINAL STUDY.



Dr. NAYEEM AHMAD KHAN

DMRE
Consultant Radiologist



WOCKHARDT HOSPITALS, NAGPUR

1643, North Ambazari Road, Nagpur - 440 033. Tel : (0712) 6624444, 6624100

Fax : (0712) 2261266 Website : www.wockhardthospitals.com

Registered Office Address :- Wockhardt Towers , BKC , Bandra (East) Mumbai 400051

CIN: U85100MH1991PLC063096

DEPARTMENT OF RADIOLOGY

UHID : WHN2.0000320196 Age/Sex : 31 Year(s)/F

Name : Mrs SARITA NAZARETH

Ref. Doctor : WOCKHARDT HOSPITAL

Order Date : 26-Mar-2022

Order No. : OPD455585

Report Date : 26-Mar-2022

BOB ANNUAL HCUFOR FEMALE 2020

XR CHEST PA

RADIOLOGICAL OBSERVATION & IMPRESSION :

BILATERAL LUNG FIELDS APPEAR NORMAL.


BOTH CP ANGLES ARE CLEAR.

BILATERAL HILAE & CARDIAC SILLHOUTTE APPEAR NORMAL.

BONY CAGE APPEAR NORMAL.

SOFT TISSUES IN VIEW ARE GROSSLY NORMAL.

IMPRESSION: NORMAL STUDY.


DR. NAYEEM AHMAD KHAN

DMRE
Consultant Radiologist



WOCKHARDT HOSPITALS, NAGPUR

1643, North Ambazari Road, Nagpur - 440 033. Tel : (0712) 6624444, 6624100

Fax : (0712) 2261266 Website : www.wockhardthospitals.com

Registered Office Address :- Wockhardt Towers, BKC, Bandra (East) Mumbai 400051

CIN: U85100MH1991PLC063096

DEPARTMENT OF PATHOLOGY TEST REPORT

| | | | | |
|-------------|-----------------------|----------------------------|-------------|---------------|
| UHID | : WHN2.0000320196 | Age/Sex: 30(Y)11(M)22(D)/F | Order Date | : 26-Mar-2022 |
| Name | : Mrs SARITA NAZARETH | | Order No. | : OPD455585 |
| Ref. Doctor | : WOCKHARDT HOSPITAL | | | |
| Con.Doctor | : WOCKHARDT | | Report Date | : 26-Mar-2022 |

BOB ANNUAL HCUFOR FEMALE 2020

| <u>Parameter</u> | <u>Result</u> | <u>Unit</u> | <u>Reference Range</u> |
|--|---------------|-------------|------------------------|
| COMPLETE BLOOD COUNT (WITH ESR) | | | |
| Haemoglobin, Cell counter | 14.6 | g% | 12-16 |
| Haematocrit, Calculated | 44.1 | % | 37-47 |
| MCV, Calculated | 87.6 | fl | 76-96 |
| MCH, Calculated | 29.0 | pg | 27-32 |
| MCHC, Calculated | 33.1 | % | 30-35 |
| RDW-CV, Calculated | 12.4 | % | 12-15 |
| RBC Count, Cell counter | 5.04 * | Million/ul | 4-5 |
| TLC Count, Cell counter | 10900 | Cells/cumm | 4000-11000 |
| Differential Count | | | |
| Neutrophil, Cell Counter/Manual | 80 * | % | 40-70 |
| Lymphocyte, Cell Counter/Manual | 13 * | % | 20-40 |
| Monocyte, Cell Counter/Manual | 05 | % | 2-8 |
| Eosinophil, Cell Counter/Manual | 02 | % | 2-6 |
| Basophil, Cell Counter/Manual | 00 | % | 0-2 |
| Platelet Count, Cell counter | 272 | Thou/Cumm | 150-450 |
| Blood ESR, Westergren's Method | 35 * | mm/hr | 0-20 |

CBC done on 5-part Coulter UniCel DxH 800 haematology analyzer.

ESR done on ALIFAX Roller 20LC ESR analyzer.

* Indicates test value is outside reference range defined. All such values are rechecked.



Dr. ALKA THOOL, MD-PATH
SENIOR PATHOLOGIST

13482 SONAL SINGH
Performed by



WOCKHARDT HOSPITALS, NAGPUR

1643, North Ambazari Road, Nagpur - 440 033, Tel : (0712) 6624444, 6624100

Fax : (0712) 2261266 Website : www.wockhardthospitals.com

Registered Office Address :- Wockhardt Towers, BKC, Bandra (East) Mumbai 400051

CIN: U85100MH1991PLC063096

DEPARTMENT OF PATHOLOGY TEST REPORT

| | | | | |
|-------------|-----------------------|----------------------------|-------------|---------------|
| UHID | : WHN2.0000320196 | Age/Sex: 30(Y)11(M)22(D)/F | Order Date | : 26-Mar-2022 |
| Name | : Mrs SARITA NAZARETH | | Order No. | : OPD455585 |
| Ref. Doctor | : WOCKHARDT HOSPITAL | | | |
| Con. Doctor | : WOCKHARDT | | Report Date | : 26-Mar-2022 |

BOB ANNUAL HCUFOR FEMALE 2020

| <u>Parameter</u> | <u>Result</u> | <u>Unit</u> | <u>Reference Range</u> |
|-------------------------------------|---------------|-------------|--|
| Glycosylated Hemoglobin HbA1C, HPLC | 4.7 | % | Action required: 7.0-8.0% Good control: 6.5-7.0% Normal control: 4.8-6.4% Poor control: >8.0% |
| Estimated Mean glucose | 90.02 | mg/dl | |

Aberrant glycosylated haemoglobin values may be seen in patients with haemoglobinopathies, recent blood transfusion and severe anemias. In such cases, alternative methods of determination of blood glucose is recommended.

Dr. ALKA THOOL, MD-PATH
SENIOR PATHOLOGIST13482 SONAL SINGH
Performed by**WOCKHARDT HOSPITALS, NAGPUR**

1643, North Ambazari Road, Nagpur - 440 033. Tel : (0712) 6624444, 6624100

Fax : (0712) 2261266 Website : www.wockhardthospitals.com

Registered Office Address :- Wockhardt Towers, BKC, Bandra (East) Mumbai 400051

CIN: U85100MH1991PLC063096

DEPARTMENT OF PATHOLOGY TEST REPORT

| | | | | | |
|-------------|-----------------------|-------------|---------------------|------------|---------------|
| UHID | : WHN2.0000320196 | Age/Sex | : 30(Y)11(M)22(D)/F | Order Date | : 26-Mar-2022 |
| Name | : Mrs SARITA NAZARETH | Order No. | : OPD455585 | | |
| Ref. Doctor | : WOCKHARDT HOSPITAL | | | | |
| Con. Doctor | : WOCKHARDT | Report Date | : 26-Mar-2022 | | |

BOB ANNUAL HCUFOR FEMALE 2020

| <u>Parameter</u> | <u>Result</u> | <u>Unit</u> | <u>Reference Range</u> |
|---------------------------------------|---------------|-------------|---|
| Fasting Blood Sugar, Hexokinase | 94 | mg/dl | 70-115 |
| Urine Sugar (fasting) | Not Detected | | |
| Post Prandial Blood Sugar, Hexokinase | 92 * | mg/dl | 100-140 |
| Urine Sugar (post Prandial) | NA | | |
| <u>LIPID PROFILE</u> | | | |
| Serum Cholesterol, CHOD-PAP | 194 | mg/dl | 1) Desirable Cholesterol Level: <201 2) Borderline Cholesterol: 200-240 3) High Cholesterol: >240 |
| Serum Triglycerides, GPO-PAP | 142 | mg/dl | 70-200 |
| Serum HDL-Cholesterol, Direct Method | 53 | mg/dl | 45-65 |
| Serum VLDL Cholesterol, Calculated | 28.40 | mg/dl | 10-35 |
| Serum LDL Cholesterol, Calculated | 112.60 | mg/dl | 80-130 |
| Serum CHOL/HDL RATIO, Calculated | 3.66 | | 1) Low Risk 3.3-4.4 2) Average Risk 4.4-7.1 3) Moderate Risk 7.1-11.0 4) High Risk >11.0 |

* Indicates test value is outside reference range defined. All such values are rechecked.



Dr. ALKA THOOL, MD-PATH
SENIOR PATHOLOGIST

Performed by



WOCKHARDT HOSPITALS, NAGPUR

1643, North Ambazari Road, Nagpur - 440 033; Tel : (0712) 6624444, 6624100

Fax : (0712) 2261266 Website : www.wockhardthospitals.com

Registered Office Address :- Wockhardt Towers, BKC, Bandra (East) Mumbai 400051

CIN: U85100MH1991PLC063096


DEPARTMENT OF PATHOLOGY TEST REPORT

| | | | | |
|-------------|-----------------------|----------------------------|-------------|---------------|
| UHID | : WHN2.0000320196 | Age/Sex: 30(Y)11(M)22(D)/F | Order Date | : 26-Mar-2022 |
| Name | : Mrs SARITA NAZARETH | | Order No. | : OPD455585 |
| Ref. Doctor | : WOCKHARDT HOSPITAL | | | |
| Con. Doctor | : WOCKHARDT | | Report Date | : 26-Mar-2022 |

BOB ANNUAL HCUFOR FEMALE 2020

| <u>Parameter</u> | <u>Result</u> | <u>Unit</u> | <u>Reference Range</u> |
|---|---------------|-------------|------------------------|
| Blood Urea Nitrogen, Calculated | 9.81 | mg/dl | 6-20 |
| Serum Uric Acid, Enzymatic | 3.54 | mg/dl | 1-5.7 |
| Serum Creatinine, Jaffe's Kinetic | 0.75 | mg/dl | 0.5-0.9 |
| <u>LIVER PROFILE</u> | | | |
| Serum Alkaline Phosphatase, PNP AMP Kinetic | 102 | U/L | 35-104 |
| Serum SGOT, UV Kinetic (AST) | 24 | U/L | 1-32 |
| Serum SGPT, UV Kinetic (ALT) | 19 | U/L | 1-31 |
| Serum Total Protein, Biuret | 8.02 | g/dl | 6.6-8.7 |
| Serum Albumin, BCG | 5.08 * | g/dl | 3.4-4.8 |
| Serum Globulin, Calculated | 2.94 | g/dl | 2-4 |
| Serum Albumin:Globulin Ratio, Calculated | 1.73 | | 1-2 |
| Serum Total Bilirubin, Diazo | 0.62 | mg/dl | 0-1.2 |
| Serum Direct Bilirubin, Diazo | 0.23 | mg/dl | 0-0.3 |
| Serum Indirect Bilirubin, Calculated | 0.39 | mg/dl | 0-0.8 |

* Indicates test value is outside reference range defined. All such values are rechecked.



Dr. LAXMI LOKESH, MD-PATH
PATHOLOGIST

Performed by



WOCKHARDT HOSPITALS, NAGPUR

1643, North Ambazari Road, Nagpur - 440 033, Tel : (0712) 6624444, 6624100

Fax : (0712) 2261266 Website : www.wockhardthospitals.com

Registered Office Address : Wockhardt Towers, BKC, Bandra (East) Mumbai 400051

CIN. U85100MH1991PLC063096

DEPARTMENT OF PATHOLOGY TEST REPORT

| | | | | |
|-------------|-----------------------|----------------------------|-------------|---------------|
| UHID | : WHN2.0000320196 | Age/Sex: 30(Y)11(M)22(D)/F | Order Date | : 26-Mar-2022 |
| Name | : Mrs SARITA NAZARETH | | Order No. | : OPD455585 |
| Ref. Doctor | : WOCKHARDT HOSPITAL | | | |
| Con.Doctor | : WOCKHARDT | | Report Date | : 26-Mar-2022 |

BOB ANNUAL HCUFOR FEMALE 2020

| <u>Parameter</u> | <u>Result</u> | <u>Unit</u> | <u>Reference Range</u> |
|-----------------------|---------------|-------------|------------------------|
| Serum Total T3, ECLIA | 75.36 * | ng/dL | 84.6-201.8 |
| Serum Total T4, ECLIA | 6.39 | µg/dl | 5.13-14.06 |
| Serum TSH, ECLIA | 4.28 * | µIU/mL | 0.2-4.2 |

* Indicates test value is outside reference range defined. All such values are rechecked.



Dr. ALKA THOOL, MD-PATH
SENIOR PATHOLOGIST

Performed by



WOCKHARDT HOSPITALS, NAGPUR

1643, North Ambazari Road, Nagpur - 440 033 Tel : (0712) 6624444, 6624100

Fax : (0712) 2261266 Website : www.wockhardthospitals.com

Registered Office Address : Wockhardt Towers , BKC , Bandra (East) Mumbai 400051

CIN: U85100MH1991PLC063096

DEPARTMENT OF PATHOLOGY TEST REPORT

| | | | | |
|-------------|-----------------------|-----------------------------|-------------|---------------|
| UHID | : WHN2.0000320196 | Age/Sex : 30(Y)11(M)22(D)/F | Order Date | : 26-Mar-2022 |
| Name | : Mrs SARITA NAZARETH | | Order No. | : OPD455585 |
| Ref. Doctor | : WOCKHARDT HOSPITAL | | | |
| Con. Doctor | : WOCKHARDT | | Report Date | : 26-Mar-2022 |

BOB ANNUAL HCUFOR FEMALE 2020

| <u>Parameter</u> | <u>Result</u> | <u>Unit</u> |
|--|---------------|-------------|
| <u>URINE ROUTINE</u> | | |
| <u>Physical Examination</u> | | |
| Colour | Pale Yellow | |
| Appearance | Clear | |
| <u>Urinalysis(Roche UriSys1100)</u> | | |
| Specific Gravity | 1.015 | |
| PH | 6 | |
| Leukocytes, by urinalyser, calculated | 0.00 | /hpf |
| Nitrite, urinalyser | Negative | |
| Protein, urinalyser | Negative | |
| Glucose, urinalyser | Normal | |
| Ketone, urinalyser | Negative | |
| Urobilinogen, urinalyser | Normal | |
| Bilirubin, urinalyser | Negative | |
| Erythrocytes, by urinalyser,calculated | 0.00 | /hpf |


Dr. ALKA THOOL , MD-PATH
SENIOR PATHOLOGIST


2D ECHOCARDIOGRAPHY & COLOUR DOPPLER STUDY

Name : Mrs. Sarita Nazareth

Age / Sex: 30 Yrs. / Female

Done By : Dr. Prajakta Deshmukh

Date : March 26, 2022

UHID No. : 320196

OPD

Comments :

Sector echo done in plax, psax, apical 4 & 5 chambers, subcostal view shows:

Normal morphology of mitral, aortic, tricuspid and pulmonary valves.

The left atrium, left ventricle, right atrium and right ventricle are normal in dimension and morphology. There is no regional wall motion abnormality of left ventricle at rest. The left ventricular systolic function is **good**. The global left ventricular ejection fraction is 61 %.

The IAS and IVS are intact.

The pericardium is normal. There is no pericardial effusion.

Aortic root / visualized segment of ascending aorta normal.

Pulmonary arteries normal.

There is no clot or vegetation seen.

CW, PW and Colour Doppler: Transmitral flow is suggestive of normal left ventricular diastolic function. There is no evidence of pulmonary hypertension.

Impression:


Normal cardiac valves and chambers

No regional wall motion abnormality of left ventricle at rest

Good left ventricular systolic function. LVEF – 61 %

Normal LV diastolic function

Good RV systolic function



Dr. Prajakta Deshmukh

MD (Med.), MASE

Sr. Consultant – Non Invasive Cardiologist



WOCKHARDT HOSPITALS, NAGPUR

1643, North Ambazari Road, Nagpur - 440 033. Tel : (0712) 6624444, 6624100

Fax : (0712) 2261266 Website : www.wockhardthospitals.com

Registered Office Address :- Wockhardt Towers, BKC, Bandra (East) Mumbai 400051

CIN: U85100MH1991PLC063096

Name : *Savitri Nazareth* Age/ Sex : yrs /

Date: *28/8/22*

Fundus Examination
(Direct Ophthalmoscopy)

Right

Left

Media

Optic Disc

Colour
Size
Shape
Margin
NRR
C:D

star Refs

Blood Vessels

A:V ratio
Abnormalities

Macula

FR
Abnormalities

Periphery

Impression

Dr. NITIN DHOK
9096377550
Consultant Ophthalmology



WOCKHARDT HOSPITALS, NAGPUR

1643, North Ambazari Road, Nagpur - 440 033. Tel : (0712) 6624444, 6624100

Fax : (0712) 2261266 Website : www.wockhardt.hospitals.com

Registered Office Address :- Wockhardt Towers, BKC, Bandra (East) Mumbai 400051

CIN: U85100MH1991PLC063096

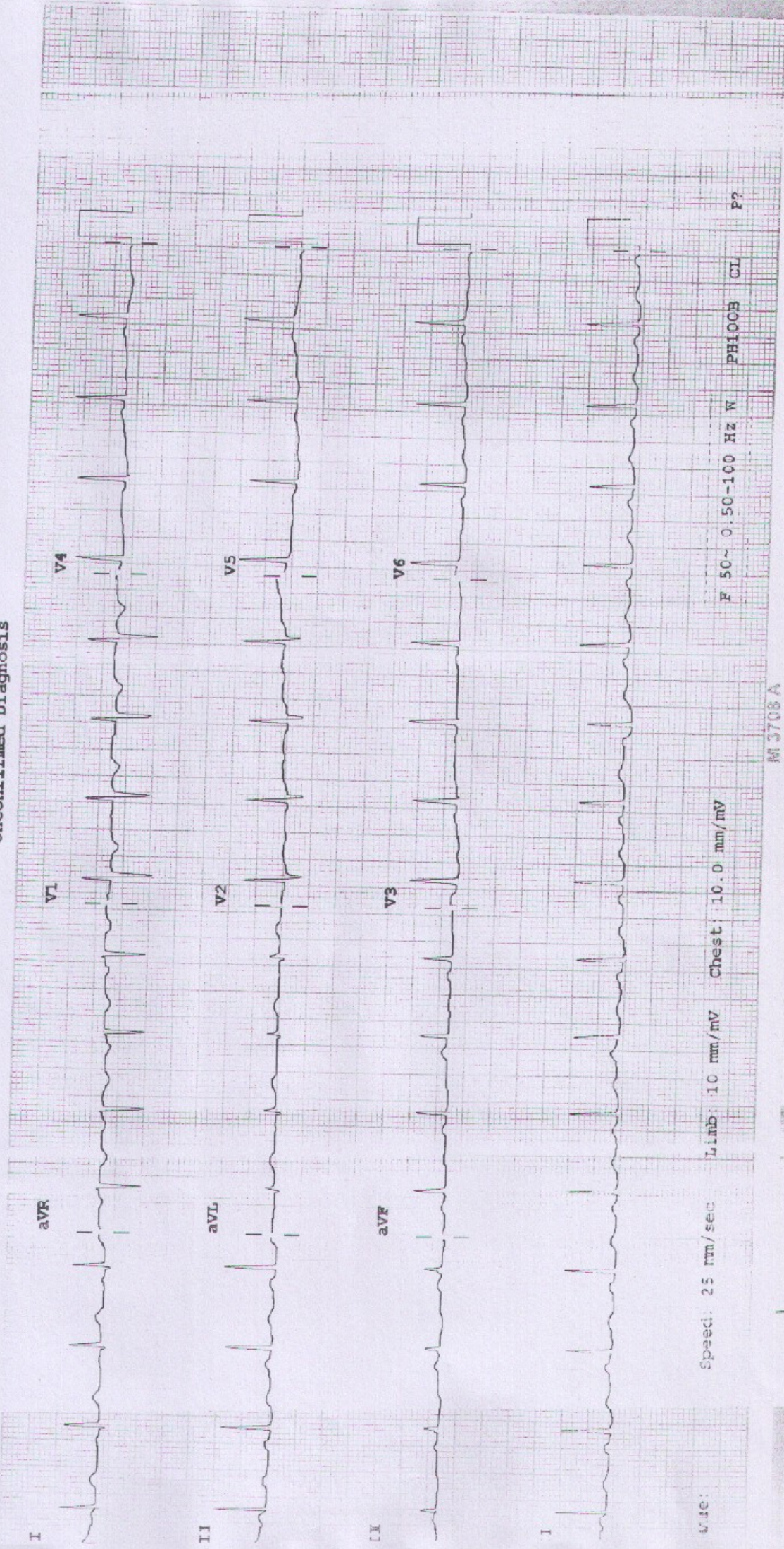
Rte 100 : Age not entered, assumed to be 50 years old for purpose of ECG interpretation
 PE 144 : Sinus tachycardia
 QED 62 : Abnormal R-wave progression, early transition
 QT 324 : Borderline T abnormalities, diffuse leads
 QT 418 : Baseline wander in lead(s) V2

--MS--
 P 61
 QE 49
 T -1

11 Lead; Standard Placement

- BORDERLINE ECG -

Unconfirmed Diagnosis



Speed: 25 mm/sec
 Limb: 10 mm/mV
 Chest: 10.0 mm/mV

F 50-0.50-100 Hz W PH100B CL P2

M 3708 A