

Mrs. Akshata S. Gramapurohit

Age 1341 F



AR $\leftarrow \begin{matrix} -0.75 / 2.50 \times 180 \\ -0.75 \end{matrix}$

Vision $\leftarrow \begin{matrix} 6/9 \\ 6/9 \end{matrix}$

Eqn
Vision $\leftarrow \begin{matrix} N16 \\ N16 \end{matrix}$

Eqn
Vision $\leftarrow \begin{matrix} 6/6 \\ 6/6 \end{matrix}$

Ref $\leftarrow \begin{matrix} -0.75 / 2.25 \times 180 \text{ 6/6} \\ -0.75 \text{ DDPH} \quad 6/6 \end{matrix}$

COV
Vision $\leftarrow \underline{38/38}$

Dr. [Signature]
M.D. [Signature]
Consultant of Ophthalmology & Cornea Specialist
Reg. No. 1401-10154

Apollo Sage Hospital - Bhopal

Regd No. NH/7272/Sept. 2022

(A unit of S. R. Associates)

KH No. 98/3-99-100, E-8 Arera Colony, Bhopal - 462026 (MP) India

+91 -755- 4308101

Emergency +91 -755- 3505050

info@apollosage.in

www.apollosage.in



Scan here to know us better

ApolloSageHospitals

apollosagehospital

apollo-sage-hospital

Mrs. Akashata. Grampusht 34yrs , 25.11.23

Came for health check up.

No complaints

LMP - 11.11.23.

P₂L₂
LO 2020-

Wt. 90.4 kg

P - 96/m

BP - 113/82

Afebrile

P/A soft

P/S 

Minimal circumferential erosion ⊕

Bleed on touch

ph uterus normal size, B/L fornices free.

ly.

- Zocon AS. Kit. / FAS-3 kit

- F heal vaginal pessary
1HS V x 6d.

- R/v. c PAP smear report



Dr. Swabli Dube
(MD, DNB, PNB)
MP-12415




34 Years

Female

QRS : 74 ms
 QT / QTcBaz : 392 / 452 ms
 PR : 138 ms
 P : 92 ms
 RR / PP : 752 / 750 ms
 P / QRS / T : 49 / 48 / 51 degrees

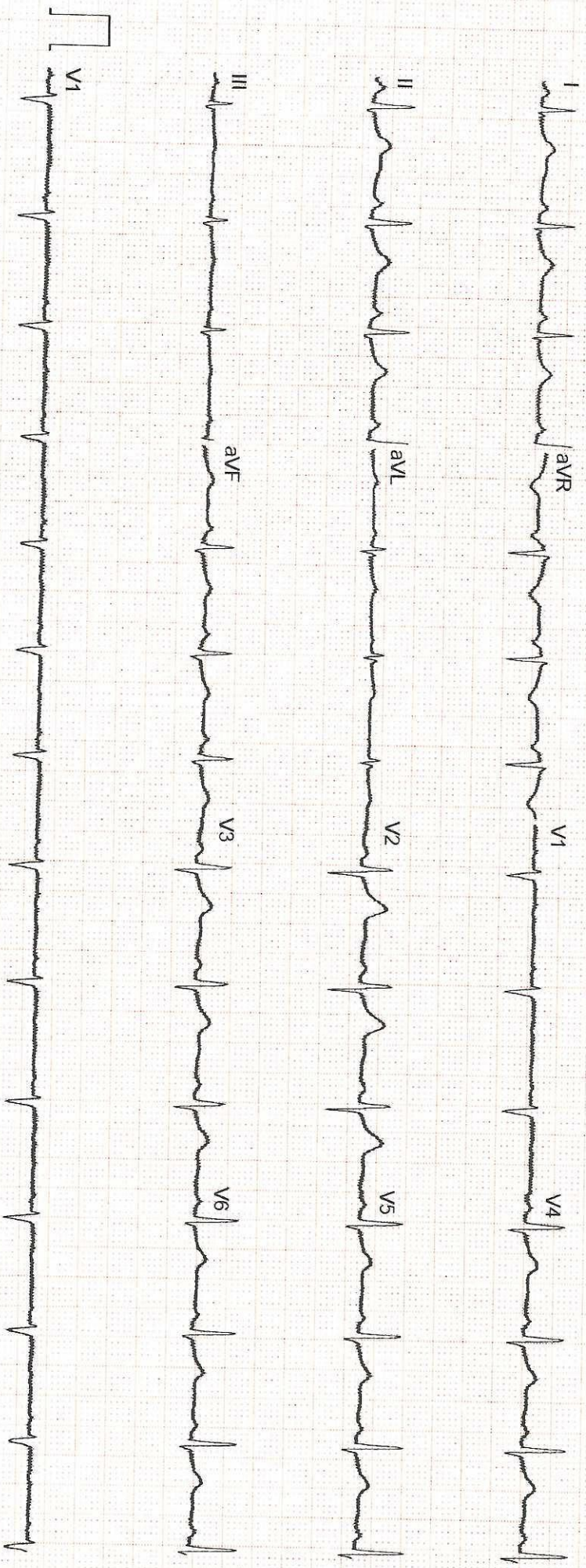
Normal sinus rhythm
 Normal ECG



Location: _____
 Room: _____
 Order Number: _____
 Indication: _____
 Medication 1: _____
 Medication 2: _____
 Medication 3: _____

Technician:
 Ordering Ph: _____
 Referring Ph: _____
 Attending Ph: _____

80 bpm
 -- / -- mmHg



GE MAC2000 1.1 12SL™ V241

25 mm/s 10 mm/mV

ADS 0.56-150 Hz 50 Hz 4x2.5x3_25_R1

Unconfirmed

APOLLO SAGE HOSPITALS
BAWADIYA KALAN, BHOPAL

Name **AKSHATA S. GRAMPUROHIT,**

Gender **Female**

Patient Id **ASHB.0000022955**

Age **34 years**

Date **25/11/2023**

2D

<u>M-Mode</u>		<u>Doppler</u>	
IVSd	1.0 cm	MV E Vel	0.64 m/s
LVIDd	3.6 cm	MV DecT	129 ms
LVPWd	1.0 cm	MV Dec Slope	4.9 m/s ²
IVSs	1.4 cm	MV A Vel	0.56 m/s
LVIDs	2.1 cm	MV E/A Ratio	1.14
LVPWs	1.2 cm	AV Vmax	1.67 m/s
EDV(Teich)	56 ml	AV Vmean	1.17 m/s
ESV(Teich)	14 ml	AV maxPG	11.22 mmHg
EF(Teich)	75 %	AV meanPG	6.22 mmHg
%FS	43 %	AV Env.Ti	266 ms
SV(Teich)	42 ml	AV VTi	31.2 cm
RWT	0.57	HR	100 BPM
Ao Diam	2.2 cm	PV Vmax	1.29 m/s
LA Diam	3.3 cm	PV Vmean	0.91 m/s
LA/Ao	1.50	PV maxPG	6.80 mmHg
		PV meanPG	3.66 mmHg
		TR Vmax	1.93 m/s
		TR maxPG	14.83 mmHg

ECHO SUMMARY

- Left Ventricle: Normal Left Ventricular Size, Wall Thickness & Functions
- Left Ventricular Ejection Fraction is Within Normal Limits (LVEF = 60 %)
- Left Atrium: Normal Left Atrial Size & Functions
- Right Ventricle: Normal Right Ventricular Size & Functions
- Right Atrium: Normal Right Atrial Size & Function.
- Valvular Structures: Normal Mitral, Tricuspid, Pulmonic & Aortic Valve Structures
- Aortic Root is Normal
- No Evidence of Pericardial Effusion

Dr. Gaurav Khandelwal
DM (Cardiology), FACC, FESC, FSCAI, FIC
Interventional Cardiologist

Dr. Anurag Jain
MD, DNB, DM (Cardiology)
Interventional Cardiologist

Dr. Akhil Kumar Tiwari
MD, FRCP (UK)
Senior Consultant, Internal Medicine
Clinical Cardiology

Dr. Manish Kedia
MBBS, PGDCC
Specialist Non Invasive
& Clinical Cardiology

APOLLO SAGE HOSPITALS

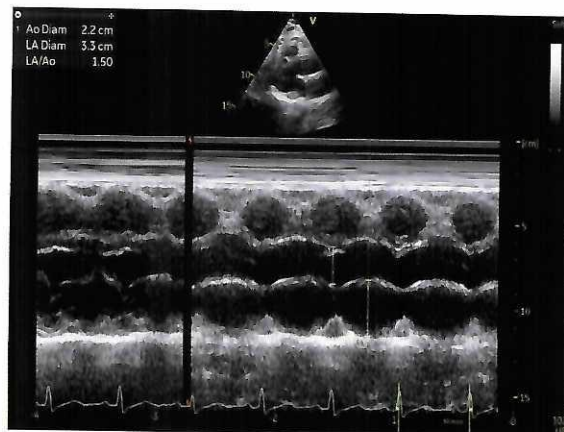
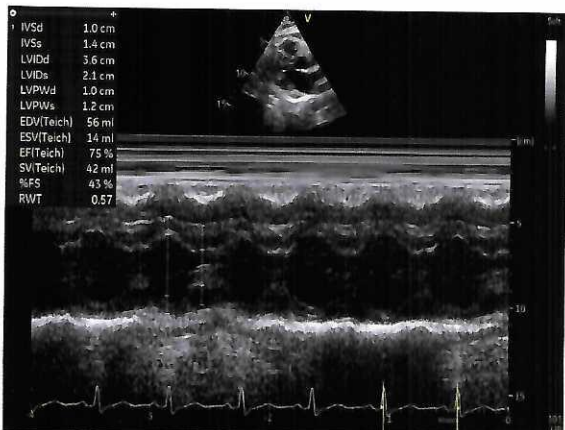
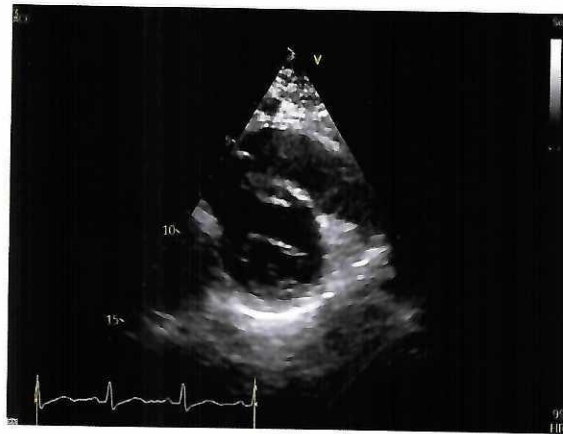
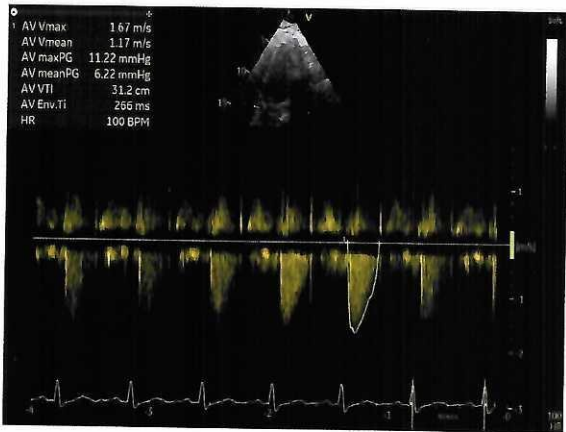
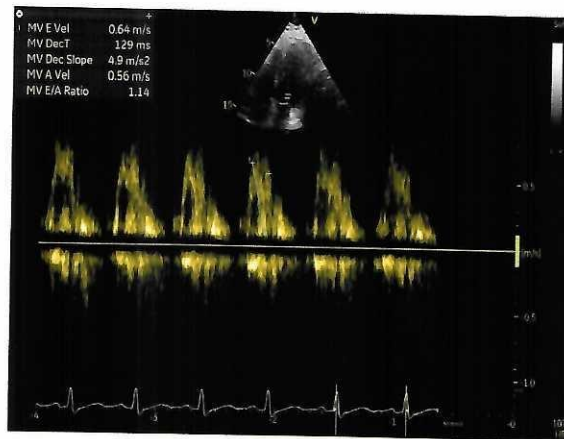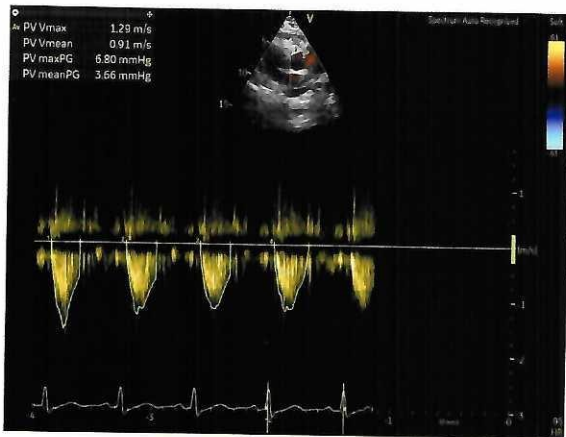
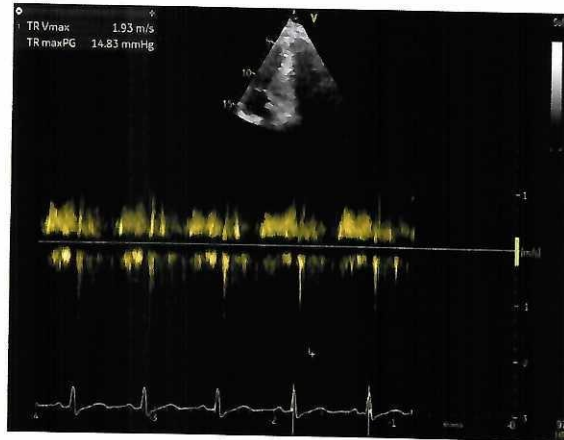
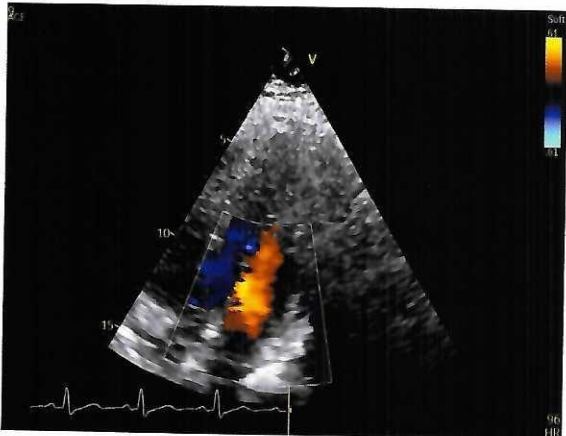
BAWADIYA KALAN , BHOPAL

Name **AKSHATA S. GRAMPUROHIT,**

Gender **Female**

Patient Id **ASHB.0000022955**

Date **25/11/2023**



ULTRA SONOGRAPHY ABDOMEN

NAME	Mrs. Akshata S. Grampurohit	UHID NUMBER:-	ASHIB.0000022955	
REF. BY	Dr. Akhil Kumar Tiwari	DATE	25.Nov.2023	AGE/SEX:- 34y/F

Liver:- is normal in size and shows mild increase in echotexture. Portal and hepatic venous system appears normal. Intra and extra hepatic biliary radicals are not dilated.

Gall Bladder:- is normal in size and shape. Its lumen is echofree.

Pancreas is normal in size outline and echopattern.

Spleen is normal in size and echopattern.

Both kidneys are normal in size, shape and echogenicity. Central pelvicalyceal sinus and corticomedullary ratio are normal.

Right kidney measures:- 9.8x4.5cm

Left kidney measures:- 10.8x4.7cm

No evidence of ascites is seen.

Urinary bladder is normal in shape and contour. Its wall is normal.

Uterus and ovaries:- Uterus is anteverted and shows inhomogeneous echopattern.

Cervix shows normal echopattern. No adnexal mass. No free fluid in POD.

Uterus measures:- 8.5x6.2x4.8cm. Endometrial thickness is 4.0mm.

Right ovary measures 3.4x2.1x2.1cm, volume- 8.3cc.

Left ovary measures 2.3x1.3x1.8cm, volume- 7.0cc.

IMPRESSION:- Sonography Study Reveals:-

- Grade- I fatty liver.

ADV:- Clinical Correlation.

for
Dr. Manish Kumar Verma, MD
Sr. Consultant Radiologist

Apollo Sage Hospital - Bhopal

Regd No. NH/7272/Sept. 2022

(A unit of S. R. Associates)

KH No. 98/3-99-100, E-8 Arera Colony, Bhopal - 462026 (MP) India

+91 -755- 4308101

Emergency +91 -755- 3505050

info@apollosage.in


www.apollosage.in

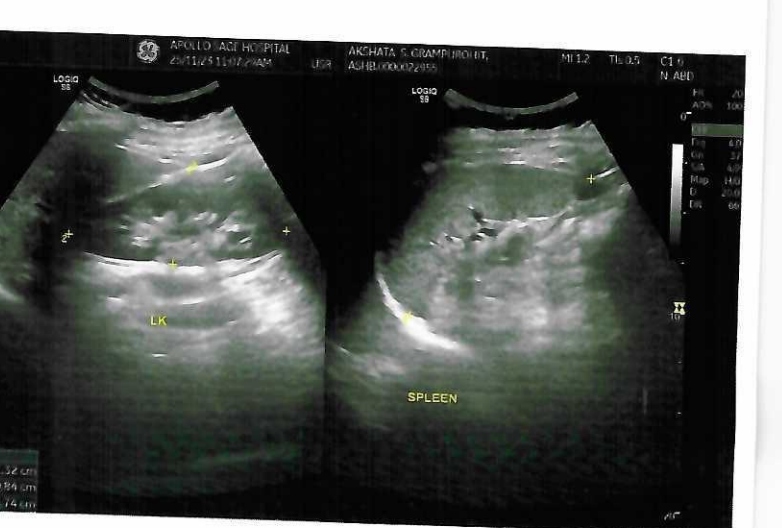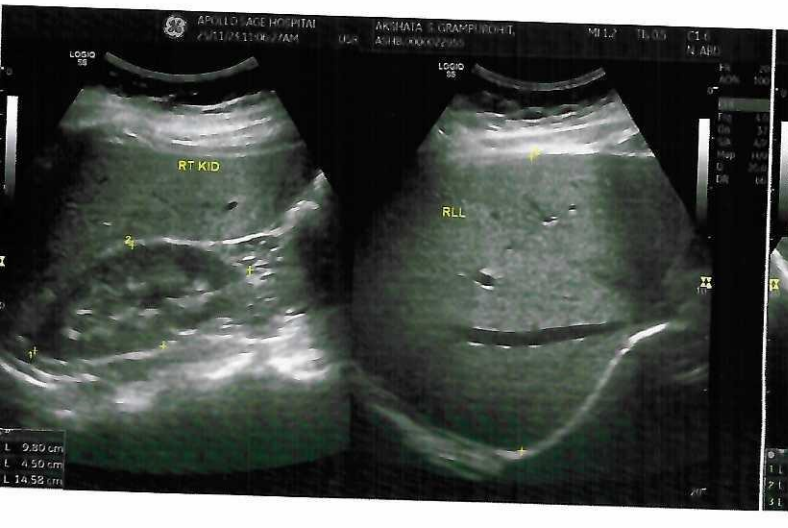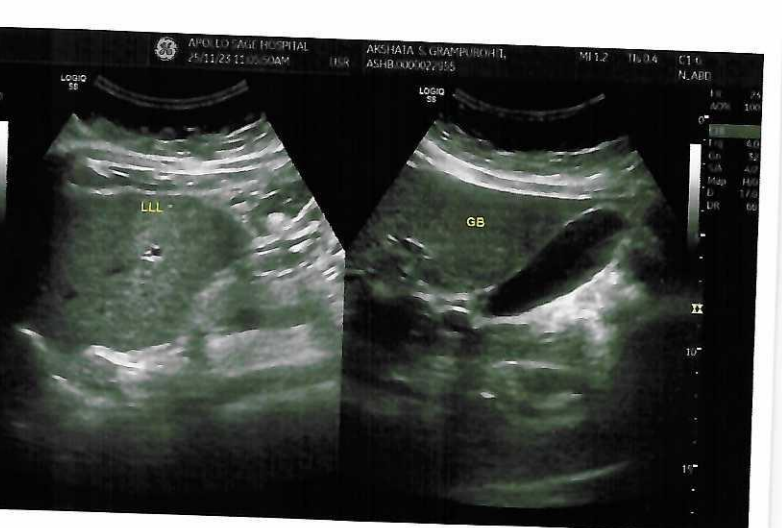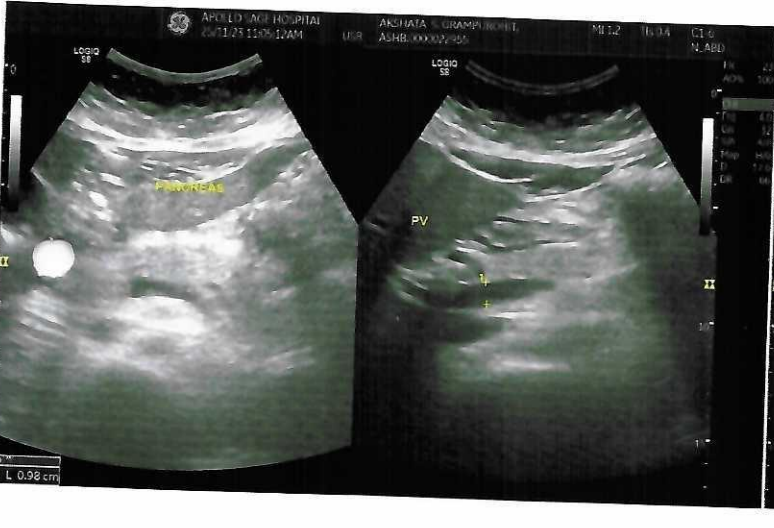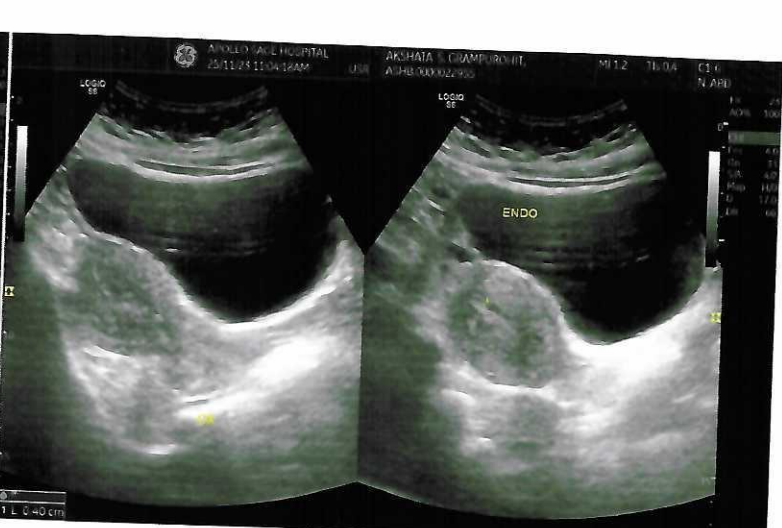
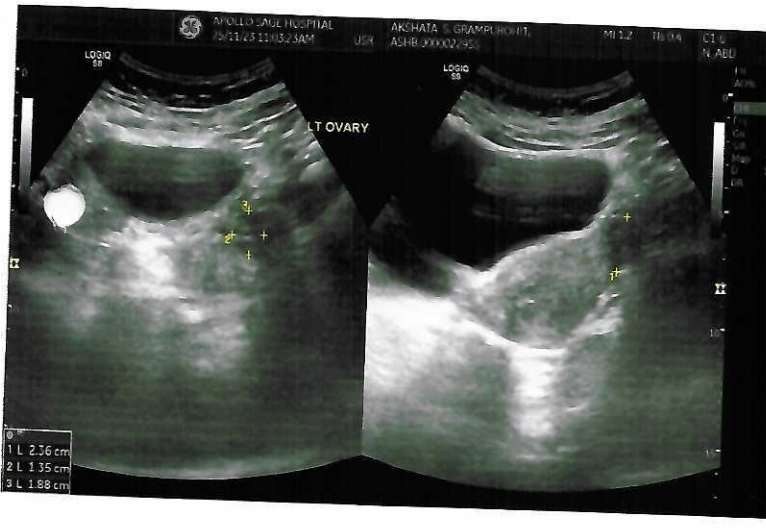
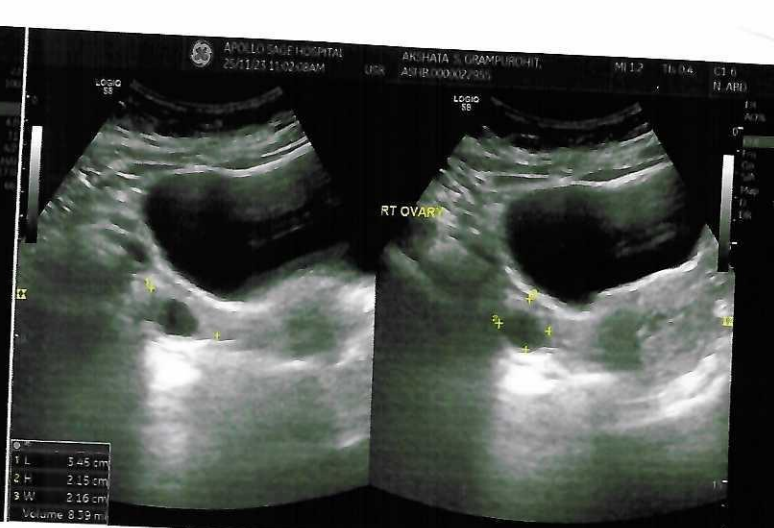
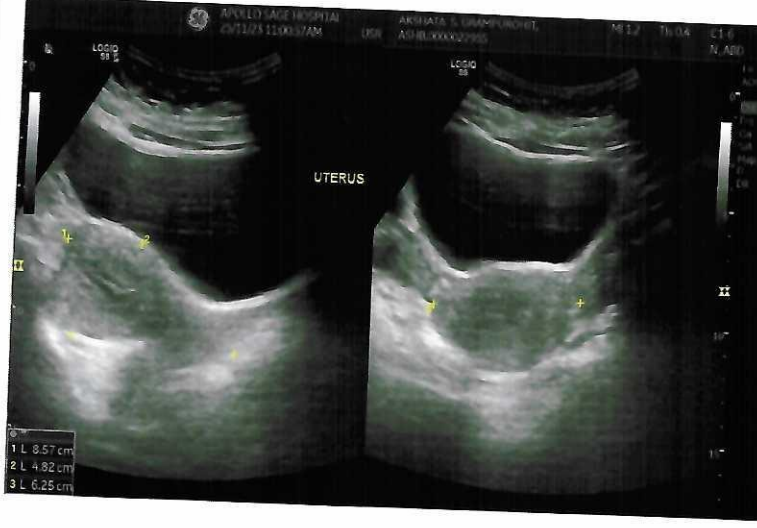


Scan here to know us better

 ApolloSageHospitals

 apollosagehospital

 apollo-sage-hospital



Patient Name:	AKSHATA S. GRAMPUROHIT	Patient ID:	ASHB.0000022955
Age:	34 Years	Sex:	F
Accession Number:	17101.123012603	Modality:	DX
Referring Physician:	Akhil Kumar Tiwari	Study:	CHEST
Study Date:	25-Nov-2023		

X-RAY CHEST (PA VIEW)

Both lung fields are clear. No active pleural or parenchymal lesion is seen.

The hila, mediastinum, bony thoracic cage and the diaphragmatic domes are normal.

The costophrenic and cardiophrenic angles are clear.

The cardiac silhouette is unremarkable.

IMP:- RADIOGRAPHIC IMAGE REVEALS:-

Normal findings are seen.

Thanks for Ref



DR. HARI SANTOSH
CONSULTANT RADIOLOGIST

Date: 25-Nov-2023 10:49:53



22955



Out Patient Assessment Form

Apollo Hospital, Bhopal

Place Patient Label Here

Mrs. AKSHATA
If label not available, write Pt. Name UHID No. IP
No Age, Sex, Date, Name of Treating Physician

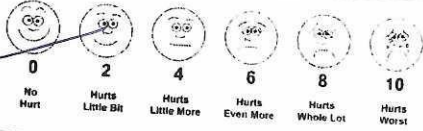
Date : 25/11/23

Time : 8:57 AM

Consultant Name : HC

Pain Assessment

Nursing Assessment



Height 165cm

Weight 90.4kg

Pulse : 96/M BP : 113/82

Allergies (if any)

NO

Falls risk : Yes No

Oral hygiene :

Poor

Fair

Good

Investigation Ordered

SpO₂ - 99%

BMI - 33.2

Chief complains past medical / surgical history. Diagnosis, Treatment Plan, Current Medications & Follow - up advice :

Patient Education (Patient Is Briefed on Following) Cost May Vary In Course Of Disease

Proposed Care Plan Yes No

Expected Outcome : Yes No

Expected Cost : Yes No

Admission Advice : Yes No

Consultant Signature

Date :

Time

Name : Mrs. AKSHATA S. GRAMPUROHIT **OP Number:** BPLAH4753 **Bill No:** BPL-OCR-2307

Package Information

S.No	Service Type\Service Name	Department
1	MEDIWHEEL FULL BODY HEALTH ANNUAL PLUS CHECK FEMALE	
1	ALBUMIN - SERUM	BioChemistry
2	ALBUMIN/GLOBULIN RATIO	BioChemistry
3	ALKALINE PHOSPHATASE - SERUM/PLASMA	BioChemistry
4	ALT(SGPT) - SERUM / PLASMA	BioChemistry
5	AST (SGOT) - SERUM	BioChemistry
6	BILIRUBIN CONJUGATED (DIRECT) - SERUM	BioChemistry
7	BILIRUBIN UNCONJUGATED (INDIRECT) - SERUM	BioChemistry
8	BILIRUBIN, TOTAL - SERUM	BioChemistry
9	BLOOD GROUPING AND TYPING (ABO and Rh)	Blood Bank - 2 Services
10	BUN (BLOOD UREA NITROGEN)	BioChemistry
11	CBC	Haematology
12	CHOLESTEROL - SERUM / PLASMA	BioChemistry
13	COMPLETE BLOOD COUNT(CBC) WITH ESR	Haematology
14	CONSULTATION - DENTAL	Dental
15	CONSULTATION - DIET	Dietetics
16	CONSULTATION - ENT	Ear Nose and Throat
17	CONSULTATION - GYNAEOCOLOGICAL	OB and Gynaec Ultrasound
18	CONSULTATION - INTERNAL MEDICINE	General Medicine
19	CONSULTATION - OPHTHALMOLOGY	Ophthalmology
20	CREATININE - SERUM / PLASMA	BioChemistry
21	ECG	CARDIOLOGY
22	ERYTHROCYTE SEDIMENTATION RATE (ESR)	Haematology
23	GGTP: GAMMA GLUTAMYL TRANSPEPTIDASE - SERUM	BioChemistry
24	GLOBULIN - SERUM	BioChemistry
25	GLUCOSE - SERUM / PLASMA (FASTING)	BioChemistry
26	GLUCOSE - SERUM / PLASMA (POST PRANDIAL)	BioChemistry

Name : Mrs. AKSHATA S. GRAMPUROHIT		OP Number: BPLAH4753	Bill No: BPL-OCR-2307
27	GLYCOSYLATED HEMOGLOBIN (HBA1C) - WHOLE BLOOD		BioChemistry
28	HDL CHOLESTEROL - SERUM / PLASMA		BioChemistry
29	HISTORY TAKING - AHC		Medical
30	LDL CHOLESTEROL - SERUM / PLASMA		BioChemistry
31	LIPID PROFILE TEST (PACKAGE)		BioChemistry
32	LIVER FUNCTION TEST (PACKAGE)		BioChemistry
33	PAP SMEAR /CERVICAL SMEAR		Histopathology
34	PHYSICAL EXAMINATION		Medical
35	PROTEIN TOTAL - SERUM / PLASMA		BioChemistry
36	THYROID PACKAGE		BioChemistry
37	TMT/2D ECHO		CARDIOLOGY
38	TOTAL CHOLESTEROL AND HDL RATIO		BioChemistry
39	TOTAL T3: TRI IODOTHYRONINE - SERUM		BioChemistry
40	TOTAL T4: THYROXINE - SERUM		BioChemistry
41	TRIGLYCERIDES - SERUM / PLASMA		BioChemistry
42	TSH: THYROID STIMULATING HORMONE - SERUM		BioChemistry
43	ULTRASOUND - WHOLE ABDOMEN		Ultrasound Radiology
44	URIC ACID - SERUM / PLASMA		BioChemistry
45	URINE ROUTINE (CUE)		Haematology
46	VLDL CHOLESTEROL - SERUM		BioChemistry
47	X-RAY CHEST PA		X Ray

Amount saved on availing Health Check Package INR 13510

Note: Cancellation of individual test will not be refunded.

Amount saved on availing Health Check Package INR 13510