

Patient Name : Mrs.GANGA BAI	Collected : 27/Feb/2022 11:33AM
Age/Gender : 47 Y 0 M 0 D /F	Received : 27/Feb/2022 11:49AM
UHID/MR No : DSUS.0000001642	Reported : 27/Feb/2022 12:31PM
Visit ID : DSUSOPV1826	Status : Final Report
Ref Doctor : APOLLO CLINIC	Client Name : PUP APOLLO CLINIC SAMRIDDHI AR
IP/OP NO :	Patient location : Raipur,Raipur

DEPARTMENT OF IMMUNOLOGY

Test Name	Result	Unit	Bio. Ref. Range	Method
-----------	--------	------	-----------------	--------

THYROID PROFILE (TOTAL T3, TOTAL T4, TSH) , SERUM

TRI-iodothyronine (T3, TOTAL)	0.95	ng/mL	0.6-1.81	CLIA
THYROXINE (T4, TOTAL)	8.20	µg/dL	3.2-12.6	CLIA
THYROID STIMULATING HORMONE (TSH)	3.370	µIU/mL	0.35-5.5	CLIA

Comment:

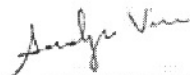
Serum TSH concentrations exhibit a diurnal variation with the peak occurring during the night and the nadir occurring between 10 a.m. and 4 p.m. In primary hypothyroidism, thyroid-stimulating hormone (TSH) levels will be elevated. In primary hyperthyroidism, TSH levels will be low. Elevated or low TSH in the context of normal free thyroxine is often referred to as subclinical hypo- or hyperthyroid-ism, respectively. Physiological rise in Total T3 / T4 levels is seen in pregnancy and in patients on steroid therapy.

Recommended test for T3 and T4 is unbound fraction or free levels as it is metabolically active.

Note:

For pregnant females	Bio Ref Range for TSH in uIU/ml (As per American Thyroid Association)
First trimester	0.1 - 2.5
Second trimester	0.2 - 3.0
Third trimester	0.3 - 3.0

*** End Of Report ***


Dr. SANDHYA VERMA
MBBS, MD,(Pathology)
Consultant Pathologist

Page 1 of 1



www.apolloh.com

Apollo Health and Lifestyle Limited

(CIN - U85110TG2000PLCT15819)

Corporate Office: 7-1-617/A, 7th Floor, Imperial Towers, Ameerpet, Hyderabad-500016, Telangana

Ph No: 040-4904 7777

www.apollohl.com | Email ID:enquiry@apollohl.com

Patient Name : Mrs. GANGA BAI
Age/Sex : 47 Y/F
Pres Doctor :
Ref.by : Bank of Baroda

MR No : FRAI.0000021663
Visit No : FRAIOPV39143
Bill Date : 26-02-2022 03:49
Report Date : 26-02-2022 19:20

RADIOGRAPH CHEST PA VIEW

FINDINGS:

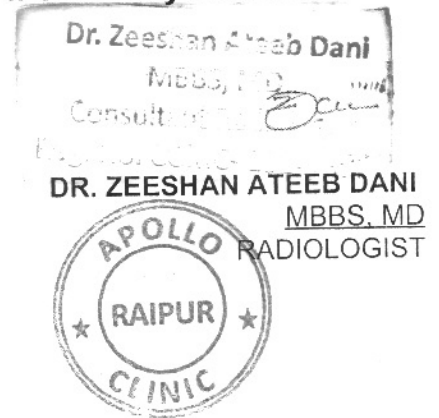
- Both the domes of diaphragm and CP angles are normal.
- Both the hila and mediastinum are normal.
- Both the lung fields are clear. No e/o focal parenchymal lesion.
- Cardiomegaly (CT ratio=56%) with left ventricular silhouette.
- Soft tissues and bony cage are unremarkable.

IMPRESSION:

CARDIOMEGALY.

Advised: Further evaluation with ECHO cardiography if clinically indicated.

Technician



*THIS PAPER IS USED FOR CLINICAL REPORTING PURPOSE ONLY

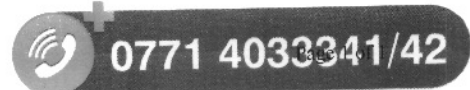Apollo Clinic

LICENSEE : SAMRIDDHI AROGYAM PVT. LTD.

Apollo Clinic @ Tiara Complex A.T. Classic Near Ashoka Ratan, VIP Estate, Shankar Nagar, Raipur (C.G.)

Email : raipur1@apolloclinic.com

Online appointments: www.askapollo.com | Online reports: <https://phr.apolloclinic.com>



www.apolloclinic.com

EXAMINATION OF EYES :- (BY OPHTHALMOLOGIST)

Patient Name Mrs Ganga Bai

Date 25/2/22

Sex/Age F/47

MR No

Employee Id

EXTERNAL EXAMINATION				
SQUINT		} NAD		
NYSTAGMUS				
COLOUR VISION				
FUNDUS:(RE):-		} NORMAL		
		} WNL (LE):- WNL		
INDIVIDUAL COLOUR IDENTIFICATION		} NORMAL		
DISTANT VISION:(RE):-		} 6/12 E 4 6/6 (LE):- 6/12 E 4 6/6		
NEAR VISION:(RE):-		} 18 E 4 16 (LE):- 18 E 4 16		
NIGHT BLINDNESS		} NAD		
	SPH	CYL	AXIS	ADD
RIGHT	+1.0	—	—	+1.75
LEFT	—	+1.0	10'	+1.75
REMARKS :-				

Dr. V. ...
MBBS, MS(O) ...
Reg. No ...



*THIS PAPER IS USED FOR CLINICAL REPORTING PURPOSE ONLY

Apollo Clinic

LICENSEE : SAMRIDDHI AROGYAM PVT. LTD.

Apollo Clinic @ Tiara Complex A.T. Classic Near Ashoka Ratan, VIP Estate, Shankar Nagar, Raipur (C.G.)

Email : raipur1@apolloclinic.com

Online appointments: www.askapollo.com | Online reports: https://phr.apolloclinic.com

 **0771 4033341/42**

www.apolloclinic.com



10 / MRS GANGA BAL... / 47 Yrs / F / 146 Cms / 78 Kg Date: 26-Feb-2022

Stage	Time	Duration	Speed(Kmph)	Elevation	METs	Rate	% THR	BP	RPP	PVC	Comments
Supine	00:03	0:03	00.0	00.0	01.0	102	59 %	140/90	142	00	
Standing	00:06	0:03	00.0	00.0	01.0	097	56 %	140/90	135	00	
ExStart	00:19	0:13	00.0	00.0	01.0	097	56 %	140/90	135	00	
BRUCE Stage 1	03:19	3:00	00.0	10.0	04.3	145	84 %	150/90	217	00	
PeakEx	03:26	0:07	00.8	00.0	04.4	136	79 %	150/90	204	00	
Recovery	03:56	0:30	00.8	00.0	01.3	126	73 %	150/90	189	00	
Recovery	04:26	1:00	00.8	00.0	01.0	111	64 %	140/90	155	00	
Recovery	04:32	1:07	00.8	00.0	01.0	109	63 %	140/90	152	00	

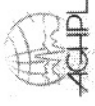FINDINGS :

Exercise Time : 03:07
 Max HR Attained : 145 bpm 84% of Target 173
 Max BP Attained : 150/90
 Max WorkLoad Attained : 4.4 Poor response to induced stress
 Test End Reasons : Test Complete, Test Complete, Heart Rate Achieved

REPORT :

Report: Stress test is Negative for Reversible Myocardial Ischemia with POOR function capacity.





10 / MRS GANGA BAL... / 47 Yrs / F / 146 Cms / 78 Kg / HR : 102

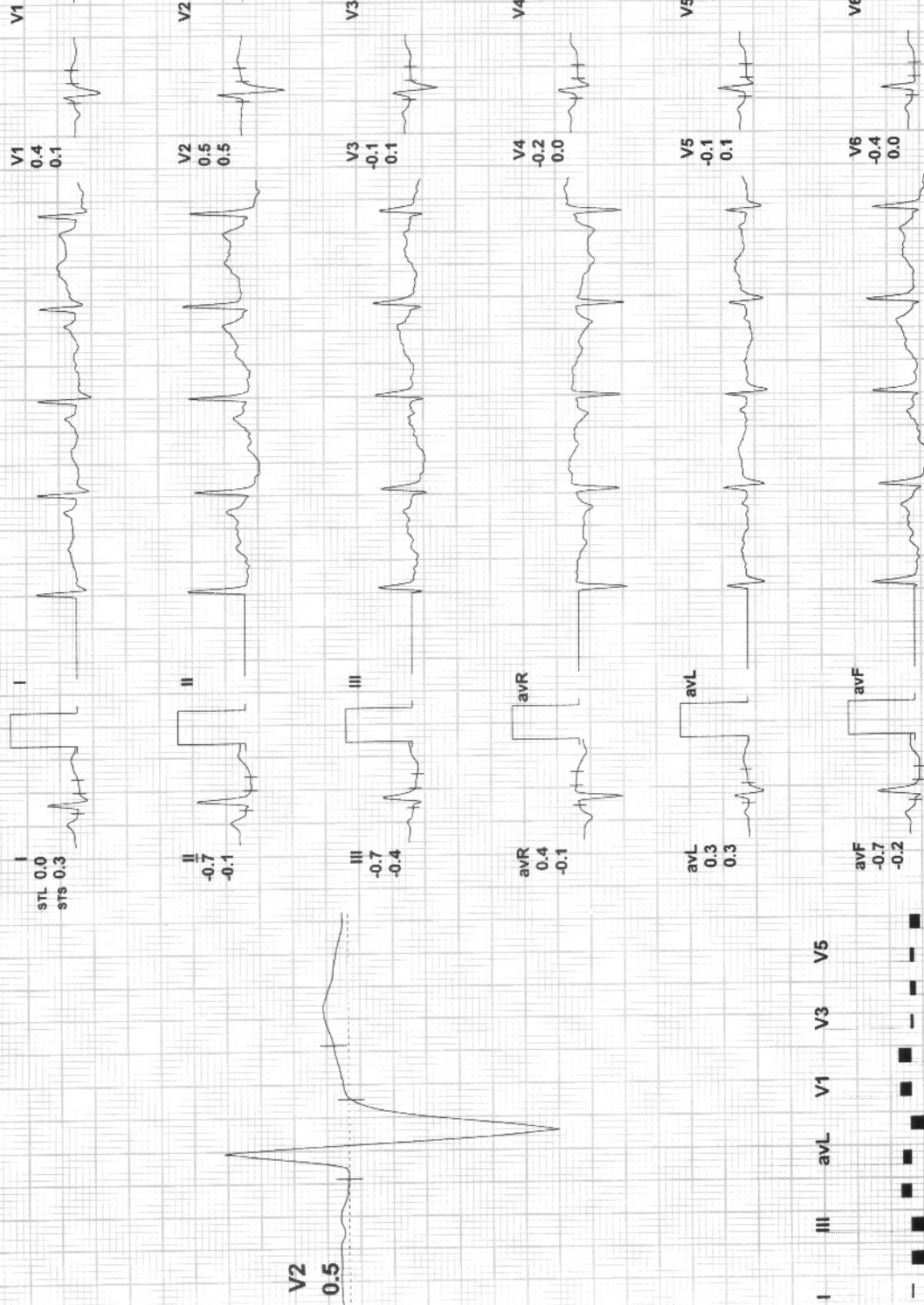
Date: 26-Feb-2022 12:38:24 PM

METS: 1.0 / 102 bpm 59% of THR

BP: 140/90 mmHg Raw ECG/ BLC On/ HF 0.05 Hz/LF 35 Hz

Ex Time: 00:00 0.0 Km/h, 0.0%
25 mm/Sec. 1.0 Cm/mV

4X 80 mS Post J



REMARKS: I II III aVR aVL aVF V1 V2 V3 V4 V5 V6



BRUCE: Standing(0:07)

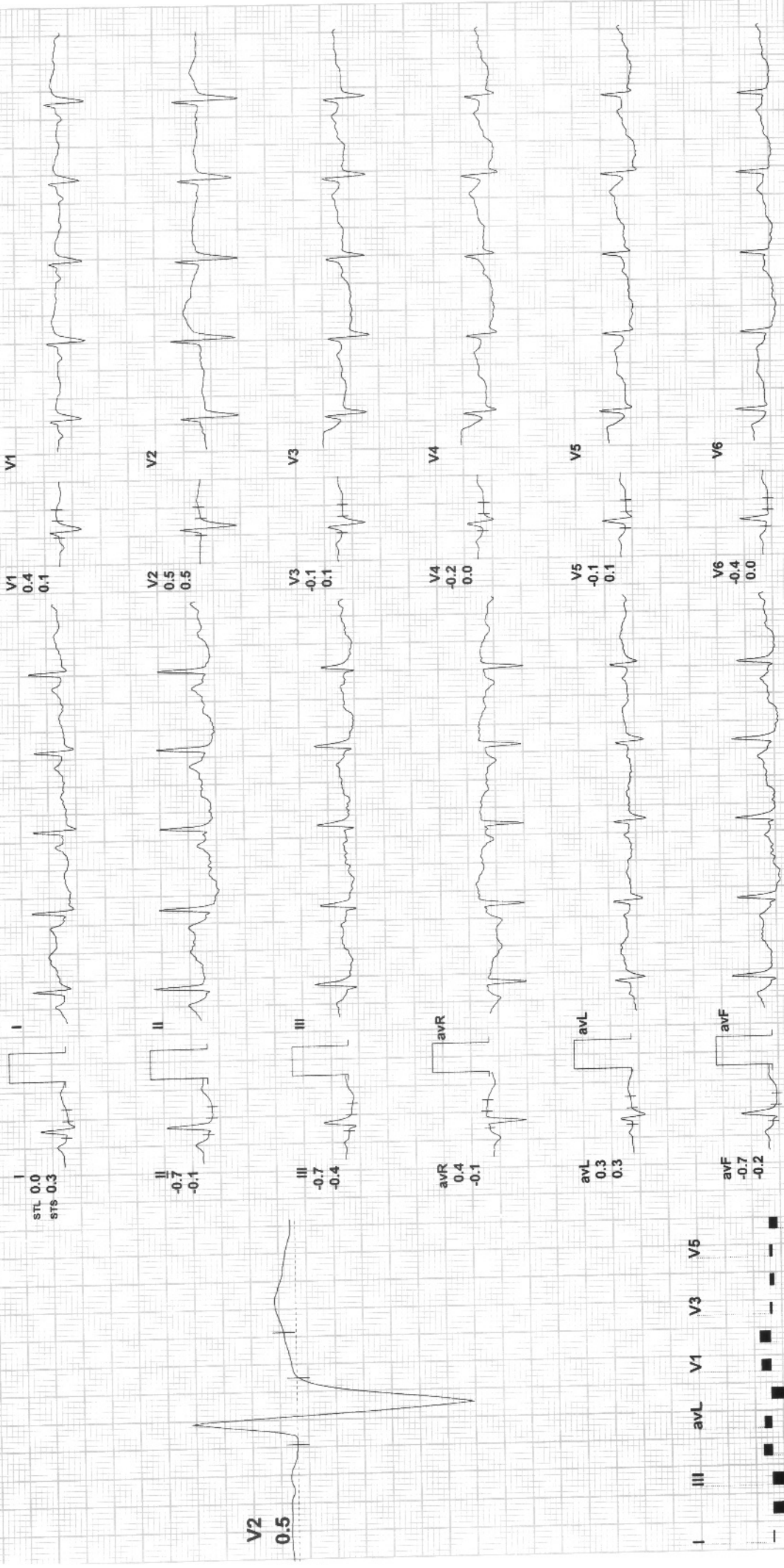
ipollo

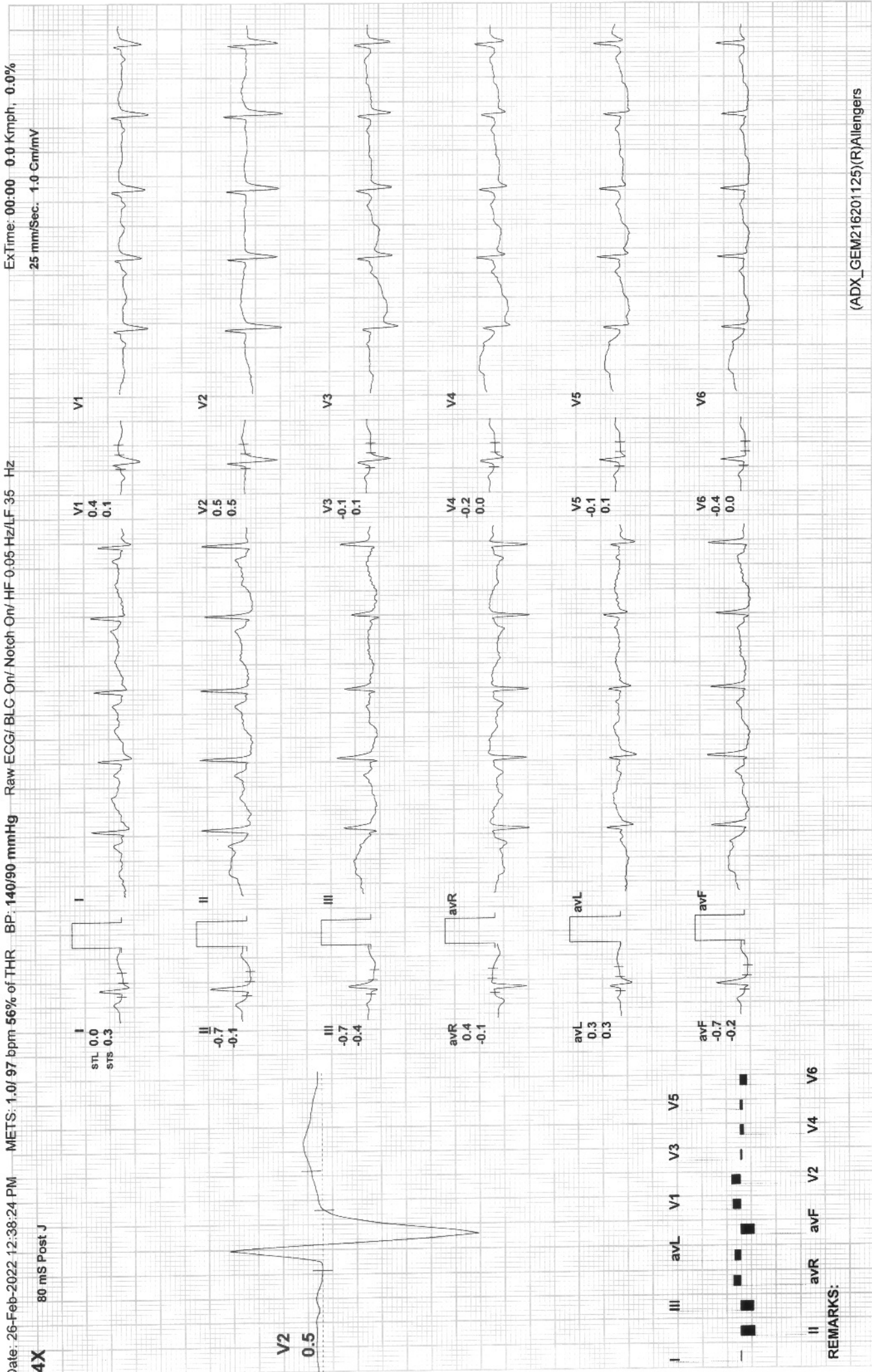
0 / MRS GANGA BAI... / 47 Yrs / F / 146 Cms / 78 Kg / HR : 97

late: 26-Feb-2022 12:38:24 PM METS: 1.0/ 97 bpm 56% of THR BP: 140/90 mmHg Raw ECG/BLC On/ Notch On/ HF 0.05 Hz/LF 35 Hz

ExTime: 00:00 0.0 Km/h: 0.0%
25 mm/Sec. 1.0 Cm/mV

4X 80 mS Post.J



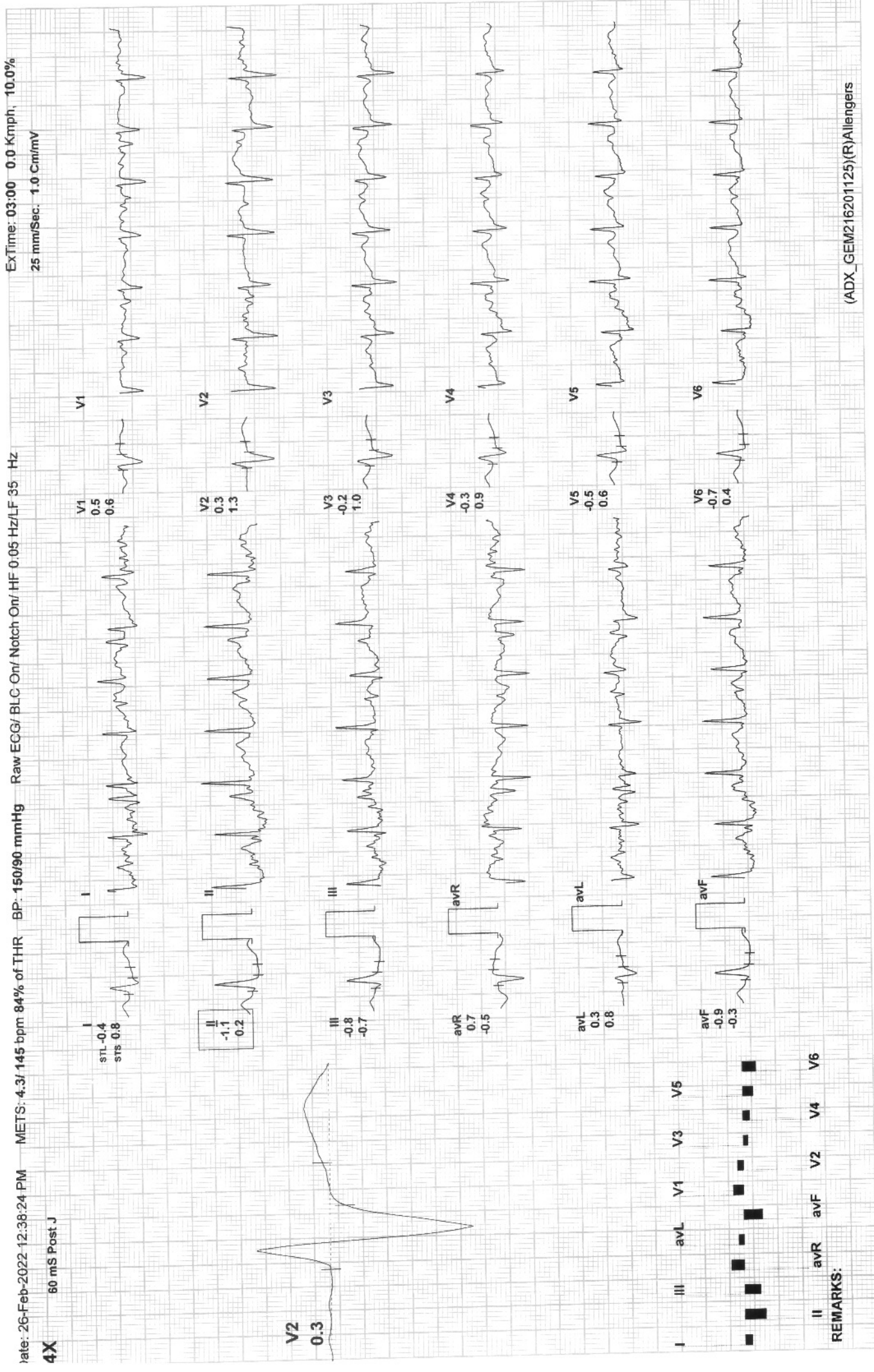




BRUCE: Stage 1(3:00)

ipollo

0 / MRS GANGA BAL... / 47 Yrs / F / 146 Cms / 78 Kg / HR : 145





PeakEx

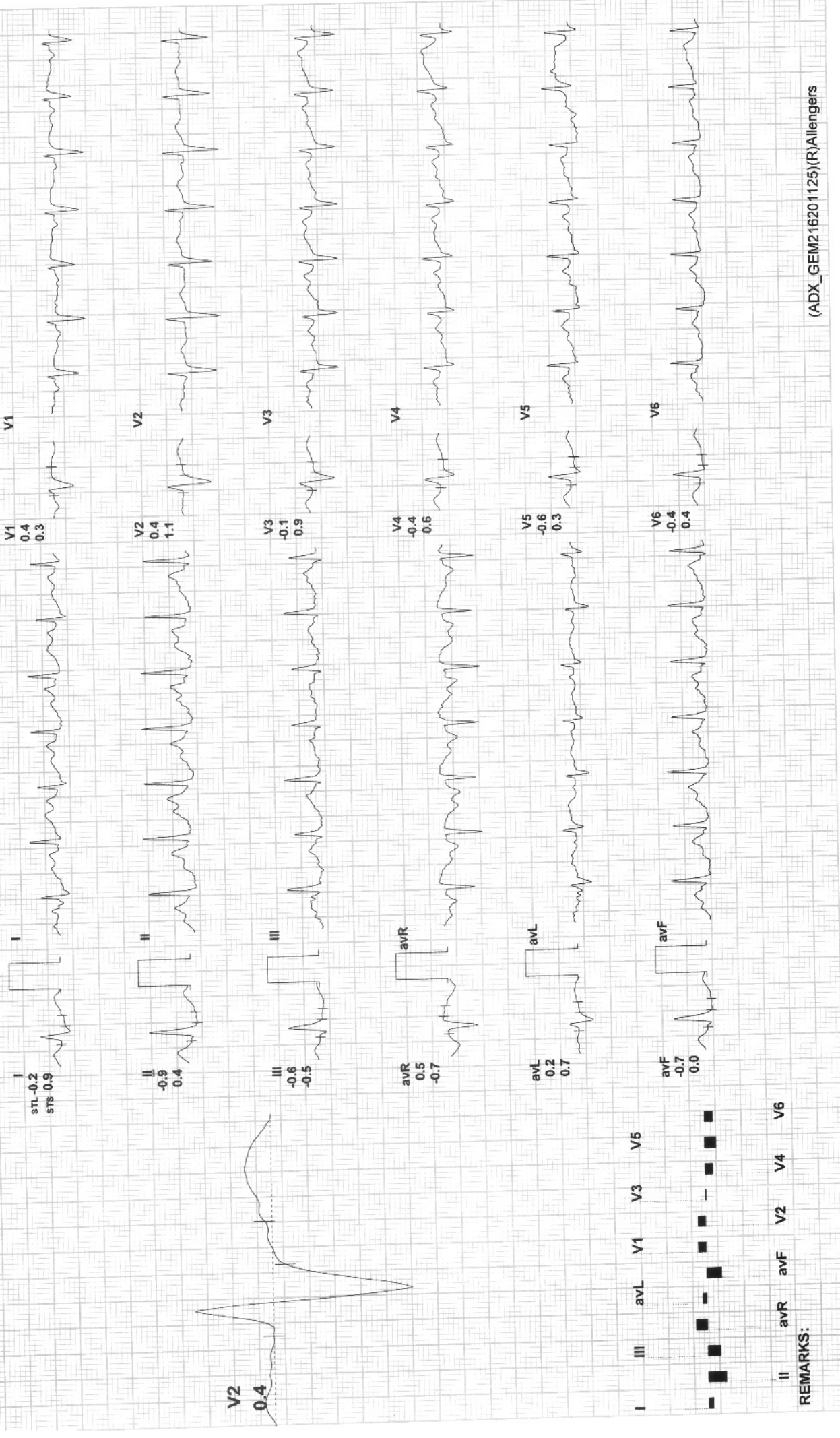
ipollo

0 / MRS GANGA BAI... / 47 Yrs / F / 146 Cms / 78 Kg / HR : 136

ExTime: 03:08 0.8 Km/h; 0.0%
25 mm/Sec. 1.0 Cm/mV

Date: 26-Feb-2022 12:38:24 PM METS: 4.4/136 bpm 79% of THR BP: 150/90 mmHg Raw ECG/BLG On/ HF 0.05 Hz/LF 35 Hz

4X 60 mS Post J



REMARKS:

(ADX_GEM216201125)(R)Allengers



Recovery(0:30)

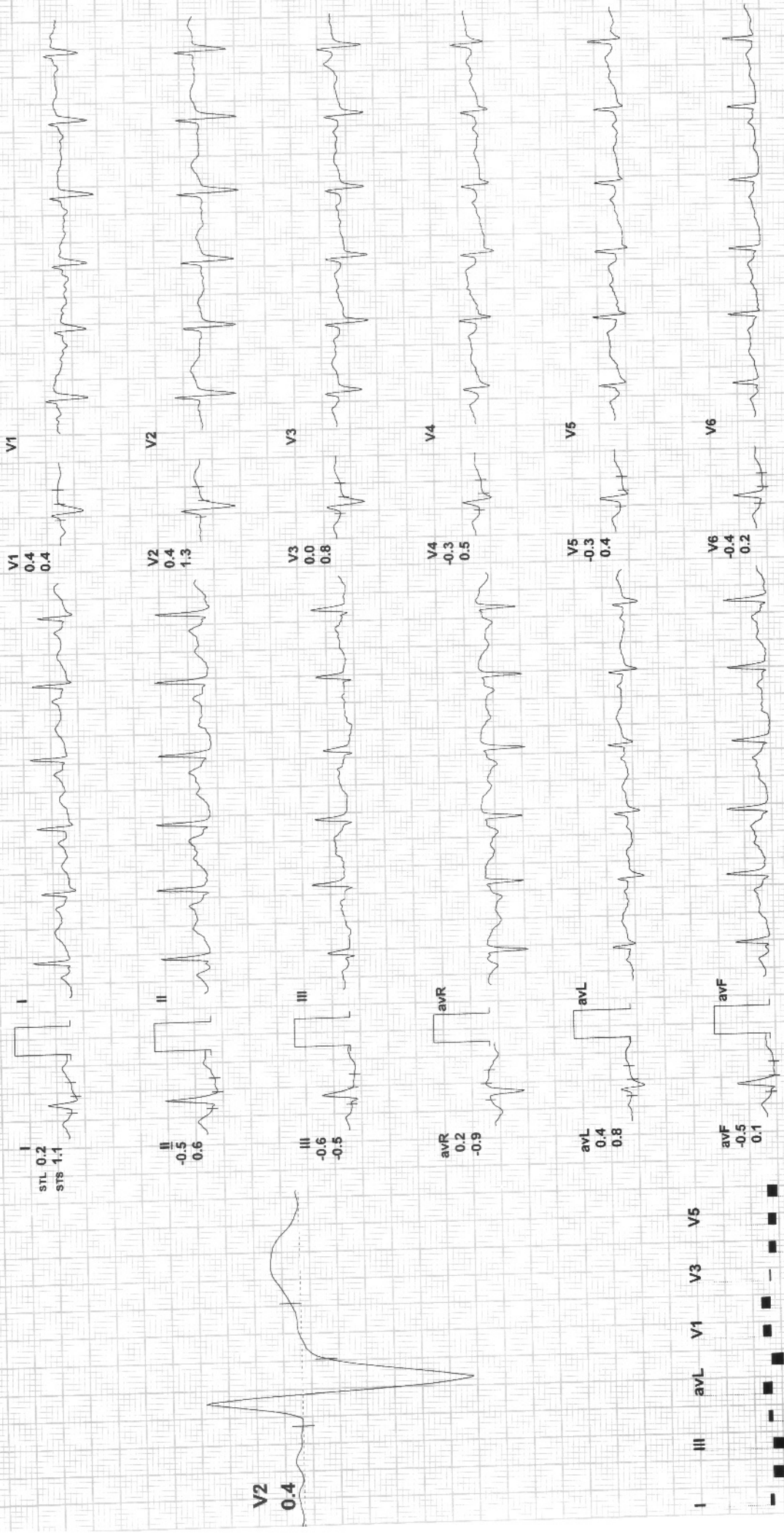
ipollo

0 / MRS GANGA BAI... / 47 Yrs / F / 146 Cms / 78 Kg / HR : 126

ExTime: 03:07 0.8 KmPh, 0.0%
25 mm/Sec., 1.0 Cm/mV

Rate: 26-Feb-2022 12:38:24 PM METS: 1.3/ 126 bpm 73% of THR BP: 150/90 mmHg Raw ECG/ BLC-On/ Notch On/ HF 0.05 Hz/LF 35 Hz

4X 60 mS Post J



REMARKS:

(ADX_GEM216201125)(R)Allengets



Recovery(1:00)

pollo

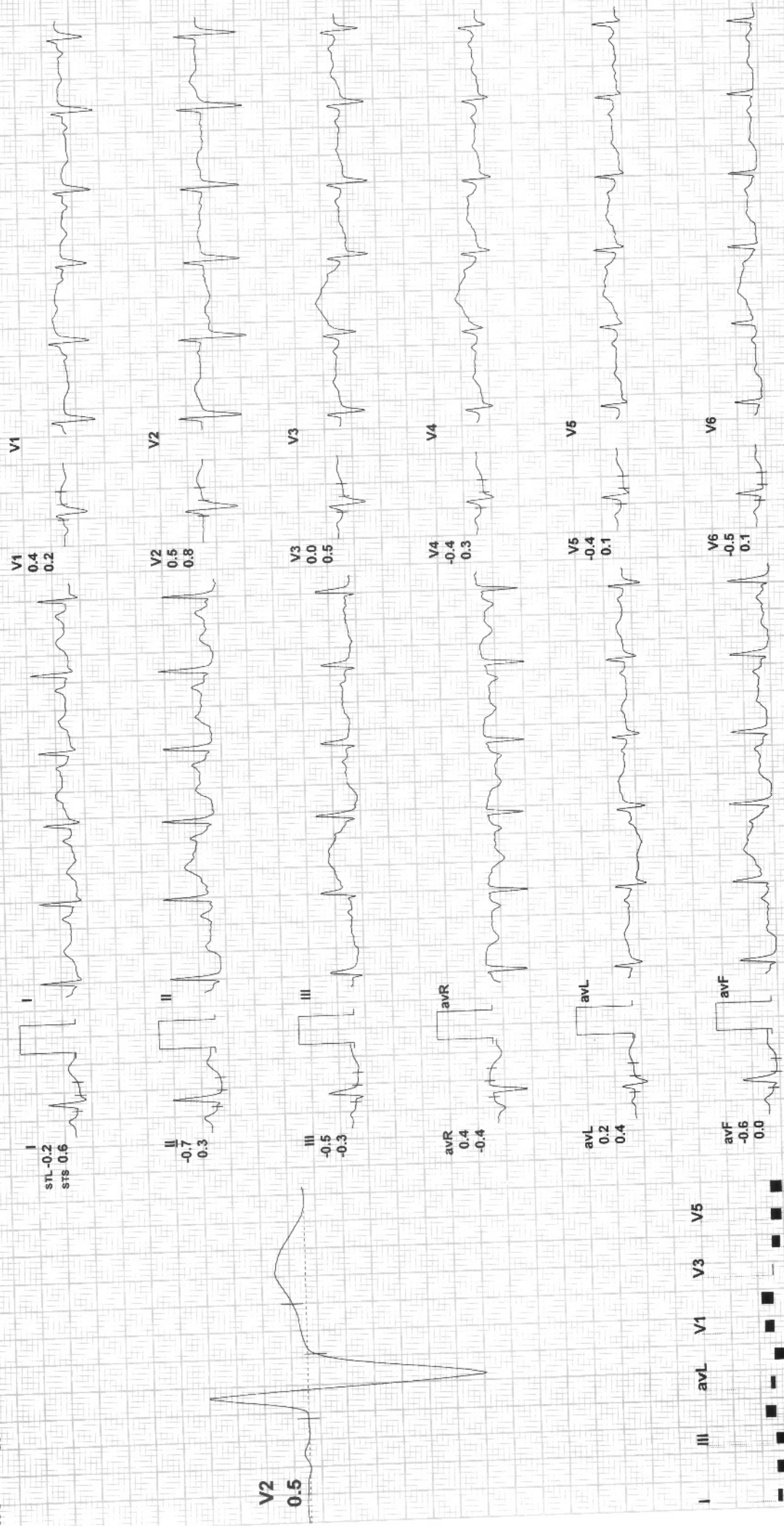
0 / MRS GANGA BAL... / 47 Yrs / F / 146 Cms / 78 Kg / HR : 111

ExTime: 03:07 0.8 Kmph, 0.0%
25 mm/Sec. 1.0 Cm/mV

MEIS: 1.0/ 111 bpm 64% of THR BP: 140/90 mmHg Raw ECG/ BLC On/ Notch On/ HF 0.05 Hz/LF 35 Hz

ate: 26-Feb-2022 12:38:24 PM

IX 80 mS Post J



REMARKS:

(ADX_GEM216201125)(R)Alengers



Recovery(1:07)

pollo

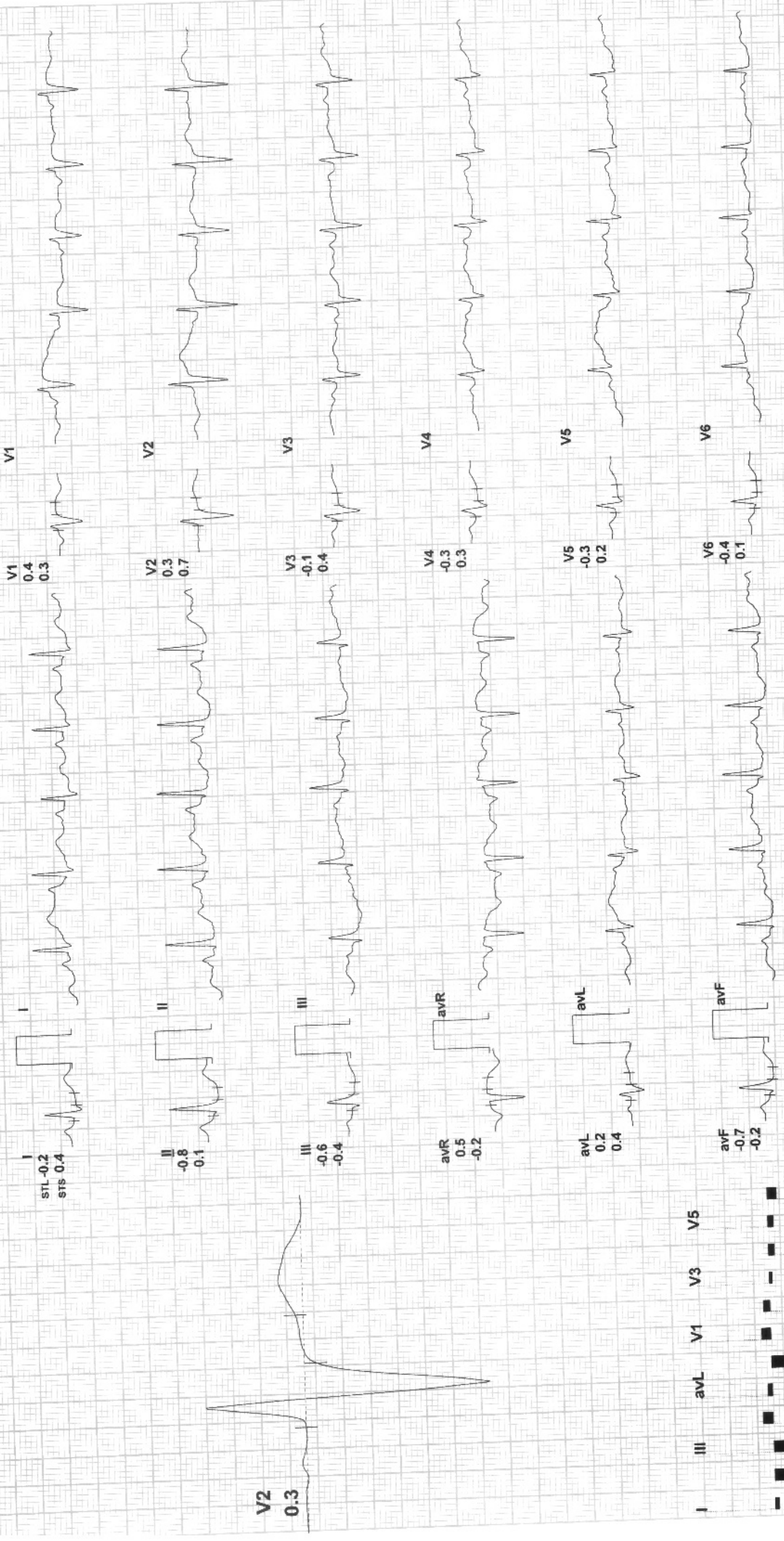
2 / MRS GANGA BAL... / 47 Yrs / F / 146 Cms / 78 Kg / HR : 109

ExTime: 03:07 0.8 Kmph, 0.0%
25 mm/Sec. 1.0 Cm/mV

Raw ECG/BLC On/ Notch On/ HF 0.05 Hz/LF 35 Hz

ate: 26-Feb-2022 12:38:24 PM METS: 1.0/ 109 bpm 63% of THR BP: 140/90 mmHg

IX 60 mS Post J



II III avR avL avF V1 V2 V3 V4 V5 V6

REMARKS:

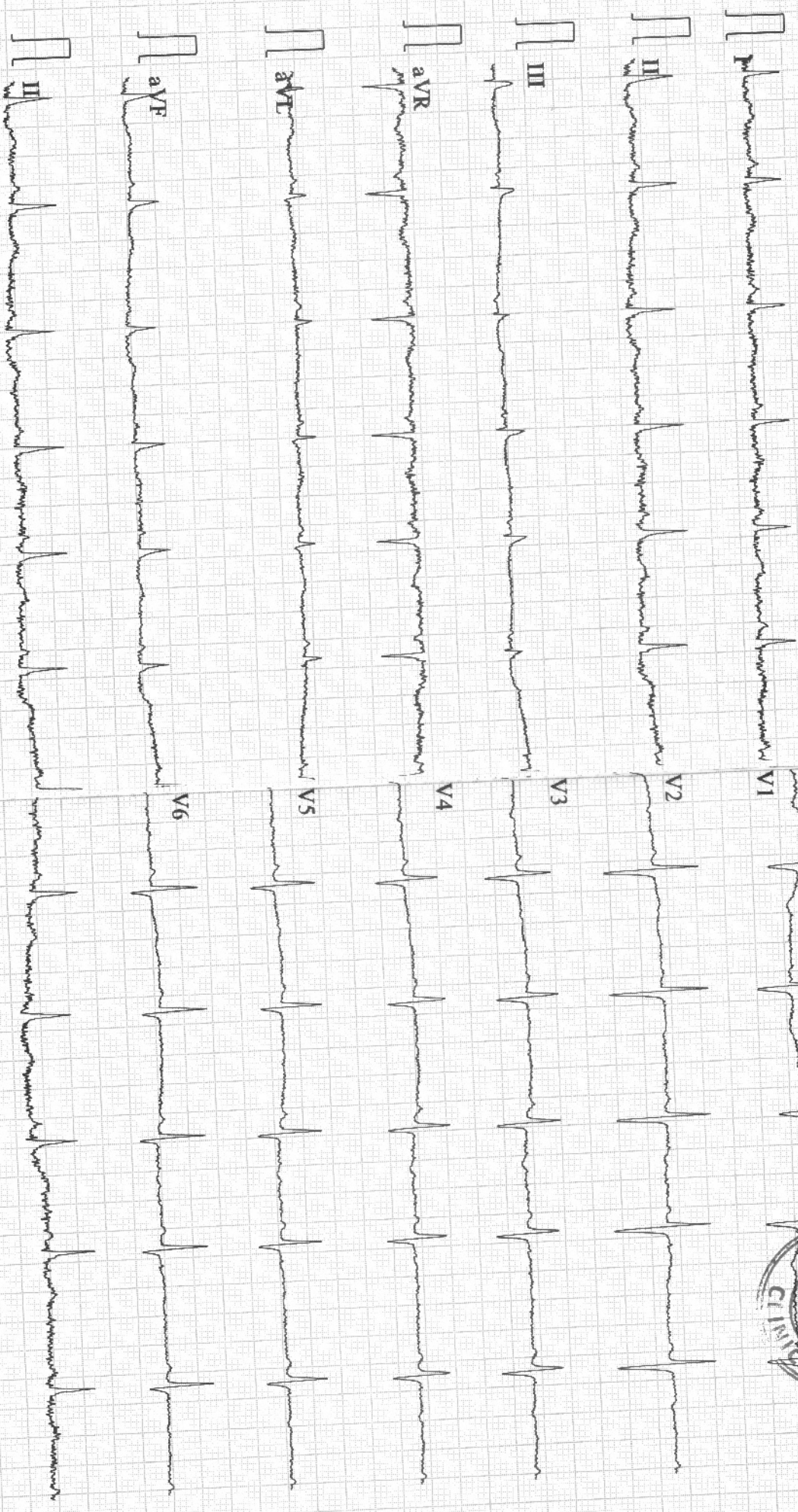

ID: 391
 MRS GANGA SAHU
 Female 47Years

26-02-2022 10:10:51 AM
 HR : 72 bpm
 P : 80 ms
 PR : 122 ms
 QRS : 90 ms
 QT/QTc : 414/454 ms
 P/QRS/T : 28/42/34 °
 RV5/SV1 : 0.696/0.555 mV

Diagnosis Information:
 Sinus arrhythmia
 Inferior and anterior T wave abnormality is nonspecific
 Borderline ECG

Report Confirmed by:

Dr. Animesh Choudhary
 MD Medicine
 Reg. No. 10000000000
 Apollo



0.05~45Hz AC50 25mm/s 10mm/mV 2*5.0s+1r ♡72 CARDI 9108 D V1.43 Glasgow V28.6.0 APOLLO CLINIC RAIPUR

0771 4033



Dr. Sudha Agrawal
 TVSX

Physio -
 Char (m) - (m)

H/O - HTN - since 5 yrs.
 - BIC done

PMS - all v/s -
 all v/s / 24y - / done last

m/h -
 PMS - Reg/No, 34 done / 25.30 done
 m/h - 12/2/22

Ganga Bai / 4/4/14
 Pain in the bag

26/2/22

Dr. Sudha Agrawal Choudhury
 MBBS, MS(OBG), DNB, F.M.A.S., FRM (Gujarat University)
 Consultant Gynaecologist - Apollo Clinic Raipur
Specialist - Infertility (IUI, IVF) Ultrasonography (TVS, Doppler, 3D, 4D)
 Formerly - AMRI Hospital (BBSR), IMS & SUM Medical college (BBSR), RKMS & VIMS (Kolkata)
 Sumiran Women's Hospital (Ahmedabad), Narkari Testube Baby Centre (Surat),
 Dr. Nagar's Institute of Infertility & IVF (Ahmedabad)
 Reg. No. : C.G.M.C./10775/2021
Laparoscopy Surgeon & Infertility Specialist



Patient Name : Mrs. GANGA BAI
UHID/MR No. : FRAI.0000021663
Visit Date : 26-02-2022 15:49
Sample Collected on : 26-02-2022 17:56
Ref Doctor : Bank of Baroda

Age / Gender : 47Y/Female
OP Visit No : FRAIOPV39143
Reported on : 27-02-2022 11:05
Specimen : Whole Blood (Edta)
Pres Doctor :

DEPARTMENT OF LABORATORY MEDICINE

TEST NAME	RESULT	BIOLOGICAL REFERENCE INTERVALS	UNITS
HAEMOGRAM			
Hb(Haemoglobin) Method: CELL COUNTER	11.4*	12.0 - 15.0	gm%
RBC Count Method: CELL COUNTER	4.54	3.5 - 5.5	million/ cumm
PCV / Haematocrit Method: CELL COUNTER	36.1*	37 - 50	%
MCV Method: CELL COUNTER	79.4	76 - 96	fl
MCH Method: CELL COUNTER	25.1*	27 - 32	pg
MCHC Method: CELL COUNTER	31.6	31 - 35	gm/dl
RDW Method: CELL COUNTER	14.5	12 - 15.1	%
Total Leukocyte Count Method: CELL COUNTER	6.77.	4 - 11	thous/ cumm
Neutrophil Method: CELL COUNTER	61	40 - 75	%
Lymphocyte Method: CELL COUNTER	31	20 - 40	%
Eosinophil Method: CELL COUNTER	02	1 - 6	%
Monocyte Method: CELL COUNTER	06	2 - 8	%
Basophil Method: CELL COUNTER	00	0 - 1	%
Platelet Count Method: CELL COUNTER	289	150 - 450	lacs/cumm
E S R Method: Westergren's Method	25*	00 - 20	mm/hr

End of the report

Dr. Avishesh Kumar Singh
MBBS, MD
Pathologist
Reg. No. -5767/2014

Results are to be correlated clinically

*THIS PAPER IS USED FOR CLINICAL REPORTING PURPOSE ONLY

Apollo Clinic

LICENSEE : SAMRIDHI AROGYAM PVT. LTD.

Lab Technician / Technologist
Apollo Clinic @ Tirra Complex A.T. Classic Near Ashoka Ratan, VIP Estate, Shankar Nagar, Raipur (C.G.)
Shubham Triakur

Email : raipur1@apolloclinic.com

Online appointments: www.askapollo.com | Online reports: https://phr.apolloclinic.com

Dr. AVISHESH KUMAR SINGH
MBBS, MD
0771 4033341/42

Patient Name : Mrs. GANGA BAI
UHID/MR No. : FRAI.0000021663
Visit Date : 26-02-2022 15:49
Sample Collected on : 26-02-2022 17:56
Ref Doctor : Bank of Baroda

Age / Gender : 47Y/Female
OP Visit No : FRAIOPV39143
Reported on : 27-02-2022 11:05
Specimen : EDTA Blood
Pres Doctor: :

DEPARTMENT OF LABORATORY MEDICINE

TEST NAME	RESULT	BIOLOGICAL REFERENCE INTERVALS	UNITS
BLOOD GROUP AND RH TYPE			
BLOOD GROUP	O		
Method: Slide Test			
RH:	Positive		
TEST NAME	RESULT	BIOLOGICAL REFERENCE INTERVALS	UNITS
GLUCOSE - (POST PRANDIAL)			
GLUCOSE - (POST PRANDIAL)	142.0*	70 - 140	mg/dl
Method: REAGENT GRADE WATER			
GLUCOSE - (FASTING)			
GLUCOSE - (FASTING)	75.0	60 - 120	mg/dl
Method: REAGENT GRADE WATER			
GLYCOSYLATED HEMOGLOBIN (HBA1C)			
GLYCOSYLATED HEMOGLOBIN (HBA1C) - WHOLE BLOOD..	6.6	Non-diabetic: <= 5.6 Pre-diabetic: 5.7 - 6.4 Diabetic: >= 6.5	%
Method: TURBIDOMETRY			
KFT - RENAL PROFILE-SERUM			
BUN :	10	7 - 20	mg/dL
Method: Spectrophotometric			
Creatinine .	1.11	0.6 - 1.2	mg/dL
Method: Jaffe			
Uric Acid	4.30	2.6 - 7.2	mg/dL
Method: Enzymatic			

End of the report

Results are to be correlated clinically

Lab Technician / Technologist
Shubham_Thakur

Dr. Avishesh Kumar Singh
MBBS, MD
Pathologist
Reg. No. - 5767/2017
Dr. AVISHESH KUMAR SINGH
MBBS, MD
Pathologist

*THIS PAPER IS USED FOR CLINICAL REPORTING PURPOSE ONLY

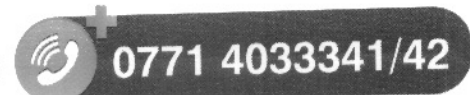
Apollo Clinic

LICENSEE : SAMRIDDI AROGYAM PVT. LTD.

Apollo Clinic @ Tiara Complex A.T. Classic Near Ashoka Ratan, VIP Estate, Shankar Nagar, Raipur (C.G.)

Email : raipur1@apolloclinic.com

Online appointments: www.askapollo.com | Online reports: https://phr.apolloclinic.com



Patient Name : Mrs. GANGA BAI
UHID/MR No. : FRAI.0000021663
Visit Date : 26-02-2022 15:49
Sample Collected on : 26-02-2022 17:56
Ref Doctor : Bank of Baroda

Age / Gender : 47Y/Female
OP Visit No : FRAIOPV39143
Reported on : 27-02-2022 11:05
Specimen : Serum
Pres Doctor: :

DEPARTMENT OF LABORATORY MEDICINE

TEST NAME	RESULT	BIOLOGICAL REFERENCE INTERVALS	UNITS
LIPID PROFILE TEST (PACKAGE)			
Total Cholesterol	152.0	00 - 200	mg/dl
Method: Spectrophotometric			
Triglyceride	78.0	60 - 150	mg/dl
Method: Spectrophotometric			
HDL	43.0	35 - 60	mg/dl
Method: Spectrophotometric			
LDL	93.4	60 - 130	mg/dl
Method: Spectrophotometric			
VLDL	15.6	10 - 50	mg/dl
Method: Spectrophotometric			
Cholesterol/HDL	3.53		
Method: Spectrophotometric			

End of the report

Results are to be correlated clinically

Lab Technician / Technologist
Shubham_Thakur


Dr. AVISHESH KUMAR SINGH
MBBS, MD
Pathologist

Dr. Avishesh Kumar Singh
MBBS, MD
Pathologist
Reg. No. -5767/2014

*THIS PAPER IS USED FOR CLINICAL REPORTING PURPOSE ONLY


Apollo Clinic

LICENSEE : SAMRIDDI AROGYAM PVT. LTD.

Apollo Clinic @ Tiara Complex A.T. Classic Near Ashoka Ratan, VIP Estate, Shankar Nagar, Raipur (C.G.)

Email : raipur1@apolloclinic.com

Online appointments: www.askapollo.com | Online reports: https://phr.apolloclinic.com

 **0771 4033341/42**

Patient Name : Mrs. GANGA BAI
UHID/MR No. : FRAI.0000021663
Visit Date : 26-02-2022 15:49
Sample Collected on : 26-02-2022 17:56
Ref Doctor : Bank of Baroda

Age / Gender : 47Y/Female
OP Visit No : FRAIOPV39143
Reported on : 27-02-2022 11:05
Specimen : Serum
Pres Doctor: :

DEPARTMENT OF LABORATORY MEDICINE

TEST NAME	RESULT	BIOLOGICAL REFERENCE INTERVALS	UNITS
LFT WITH GGT			
TOTAL BILIRUBIN (DPD) Method: Enzymatic	0.5	0.1 - 1.2	mg/dl
DIRECT BILIRUBIN (DPD) Method: Spectrophotometric	0.1	0.05 - 0.3	mg/dl
INDIRECT BILLIRUBIN Method: Spectrophotometric	0.4	0.1 - 1	mg/dl
SGPT/ALT (IFCC) Method: Enzymatic	30	6 - 40	U/L
SGOT/AST (IFCC) Method: Enzymatic	24	6 - 32	U/L
S.ALKALINE PHOSPHATASE Method: Spectrophotometric	89	25 - 147	IU/L
GGT (IFCC) Method: Spectrophotometric	66	5 - 80	U/L
TOTAL PROTEIN (BIURET) Method: Spectrophotometric	6.3	6 - 8	g/dl
ALBUMIN (BCG) Method: Spectrophotometric	3.8	3.5 - 5.0	g/dl
S.GLOBULIN Method: Spectrophotometric	2.5	1.5 - 3.6	g/dl
S.A/G RATIO Method: Spectrophotometric	1.52		

End of the report

Results are to be correlated clinically

Lab Technician / Technologist
Shubham_Thakur

Dr. Avishesh Kumar Singh
MBBS, MD
Pathologist
Reg. No. - 5767/2014

Dr. AVISHESH KUMAR SINGH
MBBS, MD
Pathologist

*THIS PAPER IS USED FOR CLINICAL REPORTING PURPOSE ONLY


Apollo Clinic

LICENSEE : SAMRIDDI AROGYAM PVT. LTD.

Apollo Clinic @ Tiara Complex A.T. Classic Near Ashoka Ratan, VIP Estate, Shankar Nagar, Raipur (C.G.)

Email : raipur1@apolloclinic.com

Online appointments: www.askapollo.com | Online reports: https://phr.apolloclinic.com

 **0771 4033341/42**

Patient Name : Mrs. GANGA BAI
UHID/MR No. : FRAI.0000021663
Visit Date : 26-02-2022 15:49
Sample Collected on : 26-02-2022 17:56
Ref Doctor : Bank of Baroda

Age / Gender : 47Y/Female
OP Visit No : FRAIOPV39143
Reported on : 27-02-2022 11:05
Specimen : Urine
Pres Doctor: :

DEPARTMENT OF LABORATORY MEDICINE

URINE ROUTINE EXAMINATION

Test	Result	Bio. Ref. Interval
PHYSICAL EXAMINATION:		
Volume of urine	30 ml	
Colour	Pale Yellow	
Specific Gravity	1.005	1.001 - 1.030
Deposit	Absent	Absent
Appearance	Clear	Clear
pH	5.0	5.0 - 7.5
CHEMICAL EXAMINATION:		
Protein	Absent	Absent
Sugar	Absent	Absent
Ketone Bodies	Absent	Absent
Blood	Absent	Absent
Leukocytes	Absent	Absent
Urobilinogen	Absent	Absent
Bili Pigments	Absent	Absent
MICROSCOPIC EXAMINATION:		
Pus Cell	2 - 4	0 - 5 / hpf
Red Blood Cells	Not Seen	0 - 2 / hpf
Epithelial Cells	Occasional	0 - 5 / hpf
Cast	Not Seen	Not seen
Crystals	Not Seen	Not seen

End of the report

Results are to be correlated clinically

Lab Technician / Technologist
Shubham_Thakur

Dr. Avishesh Kumar Singh
MBBS, MD
Pathologist
Reg. No - 5767/2014
Dr. AVISHESH KUMAR SINGH
MBBS, MD
Pathologist

*THIS PAPER IS USED FOR CLINICAL REPORTING PURPOSE ONLY

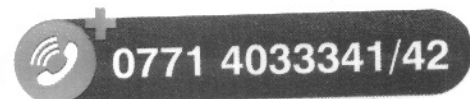
Apollo Clinic

LICENSEE : SAMRIDDI AROGYAM PVT. LTD.

Apollo Clinic @ Tiara Complex A.T. Classic Near Ashoka Ratan, VIP Estate, Shankar Nagar, Raipur (C.G.)

Email : raipur1@apolloclinic.com

Online appointments: www.askapollo.com | Online reports: https://phr.apolloclinic.com



PATIENT NAME: MRS.GANGA BAI
REF BY: SELF

AGE / SEX: 47YRS/F
DATE: 26 /02/2022

SONOGRAPHY BILATERAL BREASTS

FINDINGS:


- Both breast tissues are symmetrical and appear normal in size and echotexture.
- There are well defined hypoechoic lesion with no obvious internal vascularity seen in following position of right breast-
- 6 o'clock position size 13.7X7.1 mm on right side
- 9 o'clock position size 5.5x4.5 mm on right side
- 10o'clock position size 7.0x4.7 mm on right side
- Nipple, areola and subareolar region also appear normal.
- Bilateral axilla visualised normal without any evidence of lymphadenopathy.

IMPRESSION:

- **RIGHT BIRADS GRADE-II LESION LIKELY FIBROADENOMA.**

Advised clinical correlation and further evaluation.



Dr. Zeeshan Ateeb Dani

 Consultant Radiologist
DR. ZEESHAN ATEEB DANI
MD
CONSULTANT RADIOLOGIST

This report is for perusal of the doctor only not the definitive diagnosis; findings have to be clinically correlated. Ultrasound has its limitations in obese patients and in retroperitoneal organs. All congenital abnormalities cannot be detected on ultrasound. Sex of the fetus is not determined here. This report is not for medico-legal purposes.

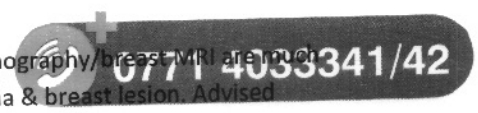Apollo Clinic

LICENSEE : SAMRIDDHI AROGYAM PVT. LTD.

Apollo Clinic @ Tiara Complex A. 1. Classic Near Ashoka Naran, VIP Estate, Shankar Nagar, Raipur (C.G.)

Email : raipur1@apolloclinic.com

Online appointments: www.askapollo.com | Online reports: https://phr.apolloclinic.com



www.apolloclinic.com

PATIENT NAME: MRS.GANGA BAI
REF BY: SELF

AGE / SEX: 47YRS/F
DATE: 26 /02/2022

USG ABDOMEN

Liver: Liver is normal in size smooth in outline & raised echotexture. IHBR's are not dilated. CBD is not dilated. Portal vein and hepatic veins are normal.

Gall bladder: Distended and normal.

Pancreas & Paraaortic Region: Normal.

Spleen: Is normal in size, and echotexture.

Kidneys	RIGHT	LEFT
SIZE	9.80X3.70Cm	10.40X2.50 Cm
CORTICAL ECHOGENICITY	Normal	Normal
CORTICOMEDULLARY DIFFERENTIATION	Maintained	Maintained
PCS	Not Dilated	Not Dilated
Any other remarks	Nil	Nil

Urinary bladder: Distended & normal.

Uterus is normal in size (4.8X3.8X8.1 cm, Vol. -78cc) and echotexture. Endometrial thickness 3 mm.

Bilateral Adnexa Normal

No evidence of free fluid in abdomen or pelvis.

IMPRESSION:

- **GRADE-I FATTY LIVER.**

Advised clinical correlation/further evaluation if clinically indicated.



Dr. Zeeshan Ateeb Dani
MBBS, MD
Consultant Radiologist

DR. ZEESHAN ATEEB DANI
(MD)
CONSULTANT RADIOLOGIST

This report is for perusal of the doctor only not the definitive diagnosis; findings have to be clinically correlated. Ultrasound has its limitations in obese patients and in retroperitoneal organs. All congenital abnormalities cannot be detected on ultrasound. This report is not for medico-legal purposes.

*THIS PAPER IS USED FOR CLINICAL REPORTING PURPOSE ONLY

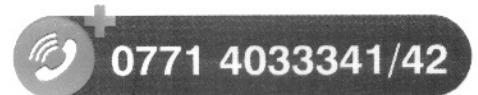
Apollo Clinic

LICENSEE : SAMRIDDHI AROGYAM PVT. LTD.

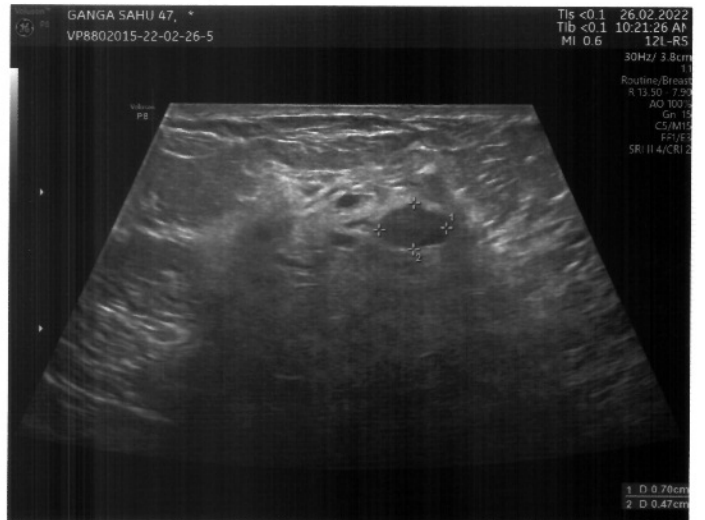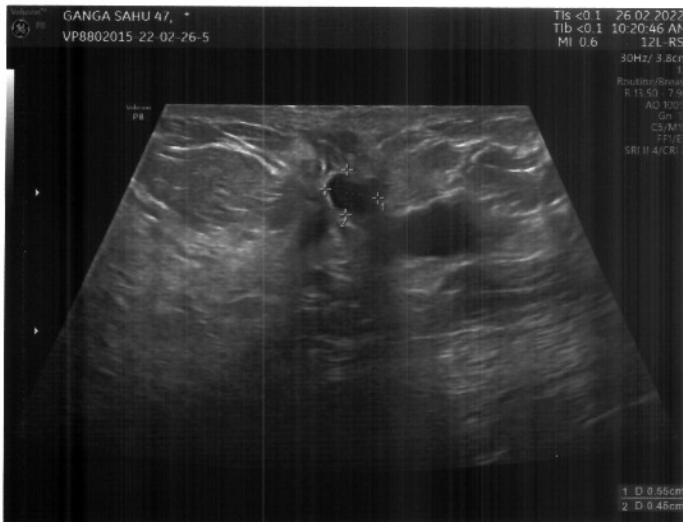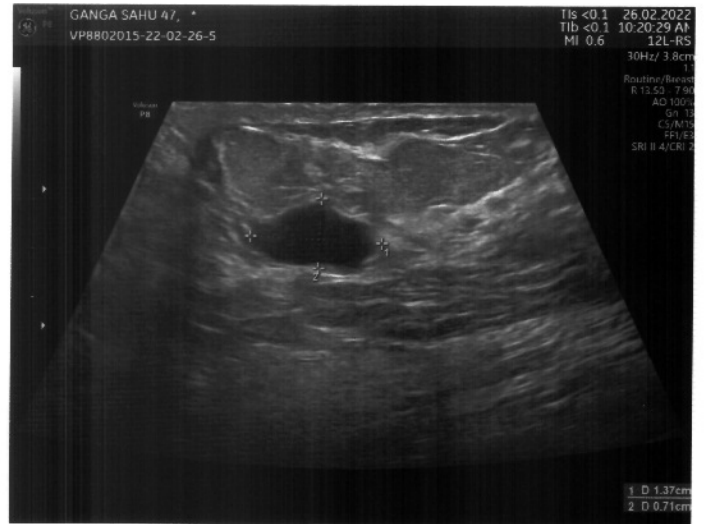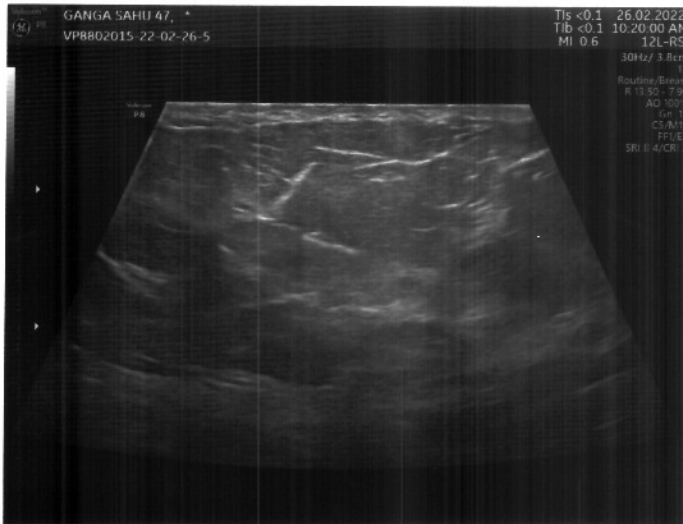
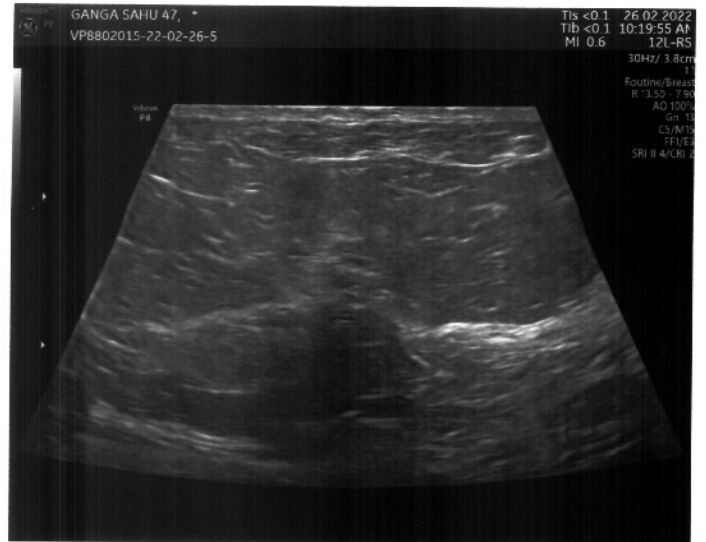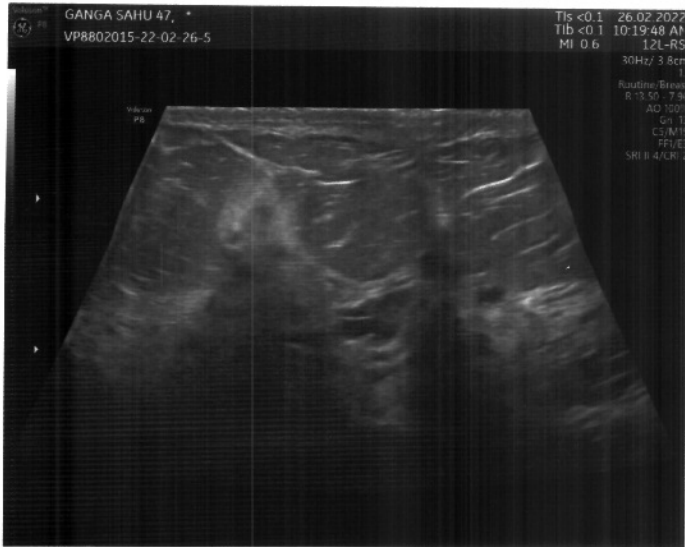Apollo Clinic @ Tiara Complex A.T. Classic Near Ashoka Ratan, VIP Estate, Shankar Nagar, Raipur (C.G.)

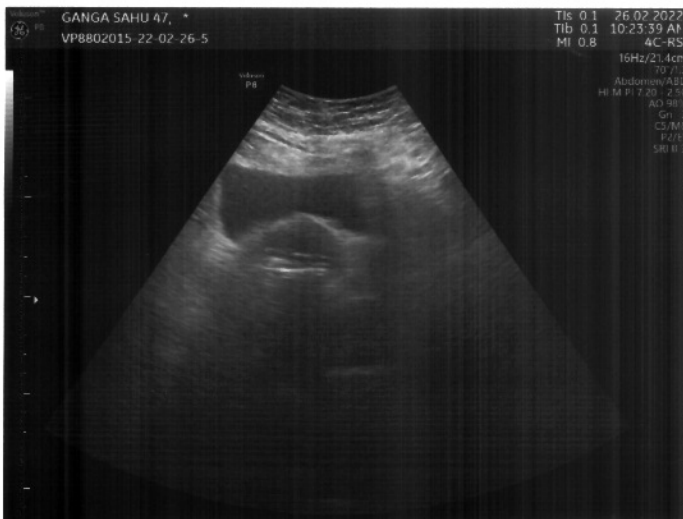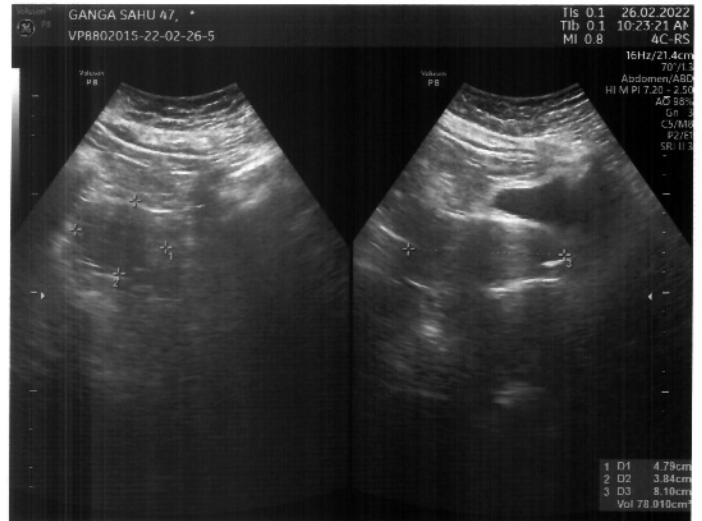
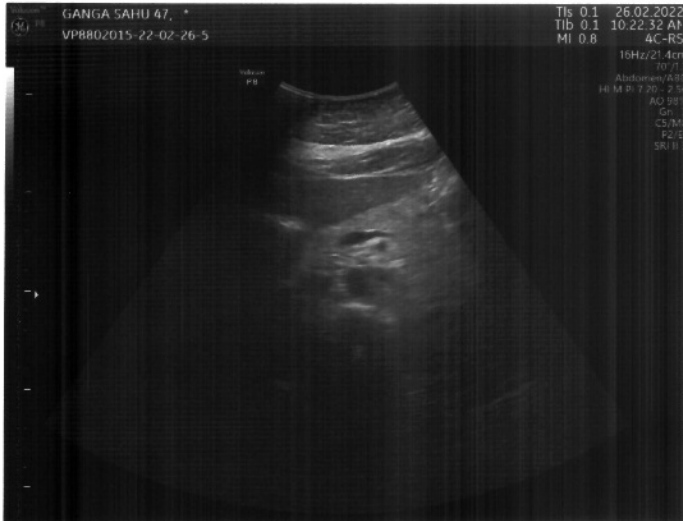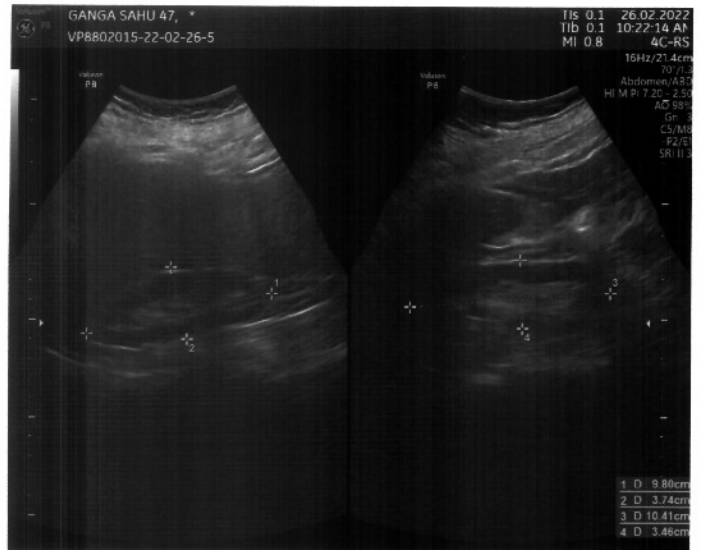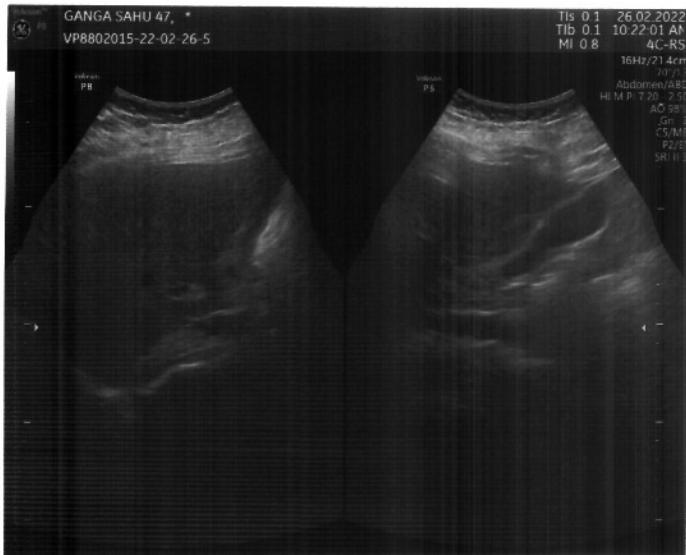
Email : raipur1@apolloclinic.com

Online appointments: www.askapollo.com | Online reports: https://phr.apolloclinic.com



www.apolloclinic.com







सत्यमेव जयते
भारत सरकार



आधार

भारतीय विशिष्ट पहचान अधिकरण

भारत सरकार

Unique Identification Authority of India

Government of India

नामांकन क्रम / Enrollment No 1307/20024/01662

To,

गंगा बाई

GANGA BAI

W/O: Shashi Kumar Sahu

PARAS NAGAR

WARD KR. -22

POSTMAN GALI

Raipur

Raipur Bindrawangarh Raipur

Chhattisgarh 492001

9669053040

08/03/2014

Ref: 235 / 20C / 240468 / 241656 / P



SE005089512FT



आपका आधार क्रमांक / Your Aadhaar No. :

3569 3700 5951

आधार - आम आदमी का अधिकार



भारत सरकार

Government of India



गंगा बाई

GANGA BAI

पिता : दाऊ लाल

Father : DAULAL

जन्म तिथि / DOB : 05/05/1974

महिला / Female



3569 3700 5951

आधार - आम आदमी का अधिकार

