

**Facilities:**

All clinical Biomedical & Hematology Investigations including Bone Marrow Examination VPT, Podiascan & Complete Foot Care (First Time in Purvanchal) All Hormonal Investigation by Chemiluminescent Method Visceral Fat by (AB-140) Ambulatory BP Monitoring CGMS & Insulin Pump Available PFT, 2D-ECHO (Color Doppler), Holter, TMT, Cardiac-3 available VIA, VILI, Colposcopy available Special Endocrinological Investigation Protocols.

ISO 9001:2008 Certified  
Mobile: 9389994334, 9554572190, 9453837595



**Panacea Pathology**  
**Clinical Reference Lab**  
Persistence, Preparedness and Precision  
EQAS (CMC Vellore Attached) & IQAS System  
पूर्वांचल की सर्वोत्तम गुणवत्ता वाली पैथोलॉजी

PATIENT NAME : RAKESH MEHTA

AGE/GENDER : 50 YRS/MALE

REFD BY DR. : ARCO FEMI HEALTHCARE LTD.

RECEIVED DATE : 28-11-2022 (10:15 AM)

SAMPLE : BLOOD & URINE

REPORT DATE : 28-11-2022 (18:15 PM)

## PATHOLOGY REPORT

### COMPLETE BLOOD COUNT (CBC)

TEST	LAB TEST VALUES	NORMAL RANGE
<b>HEMOGRAM</b>		
HEMOGLOBIN (FLOW CYTOMETRY)	16.3	13 – 16 gm/dl
TOTAL LEUCOCYTE COUNT (TLC)	7800	4000 – 11000
RBC COUNT	4.97	3.5 – 5.5
PCV (HCT)	49.4	37 – 47
MCV	99.4	80 – 95
MCH	32.8	28 – 34
MCHC	33.1	30 – 36
PLATELET COUNT	1,73,000	1,50,000 – 4,00,000
E.S.R. (WINTROBE FIRST HOURS)	8.0	20 mm/1 <sup>st</sup> hr
<b>DIFFERENTIAL LEUCOCYTE</b>		
NEUTROPHILS	50	40 – 75%
LYMPHOCYTES	36	20 – 45%
EOSINOPHILS	08	1 – 6%
MONOCYTES	06	2 – 8%
BASOPHILS	00	< 2%

### RENAL & KIDNEY PROFILE, SERUM

TEST	LAB TEST VALUES	NORMAL RANGE
<b>RENAL FUNCTION TESTS</b>		
BLOOD UREA NITROGEN (BUN)	11.0	10 – 50 mg/dl
SERUM CREATININE	0.85	0.60 – 1.60 mg/dl
URIC ACID	4.5	3.60 – 7.70 mg/dl
ALKALINE PHOSPHATASE (ALP)	102.00	142 – 353 mg/dl
TOTAL PROTIENS	7.50	0 – 39 mg/dl
ALBUMIN	4.21	3.8 – 5.4 mg/dl
SERUM GLOBULIN	3.29	2.1 – 3.5 mg/dl
CALCIUM	10.0	8.80 – 10.20
PHOSPHORUS	3.42	2.50 – 5.00
SERUM SODIUM NA+	140.8	135.00 – 155.00 mEq/Ltr
SERUM POTASIUUM K+	4.08	3.60 – 5.50 mEq/Ltr
ICALCIUM	1.25	1.10 – 1.35 mmol/L
SERUM CHLORIDE CL+	104.3	98.00 – 110.00 mEq/Ltr

PAGE 1

Lab Technician

**PANACEA HOSPITAL**  
A UNIT OF AAROH HEALTH CARE PVT. L.  
R.M.D. Pathology  
B-36/44 B-4 KABIR NAGAR  
DURGAKUND, VARANASI

Timing : 8.00 a.m. to 9.00 p.m. (Sunday 8.00 a.m. to 3.00 p.m.)

This Report is not valid for medico legal purpose

**Note:** These tests have technical limitations. Clinico-pathological interpretation is necessary. In case of any disparity test may be repeated immediately.

**Address :** 36/44 FK Kabir Nagar, Durgakund, Varanasi – 221005

**Email :** [dramishra@gmail.com](mailto:dramishra@gmail.com), [drpallaviojha@gmail.com](mailto:drpallaviojha@gmail.com) **Website:** [panaceahospital.org](http://panaceahospital.org)

**Facilities:**

All clinical Biomedical & Hematology Investigations including Bone Marrow Examination  
VPT, Podiascan & Complete Foot Care (First Time in Purvanchal)  
All Hormonal Investigation by Chemiluminescent Method  
Visceral Fat by (AB-140) Ambulatory BP Monitoring  
CGMS & Insulin Pump Available  
PFT, 2D-ECHO (Color Doppler), Holter, TMT, Cardiac-3 available  
VIA, VILI, Colposcopy available  
Special Endocrinological Investigation Protocols.

ISO 9001:2008 Certified  
Mobile: 9389994334, 9554572190, 9453837595



# Panacea Pathology

## Clinical Reference Lab

Persistence, Preparedness and Precision  
EQAS (CMC Vellore Attached) & IQAS System  
पूर्वाचल की सर्वोत्तम गुणवत्ता वाली पैथोलॉजी

PATIENT NAME : RAKESH MEHTA	AGE/GENDER : 50 YRS/MALE
REFD BY DR. : ARCO FEMI HEALTHCARE LTD.	RECEIVED DATE : 28-11-2022 (10:15 AM)
SAMPLE : BLOOD & URINE	REPORT DATE : 28-11-2022 (18:15 PM)

### PATHOLOGY REPORT

#### LIPID PROFILE, SERUM

TEST	LAB TEST VALUES	NORMAL RANGE
<b>BLOOD CHEMISTRY</b>		
TOTAL CHOLESTEROL (SERUM)	173.0	Desirable:- < 200 mg/dl Borderline:- 200 – 239 mg/dl High:- > 240 mg/dl
TRIGLYCERIDES (SERUM)	148.0	35 – 170 mg/dl
HDL CHOLESTEROL (SERUM)	42.0	35.30 – 79.50 mg/dl
LDL CHOLESTEROL (SERUM)	101.4	< 130 mg/dl
VLDL	29.6	< 40 mg/dl
NON HDL	70.6	0.00 – 100.00 mg/dl
CHOLESTROL/HDL RATIO	4.11	< 3.0 Low Risk Ratio 3.0 – 5.0 Avg Risk > 5.0 High Risk
LDL/HDL RATIO	2.40	< 3 Ratio

#### GLYCOSYLATED HEMOGLOBIN (HBA1C)

TEST	LAB TEST VALUES	NORMAL RANGE
HBA1C	6.9	Normal : <5.97 % Good Control : 5.97 – 6.81% Fair Control : 6.81 – 7.65% Poor Control : >7.65%

#### THYROID PROFILE (T3, T4, TSH)

TEST	LAB TEST VALUES	NORMAL RANGE
<b>THYROID FUNCTION TEST</b>		
T3	1.02	0.60 – 1.81 ng/ml
T4	7.46	4.50 – 10.90 ug/dl
TSH	1.61	0.39 – 6.10 uIU/mL

PAGE 2

Lab Technician

Timing : 8.00 a.m. to 9.00 p.m. (Sunday 8.00 a.m. to 3.00 p.m.)

This Report is not valid for medico-legal purpose

PANACEA HOSPITAL

A UNIT OF ARCO FEMI HEALTHCARE PVT. L.  
M.D., Pathology  
REG. NO.: AL-1500

B-36/44 B-4, KABIR NAGAR  
DURGAKUND, VARANASI

**Note:** These tests have technical limitations. Clinico-pathological interpretation is necessary. In case of any disparity test may be repeated immediately.

Address : 36/44 FK Kabir Nagar, Durgakund, Varanasi – 221005

Email: [dramishra@gmail.com](mailto:dramishra@gmail.com), [drpallaviojha@gmail.com](mailto:drpallaviojha@gmail.com) Website: [panaceahospital.org](http://panaceahospital.org)

**Facilities:**

All clinical Biomedical & Hematology Investigations  
 including Bone Marrow Examination  
 VPT, Podiascan & Complete Foot Care (First Time in Purvanchal)  
 All Hormonal Investigation by Chemiluminescent Method  
 Visceral Fat by (AB-140) Ambulatory BP Monitoring  
 CGMS & Insulin Pump Available  
 PFT, 2D-ECHO (Color Doppler), Holter, TMT, Cardiac-3 available  
 VIA, VILI, Colposcopy available  
 Special Endocrinological Investigation Protocols.

ISO 9001:2008 Certified  
 Mobile: 9389994334, 9554572190, 9453837595



**Panacea Pathology**  
**Clinical Reference Lab**  
 Persistence, Preparedness and Precision  
 EQAS (CMC Vellore Attached) & IQAS System  
 पूर्वांचल की सर्वोत्तम गुणवत्ता वाली पैथोलॉजी

PATIENT NAME : RAKESH MEHTA	AGE/GENDER : 50 YRS/MALE
REFD BY DR. : ARCO FEMI HEALTHCARE LTD.	RECEIVED DATE : 28-11-2022 (10:15 AM)
SAMPLE : BLOOD & URINE	REPORT DATE : 28-11-2022 (18:15 PM)

### PATHOLOGY REPORT

#### LIVER PROFILE TEST, SERUM

TEST	LAB TEST VALUES	NORMAL RANGE
<b>BIO CHEMISTRY</b>		
TOTAL BILIRUBIN	0.68	0.0 – 1.1 mg/dl
DIRECT BILIRUBIN	0.22	0.0 – 0.2 mg/dl
INDIRECT BILIRUBIN	0.46	< 0.90 mg/dl
SGOT (AST)	19.0	0 – 52 mg/dl
SGPT (ALT)	21.6	0 – 39 mg/dl
GGT (GYT)	25.0	< 55 U/L
AG RATIO	1.96	-

#### URINE ROUTINE EXAMINATION

TEST	LAB TEST VALUES	NORMAL RANGE
<b>PHYSICAL EXAMINATION</b>		
QUANTITY	30	ML
COLOUR	STRAW	PALE YELLOW
APPEARANCE	CLEAR	CLEAR
SPECIFIC GRAVITY	1.030	1.01 – 1.03
PH	6.0	4.7 – 7.5
<b>CHEMICAL EXAMINATION</b>		
GLUCOSE	Not Detected	Not Detected
PROTEIN	NIL	Not Detected
<b>MICROSCOPIC EXAMINATION</b>		
PUS CELLS	3-4	0-5
RBC	Not Detected	Not Detected
EPITHELIAL CELLS	1-2	0-5
CASTS	Not Detected	Not Detected
CRYSTALS	Not Detected	Not Detected
BACTERIA	Not Detected	Not Detected

#### BLOOD GROUP

TEST	LAB TEST VALUES
BLOOD GROUPING	
SAMPLE WHOLE BLOOD EDTA	"B" POSITIVE

PAGE 3

Lab Technician

**PANACEA HOSPITAL**

A UNIT OF AARCHA HEALTH CARE PVT. L.

M.D. Pathology

B-36/44, B-4, KABIR NAGAR

DURGAKUND, VARANASI

Timing : 8.00 a.m. to 9.00 p.m. (Sunday 8.00 a.m. to 3.00 p.m.)

This Report is not valid for medico-legal purpose

**Note:** These tests have technical limitations. Clinico-pathological interpretation is necessary. In case of any disparity test may be repeated immediately.

Address : 36/44 FK Kabir Nagar, Durgakund, Varanasi – 221005

Email: [dramishra@gmail.com](mailto:dramishra@gmail.com), [drpallaviojha@gmail.com](mailto:drpallaviojha@gmail.com) Website: [panaceahospital.org](http://panaceahospital.org)

**Facilities:**

All clinical Biomedical & Hematology Investigations including Bone Marrow Examination  
 VPT, Podiascan & Complete Foot Care (First Time in Purvanchal)  
 All Hormonal Investigation by Chemiluminescent Method  
 Visceral Fat by (AB-140) Ambulatory BP Monitoring  
 CGMS & Insulin Pump Available  
 PFT, 2D-ECHO (Color Doppler), Holter, TMT, Cardiac-3 available  
 VIA, VILI, Colposcopy available  
 Special Endocrinological Investigation Protocols.

ISO 9001:2008 Certified  
 Mobile: 9389994334, 9554572190, 9453837595



# Panacea Pathology

## Clinical Reference Lab

Persistence, Preparedness and Precision  
 EQAS (CMC Vellore Attached) & IQAS System  
 पूर्वांचल की सर्वोत्तम गुणवत्ता वाली पैथोलॉजी

PATIENT NAME : RAKESH MEHTA	AGE/GENDER : 50 YRS/MALE
REFD BY DR. : ARCO FEMI HEALTHCARE LTD.	RECEIVED DATE : 28-11-2022 (10:15 AM)
SAMPLE : BLOOD & URINE	REPORT DATE : 28-11-2022 (18:15 PM)

### FASTING/RANDOM BLOOD SUGER

TEST	LAB TEST VALUES	NORMAL RANGE
FBS/RBS		
FASTING BLOOD SUGER	136.7	110-125 mg/dl
RANDOM BLOOD SUGER	162.0	125-140 mg/dl

----- End of Report -----

Lab Technician

PANACEA HOSPITAL

A UNIT OF AAROH HEALTH CARE PVT. L

REG. NO: AL 1500

M.D. Pathology

B.36/44, B-4, KABIR NAGAR

DURGAKUND, VARANASI

Timing : 8.00 a.m. to 9.00 p.m. (Sunday 8.00 a.m. to 3.00 p.m.)

This Report is not valid for medico legal purpose

**Note:** These tests have technical limitations. Clinico-pathological interpretation is necessary. In case of any disparity test may be repeated immediately.

Address : 36/44 FK Kabir Nagar, Durgakund, Varanasi – 221005

Email: [dramishra@gmail.com](mailto:dramishra@gmail.com), [drpallaviojha@gmail.com](mailto:drpallaviojha@gmail.com) Website: [panaceahospital.org](http://panaceahospital.org)



PERN

# PANACEA HOSPITAL

B 36/44 F.K KABIR NAGAR, DURGAKUND  
TOLLFREE NO-18001233070.  
Whatsapp No - 8795832852  
www.piire.org



## OP Slip

Print Date : 28-Nov-2022 02:36PM



UHID No :- UD-22230002714      OP No :- OP-22230010287      OP Date :- 28 Nov 2022 2:36PM

Patient Name :- Mr RAKESH MEHTA      Age/Sex :- 51 Y/Male      Mobile No :- 9792446555

Father :- LET J L MEHTA      Department :- DIABETES, ENDOCRINOLOGY & METABOLIC PHYSICIAN

Pay Type :- Cash      Consultant :- Dr ASHUTOSH MISHRA (MD(MEDICINE), IMS, BHU)

Token No :- NOR. - 31      Paid/Bal :- 0.00 / 500.00

Patient Type :- Normal

Address :- CHAUK, varanasi

BP 140/90

height :- 167

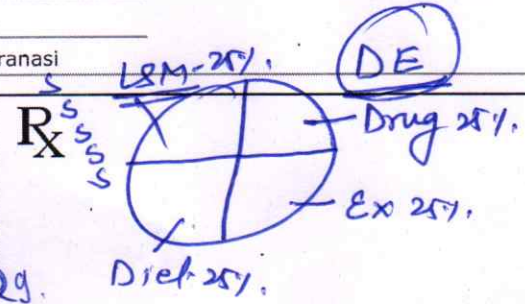
Weight (kg) :- 83.4

BMI :-  $BMI = 29$

• SpO<sub>2</sub> - 96

PR - 104

RBS - 140



FD DM  
HTH

Rx. Tab. Diabemes - M (500/10) OD (6week)

Tab. Vildagliptin (500/50)

Tab. Drogler (15) OD

Tab. Berpophos OD

(500+2) OD  
Telus-3D

Telus 3D  
4-15 (11.5)

ME  
WA  
CKD

Dr. Pallavi

R/A 2 month

C/O Rx Diabetes

① F=100+30 PP=140+80



AMM (SMBC) NBAC =

Printed By : Mr NITIN YADAV

Created By : Mr NITIN YADAV

Tab. Renny 20mg

Tab. Cilnidipine 10mg

Tab. ~~Buckley~~ OD 800mg

Tab. Losartan (50mg)

Rotabete Arifus 25mg OD

Tab

② BP = 130/80



Call Now - 1800-123-3070

# PANACEA HOSPITAL

*A shelter for many hearts A Home for many lives*

(An ISO 9001:2008 Certified Organisation)

Lab Attached with CMC Vellore Under EQAS Scheme

Name	MR.RAKESH MEHTA	Sex /Age	51Y/M	Date	28/11/2022
Ref. by	DR.PALLAVI MISHRA(MD)	BSA - m <sup>2</sup>		Echo window	fair

## Echo - Cardiography

MITRAL VALVE Doppler	AML - normal morphology MV Flow - E - 0.6 A-0.6 E/A=0.81	PML - normal morphology MVA - 3.0 cm <sup>2</sup> Mitral Regurgitation - <b>Trivial MR</b>
TRICUSPID VALVE Doppler	Normal TV Flow -No	Tricuspid Regurgitation - <b>No</b>
PULMONARY VALVE Doppler	Normal PV Flow -No	Pulmonary Regurgitation - <b>No</b>
AORTIC VALVE Doppler	Trileaflet-No AV Flow - no	Aortic Regurgitation - <b>No</b>
MEASUREMENT	Aorta - 32.0 (20-38) mm IVS ed - 9.7 (6 -12) mm LVID ed - 31.4 (35 - 55) mm LVPW ed - 17.7 (6 -12) mm OA - 7 (> 5) mm	LA -25.7 (24-32) mm IVS es -14.8 (6 - 12) mm LVID es - 21.1 (24 - 40) mm LVPW es - 18.8 (6 -12) mm EPSS - 06 (< 9) mm

### CONCLUSION

All cardiac chamber dimension are WNL

**Trivial MR is present, rest other valve are WNL**

Good LV systolic function present Modified Simpson's method (4C, 2C) (LVEF-63%)

**Grade I diastolic dysfunction present (E/A = 0.91) by tissue Doppler (E/e'=7.6)**

No RWMA

No pericardial effusion

Intact IAS / IV

No PAH

No intra cardiac mass /thrombus /vegetation

### IMPRESSION

All cardiac chamber dimension are WNL


**Trivial MR is present, rest other valve are WNL**

Good LV systolic function present Modified Simpson's method (4C, 2C) (LVEF-63%)

**Grade I diastolic dysfunction present (E/A = 0.91) by tissue Doppler (E/e'=7.6)**

Rest all other finding are WNL

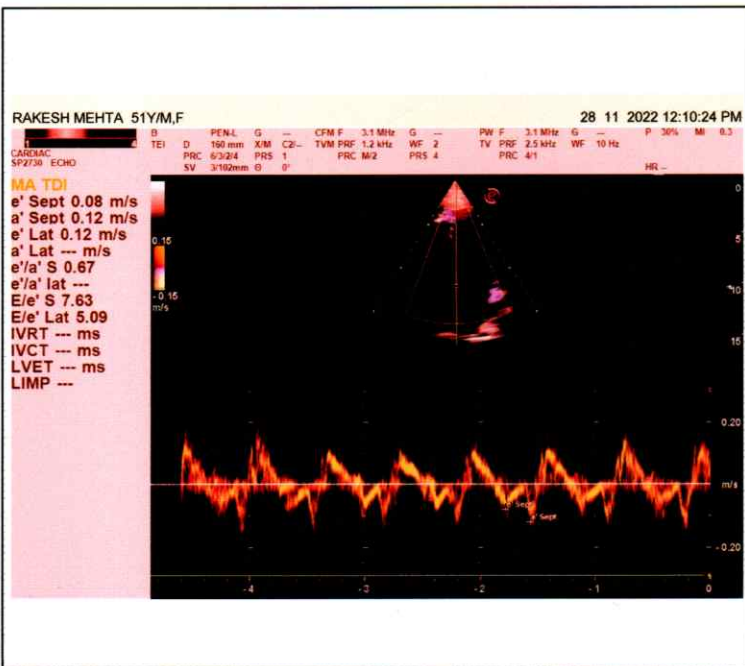
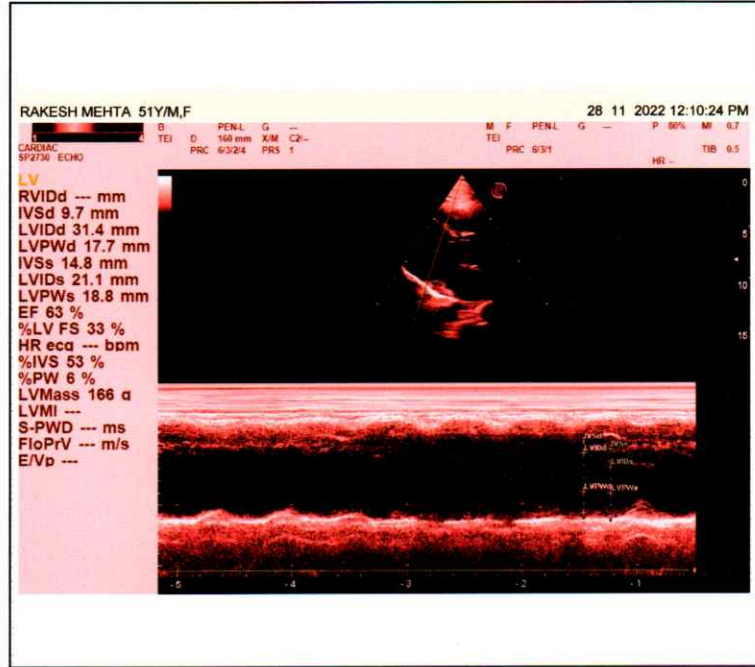
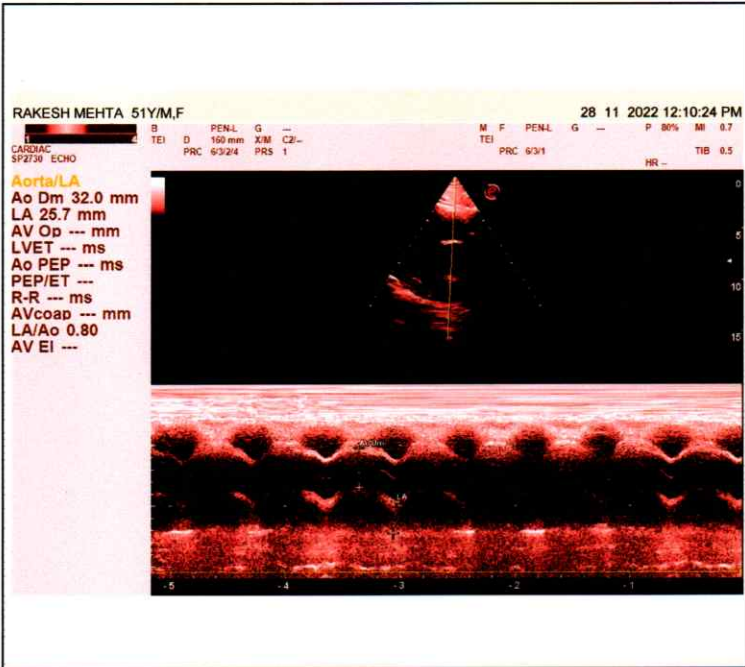
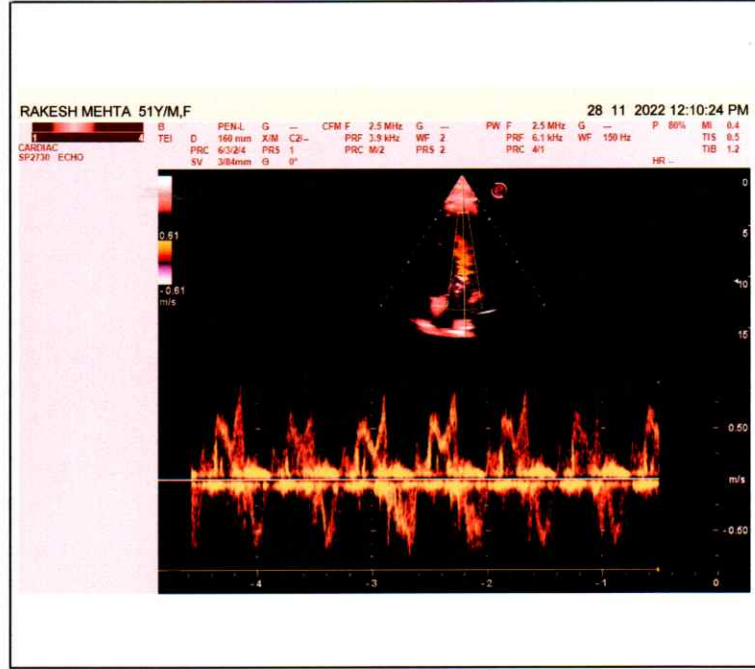
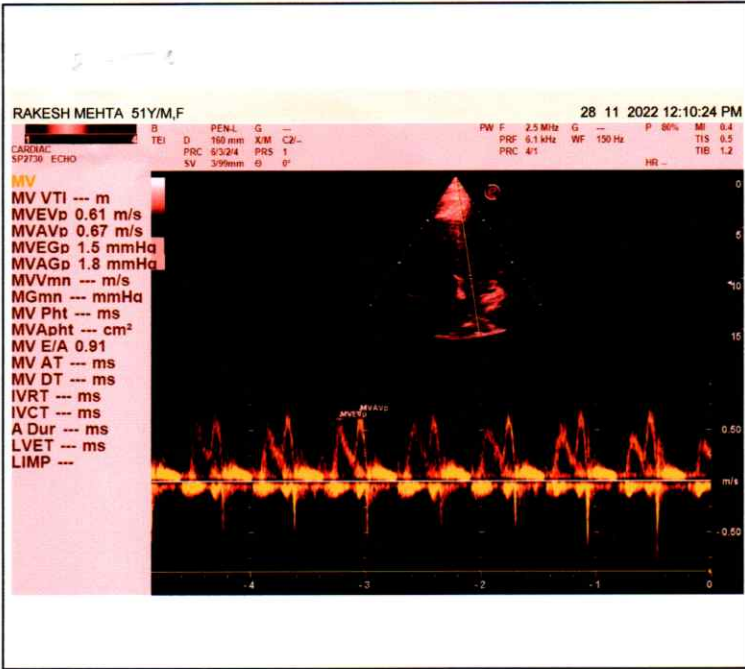
  
Nira Mishra  
Physician Assistant  
(PIRE)

  
Dr. Pallavi Mishra  
MBBS, MD (MED) Lucknow  
Echocardiography Specialist, MIAE  
Non-invasive cardiologist  
Women Cardiologist  
Diabetocardiologist

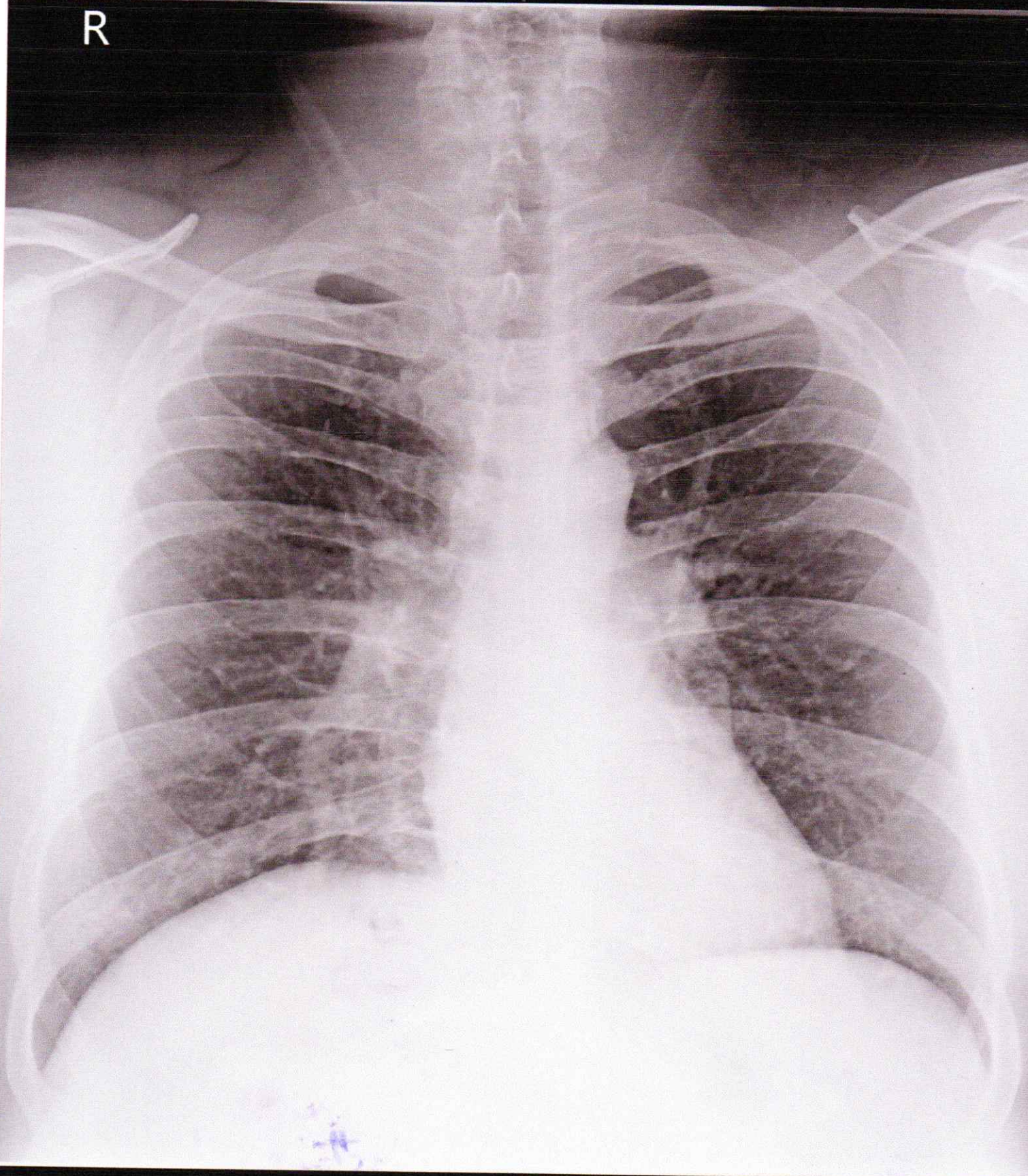
Address : Kabir Nagar (Near Sanjay Shiksha Niketan), Durgakund, Varanasi

Mobile : 9554572190 / 9453837595 / Recpn. 9389994334

E-mail : dramishra@gmail.com, drpallaviojha@gmail.com, Website: www.piire.org



R



RAKESH MEHTA 51Y/M 4786 O CHEST P.A. 28-Nov-22 01:45 PM

PANACEA HOSPITAL, KABIR NAGAR, DURGAKUND, VARANASI





# PANACEA HOSPITAL

*A shelter for many hearts A Home for many lives*

(An ISO 9001:2008 Certified Organisation)

Lab Attached with CMC Vellore Under EQAS Scheme

**NAME:** MR.RAKESH MEHTA

**AGE/SEX:** 51 YRS / MALE

**REF BY:** DR. ASHUTOSH MISHRA (MD)

**DATE:** 28/11/2022

## ULTRA SOUND WHOLE ABDOMEN REPORT

**Liver:** *Normal in shape and size (13.1cm) and shows mildly increased echogenicity.*  
Margins are smooth and regular. No focal lesion seen.

**Gall bladder:** Partially distended with normal wall thickness and echo-free lumen.

**CBD diameter** Visualized part normal in course & caliber.

**Pancreas:** Normal in size, shape & echogenicity.  
Margins are smooth & regular.  
No diffuse/ focal lesion seen. Pancreatic tail obscured.

**Spleen:** Normal in size, shape & echogenicity.  
Margins are smooth & regular. No diffuse / focal lesion seen.  
Splenic vessels at hilum is normal.

**Kidney:** Right kidney: 10.3 X 5.0cm  
Left kidney: 9.0 X 4.8 cm  
Both normal in size, shape, echogenicity & position.  
Cortical-medullary differentiation is maintained.  
Pelvicalyceal system normal.  
No calculus/mass lesion seen.  
No hydronephrosis/ hydroureter seen.  
No suprarenal mass lesion.



# PANACEA HOSPITAL

*A shelter for many hearts A Home for many lives*

(An ISO 9001:2008 Certified Organisation)

Lab Attached with CMC Vellore Under EQAS Scheme

**Urinary bladder:** Normally distended, wall thickness is normal.  
No echogenic foci lumen or diverticula seen.  
Both VUJ appears normal.  
No E.R. calculus / mass lesion seen.

**Prostate:** Normal in size, shape, & echogenicity.  
No calcification or focal cystic lesion seen.  
Capsular margins are smooth and regular.  
Seminal vesicles appear normal in size, shape & echogenicity.  
No diffuse /focal lesion seen.

**Others:** No free fluid in peritoneal cavity.  
No free fluid in bilateral pleural cavity.

**IMPRESSION:**

❖ *Grade I fatty liver*

-----  
Please correlate clinically and further investigations.

**DR. PALLAVI MISHRA**  
MBBS MD(MED) Lucknow  
Echocardiography specialist, MIAE  
Non invasive cardiologist  
Women cardiologist

  
**Radiologist**

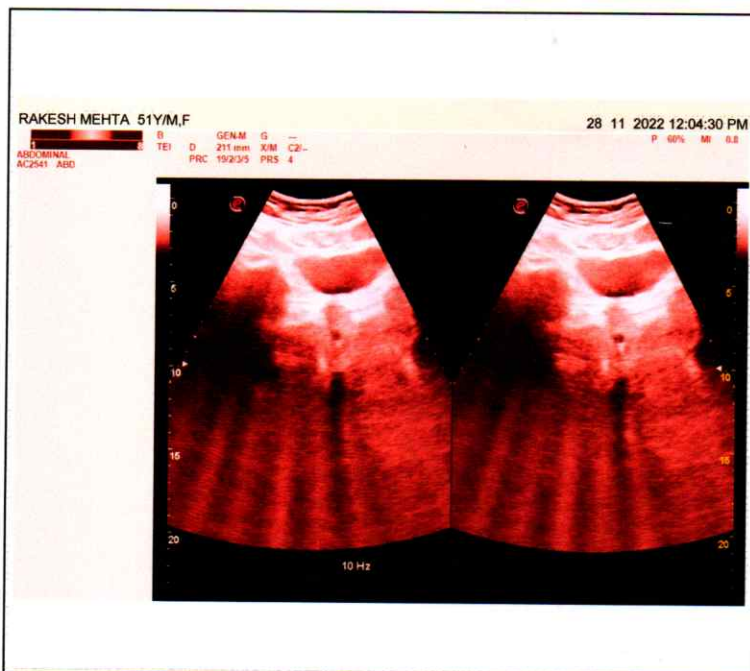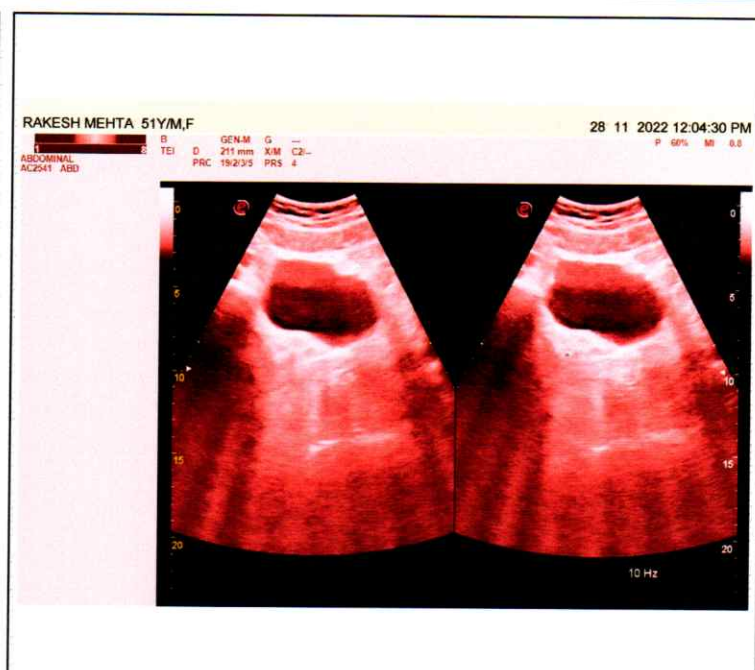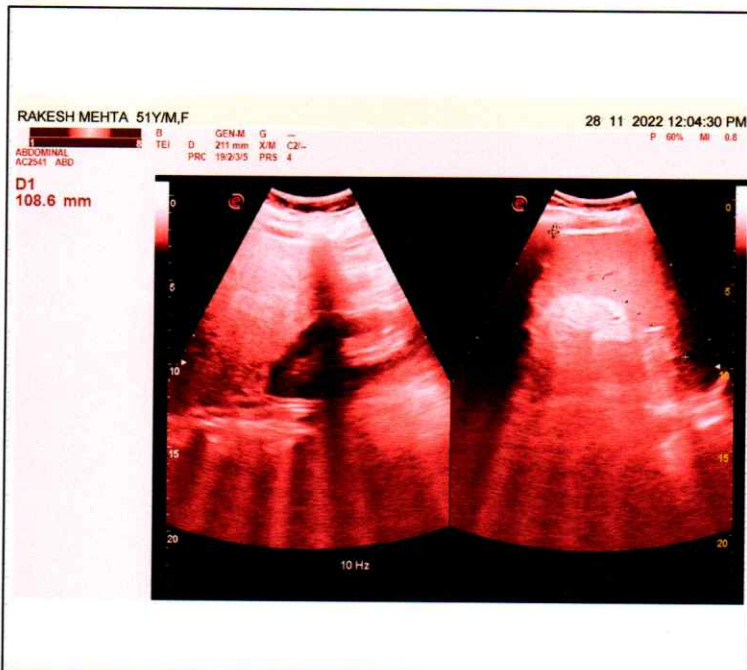
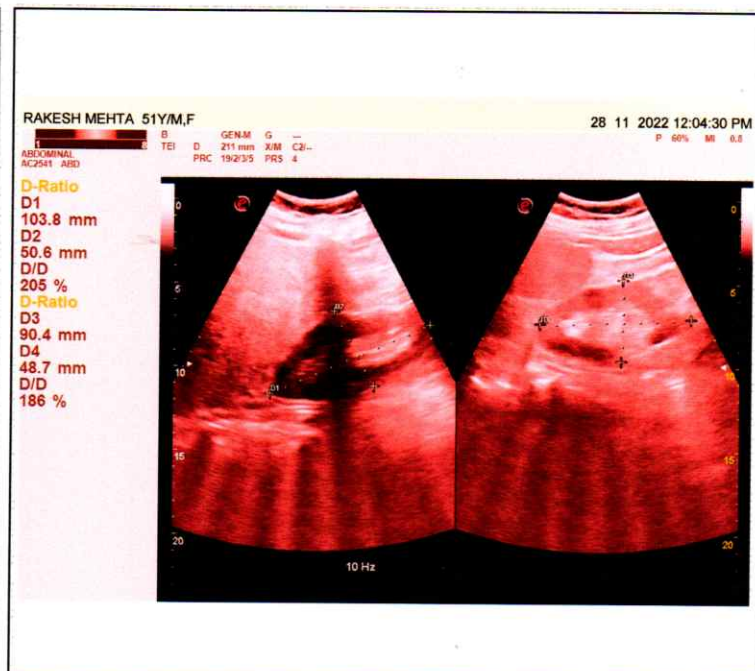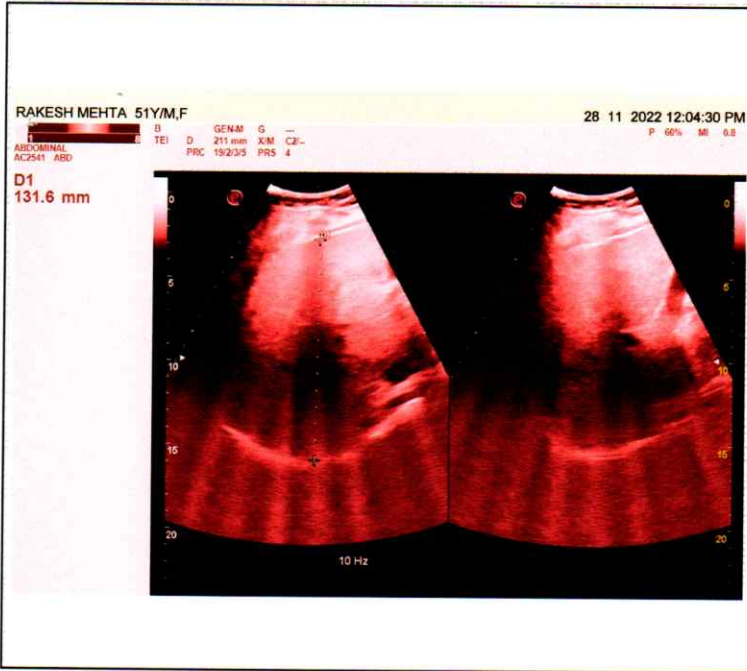**Dr. Tusharika Rai**  
MBBS MS

  
**NIRAJ MISHRA**  
(Physician Assistant)  
(PIIRE)

**Address : Kabir Nagar (Near Sanjay Shiksha Niketan), Durgakund, Varanasi**

**Mobile : 9554572190 / 9453837595 / Recpn. 9389994334**

**E-mail : dramishra@gmail.com, drpallaviojha@gmail.com, Website: www.piire.org**





# PANACEA HOSPITAL

*A shelter for many hearts A Home for many lives*

(An ISO 9001:2008 Certified Organisation)  
Lab Attached with CMC Vellore Under EQAS Scheme

**AME:** MR. RAKESH MEHTA

**AGE/SEX:** 51 YRS / MALE

**EF BY:** DR.ASHUTOSH MISHRA(MD)

**DATE:** 28/11/2022

## X-RAY CHEST PA

### BOTH LUNG FIELDS AND PLEURAE:

Both lungs show normal bronchovascular pattern.

Right & left hila are normal

No focal mass or calcification is seen

There is no evidence of any fluid in the both the pleural cavities.

Both domes of diaphragms are normal in position.

### MEDIASTINUM:

Trachea is central in position.

Cardiac silhouette is of normal size and configuration.

No evidence of pericardial effusion.

No significant lymphadenopathy is seen.

Visualized skeleton is normal.

-----  
NO SIGNIFICANT RADIOGRAPHIC ABNORMALITY.

**REPORTED BY**  
**DR. ALPANA PATHAK**  
**MBBS (HONS, GOLD MEDALIST) PMCH, PATNA**  
**MD RADIODIAGNOSIS (GOLD MEDALIST) IMS BHU**  
**EX-SR, IMS BHU, VARANASI**

**Address :** Kabir Nagar (Near Sanjay Shiksha Niketan), Durgakund, Varanasi

**Mobile :** 9554572190 / 9453837595 / Recpn. 9389994334

**E-mail :** dramishra@gmail.com, drpallaviojha@gmail.com, **Website:** www.piire.org