

ଭାରତ ସରକାର
Government of India


କୌଷ୍ଠ ଦାସ
Kaustubh Das
ଜନ୍ମ ତାରିଖ/DOB 15.07.1992
ଲିଙ୍ଗ/ GENDER MALE



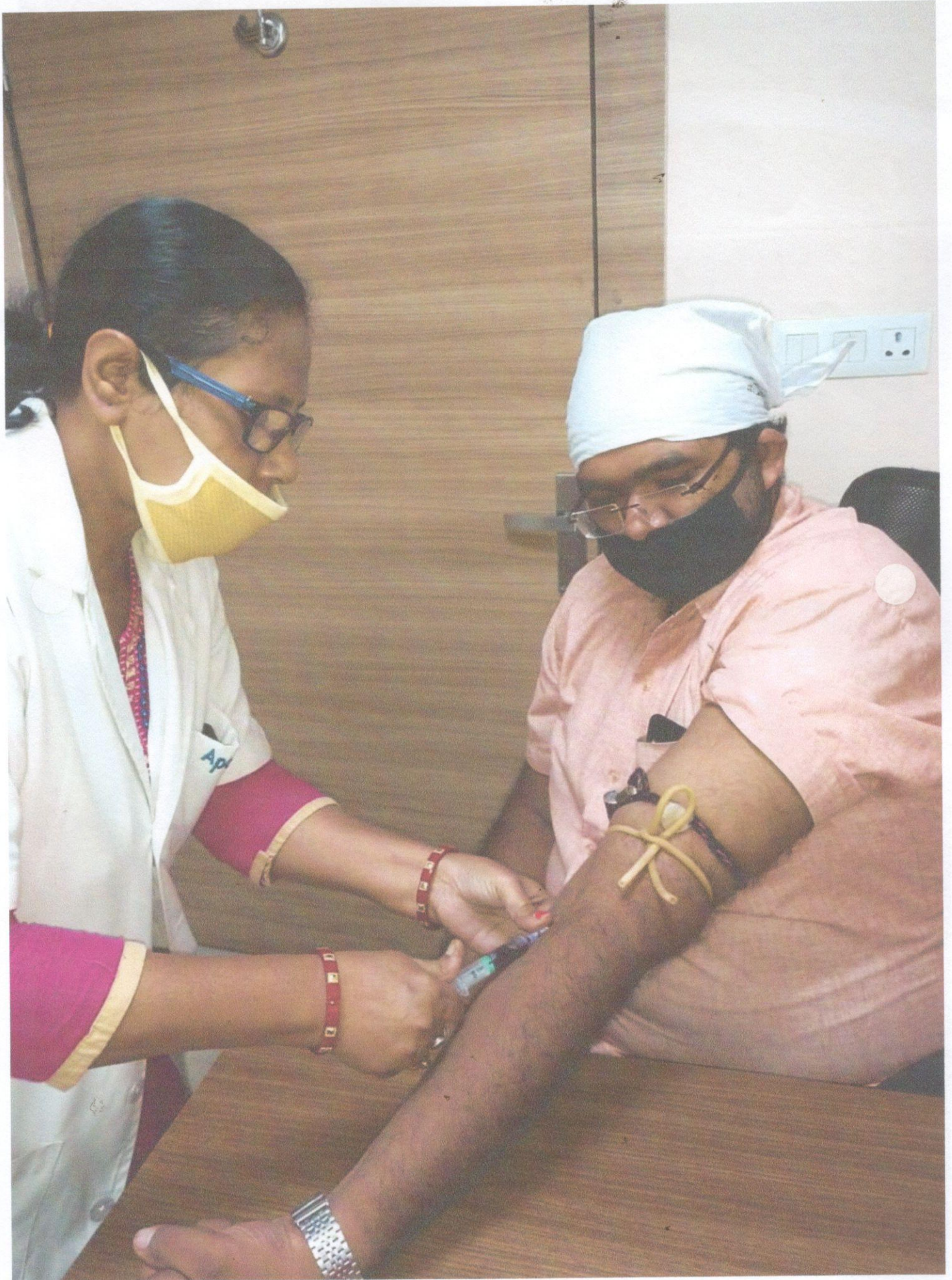2726 8202 6320

ଭାରତୀୟ ସ୍ୱାଧୀନତା, ଭାରତୀୟ ଅଭିମତ

Kaustubh Das









2021/6/25 14:09

MR. NO- FSIN.0000000

SEX-MALE

NAME: -MR.KAUSTUBH DAS

EXAMINATION DATE- 25.06.2021


AGE- 28 YRS

REPORT DATE- 25.06.2021

REF DR. SELF

FINDINGS:

- Bilateral lung fields are clear.
- Tracheal shadow is in the midline.
- Bilateral CP angle are clear
- Both hilum appear normal .
- CTR appears normal .
- No definite bone fracture is noted.




DR.ARNAB MANDAL

MD, Physician, PGDUS (Delhi) CEFT-USG (WBUHS KOLKATA)
Fellow of Jefferson Ultrasound Radiology and Education Institute
Philadelphia Ex-Radiology Resident (S.E.Railway)
Regd.No:72022(WBMC)

APOLLO CLINIC @ OM TOWER
Opp. of Rabindra Bharati University
Licensee : Satyam Credit Pvt. Ltd.

36C, B.T. Road, Kolkata - 700 002

E-mail : sinthimor@theapolloclinic.com
satyamcreditpvtltd@gmail.com

 033 2556 3333

 033 2556 5555

 +91 98521 66666

 +91 74392 97827

| | | |
|------------------------------|------------------------|-------------------------|
| NAME: MR.KAUSTUBH DAS | AGE:28YRS | SEX:MALE |
| REF BY: CORPORATE | MR NO:FSIN-0000 | DATE: 25.06.2021 |

ULTRASOUND OF WHOLE ABDOMEN

LIVER: Liver is **Enlarged Moderate fatty changes seen**. The intrahepatic tubular structures are normal. No focal area of altered echogenicity is noted. The porta hepatis is normal. The common bile duct at porta measures **0.45cm**. The portal vein measures **1.06cm** at porta.

GALL BLADDER: : Gall bladder is distended. Wall is normal limits. No calculus or mass is seen within the gall bladder.

PANCREAS: It is normal in size, Shape, Outline and echotexture. Pancreatic duct is not dilated.

SPLEEN: Spleen in normal size **10.74cm**, Shape, Outline and echotexture. No parenchymal lesion is noted.

RIGHT KIDNEY: kidneys are normal in position, size, shape, outline and echotexture. The cortico medullary differentiation is maintained. No calculus or hydronephrosis is seen.

RIGHT KIDNEY: measures – **9.16cm**.

LEFT KIDNEY: kidneys are normal in position, size, shape, outline and echotexture. The cortico medullary differentiation is maintained. No calculus or hydronephrosis is seen.


LEFT KIDNEY: measures – **9.96cm**.

URINARY BLADDER: : It is well distended with normal wall thickness. No calculus or mass is seen within the urinary bladder. The post void residual volume of urine is insignificant.

PROSTATE: It is normal in size, Shape & homogenous echotexture. The prostatic outline is smooth. The periprostatic plane is normal. It is normal size measures (**2.48cmX3.81cmX3.49cm**) Vol-17.26ml.

IMPRESSION:

- **HEPATOMEGALY WITH MODERATE FATTY CHANGES.**


DR.SUSMITA CHOWDHURY
MBBS,MD.
CONSULTANT SONOLOGIST



Name: Mr. KAUSTUBH DAS 28/M

Resting ECG Report

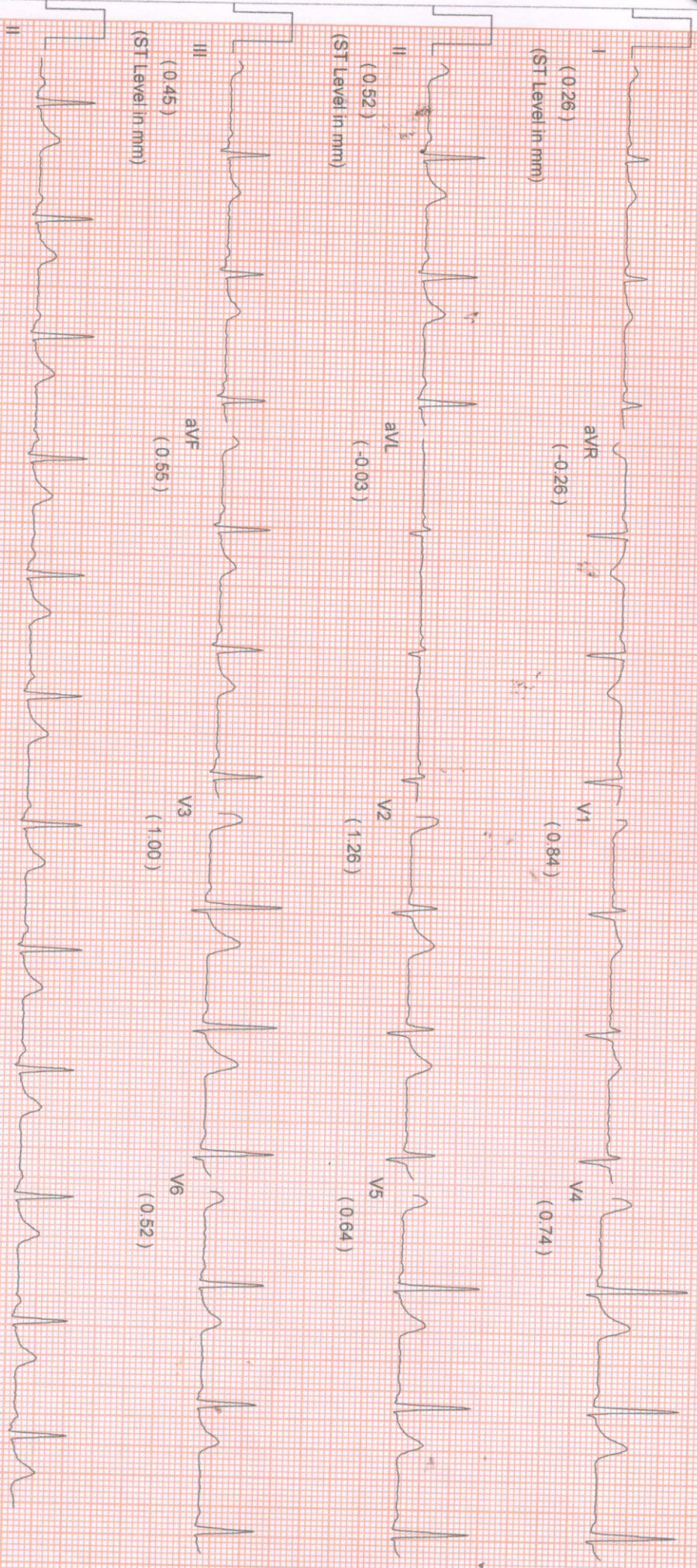
Date: 25. 2021
Time: 13:52:29

QT / QTc: 0.396 / 0.439 Sec
P-QRS-T Axis (58)-(66)-(68) deg

PR Interval: 0.15 sec
QRS Duration: 0.084 Sec

RR Interval: 0.81 sec

HR : 73 bpm
BP : 110 / 70 mmHg



Comments :-

Kaustubh Das

| | | |
|-----------------------|------------------|-------------------------|
| NAME:MR. KAUSTUBH DAS | MR NO: FSIN-0000 | DATE : 25.06.2021 |
| AGE: 30YRS. | SEX:MALE | REF BY:SELF (CORPORATE) |

ECG REPORT

HR : 73 b/min
AXIS : NORMAL
RHYTHM : SINUS
PR INTERVAL : 0.15 sec
QT INTERVAL : 0.439 sec
QRS DURATION : 0.084 sec
T-WAVE : NORMAL

IMPRESSION:

- RESTING ECG IS WITHIN NORMAL LIMITS.



Dr. SIDDHARTHA KUNDU

MBBS (Cal), PGDCC, CCEBDM
Clinical Cardiologist

Ex Sr Resident, Cardiology Dept
B.R Singh Hospital, Eastern Railway

APOLLO CLINIC @ OM TOWER
Opp. of Rabindra Bharati University

Licensee : Satyam Credit Pvt. Ltd.

36C, B.T. Road, Kolkata - 700 002

E-mail : sinthimor@theapolloclinic.com
satyamcreditpvtltd@gmail.com



033 2556 3333



033 2556 5555



+91 98521 66666



+91 74392 97827