

DAKSH HOSPITAL

396 - 397, Gandhi Nagar, Scheme No. 8, ALWAR -301001

Ref. No.

Date.....

MEDICAL EXAMINATION REPORT

Mediwheel (BOB)

Name: Mr Bhupender Saini

Age: 33 yrs Sex: Male

Date: 14/04/2023

General Physical Examination

Height	: 168 cm.	Weight	: 71.2 kg
Pulse	: 78/mt	BP	: 130/95 mm/hg
Temp.	: 96.6 °F	Respiration	: 98 %
BMI	: 25.2		

Systemic Exam:-

NORMAL

Dental Check up :-

NORMAL

Eye check-up :-

NORMAL

Skin Check up:-

NORMAL

ENT Check up:-

NORMAL

Gynae Check up:-

N/A

Impression:-X Ray chest - normal - old Head Calvarial shadow
and Fatty liverRecommendation:-

Clinical Correlation



Dr. Mukesh Kumar Gupta
MD Gen. Medicine c.s.
REG. NO. 5423/16262
दक्ष हॉस्पिटल, अलवर
रजि. नं. 5423/16262

Results

Run Date 14/04/2023 12:22:26 PM

Operator DAKSH

Last Name

Sample ID 24

First Name MR. BHUPENDAR

Department

Gender Male

Age

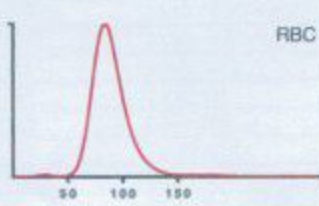
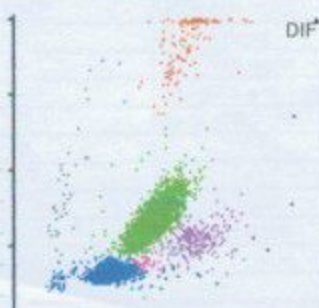
Physician DR. MUKESH GUPTA M.D

Patient ID AUTO_PID13057

Type Man

Date of birth

Sample comments

				Range		Susp. Pathologies
RBC	4.31	$10^9/\mu\text{L}$		3.80 - 5.50	 <p>RBC</p>	Macroplatelets
HGB	13.0	g/dL		13.0 - 17.0		
HCT	40.4	%		39.0 - 52.0		
MCV	93.9	μm^3		76.0 - 100.0		
MCH	30.2	pg		26.0 - 34.0		
MCHC	32.2	g/dL		32.0 - 35.0		
RDW-CV	16.4	%	h	11.0 - 16.0		
RDW-SD	57.3	μm^3	H	37.0 - 49.0		
PLT	218	* $10^9/\mu\text{L}$		150 - 450		
PCT	0.26	%		0.15 - 0.40		
MPV	12.1	μm^3	H	8.0 - 11.0		
PDW	22.4	μm^3	h	11.0 - 22.0		
P-LCC	102	$10^9/\mu\text{L}$		44 - 140		
P-LCR	46.8	%		18.0 - 50.0		
WBC	7.08	$10^9/\mu\text{L}$		3.50 - 10.00	 <p>DIF</p>	
	#	Range	%	Range		
NEU	3.98	1.60 - 7.00	56.3	40.0 - 75.0		
LYM	2.68	1.00 - 3.00	37.9	20.0 - 45.0		
MON	0.11	0.20 - 0.80	1.6	2.0 - 10.0		
EOS	0.23	0.00 - 0.50	3.3	1.0 - 6.0		
BAS	0.06	0.00 - 0.15	0.9	0.0 - 1.0		
LIC	0.02	0.00 - 0.10	0.2	0.0 - 1.0		

डॉ. मुकेश गुप्ता
M.D. F.C.C.S.
फिजिशियन एवं मधुमेह रोग विशेषज्ञ
दक्ष हॉस्पिटल, अलवर
रजि. नं. 5423/16262

14/04/2023 12:23:38 PM

Printed by : DAKSH

S/N107YOXH01 TECHNOLOGIST

All investigation have their own limitations regarding the sensitivity & specificity of individual assay procedures, Isolated laboratory investigations never confirm the final diagnosis of the disease. They only help in arriving at a diagnosis in conjunction with clinical presentation and other related investigations. Report is not valid for medico-legal purpose subject to ALWAR jurisdiction only.

Date :- 14/04/2023

Name :- MR. BHUPENDAR

Age & Sex :- -33 Yrs/ male

Refd. :- Dr Mukesh Gupta M.D.

	TEST NAME	RESULT	REFERENCE RANGE	
	ESR	12	00 -20 mm/hrs	
	Blood Group & Rh Factor	O " POSITIVE		
	HbA1C	4.7	4 - 5.6%	
	Blood Sugar (F)	84.3	< 70 - 100 mg/dl	
	Blood Sugar (PP)	111.7	< 140 mg/dl	
	Urine Sugar (F)	NIL	-	
	Urine Sugar (PP)	NIL	-	
LIVER	S.Bilirubin Total	1.10	0.30 - 1.20 mg/dl	
	S.Bilirubin Direct	0.40	0.10 - 0.30 mg/dl	
	S.Bilirubin Indirect	0.70	0.30 - 0.90 mg/dl	
	S.G.O.T.	75	> 37 u/l	
	S.G.P.T.	84	> 40 u/l	
	S.Alk. Phosp.	189	80 - 306 u/l	
	G.G.T.	18	5 -40 u/l	
	Total Protein	6.8	6.5 - 8.5 gm/dl	
	Albumin	3.7	3.8 - 5.4 gm/dl	
	Globulin	3.1	2.3 - 3.5 gm/dl	
	A/G Ratio	1.2	-	
	AST/ALT Ratio	0.9	-	
KIDNEY	Blood Urea	27.2	15 -45 mg/dl	
	S.Creatinine	0.76	0.60 - 1.30 mg/dl	
	BUN	16.0	6 -24 mg/dl	
	S.Uric Acid	5.2	M 3.1 - 7.0, F 2.5 - 5.6 mg/dl	
	BUN/Creatinine Ratio	21	-	
LIPID PROFILE	Total Cholesterol	170.1	Up to 200 mg/dl	
	S.HDL	45.1	30 - 70 mg/dl	
	S.LDL	93.1	Up to 170 mg/dl	
	S.VLDL	32.1	5.0 - 40 mg/dl	
	S. Triglycerides	160.1	Up to 170 mg/dl	
	LDL/HDL Ratio	2	-	
	Total Cholesterol/ HDL Ratio	3.7	-	
THYROID	T3	90.2	40 - 181 ng/dl	
	T4	10.1	4.6 - 10.5 µg/dl	
	TSH	2.9	0.30 - 5.0 mIU/L	
URINE EXAMINATION			Microscopic Examination :	
General/Chemical Examination:	Colour	Pale Yellow	RBC	Absent
	Reaction	Acidic	WBC	0 - 1
	Specific Gravity	QNS	Epithelial Cells	0 - 1
	Appearance	Clear	Cast	Absent
	Albumin	Nil	Crystal	Absent
	Sugar	Nil	Spermatozoa	Absent
			Amorphous Sediments	Absent
			Other	Absent
X-RAY CHEST	NORMAL STUDY			
STOOL EXAMINATION			Microscopic Examination :	
General/ Chemical Examination:	Colour	-	RBC	-
	Consistency	-	WBC	-
	PH	-	Ova & Parasites	-
	Reducing Substances	-		

Doctor

डॉ० मुकेश गुप्ता
M.D. F.C.C.S
डिप्लोमा इन मेडिकल एव
मधुमेह रोग विशेषज्ञ

TECHNOLOGIST

All investigation have their own limitations regarding the sensitivity & specificity of individual assay procedures, isolated laboratory investigations never confirm the final diagnosis of the disease. They only help in arriving at a diagnosis in conjunction with clinical presentation and other related investigations. Report is not valid for medico-legal purpose subject to ALWAR jurisdiction only.



दक्ष हॉस्पिटल

396, गाँधी नगर स्कीम नं.8, अलवर (राज०) ☎ 0144-2703340

Sonography / 2D Echo Cardiography / Doppler Report

2D/ ECHO REPORT

Name: - Mr Bhupendra

Age: - 33 Yrs

Date: - 14-Apr-23

Reg. No.:- Alw/2009/04
BOB health checkup

PROCEDURES:

M-MODE/2D/DOPPLER/COLOR/CONTRAST B.A.S. M²

MEASUREMENT:			DOPPLER:				
AOD	26	NORMAL (20- 37mm)	MV	0.5	NORMAL (cm/sec.) (0.8- 1.3)	MR	No
LA	22	(19- 40mm)	AV	1.4	(1.2- 1.8)	AR	No
AVO	16	(12- 25mm)	TV	0.6	(0.3- 0.8)	TR	No
RVDd.	13	(03- 09mm)	PV	0.8	(0.7- 1.1)	PR	No
LVDd	49	(37- 56mm)	MITRAL VALVE-				
LVDs	30	(22- 40mm)			AML	Normal	
IVS d	6	(06- 12mm)			PML	Normal	
IVS s	11		AORTIC VALVE				
PWd	5.8	(05- 10mm)				Normal	
LV FUNCTION			TV & PV are normal.				
M- E- S Separation		<0.9cm					
Minor		24.42%					
LV Ejection Fraction	68%	65 +/- 12%					

LV WALL MOTION: NO RWMA
ALL CARDIAC CHAMBERS ARE NORMAL
ALL VALVES ARE NORMAL
NO CLOT, VEGETATION, PERICARDIAL EFFUSION

FINAL DIAGNOSIS: NORMAL STUDY

Adv: - Follow up/ review at higher center for confirmation

Note:- Please Correlate clinically. Due to technical limitations as well as inaccuracies inherent in the laboratory and statistical analysis of biological process. Diagnostic accuracy of ECHO is up to 95% only.
Report is not valid for medico-legal purpose.


DR. MUKESH GUPTA
PHYSICIAN
Physician & Sonologist
RM 5423/16262



"भ्रूण लिंग परीक्षण की शिकायत
104 टोल फ्री सेवा पर भी की
सकती है"
भ्रूण लिंग परीक्षण की शिकायत 104 टोल फ्री सेवा पर भी की जा सकती है।



दक्ष हॉस्पिटल

396, गाँधी नगर स्कीम नं.8, अलवर (राज०) ☎ 0144-2703340

Sonography / 2D Echo Cardiography / Doppler Report

Name: MR. BHUPENDRA /M/33 YRS

Date: 14-Apr-23

BOB HEALTH CHECK UP

U.S.G. OF ABDOMEN & PELVIS

LIVER

Liver is **14.8 cm at vertically with mild increase echogenicty**. Intra hepatic biliary radicals are not-dilated. No evidence of focal or diffuse lesion.

GALL BLADDER

Gall bladder is normal dilated. Lumen clear. Wall thickness normal. CBD normal

PANCREAS

Pancreas is normal in size, shape & echo-texture.

SPLEEN

Normal in size with normal shape & echo- texture.

BOTH KIDNEY

Both kidneys are normal in size shape and echo- texture.

PROSTATE & URINARY BLADDER is normal shape, size & echo texture..

Fatty liver MILD

Advice- X Ray KUB / URINE EXAM

Please correlate clinically. USG accuracy is 95 % due to technical limitations as well as inaccuracies inherent in the laboratory and statistical analysis biological process.

This report is not valid for medico-legal cases.

DR. MUKESH GUPTA
SONOLOGIST

Dr. Mukesh Kumar Gupta
Physician & Sonologist
RM 5423/16262



"भ्रूण लिंग परीक्षण की शिकायत
104 टोल फ्री सेवा पर भी की
जा सकती है"

भ्रूण लिंग परीक्षण की शिकायत 104 टोल फ्री सेवा पर भी की जा सकती है।

ID: 612

14-04-2023 16:06:48

male Years

Req. No. :

HR : 73 bpm

P : 94 ms

PR : 124 ms

QRS : 98 ms

QT/QTcBz : 356/393 ms

P/QRS/T : 66/74/39 °

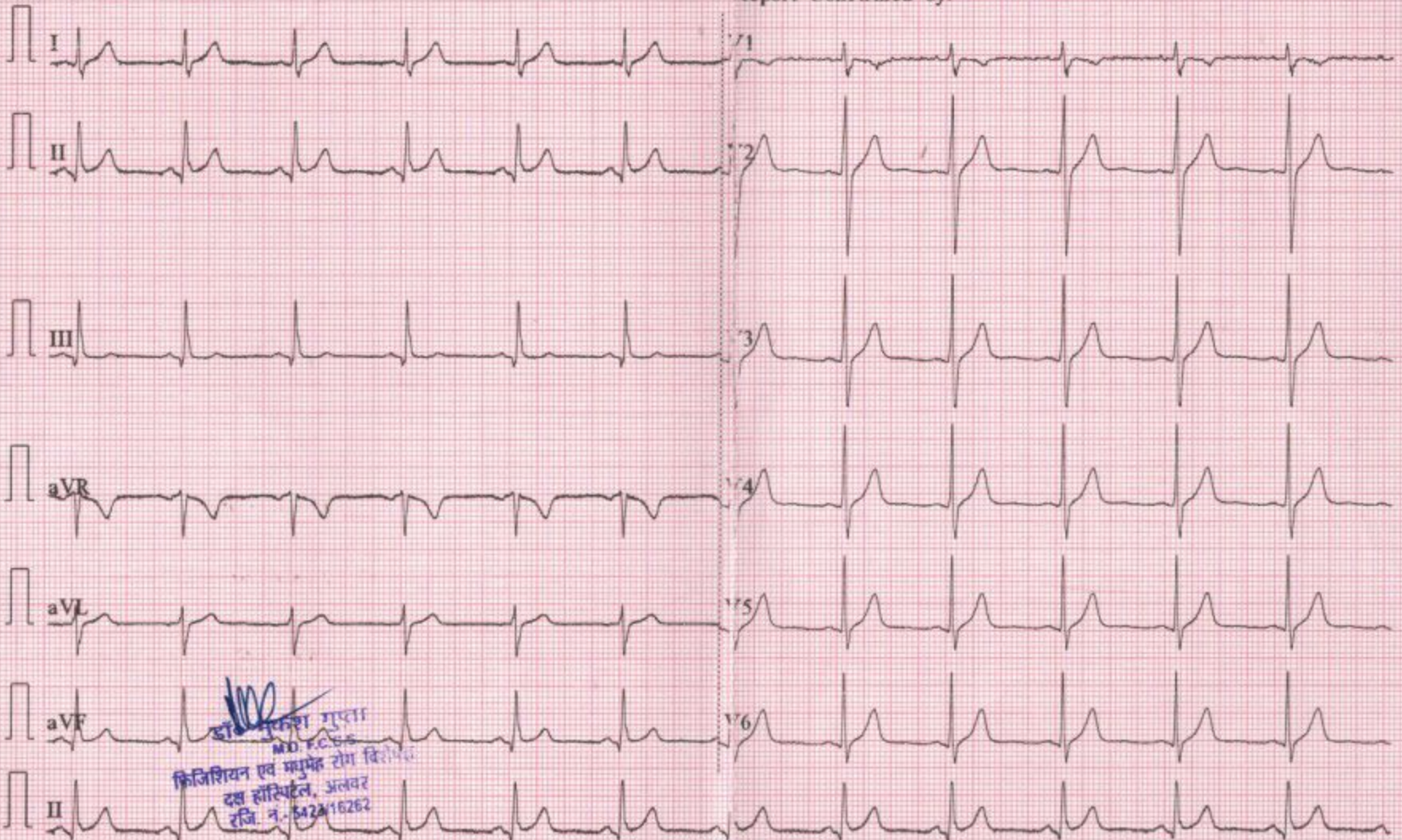
RV5/SV1 : 1.345/0.310 mV

Diagnosis Information:

Sinus rhythm

Normal ECG

Report Confirmed by:



[Handwritten Signature]
 डा. मुकेश गुप्ता
 MD, F.C.C.S.
 फिजिशियन एव मधुमेह रोग विशेषज्ञ
 दक्ष हॉस्पिटल, अलवर
 रजि. नं. 5424/16262

R

