



ABI SCANS & LABS

A unit of Aarthi Scans and Labs

Patient Name	MRS.INDHUMATHI V 30 Y	Age	
Patient ID	101019	Sex	Female
Referral Dr	MEDIWHEEL	Study Date	10 Jun 2022

X-RAY - CHEST PA VIEW

OBSERVATION:

The trachea is central.
The mediastinal and cardiac silhouette are normal.
Cardiothoracic ratio is normal.
Cardiophrenic and costophrenic angles are normal.
Both hila are normal.
Lung zones are clear.
Bones of the thoracic cage are normal.
Soft tissues of the chest wall are normal.

IMPRESSION:

No significant abnormality seen.

Dr. Abinaya., MD., (RD)
Consultant Radiologist

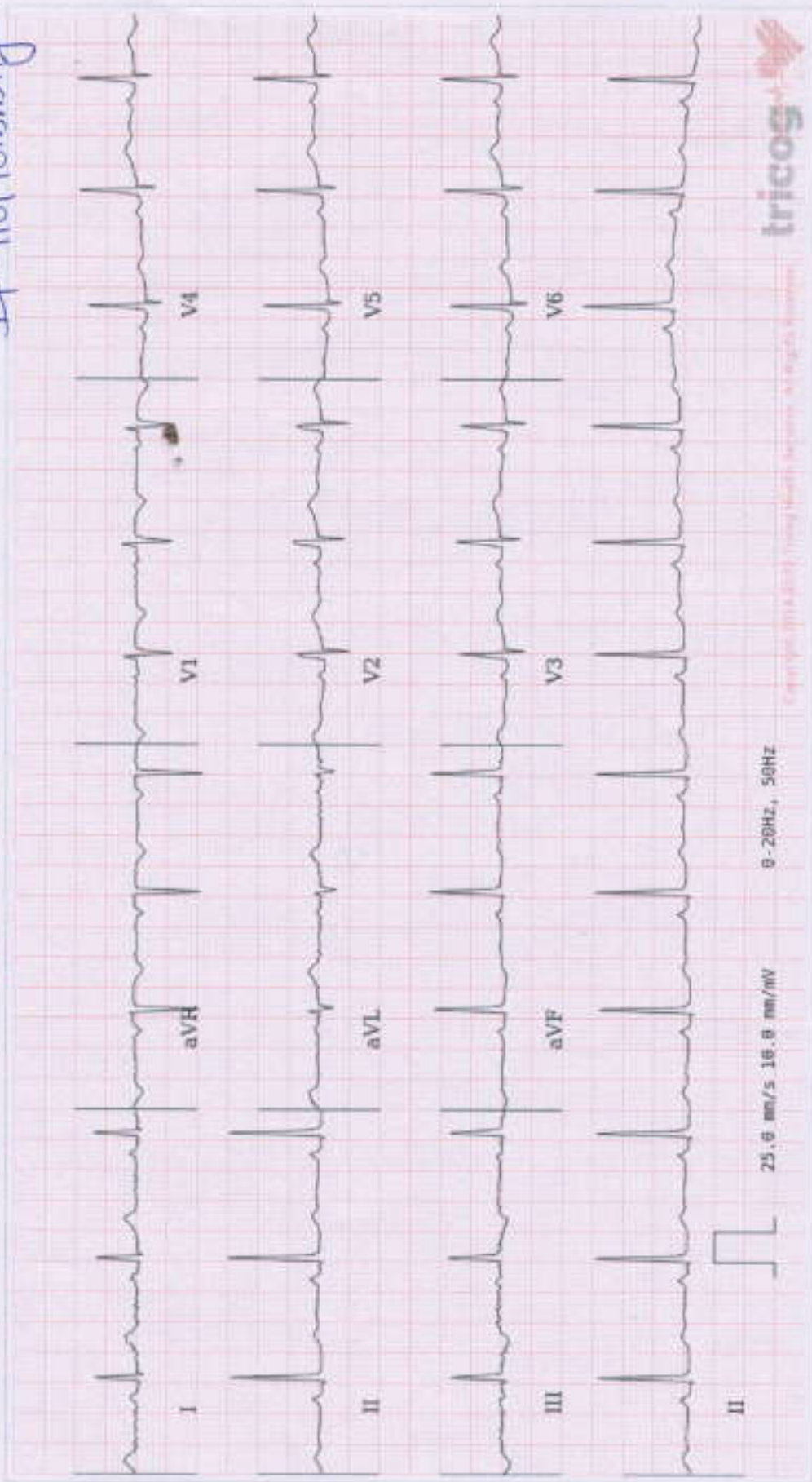


Aarthi CT and MRI Scans, R S Puram West

Age / Gender: 30/Female
Patient ID: 0000096633
Patient Name: MRS. INDHUMATHI V

Date and Time: 10th Jun 22 10:51 AM

Bp-110/70mmHg



AR: 78bpm VR: 78bpm QRSB: 74ms QF: 388ms QTC: 442ms PR: 140ms P-R-T: 33° 65° -2°

25.6 mm/s 16.0 mm/mV 0-20Hz, 50Hz

Within Normal Limits: Sinus Rhythm, Normal Axis. Please correlate clinically.



Analysis of this report is based on ECG alone and should only be used as an adjunct to clinical history, symptoms and results of other diagnostic and semi-diagnostic tests and must be interpreted by a qualified physician.



ABI SCANS & LABS

A unit of Aarthi Scans and Labs

NAME	MRS. INDHUMATHI V	PATIENT ID	96633
ACCESSION NO	101019	AGE/GENDER	30Y/FEMALE
REFERRED BY	MEDIWHEEL	DATE	10.06.2022

ECHOCARDIOGRAPHIC EVALUATION

MEASUREMENTS: ACOUSTIC WINDOW: OPTIMAL

2D/ M MODE PARAMETERS:

Parameters	Patient Values	Normal Adult Value
LA	2.50	(2.0 - 4.0 cm)
AO	2.01	(2.0 - 4.0 cm)
LVIDD	4.33	(3.5 - 5.5 cm)
LVIDS	2.95	(2.5 - 4.3 cm)
IVSd	0.75	(0.6 - 1.2 cm)
LVPWd	0.71	(0.6 - 1.2 cm)
EF	60	(50% - 70%)

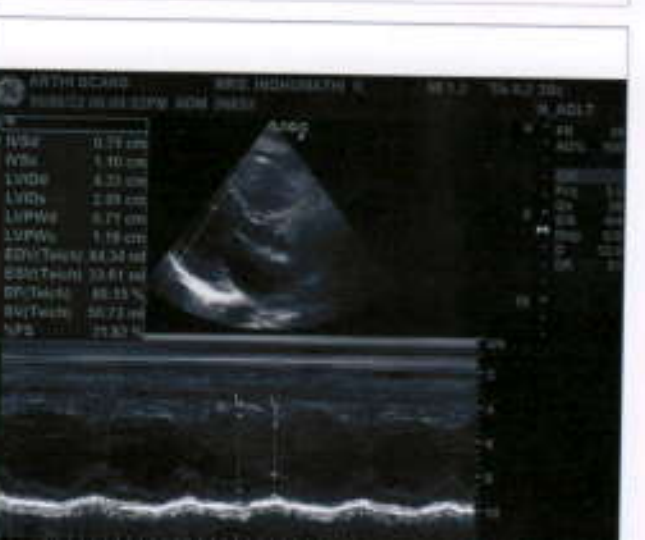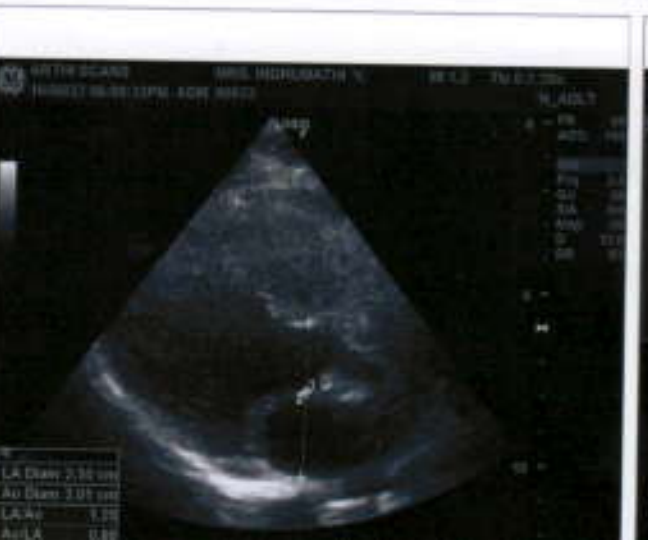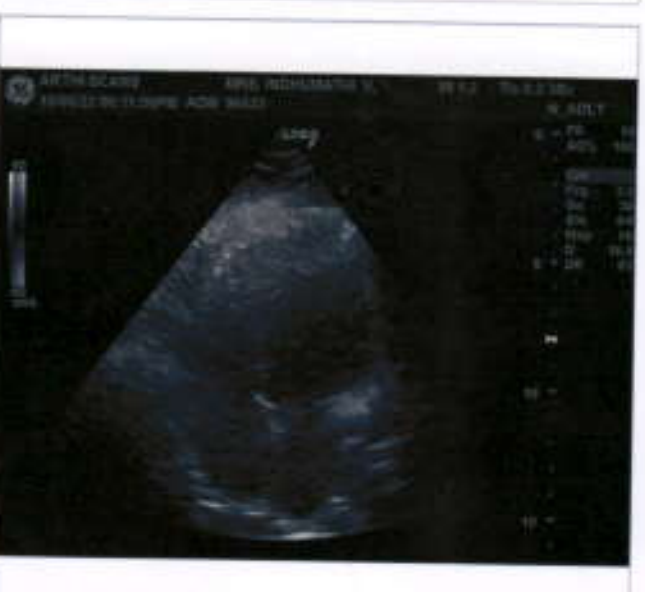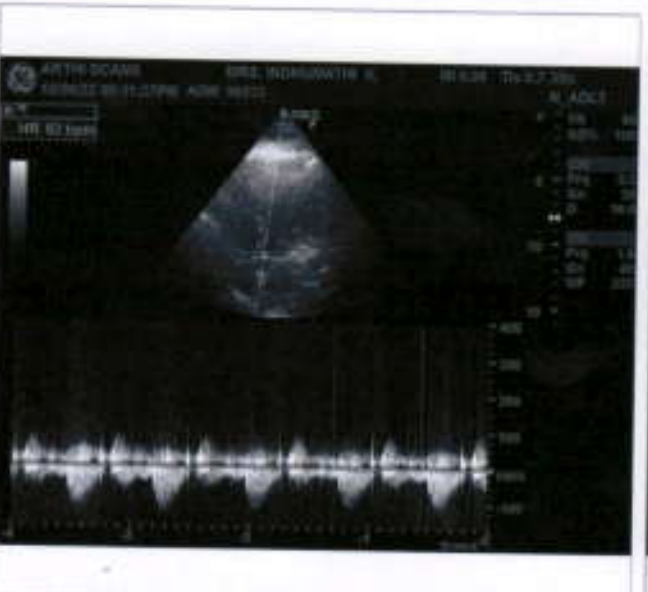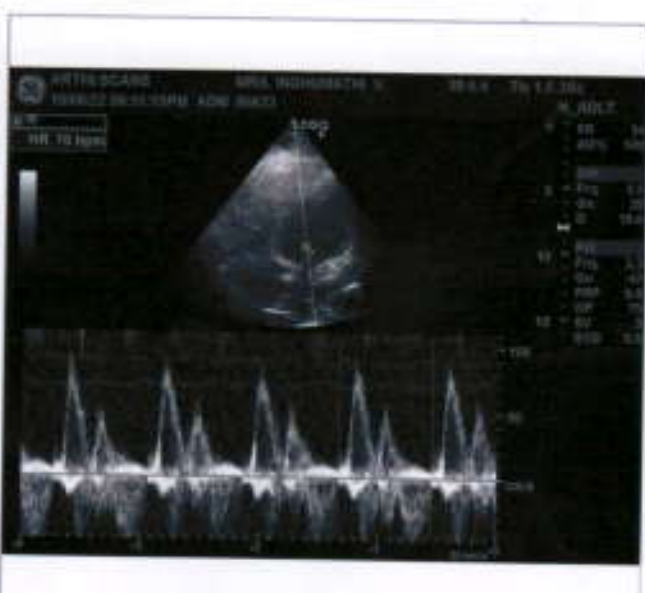
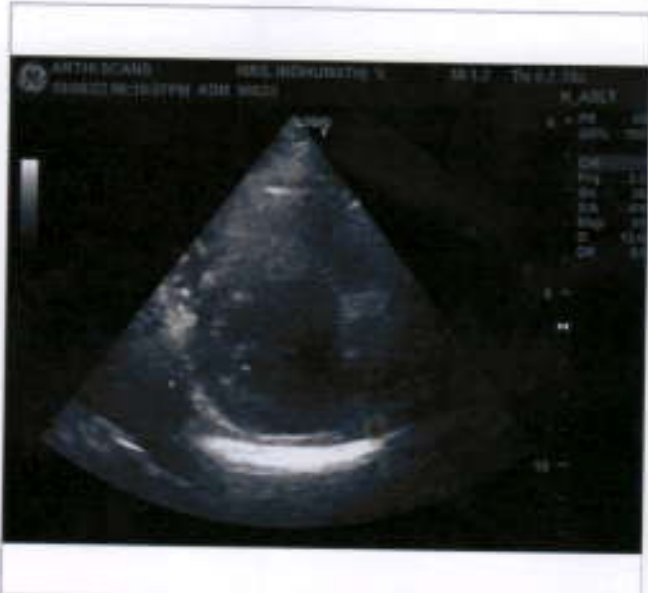IMPRESSION:

- ✚ No regional wall motion abnormality at rest.
- ✚ Normal valves and chambers.
- ✚ No pulmonary hypertension.
- ✚ No pericardial effusion.
- ✚ Normal LV systolic function.

**Dr. KARTHIK C.S.MD.,PGD(CARDIOLOGY,UKR)
CONSULTANT CARDIOLOGIST.**

ABI SCANS & LABS

MRS. INDHUMATHI V 30Y/F 96633 10-Jun-2022 05:23:40 PM Physician Name





ABI SCANS & LABS

A unit of Aarthi Scans and Labs

NAME	MRS. INDHUMATHI V	PATIENT ID	96633
ACCESSION NO	101019	AGE/GENDER	30Y/FEMALE
REFERRED BY	MEDIWHEEL	DATE	10 -JUNE-2022

VISION TEST

VISUAL ACUITY (VA)

If The Acuity Can Be Measures, Complete This Box Using Snellen acuities or snellen equivalents or NLP,LP,HM, or distance at which the patient sees the 20/100 letter.

WITH BEST CORRECTION

DISTANCE VISION	
Right	09/11
Left	09/11
Both	10/11

NEAR VISION	
Right	N6
Left	N6
Both	N6

COLOUR VISION	
BOTH	Normal



ABI SCANS & LABS

A unit of Aarthi Scans and Labs

Name	MRS. INDUMATHI V	Patient ID	96633
Accession No	101019	Age/Gender	30 Y / Female
Referred By	MEDIWHEEL	Date	10-Jun-2022

USG REPORT - ABDOMEN AND PELVIS

LIVER:

Is enlarged in size ~17 cm and shows increased echo texture.

No obvious focal lesion seen. No intra - Hepatic biliary radical dilatation seen.

GALL BLADDER:

Is adequately distended. No calculus or internal echoes are seen. Wall thickness is normal.

PANCREAS:

Appears normal in size and it shows uniform echo texture.

SPLEEN:

Is normal in size ~10.2 cm and shows uniform echogenicity.

RIGHT KIDNEY:

Right kidney measures ~10.3 x 3.7 cms.

The shape, size and contour of the right kidney appear normal.

Cortico medullary differentiation is within normal. No evidence of pelvicalyceal dilatation.

No calculi seen.

LEFT KIDNEY:

Left kidney measures ~9.4 x 3.7 cms.

The shape, size and contour of the left kidney appear normal.

Cortico medullary differentiation is within normal. No evidence of pelvicalyceal dilatation.

Calculus of size measuring ~ 4.2 mm noted in upper pole of left kidney.



ABI SCANS & LABS

A unit of Aarthi Scans and Labs

Name	MRS. INDUMATHI V	Patient ID	96633
Accession No	101019	Age/Gender	30 Y / Female
Referred By	MEDIWHEEL	Date	10-Jun-2022

USG REPORT - ABDOMEN AND PELVIS

BLADDER:

Is normal contour. No intra luminal echoes are seen.

UTERUS:

Measures ~ 9.2 x 4.2 x 5.6 cms.

Endometrium is regular and normal (5 mm).

Cervix appears normal.

OVARIES:

Right ovary measures ~ 1.8 x 1.3cms.

Left ovary measures ~ 1.4 x 1.6 cms.

No adnexal mass lesion seen. Pouch of Douglas is free. No free fluid in abdomen.

IMPRESSION:

- ❖ Mild Hepatomegaly with grade I fatty liver.
- ❖ Non obstructive left intra renal calculus.
- Suggested clinical correlation.


Dr. Lokesh Babu., MDRD.,
Radiologist

Thank you for the courtesy of this referral

Foot Note: Patient's identity is not verified. Report is not valid for medico legal purpose.

Dr. Lokesh Babu, MD.,RD.,
Reg. No: 113030

ABI SCANS AND LABS

MRS. INDHUMATHI V / F 96633 10-Jun-2022 09:39:42 AM

