

Facilities:

All clinical Biomedical & Hematology Investigations including Bone Marrow Examination VPT, Podiascan & Complete Foot Care (First Time in Purvanchal) All Hormonal Investigation by Chemiluminescent Method Visceral Fat by (AB-140) Ambulatory BP Monitoring CGMS & Insulin Pump Available PFT, 2D-ECHO (Color Doppler), Holter, TMT, Cardiac-3 available VIA, VILI, Colposcopy available Special Endocrinological Investigation Protocols.

ISO 9001:2008 Certified
Mobile: 9389994334, 9554572190, 9453837595



Panacea Pathology

Clinical Reference Lab

Persistence, Preparedness and Precision
EQAS (CMC Vellore Attached) & IQAS System
पूर्वांचल की सर्वोत्तम गुणवत्ता वाली पैथोलॉजी

PATIENT NAME : HARE RAM BHASKAR

AGE/GENDER : 34YRS/MALE

REFD BY DR. : ARCO FEMI HEALTHCARE LTD.

RECEIVED DATE : 14-01-2023 (10:00 AM)

SAMPLE : BLOOD & URINE

REPORT DATE : 14-01-2023 (06:00 PM)

PATHOLOGY REPORT

COMPLETE BLOOD COUNT (CBC)

TEST	LAB TEST VALUES	NORMAL RANGE
HEMOGRAM		
HEMOGLOBIN (FLOW CYTOMETRY)	1.56	13 – 16 gm/dl
TOTAL LEUCOCYTE COUNT (TLC)	6.300	4000 – 11000
RBC COUNT	5.36	3.5 – 5.5
PCV (HCT)	47.6	37 – 47
MCV	88.8	80 – 95
MCH	29.0	28 – 34
MCHC	32.7	30 – 36
PLATELET COUNT	2,17,000	1,50,000 – 4,00,000
E.S.R. (WINTROBE FIRST HOURS)	10.0	20 mm/1 st hr
DIFFERENTIAL LEUCOCYTE		
NEUTROPHILS	58	40 – 75%
LYMPHOCYTES	38	20 – 45%
EOSINOPHILS	02	1 – 6%
MONOCYTES	02	2 – 8%
BASOPHILS	00	< 2%

RENAL & KIDNEY PROFILE, SERUM

TEST	LAB TEST VALUES	NORMAL RANGE
RENAL FUNCTION TESTS		
BLOOD UREA NITROGEN (BUN)	11.6	10 – 50 mg/dl
SERUM CREATININE	0.83	0.60 – 1.60 mg/dl
URIC ACID	4.16	3.60 – 7.70 mg/dl
ALKALINE PHOSPHATASE (ALP)	115.6	142 – 353 mg/dl
TOTAL PROTIENS	7.6	0 – 39 mg/dl
ALBUMIN	4.2	3.8 – 5.4 mg/dl
SERUM GLOBULIN	3.30	2.1 – 3.5 mg/dl
CALCIUM	8.9	8.80 – 10.20
PHOSPHORUS	3.04	2.50 – 5.00
SERUM SODIUM NA+	1.005	135.00 – 155.00 mEq/Ltr
SERUM POTASIUUM K+	4.12	3.60 – 5.50 mEq/Ltr
ICALCIUM	1.22	1.10 – 1.35 mmol/L
SERUM CHLORIDE CL+	101.3	98.00 – 110.00 mEq/Ltr

PAGE 1

Lab Technician

PANACEA HOSPITAL
A UNIT OF ARCHA HEALTH CARE PVT. LT.
REG. NO. 1500
M.D. Pathology
B.36/44, B-4, KABIR NAGAR
DURGAKUND, VARANASI

Timing : 8.00 a.m. to 9.00 p.m. (Sunday 8.00 a.m. to 3.00 p.m.)

This Report is not valid for medico legal purpose

Note: These tests have technical limitations. Clinico-pathological interpretation is necessary. In case of any disparity test may be repeated immediately.

Address : 36/44 FK Kabir Nagar, Durgakund, Varanasi – 221005

Email: dramishra@gmail.com, drpallaviojha@gmail.com **Website:** panaceahospital.org

Facilities:

All clinical Biomedical & Hematology Investigations including Bone Marrow Examination
 VPT, Podiascan & Complete Foot Care (First Time in Purvanchal)
 All Hormonal Investigation by Chemiluminescent Method
 Visceral Fat by (AB-140) Ambulatory BP Monitoring
 CGMS & Insulin Pump Available
 PFT, 2D-ECHO (Color Doppler), Holter, TMT, Cardiac-3 available
 VIA, VILI, Colposcopy available
 Special Endocrinological Investigation Protocols.

ISO 9001:2008 Certified
 Mobile: 9389994334, 9554572190, 9453837595



Panacea Pathology

Clinical Reference Lab

Persistence, Preparedness and Precision
 EQAS (CMC Vellore Attached) & IQAS System
 पूर्वांचल की सर्वोत्तम गुणवत्ता वाली पैथोलॉजी

PATIENT NAME : HARE RAM BHASKAR

AGE/GENDER : 34YRS/MALE

REFD BY DR. : ARCO FEMI HEALTHCARE LTD.

RECEIVED DATE :14-01-2023 (10:00 AM)

SAMPLE : BLOOD & URINE

REPORT DATE : 14-01-2023 (06:00 PM)

PATHOLOGY REPORT

LIPID PROFILE, SERUM

TEST	LAB TEST VALUES	NORMAL RANGE
BLOOD CHEMISTRY		
TOTAL CHOLESTEROL (SERUM)	163.0	Desirable:- < 200 mg/dl Borderline:- 200 – 239 mg/dl High:- > 240 mg/dl
TRIGLYCERIDES (SERUM)	153.0	35 – 170 mg/dl
HDL CHOLESTEROL (SERUM)	42.0	35.30 – 79.50 mg/dl
LDL CHOLESTEROL (SERUM)	90.4	< 130 mg/dl
VLDL	30.6	< 40 mg/dl
CHOLESTROL/HDL RATIO	3.88	< 3.0 Low Risk Ratio 3.0 – 5.0 Avg Risk > 5.0 High Risk
LDL/HDL RATIO	2.14	< 3 Ratio

BLOOD GROUP

TEST	LAB TEST VALUES
BLOOD GROUP ABO & RH FACTOR	
BLOOD GROUP	"O"
RH FACTOR	POSITIVE

GLYCOSYLATED HEMOGLOBIN (HBA1C)

TEST	LAB TEST VALUES	NORMAL RANGE
HBA1C	6.0	Normal : <5.97 % Good Control : 5.97 – 6.81% Fair Control : 6.81 – 7.65% Poor Control : >7.65%

THYROID PROFILE (T3, T4, TSH)

TEST	LAB TEST VALUES	NORMAL RANGE
THYROID FUNCTION TEST		
T3	1.10	0.60 – 1.81 ng/ml
T4	7.56	4.50 – 10.90 ug/dl
TSH	1.94	0.39 – 6.10 uIU/mL

PAGE 2

Lab Technician

PANACEA HOSPITAL

A UNIT OF AARCHA HEALTH CARE PVT. LTD

REG. No. Path/1500

B.36/44, B-4, KABIR NAGAR

DURGAKUND, VARANASI

Timing : 8.00 a.m. to 9.00 p.m. (Sunday 8.00 a.m. to 3.00 p.m.)

This Report is not valid for medico legal purpose

Note: These tests have technical limitations. Clinico-pathological interpretation is necessary. In case of any disparity test may be repeated immediately.

Address : 36/44 FK Kabir Nagar, Durgakund, Varanasi – 221005

Email: dramishra@gmail.com, drpallaviojha@gmail.com Website: panaceahospital.org

Facilities:

All clinical Biomedical & Hematology Investigations including Bone Marrow Examination
 VPT, Podiascan & Complete Foot Care (First Time in Purvanchal)
 All Hormonal Investigation by Chemiluminescent Method
 Visceral Fat by (AB-140) Ambulatory BP Monitoring
 CGMS & Insulin Pump Available
 PFT, 2D-ECHO (Color Doppler), Holter, TMT, Cardiac-3 available
 VIA, VILI, Colposcopy available
 Special Endocrinological Investigation Protocols.

ISO 9001:2008 Certified
 Mobile: 9389994334, 9554572190, 9453837595



Panacea Pathology

Clinical Reference Lab

Persistence, Preparedness and Precision
 EQAS (CMC Vellore Attached) & IQAS System
 पूर्वांचल की सर्वोत्तम गुणवत्ता वाली पैथोलॉजी

PATIENT NAME : HARE RAM BHASKAR	AGE/GENDER : 34YRS/MALE
REFD BY DR. : ARCO FEMI HEALTHCARE LTD.	RECEIVED DATE :14-01-2023 (10:00 AM)
SAMPLE : BLOOD & URINE	REPORT DATE : 14-01-2023 (06:00 PM)

PATHOLOGY REPORT

LIVER PROFILE TEST, SERUM

TEST	LAB TEST VALUES	NORMAL RANGE
BIO CHEMISTRY		
TOTAL BILIRUBIN	0.72	0.0 – 1.1 mg/dl
DIRECT BILIRUBIN	0.28	0.0 – 0.2 mg/dl
INDIRECT BILIRUBIN	0.44	< 0.90 mg/dl
SGOT (AST)	22.5	0 – 52 mg/dl
SGPT (ALT)	24.1	0 – 39 mg/dl
GGT (GYT)	27.0	< 55 U/L

URINE ROUTINE EXAMINATION

TEST	LAB TEST VALUES	NORMAL RANGE
PHYSICAL EXAMINATION		
QUANTITY	29	ML
COLOUR	STRAW	PALE YELLOW
APPEARANCE	CLEAR	CLEAR
SPECIFIC GRAVITY	1.005	1.01 – 1.03
PH	6.0	4.7 – 7.5
CHEMICAL EXAMINATION		
GLUCOSE	Not Detected	Not Detected
PROTEIN	NIL	Not Detected
MICROSCOPIC EXAMINATION		
PUS CELLS	1-2	0-5
RBC	Not Detected	Not Detected
EPITHELIAL CELLS	2-3	0-5
CASTS	Not Detected	Not Detected
CRYSTALS	Not Detected	Not Detected
BACTERIA	Not Detected	Not Detected

RANDOM/FASTING BLOOD SUGER

TEST	LAB TEST VALUES	NORMAL RANGE
RBS/FBS		
RANDOM BLOOD SUGAR	110.0	125-140 mg/dl
FASTING BLOOD SUGER	95.0	110-125 mg/dl

----- End of Report -----

Lab Technician

PANACEA HOSPITAL
 UNIT OF AAROMA HEALTH CARE PVT. LTD

REG. NO. AL1500

B.36/44, B-4, KABIR NAGAR

DURGAKUND, VARANASI

Timing : 8.00 a.m. to 9.00 p.m. (Sunday 8.00 a.m. to 3.00 p.m.)

This Report is not valid for medico legal purpose

Note: These tests have technical limitations. Clinico-pathological interpretation is necessary. In case of any disparity test may be repeated immediately.

Address : 36/44 FK Kabir Nagar, Durgakund, Varanasi – 221005

Email: dramishra@gmail.com, drpallaviojha@gmail.com Website: panaceahospital.org



भारतीय विशिष्ट पहचान प्राधिकरण

भारत सरकार

Unique Identification Authority of India

Government of India

नामांकन क्रम / Enrollment No 1028/55030/04328

To,

हरे राम भास्कर

Hare Ram Bhaskar

S/O: Bindeshwar Prasad

Pirogha

Julfipur Modanganj Modanganj Arwal

Bihar 804432

20/05/2013

Ref: 20934 / 211 / 1008868 / 1008869 / P



SH323622911FT



आपका आधार क्रमांक / Your Aadhaar No. :

9007 6269 7625

आधार - आम आदमी का अधिकार



भारत सरकार

Government of India



हरे राम भास्कर

Hare Ram Bhaskar

जन्म वर्ष / Year of Birth : 1989

पुरुष / Male



9007 6269 7625

आधार - आम आदमी का अधिकार



PANACEA HOSPITAL

B 36/44 F.K KABIR NAGAR, DURGAKUND

TOLLFREE NO-18001233070.

Whatsapp No - 8795832852

www.piire.org



OP Slip

Print Date : 14-Jan-2023 08:32AM



UHID No :- UD-22230003284 OP No :- OP-22230012194 OP Date :- 14 Jan 2023 8:31AM
Patient Name :- Mr HARE RAM BHASKAR Age/Sex :- 34 Y/Male Mobile No :- 7844841466
BANK OF BARODA
Father :- VINDESHWAR PRASAD Department :- DIABETES, ENDOCRINOLOGY & METABOLIC PHYSICIAN
Pay Type :- Cash Consultant :- Dr ASHUTOSH MISHRA (MD(MEDICINE), IMS, BHU)
Token No :- NOR. - 1 Paid/Bal :- 0.00 / 500.00
Patient Type :- Normal
Address :- GANPATI APARTMENT , LANKA, varanasi

BP :- 130/80
height :- 166
Weight (kg) :- 107
BMI :-
SpO2: 98
PR: 84

Rx

Pre-Diabetes

Rx:

Tab. Diabemas (10) OD
Tab. Roumey (20) OD

R/A 2 month

Printed By : Mr NITIN YADAV

Created By : Mr NITIN YADAV

2014-08-28

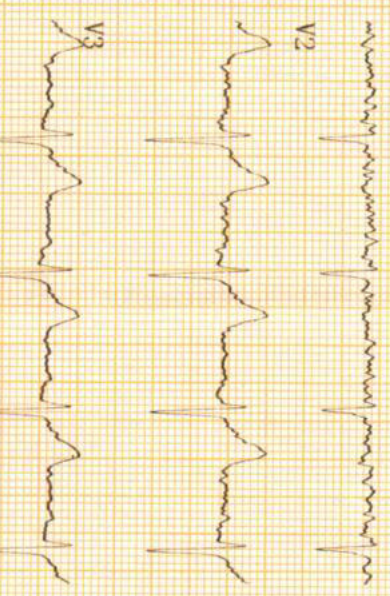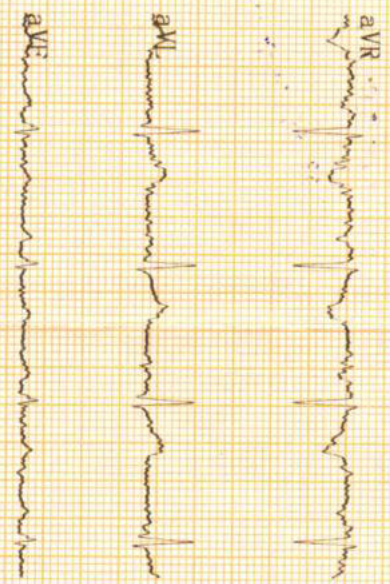
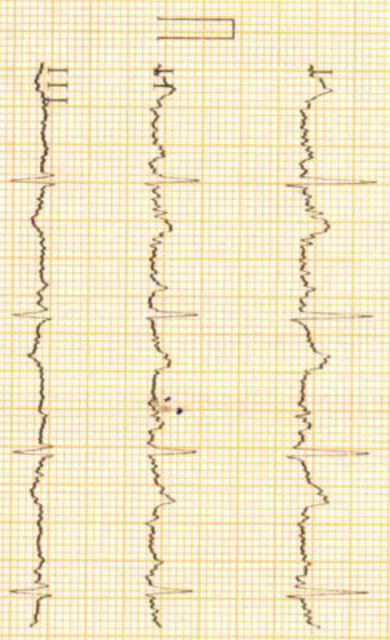AUTO 10mm/mV

1.0mm/mV

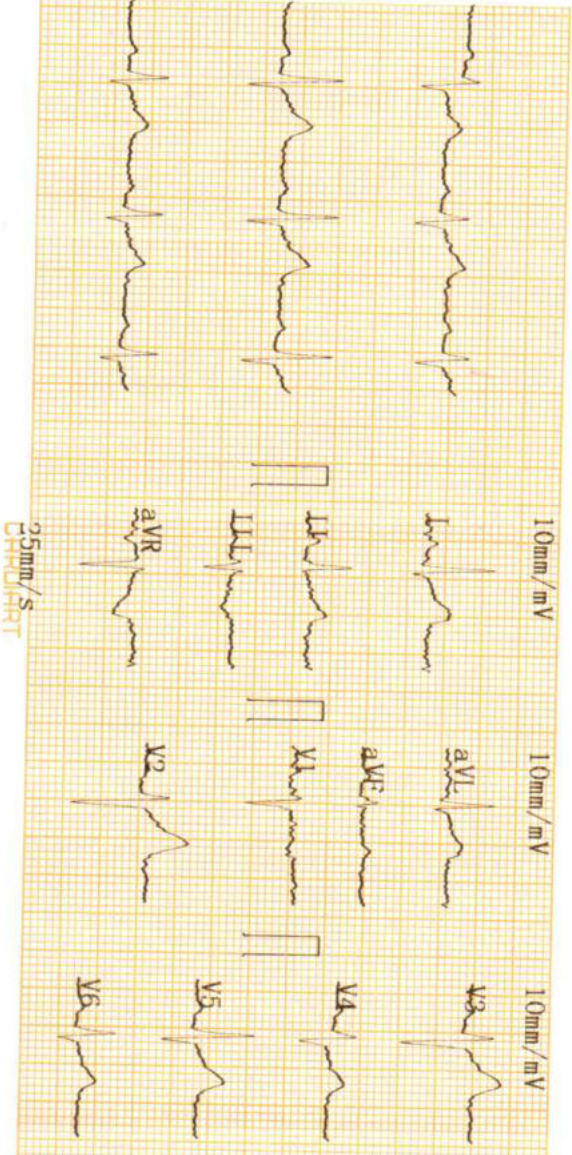
1.0mm/mV

1.0mm/mV

BPL



CARDIART 25mm/s AC50Hz+EMG35Hz



2023-01-14 08:56

BPL

ID :
 Name : **HARIT RAN BHASKAR**
 Sex :
 Height :
 SYS :
 DIA :
 HR : 82 bpm
 PR Interval : 167 ms
 P Duration : 120 ms
 QRS Duration : 82 ms
 T Duration : 220 ms
 QT/QTc : 352/411 ms
 P/QRS/T Axis : 52.8/25.8/19.0 deg
 R(V5)/S(V1) : 0.81/0.64 mV
 R(V5)+S(V1) : 1.45 mV

<< Conclusions >>

Normal Sinus Rhythm.
 Longitudinal Left axis deviation.
 Report need physician confirm

Physician

DR. PALLAVI MISHRA
 MBBS,MD (GENERAL MEDICINE)
 MCI Reg.No. 52033



PANACEA HOSPITAL

A shelter for many hearts A Home for many lives

(An ISO 9001:2008 Certified Organisation)

Lab Attached with CMC Vellore Under EQAS Scheme

name	MR.HARE RAM BHASKAR	Sex /Age	34/M	Date	14/01/2023
ef. by	Dr.Pallavi Mishra(MD)	BSA - m ²		Echo window	fair

Echo - Cardiography

MITRAL VALVE Doppler	AML - normal morphology MV Flow - E - 0.5 A-0.5 E/A=1.13	PML - normal morphology MVA - 3.0 cm ² Mitral Regurgitation - No
TRICUSPID VALVE Doppler	Normal TV Flow -No	Tricuspid Regurgitation - No
PULMONARY VALVE Doppler	Normal PV Flow -No	Pulmonary Regurgitation - No
AORTIC VALVE Doppler	Trileaflet-No AV Flow - no	Aortic Regurgitation - no
MEASUREMENT	Aorta - 25.7 (20-38) mm IVS ed - 9.7 (6-12) mm LVID ed - 46.8 (35-55) mm LVPW ed - 12.6 (6-12) mm OA - 7 (> 5) mm	LA - 36.0 (24-32) mm IVS es -14.3 (6-12) mm LVID es - 32.0 (24-40) mm LVPW es - 14.3 (6-12) mm EPSS - 5 (< 9) mm

CONCLUSION


All cardiac chamber dimensions are WNL
No valvular abnormalities
Good LV systolic function present Modified Simpson's method (4C, 2C) (LVEF-60%)
No diastolic dysfunction present (E/A = 1.13) by tissue Doppler (E/e'=6.2)
No RWMA
No pericardial effusion
Intact IAS / IV
No PAH
No intra cardiac mass /thrombus /vegetation

IMPRESSION

Normal Echocardiogram


Niraj Mishra
Physician Assistant
(PIIRE)

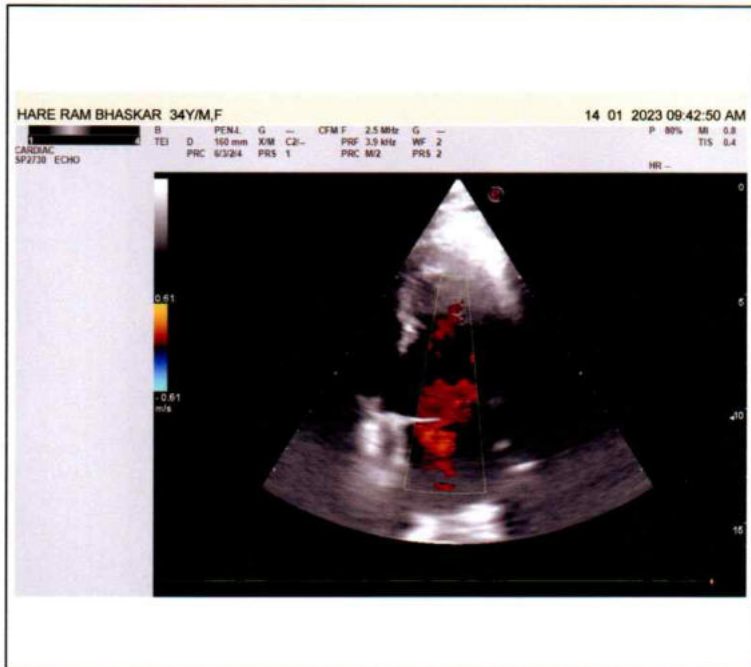
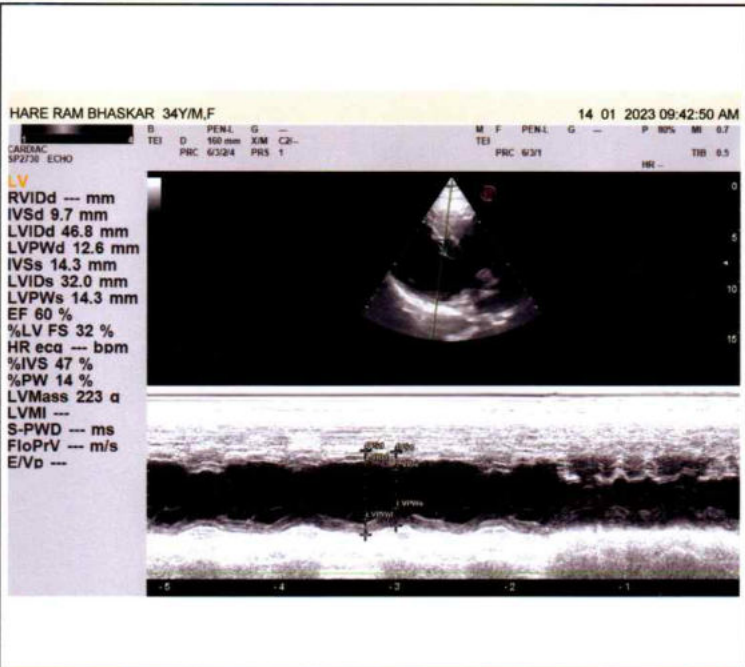
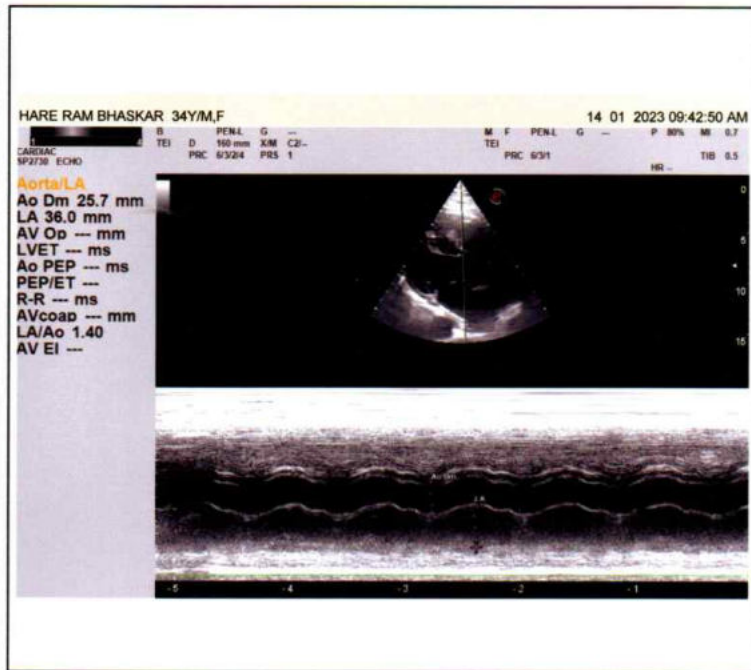
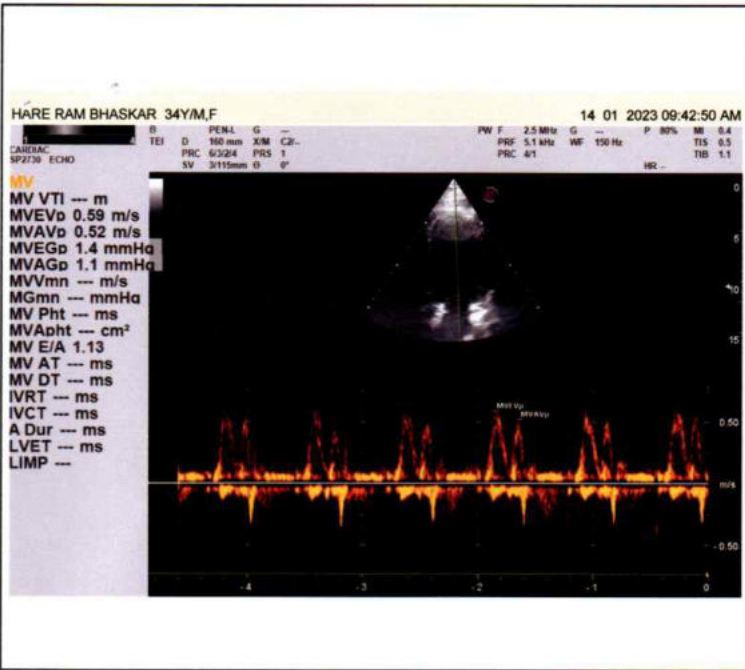
DR. PALLAVI MISHRA
MBBS, MD (GENERAL MEDICINE)
MCI Reg. No. 52033

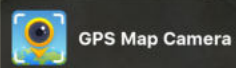
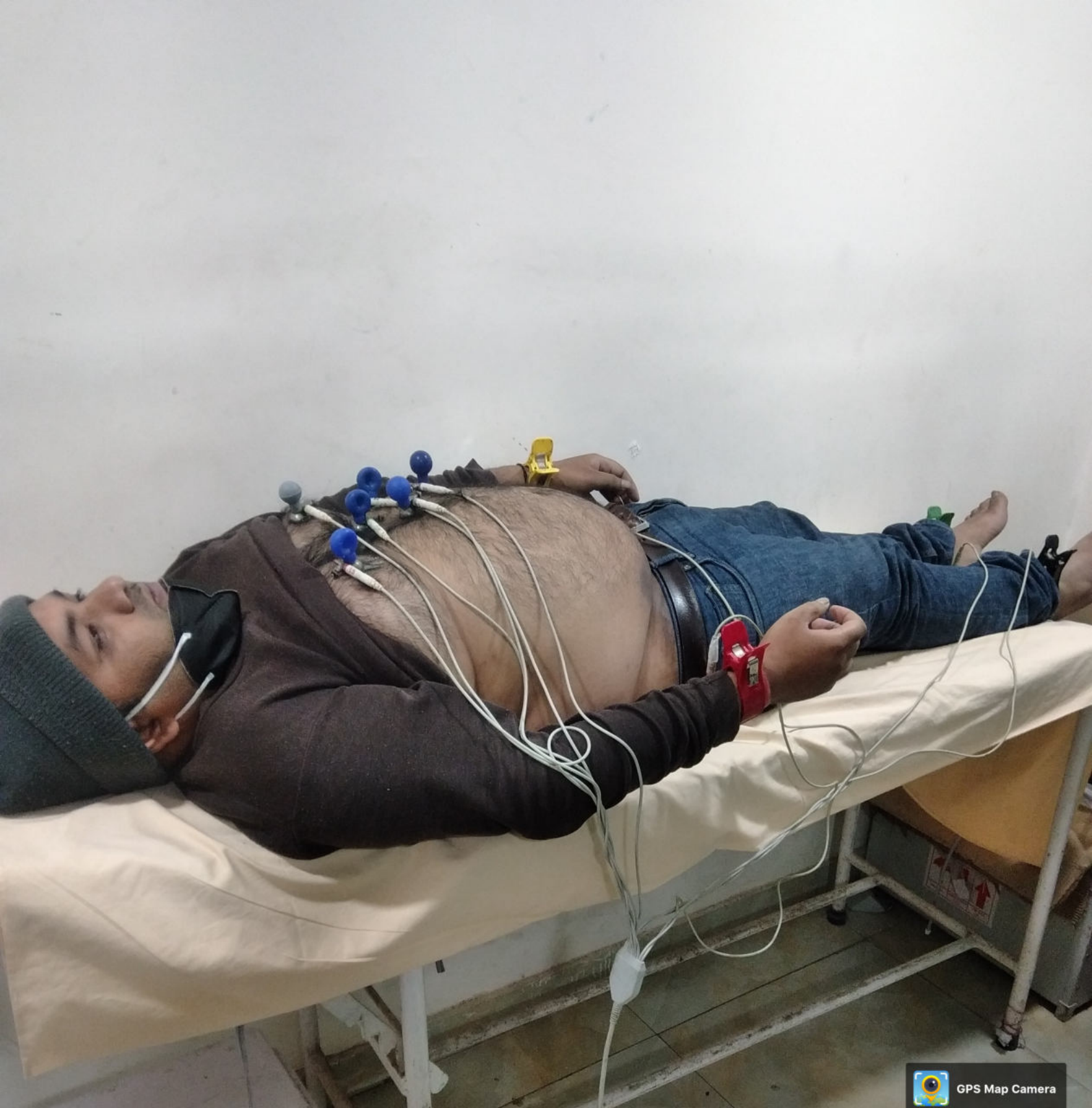
Dr. Pallavi Mishra
MBBS, MD (MED) Lucknow
Echocardiography Specialist, MIAE
Non-invasive cardiologist
Women Cardiologist
Diabetocardiologist

Address : Kabir Nagar (Near Sanjay Shiksha Niketan), Durgakund, Varanasi

Mobile : 9554572190 / 9453837595 / Recpn. 9389994334

E-mail : dramishra@gmail.com, drpallaviojha@gmail.com, Website: www.piire.org





Varanasi, Uttar Pradesh, India
B36/44B-A-R, Padampuri Colony, Durgakund,
Nagwa, Varanasi, Uttar Pradesh 221005, India
Lat 25.289166°
Long 82.993329°
14/01/23 08:56 AM GMT +05:30



PANACEA HOSPITAL

A shelter for many hearts A Home for many lives

(An ISO 9001:2008 Certified Organisation)

Lab Attached with CMC Vellore Under EQAS Scheme

AME: MR.HARE RAM BHASKAR

AGE/SEX: 34 YRS / MALE

REF BY: DR. ASHUTOSH MISHRA (MD)

DATE: 14/01/2023

ULTRA SOUND WHOLE ABDOMEN REPORT

Liver: Normal in shape and size (13.5 cm) and shows mildly increased echogenicity. Margins are smooth and regular. No focal lesion seen.

Gall bladder: Partially distended with normal wall thickness and echo-free lumen.

CBD diameter Visualized part normal in course & caliber.

Pancreas: Normal in size, shape & echogenicity. Margins are smooth & regular. No diffuse/ focal lesion seen. Pancreatic tail obscured.

Spleen: Spleen measures 12.6 cm along its long axis s/o SPLENOMEGALY. Splenic vessels at hilum is normal.

Kidney: Right kidney: 10.9 X 4.9cm
Left kidney: 10.2 X 5.7 cm
Both normal in size, shape, echogenicity & position. Cortical-medullary differentiation is maintained. Pelvicalyceal system normal. No calculus/mass lesion seen. No hydronephrosis/ hydroureter seen. No suprarenal mass lesion.

Address : Kabir Nagar (Near Sanjay Shiksha Niketan), Durgakund, Varanasi

Mobile : 9554572190 / 9453837595 / Recpn. 9389994334

E-mail : dramishra@gmail.com, drpallaviojha@gmail.com, **Website:** www.piire.org



PANACEA HOSPITAL

A shelter for many hearts A Home for many lives

(An ISO 9001:2008 Certified Organisation)

Lab Attached with CMC Vellore Under EQAS Scheme

inary bladder: Normally distended, wall thickness is normal.
No echogenic foci lumen or diverticula seen.
Both VUJ appears normal.
No E.R. calculus / mass lesion seen.

Prostate: Normal in size, shape, & echogenicity.
Size 3.3 X 2.7 X 3.6 cm Wt. 17.5 Gm approx.
No calcification or focal cystic lesion seen.
Capsular margins are smooth and regular.
Seminal vesicles appear normal in size, shape & echogenicity.
No diffuse /focal lesion seen.

Others: No free fluid in peritoneal cavity.
No free fluid in bilateral pleural cavity.

IMPRESSION:

- *Grade I fatty liver.*
- *Mild splenomegaly .*

Please correlate clinically and further investigations.

DR. PALLAVI MISHRA

MBBS MD (GENERAL MEDICINE)
MCI Reg.No. 52033

DR. PALLAVI MISHRA

MBBS MD(MED) Lucknow
Echocardiography specialist, MIAE
Non invasive cardiologist
Women cardiologist

Radiologist

Dr.Tusharika Rai
MBBS MS

NIRAJ MISHRA
(Physician Assistant)
(PIIRE)

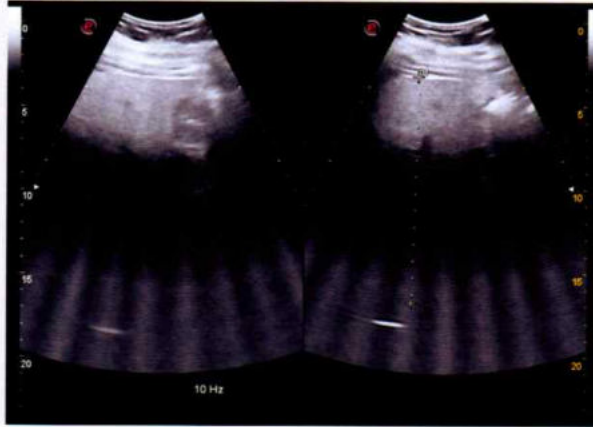
Address : Kabir Nagar (Near Sanjay Shiksha Niketan), Durgakund, Varanasi

Mobile : 9554572190 / 9453837595 / Recpn. 9389994334

E-mail : dramishra@gmail.com, drpallaviojha@gmail.com, Website: www.piire.org

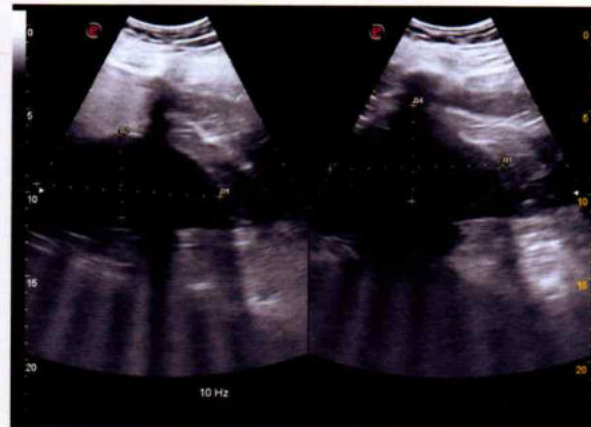
HARE RAM BHASKAR 34Y/M,F
14 01 2023 09:37:21 AM
P 60% MI 0.8
GEN.M G --
D 211 mm X/M C2--
TEI D PRC 19/2/3/5 PRS 4

D1
135.0 mm



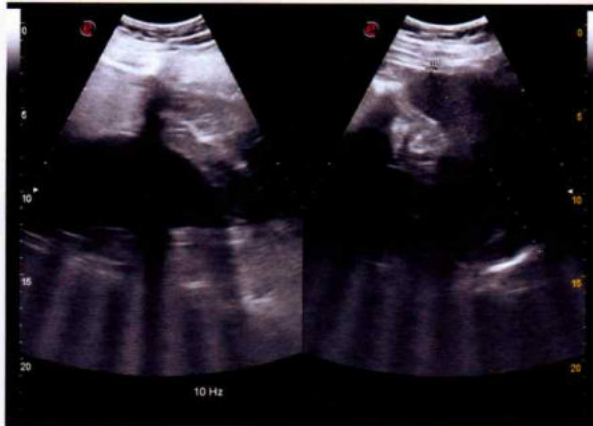
HARE RAM BHASKAR 34Y/M,F
14 01 2023 09:37:21 AM
P 60% MI 0.8
GEN.M G --
D 211 mm X/M C2--
TEI D PRC 19/2/3/5 PRS 4

D-Ratio
D1
109.5 mm
D2
49.1 mm
D/D
223 %
D-Ratio
D3
102.8 mm
D4
57.3 mm
D/D
179 %

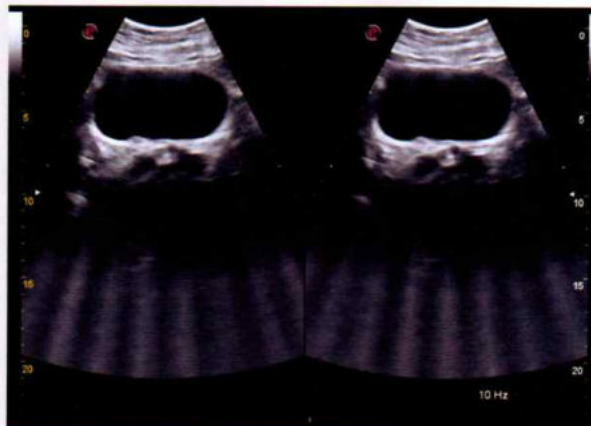


HARE RAM BHASKAR 34Y/M,F
14 01 2023 09:37:21 AM
P 60% MI 0.8
GEN.M G --
D 211 mm X/M C2--
TEI D PRC 19/2/3/5 PRS 4

D1
126.9 mm

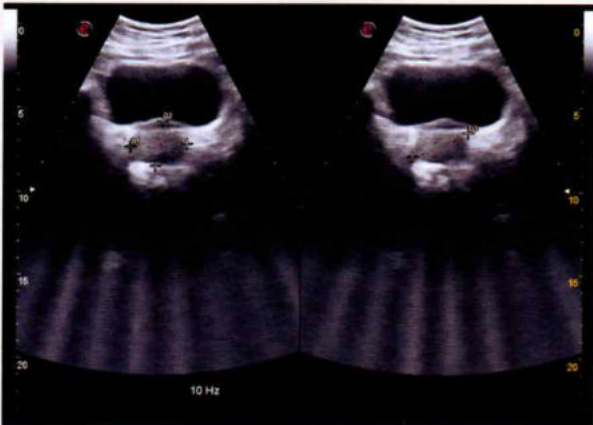


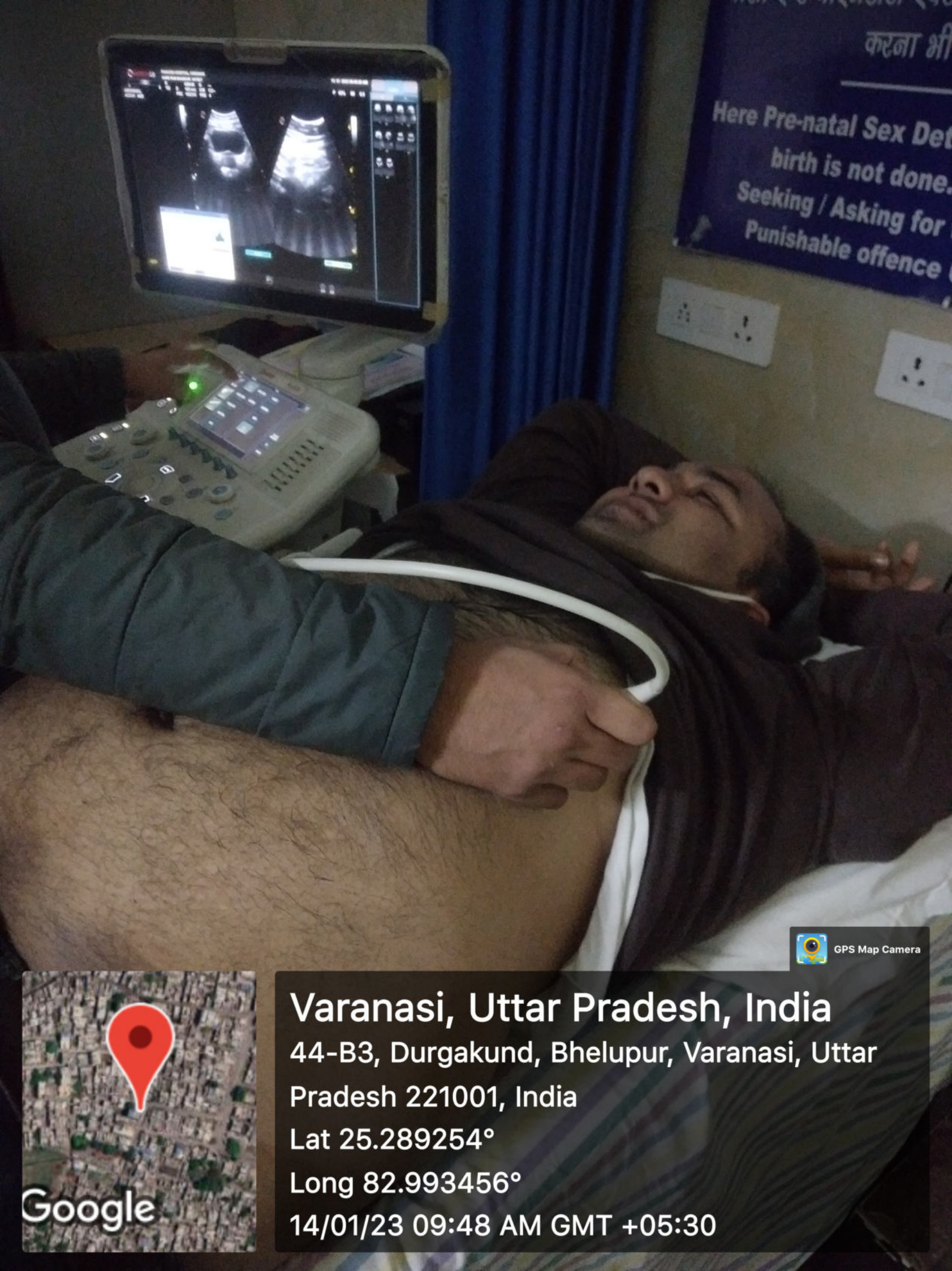
HARE RAM BHASKAR 34Y/M,F
14 01 2023 09:37:21 AM
P 60% MI 0.8
GEN.M G --
D 211 mm X/M C2--
TEI D PRC 19/2/3/5 PRS 4



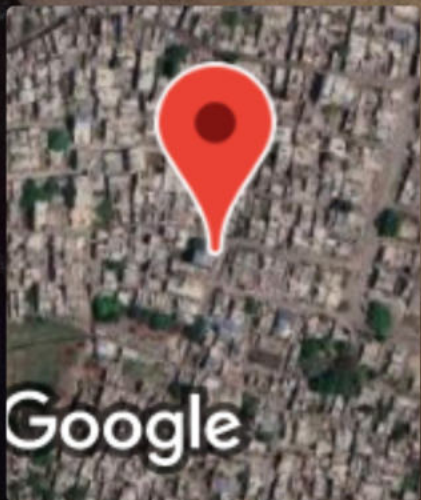
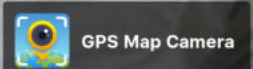
HARE RAM BHASKAR 34Y/M,F
14 01 2023 09:37:21 AM
P 60% MI 0.8
GEN.M G --
D 211 mm X/M C2--
TEI D PRC 19/2/3/5 PRS 4

BI-Volume
D1
33.9 mm
D2
27.2 mm
D3
36.2 mm
V
17.5 ml





करना भी
Here Pre-natal Sex Det
birth is not done.
Seeking / Asking for
Punishable offence



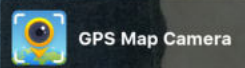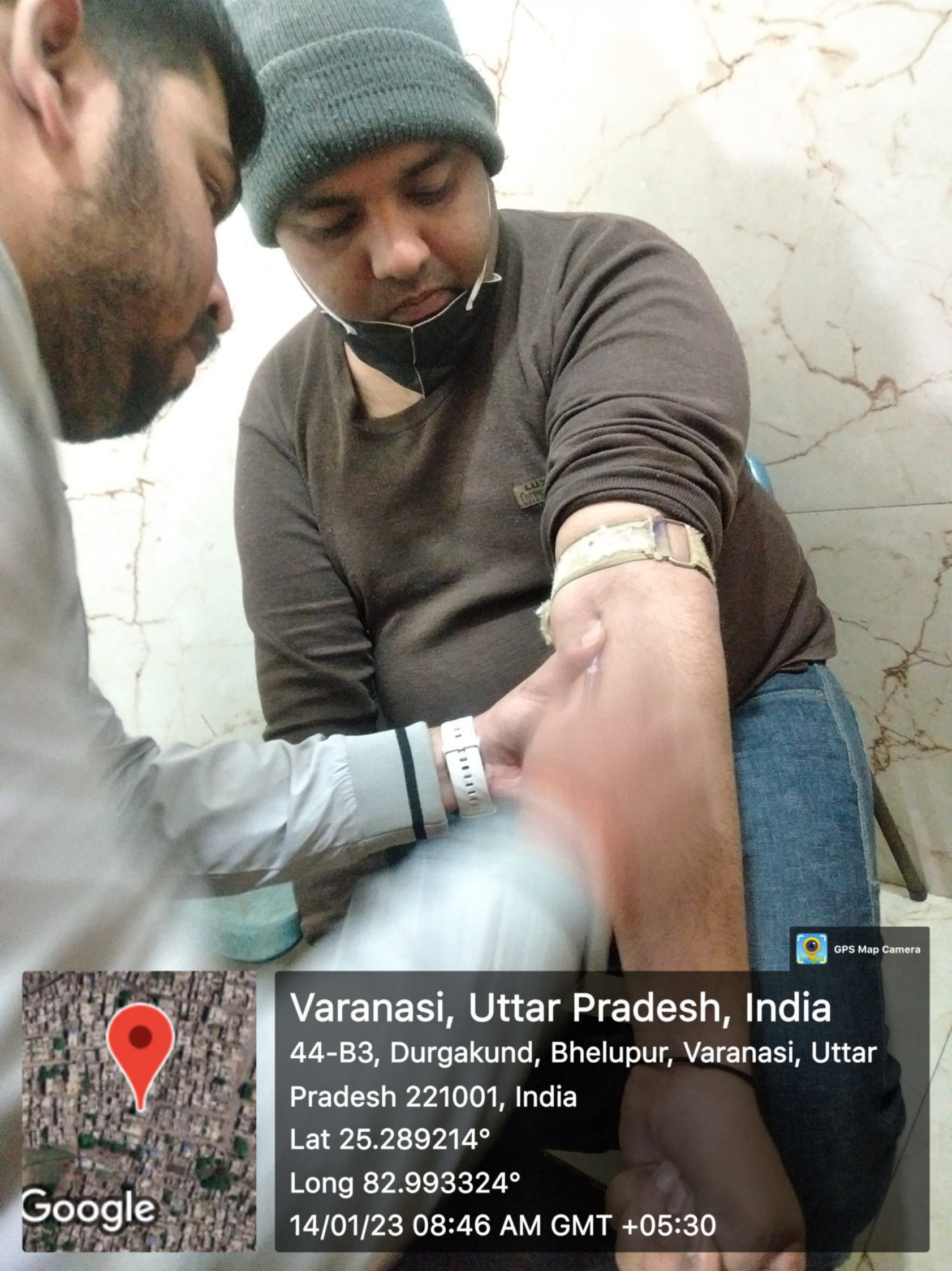Varanasi, Uttar Pradesh, India

44-B3, Durgakund, Bhelupur, Varanasi, Uttar Pradesh 221001, India

Lat 25.289254°

Long 82.993456°

14/01/23 09:48 AM GMT +05:30



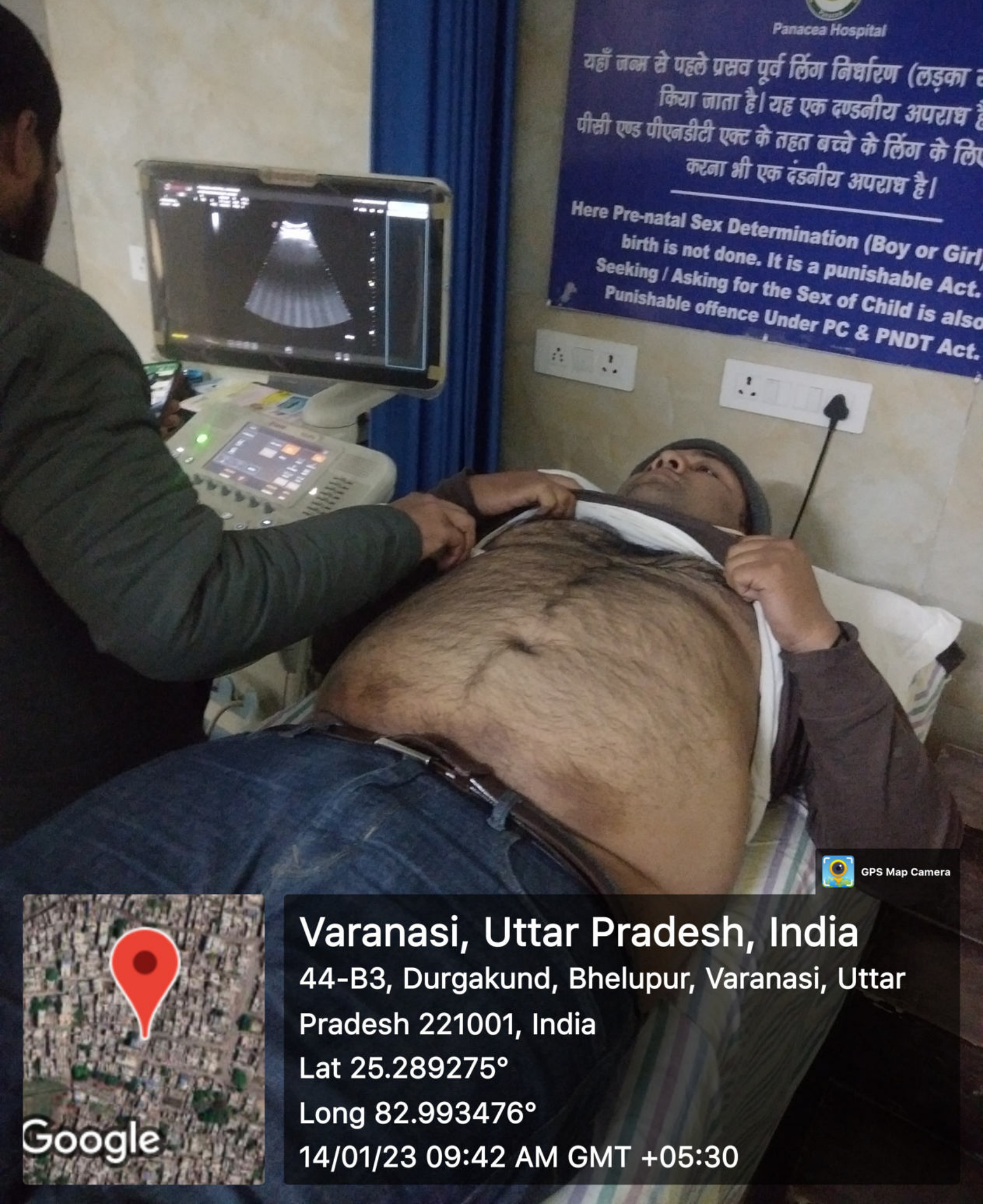Varanasi, Uttar Pradesh, India
44-B3, Durgakund, Bhelupur, Varanasi, Uttar Pradesh 221001, India
Lat 25.289214°
Long 82.993324°
14/01/23 08:46 AM GMT +05:30




Panacea Hospital

यहाँ जन्म से पहले प्रसव पूर्व लिंग निर्धारण (लड़का या लड़की) किया जाता है। यह एक दण्डनीय अपराध है। पीसी एण्ड पीएनडीटी एक्ट के तहत बच्चे के लिंग के लिए करना भी एक दंडनीय अपराध है।

Here Pre-natal Sex Determination (Boy or Girl) before birth is not done. It is a punishable Act. Seeking / Asking for the Sex of Child is also a punishable offence Under PC & PNDT Act.



GPS Map Camera



Varanasi, Uttar Pradesh, India

44-B3, Durgakund, Bhelupur, Varanasi, Uttar Pradesh 221001, India

Lat 25.289275°

Long 82.993476°

14/01/23 09:42 AM GMT +05:30

R
PA

HARE RAM BHASKAR 34Y/M 4587 O CHEST P.A. 14-Jan-23 09:54 AM

PANACEA HOSPITAL, KABIR NAGAR, DURGAKUND, VARANASI



Call Now - 1800-123-3070

PANACEA HOSPITAL

A shelter for many hearts A Home for many lives

(An ISO 9001:2008 Certified Organisation)

Lab Attached with CMC Vellore Under EQAS Scheme

AME: MR.HARE RAM BHASKAR

AGE/SEX: 34 YRS / MALE

EF BY: DR.ASHUTOSH MISHRA(MD)

DATE: 14/01/2023

X-RAY CHEST PA

BOTH LUNG FIELDS AND PLEURAE:

Both lungs show normal bronchovascular pattern.

Right & left hila are normal

No focal mass or calcification is seen

There is no evidence of any fluid in the both the pleural cavities.

Both domes of diaphragms are normal in position.

MEDIASTINUM:

Trachea is central in position.

Cardiac silhouette is of normal size and configuration.

No evidence of pericardial effusion.

No significant lymphadenopathy is seen.

Visualized skeleton is normal.

NO SIGNIFICANT RADIOGRAPHIC ABNORMALITY

DR. ALPANA PATHAK

MD, RADIOLOGY

REG. NO. 46465

REPORTED BY

DR. ALPANA PATHAK

MBBS (HONS, GOLD MEDALIST) PMCH , PATNA

MD RADIODIAGNOSIS (GOLD MEDALIST) IMS BHU

EX-SR, IMS BHU, VARANASI

Address : Kabir Nagar (Near Sanjay Shiksha Niketan), Durgakund, Varanasi

Mobile : 9554572190 / 9453837595 / Recpn. 9389994334

E-mail : dramishra@gmail.com, drpallaviojha@gmail.com, Website: www.piire.org