



(Medall Healthcare Pvt Ltd)

SASH SELF REFERRAL FORM

Stick the Barcode here

78393159

Customer Information

I, give consent to Medall Healthcare Pvt Ltd to perform the SASH Package investigation requested by me. I declare that **my age is 18 years or above 18 years** and I don't have any metal implants inside my body and don't have a pacemaker or stents. I am also aware that the blood tests are done in non-fasting (Random) Sample

Name: Mr/Ms/Mrs Borkar Anil

Company Name _____ Occupation _____

For Corporate customers only Employee id: _____ Department: _____

Date of Birth : 996607051992 or Age: 24 Gender: Male Female
D D / M M / Y Y Y Y

Contact Number : 9966777709 Pin Code _____

Email ID : _____

Vitals Observations (to be filled by Medall team)

Place of service : In store Camp – (mention Location) _____

Height 172 Cms _____ feet _____ Inches

Waist 31 Inches

Hip 38 Inches

Weight 61.7 Kgs

Fat 24.2 %

Visceral Fat 5.0 %

RM 1478 Cal

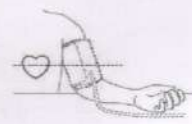
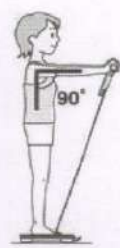
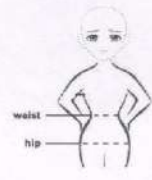
BMI 21.1

Body Age 31 Yrs

Systolic BP 120 mm/Hg

Diastolic BP 86 mm/Hg

(Always Ensure that the customer is relaxed and in sitting position while doing BP check)



Clinical History / Medicines Taken

Blank area for clinical history and medicines taken.

	Use Tobacco Products	Drink Alcohol
Never	<input type="checkbox"/>	<input type="checkbox"/>
Some days	<input type="checkbox"/>	<input type="checkbox"/>
Daily	<input type="checkbox"/>	<input type="checkbox"/>

Check in the appropriate box

Date _____ Medall Employee Name & Id: _____

Report Language option (English is default) Hindi Kannada Malayalam Odiya Tamil Telugu

How did you come to know about SASH Store Communication Social Media Friends/Family Theatres Radio Posters Others

I have verified and agree with all the data in this sheet. Customer Signature



SPECTS WORLD™

"A Complete Multi Branded Optical Store for All Interests & Age Groups"

D.No. 26-6-5/1, Ganjamvari Street, Main Raod, Big Masjid Backside Road, KAKINADA - 533 001.
www.spectsworld.com

Contact Us : 90633 34444
0884 - 6696669

Date : 12.3.22

Name : B. Anil Age: 29 Gender : M/F

PRESCRIPTION

RIGHT EYE

	Sph.	Cyl.	Axis	VA
Distant Vision	2.25			6/6
ADD				N/A

LEFT EYE

	Sph.	Cyl.	Axis	VA
Distant Vision	2.25			6/6
ADD				N/A

IPD

- Lens Advise
- Single Vision
 - Resilens
 - Hard coat
 - White
 - High refractive index
 - Kryptok
 - Polycarbonate
 - Anti reflection coat
 - Sp2
 - Asperic
 - D-Bifocal/Executive
 - Glass
 - Blue cut
 - Photo grey
 - Digital
 - Progressive
 - Polarized
 - UV Protection
 - Special Tint
 - Contact Lens

Special Instructions : For Constant use / Near work only

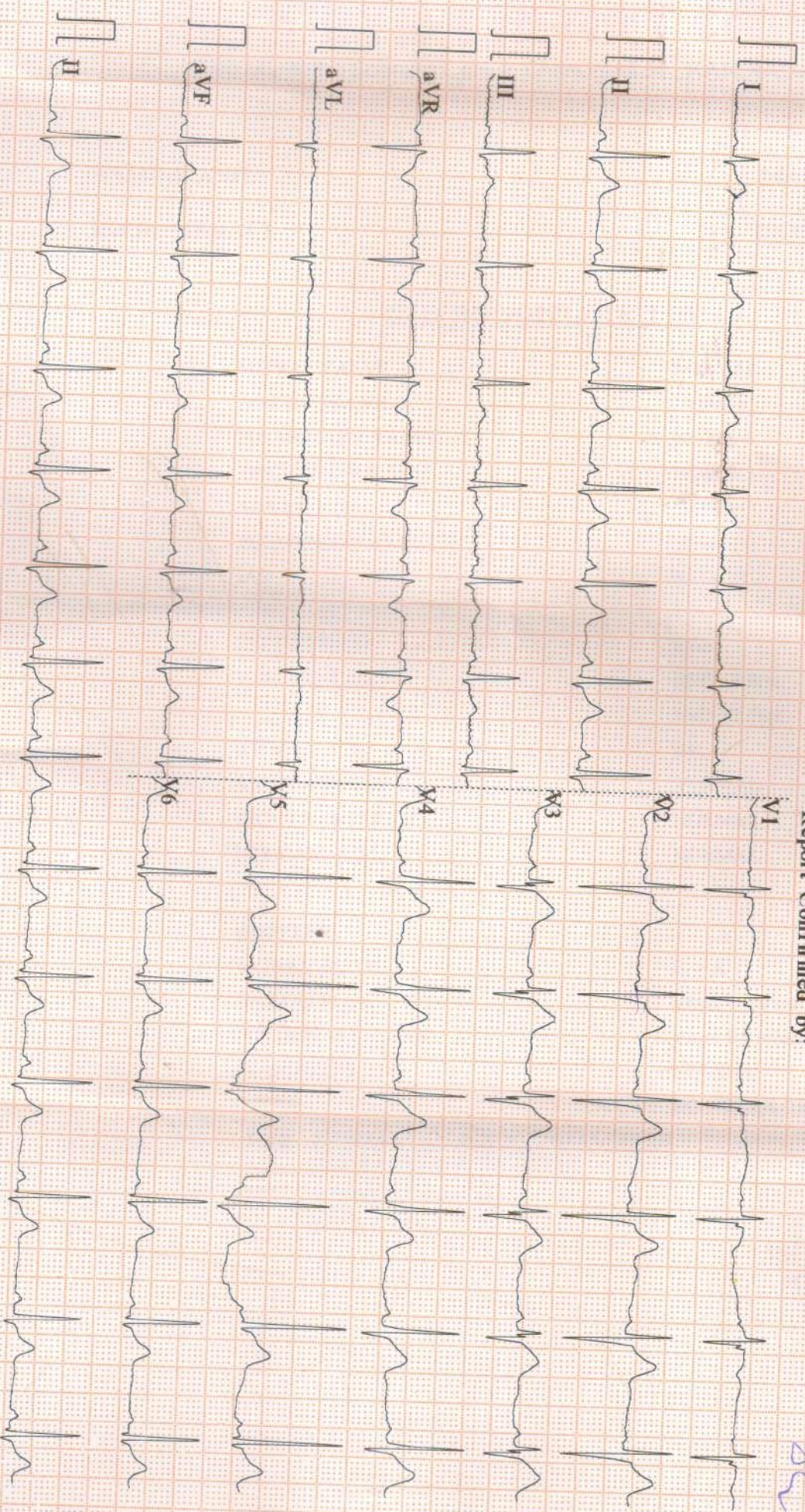
12-03-2022 02:18:31 PM
ID: 498
BANIL
Male 29 Years

HR : 76 bpm
P : 95 ms
PR : 142 ms
QRS : 90 ms
QT/QTc : 338/382 ms
P/QRS/T : 64/75/50 °
RV5/SV1 : 1.773/0.780 mV

Diagnosis Information:
Sinus Arrhythmia
Poor R Wave Progression (V3)
Slight ST Elevation (V4)

Report Confirmed by:

Dr. E. Suman
M.B.B.S. D.C. (Genl)
Clinical Cardiologist
Regd. 69460
8500008097



0.67 45Hz AC50 25mm/s 10mm/mV 2*5s+1r 76 SE 1200Express V2.01 SEMIP 1.7 HRUDEYAA HEARTCARE KK

HRUDEYAA HEART CARE

Near Mamatha Scanning Center, Bhanugudi Jn., KAKINADA

NAME: B.ANIL

MALE /29YEARS

Ref Dr: MEDALL

DATE-12-03-2022

2D ECHO/DOPPLER STUDY

MITRAL VALVE	NORMAL
AORTIC VALVE	NORMAL
PULMONARY VALVE	NORMAL
TRICUSPID VALVE	NORMAL
AORTA:	1.9 cm,
PULMONARY ARTERY:	NORMAL
IAS:	INTACT
IVS:	1.2cm,
LEFT ATRIUM	2.0cm,
LEFT VENTRICLE	EDD : 3.9cm, EF :65%
	ESD : 2.5cm
RWMA:	NIL
RIGHT ATRIUM	NORMAL
RIGHT VENTRICLE	NORMAL
PERICARDIUM	NORMAL

DOPPLER

MITRAL FLOW	E > A
AORTIC FLOW	Vmax 1.2m/sec.,
PULMONARY FLOW	Vmax 0.9 m/sec.,
TRICUSPID FLOW	NORMAL
COLOR DOPPLER :	NO MR/ AR /TR

IMP NORMAL CARDIAC CHAMBERS
NORMAL LV FUNCTION
NORMAL VALVES
NO RWMA

Dr. SUMALATHA
M.B.B.S., D.C. (Card)
(CELL: 7075575437)

ADIVISION OF COMPUTED RADIOGRAPHY

ANIL.V

Date: 12-03-2022

Age / Sex: 29 Y / M

Ref: MEDALL DIAGNOSTICS

X - RAY CHEST – (PA View)

- * Trachea midline position.
- * Cardiac silhouette appears normal in size and density.
- * Mediastinum and bilateral hila appear normal.
- * Bilateral lung fields appear normal.
- * Bilateral hemi diaphragms and costo-phrenic angles appear normal.
- * Rib cage is normal.

IMPRESSION: No obvious abnormality.

Note: These are COVID-19 pandemic days and no place is secure as also the diagnostic Centre.

For clinical correlation & further evaluation

Dr.S.BHASKARA RAO, MD
Consultant Radiologist
Regd. No:72607


Dr.A.CHENNA RAYUDU, DMRD
Consultant Radiologist
Regd. No: 97975

This is a professional opinion only for the interpretation of referring doctors. This report is not valid for medico- legal purpose

DIVISION OF 4D ULTRASOUND & COLOUR DOPPLER

V.ANIL

Date: 12-03-2022

Age / Sex: 29 Y / M


Ref: MEDALL DIAGNOSTICS

ULTRA SONOGRAPHY – ABDOMEN & PELVIS

- LIVER:** Normal in size (12.6 cm) & echotexture. No focal / diffuse mass lesions.
No Intrahepatic / extrahepatic biliary radicle dilatation.
- PV :** Normal in calibre.
- GALL BLADDER:** Normally distended. No calculi / wall thickening.
- CBD:** Normal in calibre
- PANCREAS:** Normal in size & echotexture. No dilatation of Main pancreatic duct.
No parenchymal / ductal calcifications.
- SPLEEN:** Normal in size (9.0 cm) & echotexture.
- KIDNEYS:** Right kidney: 9.6 X 4.1 cm, Left kidney: 10.8 X 4.6 cm
Normal in size & echotexture.
Normal cortico-medullary differentiation maintained.
No calculi / dilatation of collecting system.
- RETROPERITONEUM:** Normal.
- URINARY BLADDER:** Well distended. Normal wall thickness. No calculi / no focal masses.
- PROSTATE:** Normal in size & echotexture. No focal lesion.
- BOWEL:** Bowel appears grossly normal.
No free fluid in peritoneal cavity. No Pleural effusions.
- IMPRESSION:** **No obvious abnormality.**

Note: These are COVID-19 pandemic days and no place is secure as also the diagnostic Centre.
For clinical correlation & further evaluation

Dr.S.BHASKARA RAO, MD
Consultant Radiologist
Regd. No:72607


Dr.A.CHENNA RAYUDU, DMRD
Consultant Radiologist
Regd. No: 97975

This is a professional opinion only for the interpretation of referring doctors. This report is not valid for medico- legal purpose