

Computerised Lab  
X: M  
SIN/2021

ORT

BGT/20

डॉ. बी. एम. शरणागत  
एम.डी. (मेडिसिन)

रजि.नं. - 4612  
कार्डियो - डायबेटोलॉजिस्ट  
एवं परामर्श चिकित्सक

रजि.क्र.-NHA/REG./BGT/2012/21  
क्रिटिकल केंद्र युनिट I.C.C.U. सुविधायुक्त

**आयुष्मान हॉस्पिटल**  
एंड डायग्नोस्टिक रिसर्च सेंटर

सर्किट हाउस रोड, बालाघाट 07632-241070 | समय-सुबह 10 बजे से संध्या 8.00 बजे तक

Name MR. DILIP KUMAR PARTE R/O

Date 05/06/2023

General Physical Examination

Date of Examination 05/06/2023

Name MR. DILIP KUMAR PARTI Age 36 DOB 14/10/1986 Sex M

Referred by MEDIWHEEL

Photo ID AADHAAR CARD ID

Ht 169 (CM)

Wt 76 (kg)

Chest (Expiration): 90 (cm)

Abdomen Circumference 98 (cm)

Blood Pressure 130/80 mm Hg

PR 17 /min

RR 73 /min

Temp 98.6°

BMI 20.1%

Eye Examination Normal (RG/LE) 6/6/6

Other: Nil

On examination he/she appears physically and mentally fit: Yes/No


Signature of Examinee: [Signature] Name of Examinee: MR. DILIP KUMAR PARTE

Signature Medical Examiner: [Signature] Name Medical Examiner

Dr. B.M. SHARNAGAT  
M.D. (Medicine) Regd No. 4612  
AYUSHMAN HOSPITAL  
& Diagnostic Research Center  
BALAGHAT (M.P.) 481001

|| उपलब्ध सुविधाएं ||

- क्रिटिकल केंद्र युनिट/आई.सी.सी.यू., सेंट्रल ऑक्सीजन पाइप लाईन युक्त
- फेफड़ों के कार्य क्षमता की कम्प्यूटराईज्ड जांच (P.F.T.)
- मल्टीपैरा, पल्स ऑक्स, डीप्रिब्रीलेटर एवं वेंटीलेटर सुविधाएं
- फिजियोथेरेपी युनिट एवं डायटिशियन परामर्श।
- कम्प्यूटराईज्ड ई.सी.जी., टी.एम.टी., होल्टर मॉनिटरिंग व अल्ट्रासोनो नेबुलाईजेशन
- डायबीटिज, अस्थमा एवं किडनी क्लिनिक।
- एक्सरे, पैथालॉजी, मेडिकल स्टोर्स व कैंटीन सुविधा
- मनोचिकित्सक, चर्मरोग, कैंसर एवं किडनी विशेषज्ञ द्वारा परामर्श - प्रति रविवार
- सेंट्रली एयर क्लूड एवं ए.सी.युक्त प्राइवेट एवं जनरल वार्ड
- 24 घंटे इमरजेन्सी सेवा, एम्बुलेन्स एवं विद्युत जनरेटर व्यवस्था।



**ULTRASOUND REPORT**

Name - MR. DILIP PARTE

Age - 36 Yrs/M

Refd. By - SELF

Date - 05.06.2023

**LIVER :** The liver is normal in size and shape. It shows normal parenchymal echo texture. The IHBR, IHPR and porta hepatis appear normal.

There is no e/o any lesion.

**GALLBLADDER :** Normal. There is no e/o evidence of calculi.

**PANCREAS :** Normal in size and shows normal echotexture.

**SPLEEN :** Spleen is normal in size and shows homogenous echo texture.

**KIDNEYS :** Both Kidneys are normal in size, shape, contour and in position.

There is no renal calculi and no pelvicalyceal dilatation.

**LEFT KIDNEY MEASURES :** 6.7 X 5.2 CM

**RIGHT KIDNEY MEASURES :** 6.2 X 4.7 CM

**PROSTATE :** The prostate is normal in size and shows normal echo texture.

There is no e/o free Fluid in pelvis.

Urinary bladder is well filled with smooth and regular outline.

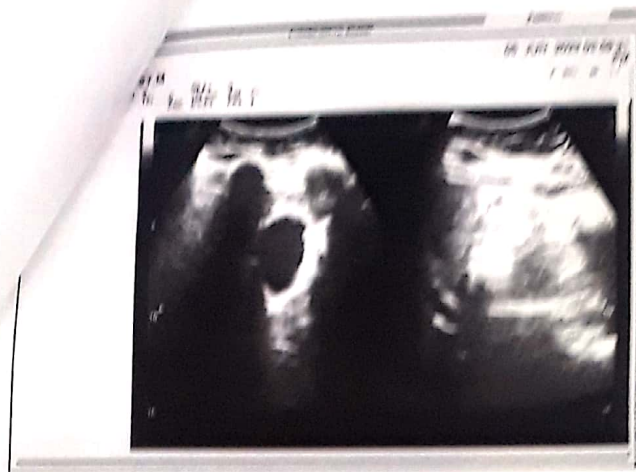Ureters are not dilated.

**IMPRESSION :-** NORMAL STUDY OF ABDOMEN.

A handwritten signature in black ink, appearing to be 'B.M. Sharnagat', is written above the printed name.

Dr. B.M. SHARNAGAT  
**Dr. B.M. Sharnagat (MD Medicine)**  
AYUSHMAN HOSPITAL  
& Diagnostic Research Center  
BALAGHAT (M.P.) 481001

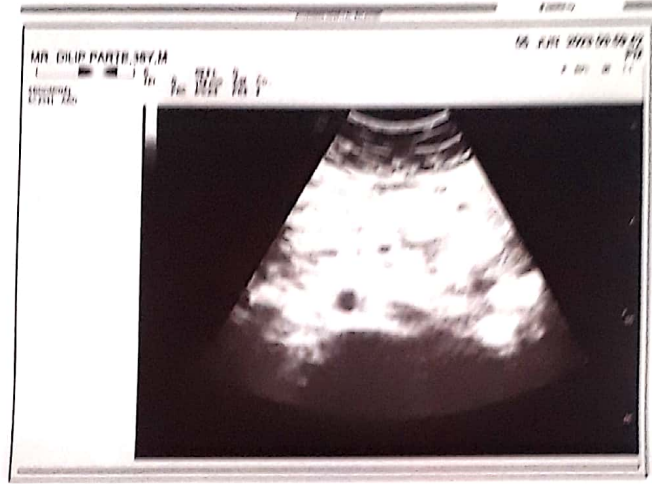




SAR

10/23

TV AN

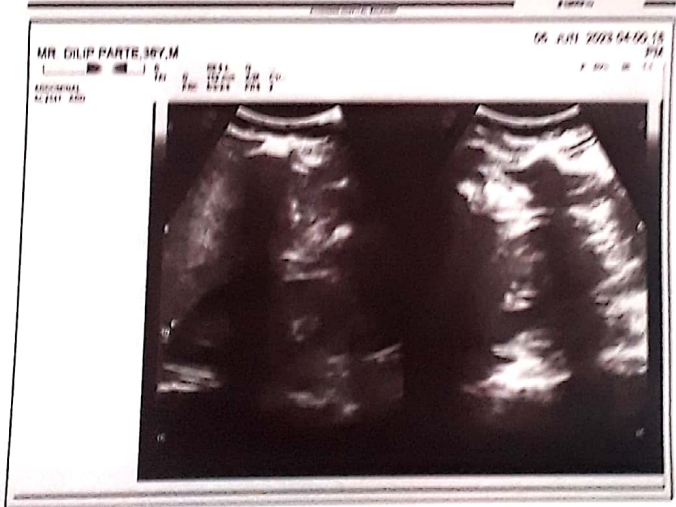

mmu

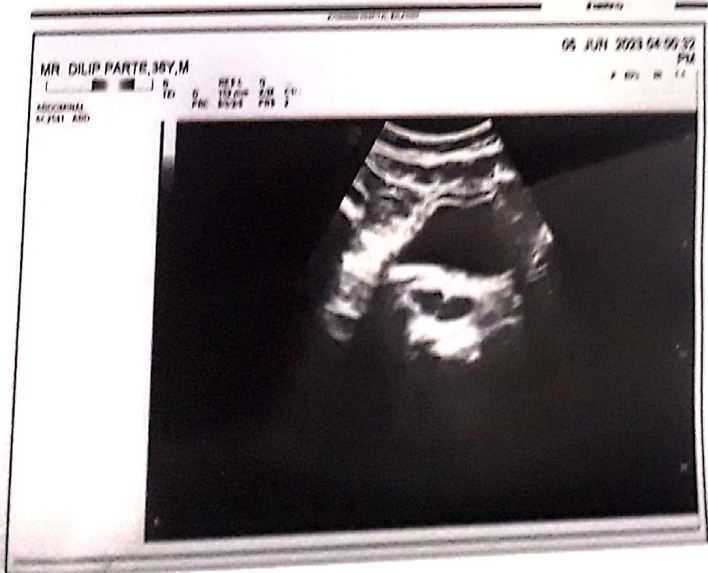mmu

mmu

mmu



(No



Dr. D.



**2D ECHOCARDIOGRAPHY AND DOPPLER REPORT**

Name -MR. DILIP PARTE

Age - 36Yrs/M

Refd By - SELF

Date - 05.06.2023

**M-Mode & Essential Measurements :-**

Heart Rate :74Bpm	LVID(D) : 41 mm	MV Annulus :24mm	RVID(d) : 34 mm
Aortic Root :31 mm	LVID(S) : 24 mm	TV Annulus :22mm	IVC : 16 mm
Left Atrium : 35mm	IVSd (D) : 12 mm	AO Annulus :17mm	Mitral-Epss : 08 mm
LVEF : 60 %	LVPWd(D):10mm	PV Annulus :21mm	TAPSE : 16 mm

**2D Echo Findings :-**

RWM(LV) : NORMAL  
 VALVES : NORMAL  
 CHAMBERS : NORMAL SIZED  
 IAS/IVS : INTACT  
 CLOT/VEGETATION : NIL  
 PERICARDIAL EFFUSION : NIL  
 PLEURAL EFFUSION : NIL

**Doppler Study :-**

VALVES	Peak Gradient (mm of Hg)	Mean Gradient (mm of Hg)	Valve area (Normal Range)	Grade of Regurgitation
Mitral Valve	--	--	4.0-6.0	NIL
Aortic Valve	--	--	2.5-4.0	NIL
Tricuspid Valve	--	--	7.0-9.0	NIL
Pulmonary valve	--	--	2.0-3.0	NIL

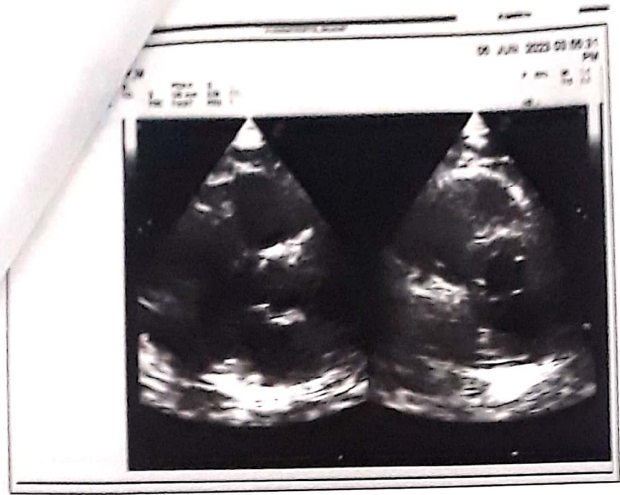
Estimated PASP by TR jet = 25 mm of Hg.

**FINAL DIAGNOSIS :-**

NO RWMA/ LVDD  
 NORMAL VALVES,  
 NORMAL LV SYSTOLIC FU  
 NORMAL RV FUNCTION.

Dr. B.M. SHANNAGAT  
 Dr. B.M. Shannagat (MD Medicine)  
 AYUSHMAN HOSPITAL  
 & Diagnostic Research Center  
 BALAGHAT (M.P.) 481001



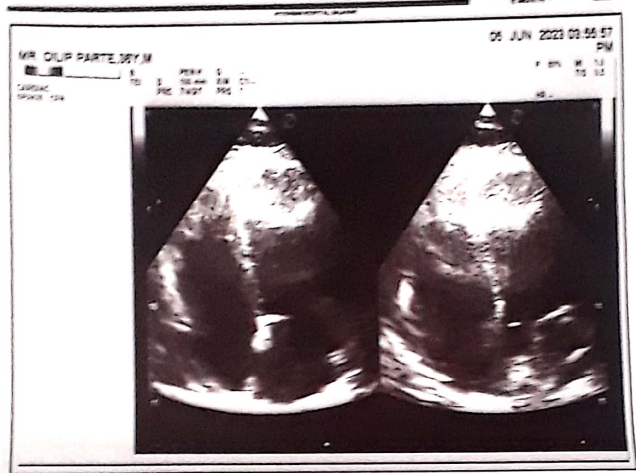


Auto An

t

Y

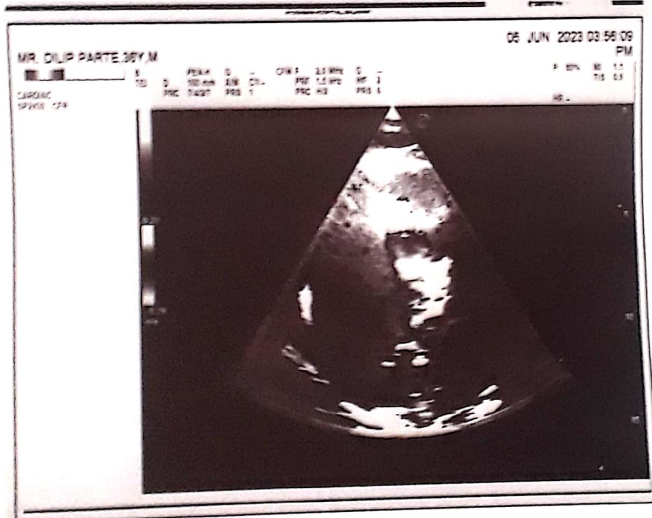
t



X  
X  
X  
X  
%  
%  
%

E

X  
%  
f  
p  
E  
%  
f

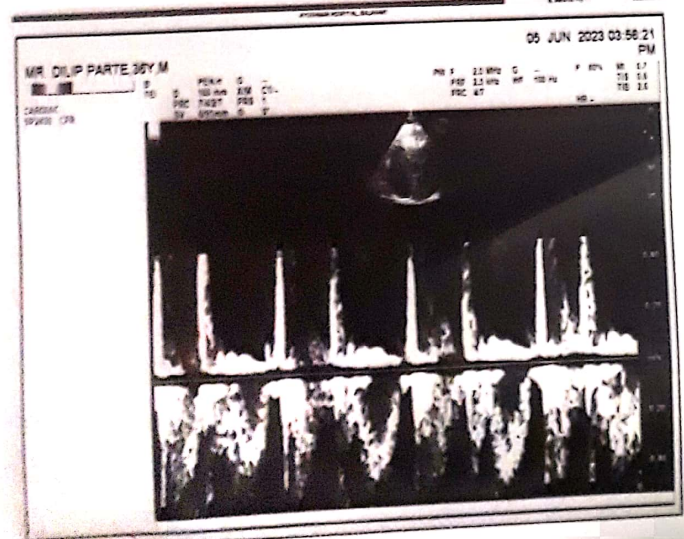


X  
f

9

f

S



Signature Medical Ex-

REGD.No. : NHA/REG/BGT/2012/21

किटिकल केयर युनिट I.C.C.U. सुविधा युक्त

आयुष्मान हॉस्पिटल

एण्ड डायग्नोस्टिक रिसर्च सेंटर

सर्किट हाऊस रोड, बालाघाट 07632:241070

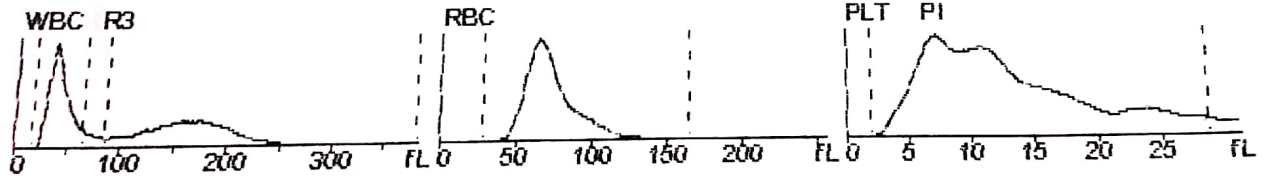
PATHOLOGY REPORT

• Auto Analyzer • Hematology Analyzer A.B.G. • Computerised Lab

CBC Report by the analyzer

ID: 2 Mode: Whole Time: 05-06-2023 11:25  
Name: MR. DILIP PARTE Gender: Male Age: 36 Years  
Chart No.: Dept.: PATHOLOGY Bed No.:

Parameter	Result	Ref. range
WBC	4.3 x 10 <sup>9</sup> /L	4.0 - 10.0
Lymph#	1.8 x 10 <sup>9</sup> /L	0.8 - 4.0
Mid#	0.2 x 10 <sup>9</sup> /L	0.1 - 1.5
Gran#	2.3 x 10 <sup>9</sup> /L	2.0 - 7.0
Lymph%	42.7 % H	20.0 - 40.0
Mid%	5.4 %	3.0 - 15.0
Gran%	51.9 %	50.0 - 70.0
HGB	12.9 g/dL	12.0 - 16.0
RBC	5.03 x 10 <sup>12</sup> /L	4.00 - 5.50
HCT	35.7 % L	40.0 - 54.0
MCV	71.1 fL L	80.0 - 100.0
MCH	25.6 pg L	27.0 - 34.0
MCHC	36.1 g/dL H	32.0 - 36.0
RDW-CV	15.1 %	11.0 - 16.0
RDW-SD	42.2 fL	35.0 - 56.0
PLT	134 x 10 <sup>9</sup> /L	100 - 300
MPV	10.0 fL	6.5 - 12.0
PDW	15.9	9.0 - 17.0
PCT	0.134 %	0.108 - 0.282



Sender: DR. B. M. SHARNAGAT Tester: L. T. BASANT TANDE Checker: DR. B. M. SHARNAGAT

Dr. B. M. SHARNAGAT  
M.D. (Medicine) Regd. No. 4612  
I.C. Pathologist/Technician  
(Ayushman Hospital, Balaghat)  
BALAGHAT (M.P.) 481001

This Report is not valid for MLC purpose.  
This Report is only for Physician's help to confirm the diagnosis.





कैम्पेक्स केयर युनिट I.C.C.U सुविधा युक्त

आयुष्मान हॉस्पिटल

एण्ड डायग्नोस्टिक रिसर्च सेन्टर

सक्ति हाउस रोड, बालाघाट 07632-241070

REGD No : NHA/REG/BGT/2012/21

PATHOLOGY REPORT

• Auto Analyzer • Hematology Analyzer A.B.G. • Computerised Lab

NAME : MR. DILIP KUMAR PARTE AGE : 36Yrs. SEX : M
REF. BY : Dr. B. M. SHARNAGAT (M.D.) DATE : 05/06/2023

BIOCHEMISTRY

Table with 4 columns: TESTS, RESULTS, UNITS, REF. RANGE. Rows include Lipid Profile (S. Cholesterol, Triglycerides, HDL, LDL, VLDL, Ratios), KFT (Creatinine, BUN), LFT (Bilirubin, SGPT, SGOT, Phosphatase, Proteins, GGT), B.SUGAR, and S.URIC ACID.

SEROLOGY

HIV I&II :NON-REACTIVE
HbsAg :NON-REACTIVE
COTININE TEST :NEGATIVE
(Qualitative)

HbA1C 5.2 %

Nondiabetic :4.5 -6.2
Good Control: 6.0 -7.0%
Fair Control: 7.0 -8%
Poor Control: >8%

(Action Suggested)

ESR Method

:10 1st Hr westangren

Dr. B.M. SHARNAGAT
(M.C. Pathologist/Technician)
Ayushman Hospital
Balaghat (M.P.) 481001

not valid for MLC purpose.

**आयुष्मान हॉस्पिटल**

एण्ड डॉयग्नोस्टिक रिसर्च सेन्टर

सर्कित हाऊस रोड, बालाघाट 07632-241070

**PATHOLOGY REPORT**

• Auto Analyzer • Hematology Analyzer • A.B.G. • Computerised Lab

NAME : MR. DILIP KUMAR PARTE

AGE : 36Yrs. SEX : M

REF. BY : Dr. B. M. SHARNAGAT (M.D.)

DATE : 05/06/2023

**BIOCHEMISTRY**

TEST	RESULTS	UNITS	REF. RANGE
<b>BLOOD SUGAR</b>			
B.SUGAR (f)	:86	mg/ dl	60-100
(p.p)	:125	mg/dl	120-160
METHOD : GOD-POD			

Blood group A  
Rh Type Positive

**STOOL EXAMINATION**

Stool for Routine & Microscopic Examination : Normal

Stool for Occult blood : Negative

**THYROID HORMONE**

TSH	3.5	uIU/mL	0.3 - 5.0
T3	0.65	ng/mL	0.6-1.8
T4	6.6	ug/dL	4.5-11.6

**URINE ANALYSIS REPORT (By urometer 120 analyzer)**

**PHYSICAL EXAMINATION**

Colour : pale Yellow  
Quantity : 10ml  
Apperance : clear

**CHEMICAL EXAMINATION**

Sugar : nil  
Bile Pigment : nil  
Nitrite : nil  
Protein : nil  
Bilirubin : nil  
Ketone : nil  
Albumin : nil  
Urobilinogen : Normal 0.01 mg/ml  
Specific gravity : 1.015 1.010-1.030  
Reaction(pH) : 5.5 (Acidic 3-6, Alkaline 8-10)

**MICROSOPIC EXAMINATION**

Pus(WBCs) Cells : NIL/ hpf  
RBC : nil/hpf  
Crystals : Absent  
Spermatozoa : Absent  
Epithelial Cells : Absent  
Bactria : Absent

Dr. B. M. SHARNAGAT  
M.D (Medicine) Reg. No 4612  
AYUSHMAN HOSPITAL  
& (Ayushman Hospital) Balaghat  
BALAGHAT (M.P.) 481001

• This Report is not valid for MLC purpose.

• This Report is only for Physician's help to confirm the diagnosis.



Signature of Examinee.....  
Examiner:.....

आयुष्मान हॉस्पिटल  
एण्ड डायग्नोस्टिक रिसर्च सेन्टर  
Regd.No. : NHA/REG/BGT/2012/21

NAME - Mr .DILIP KUMAR PARTE

Age - 36Y/M

R / By -MEDIWHEEL

Date - 05/06/23


X- RAY CHEST ( PA VIEW)

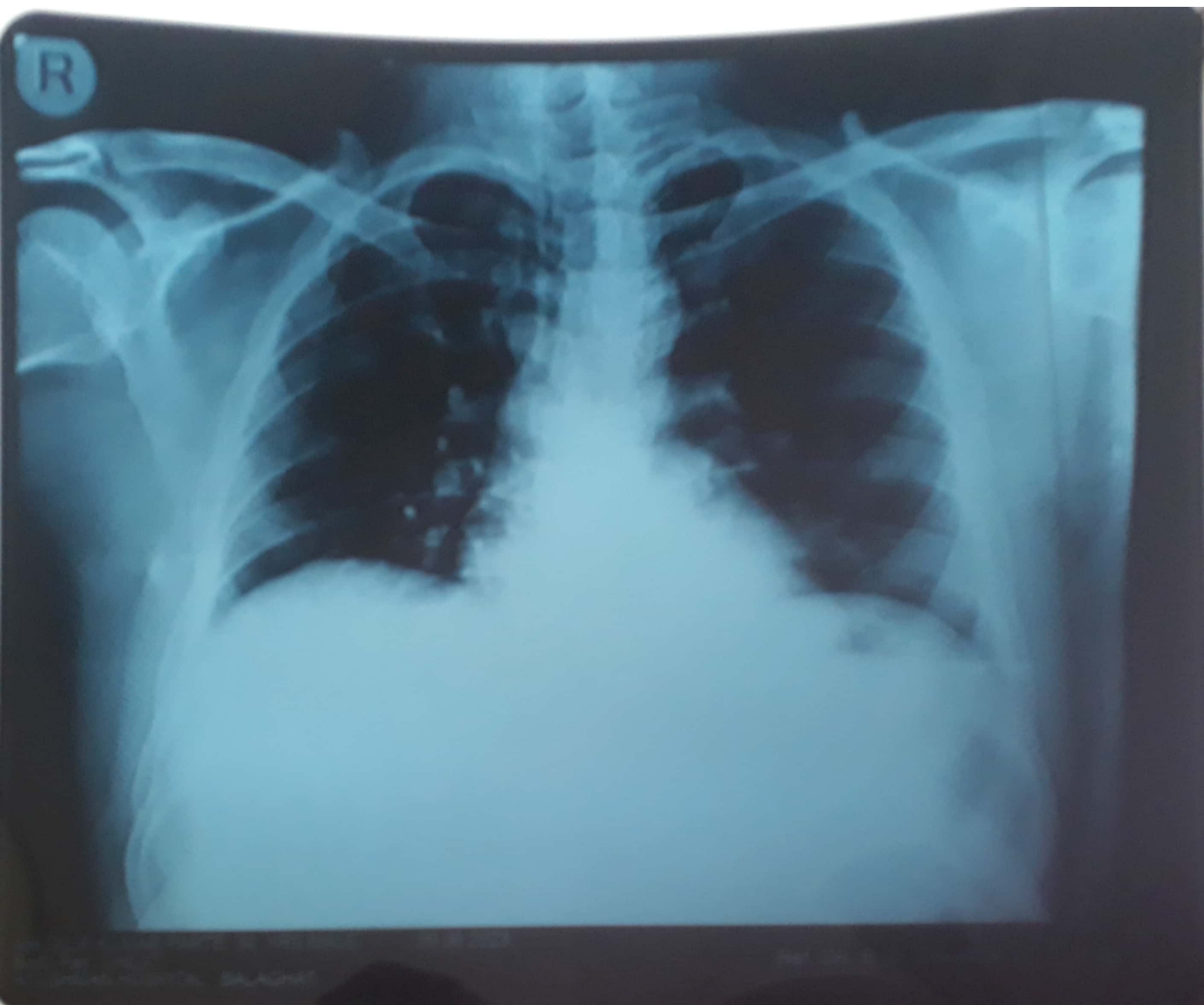
- \*Bony cage - Normal.
- \*Trachea - Normal.
- \* Heart - Position --- Normal.  
C-T ratio---Within normal limits.  
Cardiac borders--- Normal.  
Specific chamber enlargement---None.
- \*Aorta- Position---Normal.
- \*Mediastinum- Relative Position ---Normal.  
Any Lesion---None.
- \*Angles- Cardiophrenic angles---Clear.  
Costophrenic angles---Clear.
- \*Pleura- Normal.
- \*Lungs- .Lung apices seen clear.  
.Both lungs seen clear.  
.No evidence of any focal active lesion in lung fields.  
.Broncho-vascular markings appear normal.
- \*Hilar shadows- Normal.
- \*Diaphragms- Relative position---Normal.  
Outline---Normal.

OPINION

"X-RAY CHEST APPEARS NORMAL."  
"NO ABNORMALITY DETECTED."

Thanks for referral.

  
Dr.B.M.SHARNAGAT  
M.D.(Medicine) Reg. No 4612  
AYUSHMAN HOSPITAL  
& Diagnostic Research Center  
BALAGHAT (M.P.) 481001  
Stamp





भारत सरकार  
GOVERNMENT OF INDIA



डिप कुमार परले  
Dip Kumar Parle  
Year of Birth / Year of Birth: 1986  
पुरुष / Male



0951

आधार - आम आदमी का अधिकार

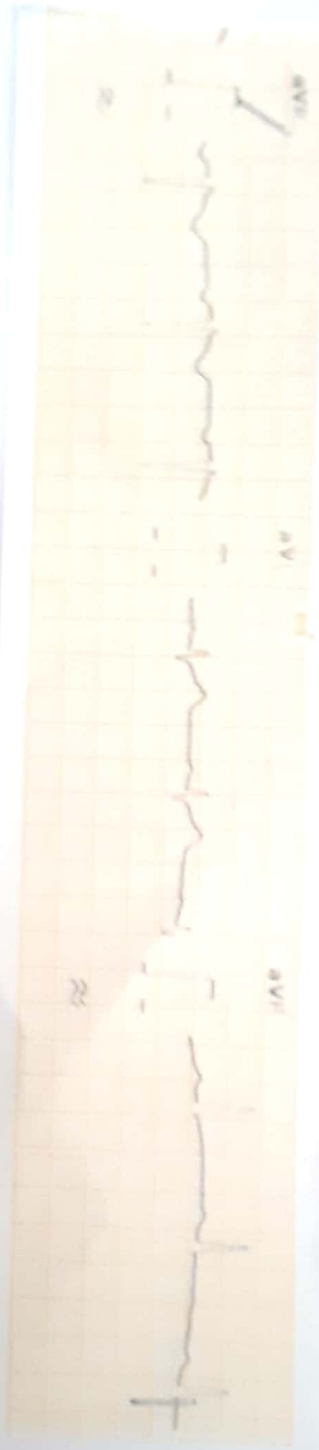
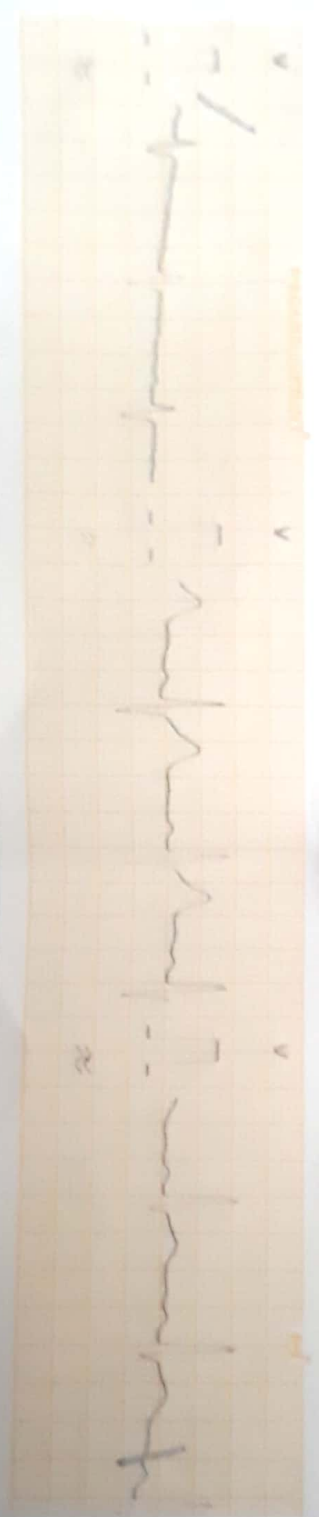

Dr. B.M. SHARNAGAT  
M D (Medicine) Regd No 4612  
AYUSHMAN HOSPITAL  
& Diagnostic Research Ceter  
BALAGHAT (M.P.) 481001

भारतीय विज्ञान संस्थान प्राधिकरण  
INDIAN INSTITUTE OF SCIENCE EDUCATION AND RESEARCH

पता  
S/O. भारत लाल परले, एमएच  
784- भग 1, डॉ. भाभासाहू  
नं. 6 का घोडादंगरी, बेतुल,  
480447

Address  
S/O Bharat Lal Parle, S/E  
784- Bhag 1, Dr. Bhabhasah  
Ward No. 6, Tah  
Ghodadongri, Betul, Saml  
Madhya Pradesh, 480447

एन. सी. सी. नं. 102 /  
Bengaluru, 560011



NAME - MR. DILIP KUMAR DADTU  
Age 11 36/11/17

Date - 5/06/2023

*[Signature]*  
Dr. B. M. SHARNAGAT  
MD (Medical) Part No 4812  
AYUSH M. ... HITAL  
& Diagnostic Res. ... h Ceter  
BALAGHAT M. ... 181301