

679243



Park Hospital

GROUP SUPER SPECIALITY HOSPITAL

MRS. POOJA AGARWAL
29 Y/F

18/2/23

BP- 90/60
Weight- 57kg
Routine eyes checkup

Height- 154cm
6/6 unaddeed
6/6

NV
N6
N6

Colour Vision - Normal (BE)

Fundus - WNL



(This is only professional opinion and not the diagnosis, please correlate clinically)

Q Block, South City -II, Sohna Road, Sector-47, Gurgaon, Haryana
Ph.: 0124-4900000 (100 Lines), Toll Free No. : 1800-102-6767, Mob.: 62 62 82 82 35, Email: customercare@parkhospital.in

PARK GROUP OF HOSPITALS : West Delhi - Gurugram - Faridabad - Sonapat - Panipat - Karnal - Ambala - Patiala - Behror - Jaipur



Has come for routine check up.

KICID Hypothyroidism on eltroxin

O/E

Parent is afebrile.

P° 2°

PR - 80/m.

BP - 90/60 mmHg.

Chest - BIL vesicular B/S

crs - S1 S2 ⊕

Adm

1. Remains with reports.

[Signature]



Cert. No. H-2016-0369 Cert. No. MC-4830

(This is only professional opinion and not the diagnosis, please correlate clinically)

Q Block, South City -II, Sohna Road, Sector-47, Gurgaon, Haryana
Ph.: 0124-4900000 (100 Lines), Toll Free No. : 1800-102-6767, Mob.: 62 62 82 82 35, Email: customercare@parkhospital.in

PARK GROUP OF HOSPITALS : West Delhi - Gurugram - Faridabad - Sonipat - Panipat - Karnal - Ambala - Patiala - Behror - Jaipur

the **health** care providers

the **health** care providers





Dental

Vitals :

Chief Complaints :

H/O Present Illness :

O/E Stain ++, Calculus +

Past History :

Acidic

Sealing & Polishing

Investigation :

Drug Allergies : (if any)

Treatment :



Gurgaon

Q Block South City 11, Sohna Road, Main Sector-47, Gurgaon, Haryana Ph.: 0124-49000000 Fax : 0124-2218733
E-mail : parkmedicenters@gmail.com

● West Delhi ● South Delhi ● Faridabad ● Panipat ● Karnal

the **health** care providers

the **health** care providers





For medical exam

Vitals :

Chief Complaints

Ear

TM



H/O Present Illness :

Past History :

Oral - Poor ph wall - clear.

Nose - Caudal deviation (+) to R side.

Drug Allergies : (if any)

Blc nasal cavity - clear.

Treatment :

Adv

P.T.A.

Q D
18/2/23





DEPARTMENT OF PATHOLOGY

Patient Name : Mrs. POOJA AGARWAL
 MR No : 672243
 Age/Sex : 29 Years 4 Months 16 Days / Female
 Type : OPD
 TPA/Corporate : MEDIWHEEL PVT LTD

Bill Date : 18/02/2023
 Reporting Date : 18/02/2023
 Sample ID : 101343
 Bill/Req. No. : 24043733
 Ref Doctor : Dr.RMO

Test	Result	Bio. Ref. Interval	Units	Method
LFT (LIVER FUNCTION TEST)				
LFT				
TOTAL BILIRUBIN	0.7	0 - 1.2	mg/dL	DIAZO
DIRECT BILIRUBIN	0.3	0 - 0.4	mg/dL	DIAZO
INDIRECT BILIRUBIN	0.4	0.10 - 0.6	mg/dL	CALCULATED
SGOT (AST)	20	0 - 45	U/L	IFCC WITHOUT
SGPT (ALT)	22	0 - 45	U/L	IFCC WITHOUT
ALKALINE PHOSPHATASE	110	30 - 170	IU/L	MODIFIED IFCC
TOTAL PROTEINS	7.4	6.4 - 8.0	g/dL	BIURET
ALBUMIN	4.3	3.3 - 5.5	g/dL	BCG DYE
GLOBULIN	3.1	2.3 - 4.5	g/dL	CALCULATED
A/G RATIO	1.39	1.1 - 2.2		CALCULATED

***** END OF THE REPORT *****



Sample no.

Dr. SONIA KUMARI
 MBBS, MD (PATHOLOGY) Gold medalist

Dr. PRADIP KUMAR
 Consultant (Microbiology)

Dr. NISHA TIWARI
 MBBS, MD (Microbiology)

USER NM AMIT1



(This is only professional opinion and not the diagnosis, please correlate clinically)

Cert. No. H-2016-0369 Cert. No. MC-4830

Q Block, South City -II, Sohna Road, Sector-47, Gurgaon, Haryana

Ph.: 0124-4900000 (100 Lines), Toll Free No. : 1800-102-6767, Mob.: 62 62 82 82 35, Email: customercare@parkhospital.in

PARK GROUP OF HOSPITALS : West Delhi - Gurugram - Faridabad - Sonapat - Panipat - Karnal - Ambala - Patiala - Behror - Jaipur

the **health** care providers

the **health** care providers





DEPARTMENT OF PATHOLOGY

Patient Name : Mrs. POOJA AGARWAL

MR No : 672243

Age/Sex : 29 Years 4 Months 16 Days / Female

Type : OPD

TPA/Corporate : MEDIWHEEL PVT LTD

Ref Doctor : Dr.RMO

Bill Date : 18/02/2023 9:11 PM

Sample Col Dt/Tm : 18/02/2023 01:53 pm

Sample Rec Dt/Tm : 18/02/2023 01:53 pm

Reporting Date : 2023-02-18 00:00:00-01 16:47

Sample ID : 101343

Bill/Req. No. : 24043733

Test	Result	Blo. Ref. Interval	Units	Method
BLOOD SUGAR FASTING				
PLASMA GLUCOSE FASTING	87	60 - 110	mg/dl	GOD TRINDERS

***** END OF THE REPORT *****



Dr. PRADIP KUMAR
Consultant (Microbiology)

Dr. SONIA KUMARI
MD Pathology (Gold Medallist)

Dr. NISHA TIWARI
MBBS, MD (Microbiology)

USER NM AMIT1



(This is only professional opinion and not the diagnosis, please correlate clinically)

Cert. No. H-2016-0369 Cert. No. MC - 4830 Q Block, South City-II, Sohna Road, Sector-47, Gurgaon, Haryana
Ph.: 0124-4900000 (100 Lines), Toll Free No. : 1800-102-6767, Mob.: 62 62 82 82 35, Email: customercare@parkhospital.in

PARK GROUP OF HOSPITALS : West Delhi - Gurugram - Faridabad - Sonapat - Panipat - Karnal - Ambala - Patiala - Behror - Jaipur

the **health** care providers

the **health** care providers





DEPARTMENT OF PATHOLOGY

Patient Name : Mrs. POOJA AGARWAL
MR No : 672243
Age/Sex : 29 Years 4 Months 16 Days / Female
Type : OPD
TPA/Corporate : MEDIWHEEL PVT LTD

Bill Date : 18/02/2023
Reporting Date : 18/02/2023
Sample ID : 101343
Bill/Req. No. : 24043733
Ref Doctor : Dr.RMO

Test	Result	Blo. Ref. Interval	Units	Method
BLOOD GROUPING AND RH FACTOR				
BLOOD GROUP	"O" RH POSITIVE			MATRIX GEL

***** END OF THE REPORT *****



Sample no.

Dr. SONIA KUMARI
MBBS, MD (PATHOLOGY) Gold medalist

Dr. PRADIP KUMAR
Consultant (Microbiology)

Dr. NISHA TIWARI
MBBS, MD (Microbiology)

USER NM AMIT1



(This is only professional opinion and not the diagnosis, please correlate clinically)

Q Block, South City -II, Sohna Road, Sector-47, Gurgaon, Haryana
Ph.: 0124-4900000 (100 Lines), Toll Free No. : 1800-102-6767, Mob.: 62 62 82 82 35, Email: customercare@parkhospital.in

PARK GROUP OF HOSPITALS : West Delhi - Gurugram - Faridabad - Sonipat - Panipat - Karnal - Ambala - Patiala - Behror - Jaipur

the **health** care providers the **health** care providers






DEPARTMENT OF PATHOLOGY

Patient Name : Mrs. POOJA AGARWAL
MR No : 672243
Age/Sex : 29 Years 4 Months 16 Days / Female
Type : OPD
TPA/Corporate : MEDIWHEEL PVT LTD

Bill Date : 18/02/2023
Reporting Date : 18/02/2023
Sample ID : 101343
Bill/Req. No. : 24043733
Ref Doctor : Dr.RMO

Test	Result	Bio. Ref. Interval	Units	Method
CBC				
HAEMOGLOBIN	12.7	12 - 15	gm/dL	COLORIMETRY
TOTAL LEUCOCYTE COUNT	7900	4000-11000	/ μ L	ELECTRICAL
DIFFERENTIAL COUNT				
NEUTROPHILS	62	40.0 - 80.0	%	FLOW CYTOMETRY
LYMPHOCYTES	28	20.0 - 40.0	%	FLOW CYTOMETRY
MONOCYTES	08	2.0 - 10.0	%	FLOW CYTOMETRY
EOSINOPHILS	02	0.0 - 5.0	%	FLOW CYTOMETRY
BASOPHILS	00	0.0 - 2.0	%	FLOW CYTOMETRY
RED BLOOD CELL COUNT	4.5	3.5 - 5.5	millions/ μ L	ELECTRICAL
PACKED CELL VOLUME	37.9	35.0 - 50.0	%	ELECTRICAL
MEAN CORPUSCULAR VOLUME	83.8	83 - 101	fL	ELECTRICAL
MEAN CORPUSCULAR HAEMOGLOBIN	28.1	27 - 31	Picograms	CALCULATED
MEAN CORPUSCULAR HB CONC	33.5	33 - 37	g/dl	CALCULATED
PLATELET COUNT	258	150 - 450	thou/ μ L	ELECTRICAL
RDW	12.6	11.6 - 14.5	%	CALCULATED

***** END OF THE REPORT *****



Sample no.

Dr. SONIA KUMARI
MBBS, MD (PATHOLOGY) Gold medalist

Dr. PRADIP KUMAR
Consultant (Microbiology)

Dr. NISHA TIWARI
MBBS, MD (Microbiology)

USER NM AMIT1



(This is only professional opinion and not the diagnosis, please correlate clinically)

Cert. No. H-2016-0369 Cert. No. MC-4830 Q Block, South City -II, Sohna Road, Sector-47, Gurgaon, Haryana Page 1 of 1
Ph.: 0124-4900000 (100 Lines), Toll Free No. : 1800-102-6767, Mob.: 62 62 82 82 35, Email: customercare@parkhospital.in

PARK GROUP OF HOSPITALS : West Delhi - Gurugram - Faridabad - Sonipat - Panipat - Karnal - Ambala - Patiala - Behror - Jaipur

the **health** care providers the **health** care providers



DEPARTMENT OF PATHOLOGY

Patient Name : Mrs. POOJA AGARWAL
MR No : 672243
Age/Sex : 29 Years 4 Months 16 Days / Female
Type : OPD
TPA/Corporate : MEDIWHEEL PVT LTD

Bill Date : 18/02/2023
Reporting Date : 18/02/2023
Sample ID : 101343
Bill/Req. No. : 24043733
Ref Doctor : Dr.RMO

Test	Result	Blo. Ref. Interval	Units	Method
ESR (WESTERGEN)				
E.S.R. - II HR.	30		mm II Hr.	Westergren

***** END OF THE REPORT *****



Sample no.

Dr. SONIA KUMARI
MBBS, MD (PATHOLOGY) Gold medalist

Dr. PRADIP KUMAR
Consultant (Microbiology)

Dr. NISHA TIWARI
MBBS, MD (Microbiology)

USER NM AMIT1



(This is only professional opinion and not the diagnosis, please correlate clinically)

Cert. No. H-2016-0369 Cert No. MC - 4830 Q Block, South City -II, Sohna Road, Sector-47, Gurgaon, Haryana 122009
Ph.: 0124-4900000 (100 Lines), Toll Free No. : 1800-102-6767, Mob.: 62 62 82 82 35, Email: customercare@parkhospital.in

PARK GROUP OF HOSPITALS : West Delhi - Gurugram - Faridabad - Sonapat - Panipat - Karnal - Ambala - Patiala - Behror - Jaipur

the **health** care providers

the **health** care providers





DEPARTMENT OF PATHOLOGY

Patient Name : Mrs. POOJA AGARWAL
 MR No : 672243
 Age/Sex : 29 Years 4 Months 16 Days / Female
 Type : OPD
 TPA/Corporate : MEDIWHEEL PVT LTD

Bill Date : 18/02/2023
 Reporting Date : 19/02/2023
 Sample ID : 101343
 Bill/Req. No. : 24043733
 Ref Doctor : Dr.RMO

Test	Result	Bio. Ref. Interval	Units	Method
------	--------	--------------------	-------	--------

THYROID PROFILE

TRI-IODOTHYRONINE (T3)	0.79	0.60 - 1.81	ng/ml	Chemiluminescence
THYROXINE (T4)	9.2	5.01 - 12.45	µg/dL	Chemiluminescence
THYROID STIMULATING HORMONE	3.07	0.5-5.50 ,	µIU/ml	
SPECIMEN TYPE	SERUM			

Method : chemiluminescent immunoassay

Note : Clinical Significance:

Thyroid function tests (TFTs) is a collective term for blood tests used to check the function of the thyroid. TFTs may be requested if a patient is thought to suffer from hyperthyroidism (overactive thyroid) or hypothyroidism (underactive thyroid), or to monitor the effectiveness of either thyroid-suppression or hormone replacement therapy. It is also requested routinely in conditions linked to thyroid disease, such as atrial fibrillation and anxiety disorder. A TFT panel typically includes thyroid hormones such as thyroid-stimulating hormone (TSH, thyrotropin) and thyroxine (T4), and triiodothyronine (T3) depending on local laboratory policy.

Note: Please correlate with clinical condition

***** END OF THE REPORT *****



Sample no.

Dr. SONIA KUMARI
 MBBS, MD (PATHOLOGY) Gold medalist

Dr. PRADIP KUMAR
 Consultant (Microbiology)

Dr. NISHA TIWARI
 MBBS, MD (Microbiology)
 USER NM PAWAN



(This is only professional opinion and not the diagnosis, please correlate clinically)

Cent. No. H-2016-0369 Cent. No. MC-4830

Q Block, South City -II, Sohna Road, Sector-47, Gurgaon, Haryana
 Ph.: 0124-4900000 (100 Lines), Toll Free No. : 1800-102-6767, Mob.: 62 62 82 82 35, Email: customercare@parkhospital.in

PARK GROUP OF HOSPITALS : West Delhi - Gurugram - Faridabad - Sonipat - Panipat - Karnal - Ambala - Patiala - Behror - Jaipur

the health care providers

the health care providers





DEPARTMENT OF PATHOLOGY

Patient Name : Mrs. POOJA AGARWAL
 MR No : 672243
 Age/Sex : 29 Years 4 Months 16 Days / Female
 Type : OPD
 TPA/Corporate : MEDIWHEEL PVT LTD

Bill Date : 18/02/2023
 Reporting Date : 18/02/2023
 Sample ID : 101343
 Bill/Req. No. : 24043733
 Ref Doctor : Dr.RMO

Test	Result	Bio. Ref. Interval	Units	Method
KFT (RENAL PROFILE)				
KFT				
SERUM UREA	27	10 - 45	mg/dL	UREASE-GLDH
SERUM CREATININE	1.0	0.4 - 1.4	mg/dL	MODIFIED JAFFES
SERUM URIC ACID	4.9	2.5 - 7.0	mg/dL	URICASE
SERUM SODIUM	137	136 - 148	mmol/L	ISE
SERUM POTASSIUM	4.8	3.5 - 5.5	meq/l	ISE
SERUM CALCIUM	9.2	8.5 - 10.5	mg/dL	ARSENazo III
SERUM PHOSPHORUS	3.9	2.5 - 4.5	mg/dL	AMMONIUM

***** END OF THE REPORT *****



Sample no.

Dr. SONIA KUMARI
 MBBS, MD (PATHOLOGY) Gold medalist

Dr. PRADIP KUMAR
 Consultant (Microbiology)

Dr. NISHA TIWARI
 MBBS, MD (Microbiology)

USER NM AMIT1



(This is only professional opinion and not the diagnosis, please correlate clinically)

Cert. No. H-2016-0369 Cert. No. MC - 4830 Q Block, South City -II, Sohna Road, Sector-47, Gurgaon, Haryana
 Ph.: 0124-4900000 (100 Lines), Toll Free No. : 1800-102-6767, Mob.: 62 62 82 82 35, Email: customercare@parkhospital.in

PARK GROUP OF HOSPITALS : West Delhi - Gurugram - Faridabad - Sonapat - Panipat - Karnal - Ambala - Patiala - Behror - Jaipur

the health care providers the health care providers



DEPARTMENT OF PATHOLOGY

Patient Name : Mrs. POOJA AGARWAL
 MR No : 672243
 Age/Sex : 29 Years 4 Months 16 Days / Female
 Type : OPD
 TPA/Corporate : MEDIWHEEL PVT LTD

Bill Date : 18/02/2023
 Reporting Date : 18/02/2023
 Sample ID : 101343
 Bill/Req. No. : 24043733
 Ref Doctor : Dr.RMO

Test	Result	Bio. Ref. Interval	Units	Method
LIPID PROFILE				
LIPID PROFILE				
TOTAL CHOLESTEROL	153	0 - 250	mg/dL	CHOD -Trinder
SERUM TRIGLYCERIDES	120	60 - 165	mg/dl	GPO-TRINDER
HDL-CHOLESTEROL	47	30 - 70	mg/dl	DIRECT
VLDL CHOLESTEROL	24	6 - 32	mg/dL	calculated
LDL	82	50 - 135	mg/dl	calculated
LDL CHOLESTEROL/HDL RATIO	1.7	1.0 - 3.0	mg/dL	calculated
TOTAL CHOLESTEROL/HDL RATIO	3.2	2.0 - 5.0	mg/dl	calculated

***** END OF THE REPORT *****



Sample no.

Dr. SONIA KUMARI
 MBBS, MD (PATHOLOGY) Gold medalist

Dr. PRADIP KUMAR
 Consultant (Microbiology)

Dr. NISHA TIWARI
 MBBS, MD (Microbiology)

USER NM AMIT1



Cert. No H-2016-0369 Cert. No MC - 4830

(This is only professional opinion and not the diagnosis, please correlate clinically)

Q Block, South City -II, Sohna Road, Sector-47, Gurgaon, Haryana
 Ph.: 0124-4900000 (100 Lines), Toll Free No. : 1800-102-6767, Mob.: 62 62 82 82 35, Email: customercare@parkhospital.in

PARK GROUP OF HOSPITALS : West Delhi - Gurugram - Faridabad - Sonapat - Panipat - Karnal - Ambala - Patiala - Behror - Jaipur

the health care providers

the health care providers





DEPARTMENT OF PATHOLOGY

Patient Name : Mrs. POOJA AGARWAL
 MR No : 672243
 Age/Sex : 29 Years 4 Months 16 Days / Female
 Type : OPD
 TPA/Corporate : MEDIWHEEL PVT LTD

Bill Date : 18/02/2023
 Reporting Date : 21/02/2023
 Sample ID : 101343
 Bill/Req. No. : 24043733
 Ref Doctor : Dr.RMO

Test	Result	Blo. Ref. Interval	Units	Method
URINE ROUTINE AND MICROSCOPY				
PHYSICAL CHARACTERSTICS				
QUANTITY	30ml	5 - 100	ml	Vishal
COLOUR	Pale Yellow	Pale Yellow		
TURBIDITY	Clear	clear		urinometer
SPECIFIC GRAVITY	1.020	1.000-1.030		PH PAPER
PH	Acidic	Acidic/Alkaline		
CHEMICAL EXAMINATION-1				
UROBILINOGEN	NIL	NIL	mg/dl	Ehrlich Protein error indicator
URINE PROTEIN	NIL	NIL		
BLOOD	NIL	NIL		
URINE BILIRUBIN	NIL	NIL	mg/dL	GOD-POD/Benedicts SOD.
GLUCOSE	NIL	NIL		
URINE KETONE	NIL	NIL		
MICRO.EXAMINATION				
PUS CELL	1-2	0-5	cells/hpf	Microscopic
RED BLOOD CELLS	Nil	0-2	cells/hpf	
EPITHELIAL CELLS	2-4	0-5	cells/hpf	
CASTS	NIL	NIL	/lpf	
CRYSTALS	NIL	NIL	/hpf	

***** END OF THE REPORT *****



Sample no.

Dr. SONIA KUMARI
 MBBS, MD (PATHOLOGY) Gold medalist

Dr. PRADIP KUMAR
 Consultant (Microbiology)

Dr. NISHA TIWARI
 MBBS, MD (Microbiology)

USER NM NIKHIL



Cert. No. H-2016-0369 Cert. No. MC - 4830

(This is only professional opinion and not the diagnosis, please correlate clinically)

Page 1 of 1

Q Block, South City -II, Sohna Road, Sector-47, Gurgaon, Haryana

Ph.: 0124-4900000 (100 Lines), Toll Free No. : 1800-102-6767, Mob.: 62 62 82 82 35, Email: customercare@parkhospital.in

PARK GROUP OF HOSPITALS : West Delhi - Gurugram - Faridabad - Sonipat - Panipat - Karnal - Ambala - Patiala - Behror - Jaipur

the health care providers

the health care providers





DEPARTMENT OF PATHOLOGY

Patient Name : Mrs. POOJA AGARWAL
MR No : 672243
Age/Sex : 29 Years 4 Months 16 Days / Female
Type : OPD
TPA/Corporate : MEDIWHEEL PVT LTD

Bill Date : 18/02/2023
Reporting Date : 21/02/2023
Sample ID : 101343
Bill/Req. No. : 24043733
Ref Doctor : Dr.RMO

Test	Result	Bio. Ref. Interval	Units	Method
------	--------	--------------------	-------	--------

URINE C/S

NAME OF SPECIMEN	URINE			Aerobic culture
ORGANISM IDENTIFIED	NO ORGANISM SEEN IN CULTURE AFTER 48 HRS OF INCUBATION AT 37 C DEGREE.			

Method : .

Note : .

***** END OF THE REPORT *****



Sample no.

Dr. SONIA KUMARI
 MBBS, MD (PATHOLOGY) Gold medalist

Dr. PRADIP KUMAR
 Consultant (Microbiology)

Dr. NISHA TIWARI
 MBBS, MD (Microbiology)

USER NM NIKHIL



(This is only professional opinion and not the diagnosis, please correlate clinically) Page 1 of 1

Cert. No. H-2016-0369 Cert. No. MC - 4830 Q Block, South City -II, Sohna Road, Sector-47, Gurgaon, Haryana
 Ph.: 0124-4900000 (100 Lines), Toll Free No. : 1800-102-6767, Mob.: 62 62 82 82 35, Email: customercare@parkhospital.in

PARK GROUP OF HOSPITALS : West Delhi - Gurugram - Faridabad - Sonapat - Panipat - Karnal - Ambala - Patiala - Behror - Jaipur

the health care providers

the health care providers





NAME	: MRS. POOJA AGARWAL	DATE	: 18 / 02 / 2023
Age Sex	: 29 Years / Female	Inpatient No	:
PERFORMED BY	: Dr. ELA MADAAN	UHID	: 24043733

TRANS THORACIC ECHO CARDIOGRAPHY REPORT

MITRAL VALVE

Morphology AML: Normal / Thickening / Calcification / Flutter / Vegetation / Non significant Prolapse / SAM
PML: Normal / Thickening / Calcification / Prolapse / Paradoxical Motion / Fixed.
Subvalvular deformity: Present / Absent

Doppler Normal / Abnormal
Mitral Stenosis Present / Absent
Mitral Regurgitation; Absent / Normal / Mild / Trace / Moderate / Severe.

TRICUSPID VALVE

Morphology Normal / Atresia / Thickening / Calcification / Prolapse / Vegetation / Doming.
Doppler Normal / Abnormal
Tricuspid Stenosis : Present / Absent.
Tricuspid Regurgitation; Absent / Normal / Mild / Trace / Moderate / Severe.

PULMONARY VALVE

Morphology Normal / Atresia / Thickening / Calcified / Doming / Vegetation.
Doppler Normal / Abnormal.
Pulmonary stenosis : Present / Absent
Pulmonary regurgitation : Present / Absent

AORTIC VALVE

Morphology Normal / Thickened / Mildly / Calcified / Flutter / Vegetation / Restricted / Opening
No. of Cusps 1 / 2 / 3 / 4
Doppler Normal / Abnormal
Aortic Stenosis : Present / Absent
Aortic regurgitation : Present / Absent / Mild / Trace



(This is only professional opinion and not the diagnosis, please correlate clinically)

Q Block, South City -II, Sohna Road, Sector-47, Gurgaon, Haryana
Ph.: 0124-4900000 (100 Lines), Toll Free No. : 1800-102-6767, Mob.: 62 62 82 82 35, Email: customercare@parkhospital.in

PARK GROUP OF HOSPITALS : West Delhi - Gurugram - Faridabad - Sonapat - Panipat - Karnal - Ambala - Patiala - Behror - Jaipur

the **health** care providers

the **health** care providers





Park Hospital

GROUP SUPER SPECIALITY HOSPITAL

<u>Measurements</u>	<u>Normal Values</u>	<u>Measurements</u>	<u>Normal Value</u>
IVSD : 1.1cm	(0.6-1.1cm))	LA : 3.5cm	(1.9-4.0cm)
LVID : 4.8cm	(3.7-5.6cm)	LVOT : 1.3cm	
LVPW : 1.0cm		AORTA : 3.0cm	(2.0-3.7cm)
EF : 55%	(55% - 80%)	IVSmotion :	Normal / Flat / Paradoxical

Any Other

CHAMBERS:-

- LV Normal / Enlarged / Clear / Thrombus / Contraction Normal LV shows concentric LVH, no gradient across LVOT / Inetic / Intra capillary Regional wall motion abnormality: Absent / Present
- LA Normal / Enlarged / Clear / Thrombus / Myxoma; LAA: Clear / Thrombus
- RA Normal / Clear / Thrombus, Dilated.
- RV Normal / Enlarged / Clear / Thrombus / Hypertrophied / Dilated.
- PERICARDIUM Normal / Thickening / Calcification / Effusion.

COMMENTS & SUMMARY:-

- All cardiac chambers dimensions are with in normal limits.
- Global LVEF 55%
- No RWMA
- NORMAL LV FUNCTION
- TRACE MR
- TRACE AR
- MILD TR
- GOOD RV FUNCTION
- IAS/IVS. No Flow seen across IAS/IVS.
- No Thrombus/Mass in any chamber.
- No Pericardial Effusion.



Please correlate clinically

Dr. Ela Madaan
MBBS, PGDCC
Fellowship in Non Invasive
Cardiology

Dr. NAVJEET SINGH
M.D.(Medicine) D.M (Cardiology).
HOD & Director Interventional cardiology.



Cert No. H-2016-0369 Cert No. MC-4830

(This is only professional opinion and not the diagnosis, please correlate clinically)

Q Block, South City -II, Sohna Road, Sector-47, Gurgaon, Haryana
Ph.: 0124-4900000 (100 Lines), Toll Free No. : 1800-102-6767, Mob.: 62 62 82 82 35, Email: customercare@parkhospital.in

PARK GROUP OF HOSPITALS : West Delhi - Gurugram - Faridabad - Sonapat - Panipat - Karnal - Ambala - Patiala - Behror - Jaipur

the health care providers

the health care providers



Scanned with OKEN Scanner



DEPARTMENT OF RADIOLOGY

Patient Name	Mrs. POOJA AGARWAL	Billed Date	: 18/02/2023	1.11 PM
Reg No	672243	Reported Date	: 18/02/2023	
Age/Sex	29 Years 4 Months 16Days / Female	Req. No.	: 24043733	
Type	OPD	Consultant Doctor	: Dr. RMO	

USG WHOLE ABDOMEN

The real time, B mode, gray scale sonography of the abdominal organs was performed.

LIVER :The liver is mild enlarged in size 14.7cm with fatty infiltration. No evidence of any focal lesion. IHBR is not dilated.

GALL BLADDER : The gall bladder is well distended . No evidence any calculus or mass seen.GB wall thickness with in normal limits.No evidence of pericholecystic fluid is seen.

BILE DUCT :The common bile duct is normal in caliber. No evidence of calculus is noted in common bile duct.

SPLEEN :The spleen is normal in size 7.6cm and shape.Its echotexture is homogeneous.No evidence of focal lesion is noted.

PANCREAS :The pancreas is normal in size, shape, contours and echotexture.No evidence of solid or cystic mass lesion is noted.MPD is not dilated. No evidence of peripancreatic collection.

KIDNEYS :The bilateral kidneys are normal in size and echotexture. Cortico-medullary differentiation is maintained.There is no evidence of obvious calculus or hydronephrosis.

URINARY BLADDER :The urinary bladder is partially distended (55cc).It shows uniformly thin walls and sharp mucosa.No evidence of calculus is seen. No evidence of mass or diverticulum is noted.

No evidence of ascites or interbowel free fluid is seen.

No evidence of obvious retroperitoneal or mesentric lymphadenopathy is seen.

IMPRESSION- Mild hepatomegaly with fatty liver grade-I

To be correlated clinically.



Dr.ANSHU K.SHARMA
MBBS,MD
CONSULTANT RADIOLOGIST

Dr.MANJEET SEHRAWAT
MBBS,MD,PDCC
CONSULTANT RADIOLOGIST

Dr. NEENA SIKKA
MBBS,DNB
CONSULTANT RADIOLOGIST



Cert. No. H-2016-0369 Cert No. MC - 4830

(This is only professional opinion and not the diagnosis, please correlate clinically)

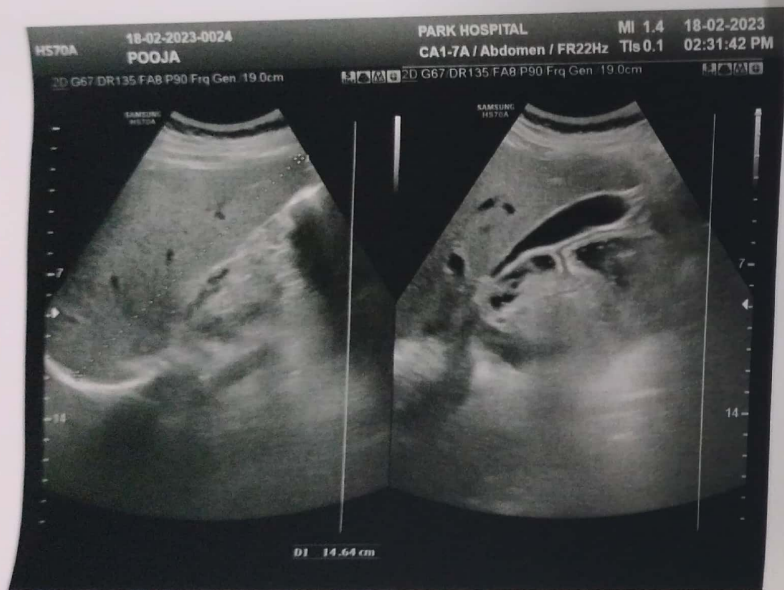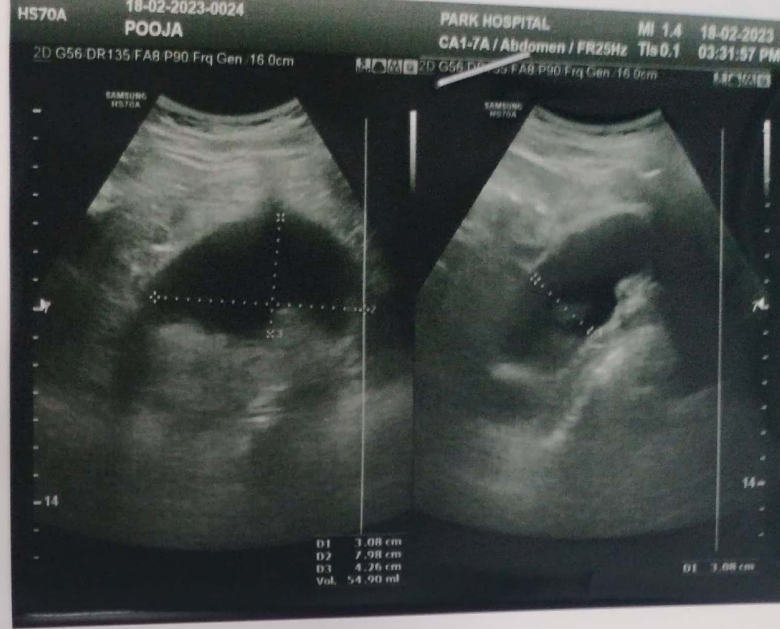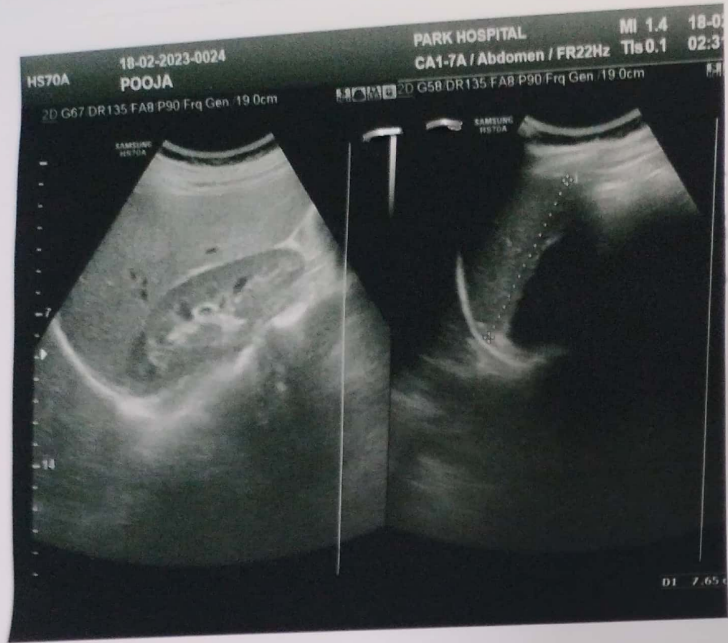
Q Block, South City -II, Sohna Road, Sector-47, Gurgaon, Haryana
Ph.: 0124-4900000 (100 Lines), Toll Free No. : 1800-102-6767, Mob.: 62 62 82 82 35, Email: customercare@parkhospital.in

PARK GROUP OF HOSPITALS : West Delhi - Gurugram - Faridabad - Sonapat - Panipat - Karnal - Ambala - Patiala - Behror - Jaipur

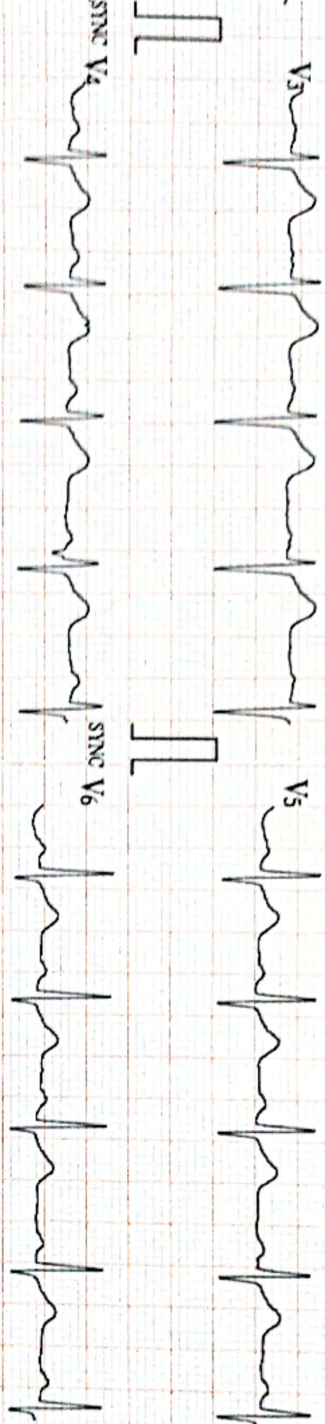
the **health** care providers

the **health** care providers





10mm/mV



10mm/mV

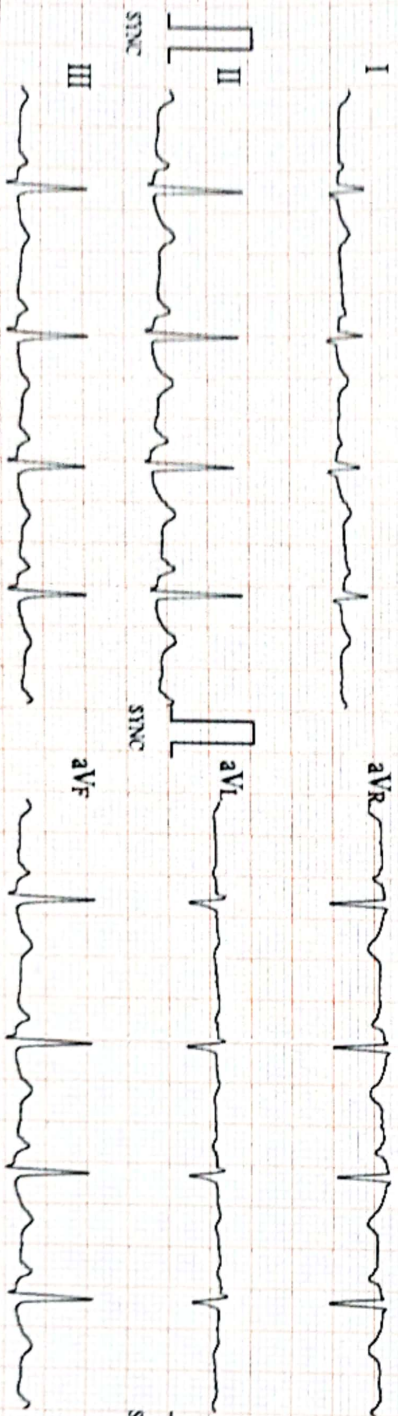
ID : 0001
 Name: Poojya
 Sex : F
 Age : 29/10
 HR : 101 bpm
 R-R : 590 ms
 P-R : 149 ms
 QRS : 90 ms
 QT/QTc : 326/423 ms
 P/QRS/T : 56/81/98 °
 RV5/SV1 : 0.68/0.500 mV
 RV5+SV1 : 1.180 mV

Unconfirmed report Verified by: WPM

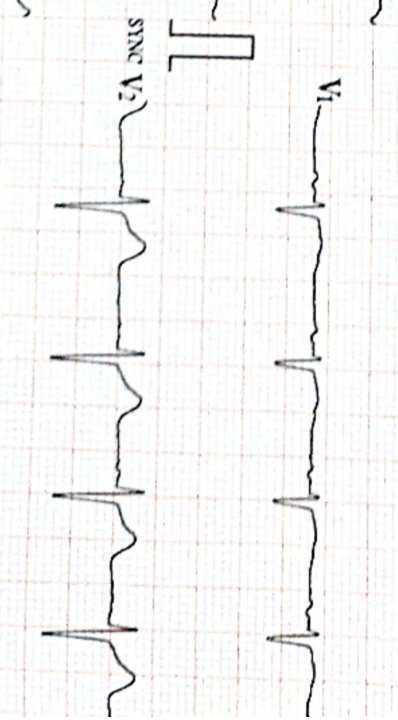
- ___ Sinus Tachycardia
- ___ Sinus Arrhythmia
- ___ T Abnormality (Flat T)

Standard 0.5-25Hz

10mm/mV



10mm/mV



10mm/mV

ECC-2007 T:000(SIG:V0.000 AMP:V1.001) 2016-00-00 00:00