


Download Date: 26/07/2022
 Delhi - 110085
 Address: House No. 233 2nd Floor Unity Apartment, Pocket 23, Rohini Sector-24, North West
 दिल्ली - 110085
 पता: 233 नंबर की 233 फ्लोर यूनैटी अपार्टमेंट, पॉकेट 23, रोहिणी


आधार पहचान
 Unique Identification Authority of India

1947 | help@uidai.gov.in | www.uidai.gov.in
 VID : 9165 9590 5300 8638
 9194 5638 6027

Sumith

Dr. Nitin Agarwal
DR. NITIN AGARWAL
 MBBS, MD
 Regn. No. DMC-R-1436


ONEPLUS ULTRASOUND LAB
 47, Harsh Vihar, Pitam Pura
 Delhi-110094
 Ph. 011-42480101, 9599913051
 E-mail: oneplusul@gmail.com

भारत सरकार

सुमित कुमार
 Sumit Kumar
 जन्म तिथि/DOB: 19/01/1984
 पुरुष/ MALE


 Issue Date: 11/01/2012

9194 5638 6027
 VID : 9165 9590 5300 8638
मेरा आधार, मेरी पहचान



Anurish

Dr. NEHA AGARWAL
MBBS, MD
Regn. No. DMC-R-1436

ONEPLUS ULTRASOUND LAB
47, Harsh Vihar, Pitam Pura,
Delhi-110034
Ph: 011-42480101, 9599913051
E-mail: oneplusul@gmail.com



OnePLUS
Ultrasound Lab
— QUALITY FIRST... ALWAYS! —

Dr. Nitin Agarwal

Pathologist & Director
Ex. Sr. Res. MAMC
& Lok Nayak Hospital
Ex. Chief of Lab Dr. Lal Path Labs.

Dr. Pooja (Garg) Agarwal

Radiologist & Director
MAMC & Lok Nayak Hospital

I, Sumit Kumar undertake not to
take stool test due to some reason.
I am also not going for IMT test owing
to high blood pressure as checked today -
11/03/2023

Sumit
11/03/2023

[Signature]
Dr. NITIN AGARWAL
MBBS, MD
Regn. No. DMC-R-1436

47, Harsh Vihar, Pitampura, New Delhi-110034 | Ph.: 011-42480101, 9599913051

E-mail: oneplusul@gmail.com | Web.: www.oneplusul.in

Clinical correlation is essential for final diagnosis. • If test results are unsatisfactory please contact personally or on phone. • This report is for perusal of doctors only.
• All disputes Subject to Delhi Jurisdiction only. • Not for medicolegal purposes. • All congenital anomalies in a foetus may not be diagnosed in routine obstetric ultrasound.



OnePLUS
Ultrasound Lab

— QUALITY FIRST... ALWAYS! —

Dr. Nitin Agarwal
Pathologist & Director
Ex. Sr. Res. MAMC
& Lok Nayak Hospital
Ex. Chief of Lab Dr. Lal Path Labs.

Dr. Pooja (Garg) Agarwal
Radiologist & Director
MAMC & Lok Nayak Hospital



NAME	:Mr. SUMIT KUMAR	Barcode No	:10139678
AGE/GENDER	:37 YRS/Male	SPECIMEN DATE	:11/Mar/2023 08:54AM
PATIENT ID	:110475	SPECIMEN RECEIVED	:11/Mar/2023 09:04AM
REFERRED BY	:Dr. MEDIWHEEL	REPORT DATE	:11/Mar/2023 03:05PM
CENTRE NAME	:ONEPLUS ULTRASOUND LAB	LAB NO.	:012303110010

Test Name	Result	Unit	Ref. Range
-----------	--------	------	------------

HAEMATOLOGY

Medi Wheel Health checkup < 40 Female

Glycosylated Hemoglobin (HbA1c)	5.5	%	Non Diabetic adults <5.7 Prediabetic (at risk) 5.7-6.4 Diabetes >6.4
--	-----	---	--

Estimated average blood glucose (eag)	111
--	-----

Reference range (mg/dl):

90 - 120:Excellent control, 121 - 150:Good Control, 151 - 180:Average Control, 181 - 210:Action Suggested

>211:Panic value

BLOOD GROUP (ABO)	A
Rh typing	POSITIVE

NOTE :

- * Apart from major A,B,H antigens which are used for ABO grouping and Rh typing, many minor blood group antigens exist. Agglutination may also vary according to titre of antigen and antibody.
- * So before transfusion, reconfirmation of blood group as well as cross-matching is needed.
- * Presence of maternal antibodies in newborns, may interfere with blood grouping.
- * Auto agglutination (due to cold antibody, falciparum malaria, sepsis, internal malignancy etc.) may also cause erroneous result.

CBC

Haemoglobin	13.9	g/dl	13.0-17.0
Total Leucocyte Count	5600	/cumm	4000-10000
Differential leucocyte count			
Neutrophils	60.1	%	40-80
Lymphocyte	34.50	%	20-40
Monocytes	3.00	%	2-10
Eosinophils	2.0	%	1-6
Basophils	0.4	%	0-2
RBC Count	4.80	million/cumm	4.5 - 5.5

Checked By.

Dr. NITIN AGARWAL
M B B S , MD (Path)
DMC/R/01436
DR. NITIN AGARWAL
MBBS,MD(PATHOLOGIST)

47, Harsh Vihar, Pitampura, New Delhi-110034 | Ph.: 011-42480101, 9599913051

E-mail: oneplusul@gmail.com | Web.: www.oneplusul.in

Page 1 of 7



OnePLUS Ultrasound Lab

— QUALITY FIRST... ALWAYS! —

Dr. Nitin Agarwal

Pathologist & Director
Ex. Sr. Res. MAMC
& Lok Nayak Hospital
Ex. Chief of Lab Dr. Lal Path Labs.

Dr. Pooja (Garg) Agarwal

Radiologist & Director
MAMC & Lok Nayak Hospital




NAME	:Mr. SUMIT KUMAR	Barcode No	:10139678
AGE/GENDER	:37 YRS/Male	SPECIMEN DATE	:11/Mar/2023 08:54AM
PATIENT ID	:110475	SPECIMEN RECEIVED	:11/Mar/2023 09:04AM
REFERRED BY	:Dr. MEDIWHEEL	REPORT DATE	:11/Mar/2023 03:05PM
CENTRE NAME	:ONEPLUS ULTRASOUND LAB	LAB NO.	:012303110010

Test Name	Result	Unit	Ref. Range
PCV(Hematocrit)	44.8	%	40-50
MCV	93.1	fL	83-101
MCH	28.8	Pg	27-32
MCHC	31	G/dL	32-35
Platelet count	197000	/cumm	150000-450000
RDW-CV	13.8	%	11.4-14.0
ESR(WESTEGRENs METHOD)	10	mm in 1st hr	0-20

BIOCHEMISTRY

Blood sugar fasting	113	mg/dL	70-110
----------------------------	-----	-------	--------

Checked By.

Dr. NITIN AGARWAL 
M B B S, MD (Pa) DR, NITIN AGARWAL
DMC/R/01436 MBBS,MD(PATHOLOGIST)

47, Harsh Vihar, Pitampura, New Delhi-110034 | Ph.: 011-42480101, 9599913051

E-mail: oneplusul@gmail.com | Web.: www.oneplusul.in

Page 2 of 7



OnePLUS
Ultrasound Lab
— QUALITY FIRST... ALWAYS! —

Dr. Nitin Agarwal

Pathologist & Director
Ex. Sr. Res. MAMC
& Lok Nayak Hospital
Ex. Chief of Lab Dr. Lal Path Labs.

Dr. Pooja (Garg) Agarwal

Radiologist & Director
MAMC & Lok Nayak Hospital



NAME	:Mr. SUMIT KUMAR	Barcode No	:10139678
AGE/GENDER	:37 YRS/Male	SPECIMEN DATE	:11/Mar/2023 08:54AM
PATIENT ID	:110475	SPECIMEN RECEIVED	:11/Mar/2023 09:04AM
REFERRED BY	:Dr. MEDIWHEEL	REPORT DATE	:11/Mar/2023 03:46PM
CENTRE NAME	:ONEPLUS ULTRASOUND LAB	LAB NO.	:012303110010

Test Name	Result	Unit	Ref. Range
-----------	--------	------	------------

BIOCHEMISTRY

Blood sugar pp	106	mg/dL	70.0-140.0
-----------------------	-----	-------	------------

Checked By.

Dr. NITIN AGARWAL
MBBS, MD
DMC/R
DR. NITIN AGARWAL
MBBS, MD (PATHOLOGIST)

47, Harsh Vihar, Pitampura, New Delhi-110034 | Ph.: 011-42480101, 9599913051
E-mail: oneplusul@gmail.com | Web.: www.oneplusul.in

Page 3 of 7

Clinical correlation is essential for final diagnosis. • If test results are unsatisfactory please contact personally or on phone. • This report is for perusal of doctors only.
• All disputes Subject to Delhi Jurisdiction only. • Not for medicolegal purposes. • All congenital anomalies in a foetus may not be diagnosed in routine obstetric ultrasound.



OnePLUS Ultrasound Lab

— QUALITY FIRST... ALWAYS! —

Dr. Nitin Agarwal

Pathologist & Director
Ex. Sr. Res. MAMC
& Lok Nayak Hospital
Ex. Chief of Lab Dr. Lal Path Labs.

Dr. Pooja (Garg) Agarwal

Radiologist & Director
MAMC & Lok Nayak Hospital



NAME	:Mr. SUMIT KUMAR	Barcode No	:10139678
AGE/GENDER	:37 YRS/Male	SPECIMEN DATE	:11/Mar/2023 08:54AM
PATIENT ID	:110475	SPECIMEN RECEIVED	:11/Mar/2023 09:04AM
REFERRED BY	:Dr. MEDIWHEEL	REPORT DATE	:11/Mar/2023 03:05PM
CENTRE NAME	:ONEPLUS ULTRASOUND LAB	LAB NO.	:012303110010

Test Name	Result	Unit	Ref. Range
-----------	--------	------	------------

BIOCHEMISTRY

<u>Bun (blood urea nitrogen)</u>	12.60	mg/dl	8.9-21.6
<u>Uric acid, serum</u>	4.6	mg/dl	3.5-7.2
<u>Creatinine, serum</u>	0.6	mg/dl	0.60-1.2

LFT(LIVER FUNCTION TEST)

Bilirubin Total	0.54	mg/dl	0.1-1.2
Bilirubin Conjugated	0.23	mg/dl	0-0.4
Bilirubin Unconjugated	0.31	mg/dl	up to 0.7
SGOT (AST)	29	U/L	0-46
SGPT (ALT)	29	U/L	0-49
Alkaline phosphatase	96	U/L	40-129
Gamma glutamyl transpeptidase	26	U/L	10-45
Total Protein	6.8	gm/dl	6.60 - 8.70
Albumin serum	3.9	g/dL	3.0-5.2
Globulin	2.90	gm/dl	1.8-3.4
Albumin/Globulin Ratio	1.34		1.10 - 2.50

LIPID PROFILE

Cholesterol	262	mg/dl	50-200
Triglycerides	291	mg/dL	25-150
HDL Cholesterol	45	mg/dL	40 - 60
LDL cholesterol	159	mg/dL	<130
VLDL cholesterol	58.2	mg/dL	5-40
Cholesterol/HDL Ratio	5.8		Low Risk 3.3-4.97 Average Risk 4.4-7.1 Moderate Risk 7.1-11.0 High Risk >11.0
LDL/HDL Ratio	3.5		0 - 3.55

According to ATP III and NCEP guidelines

Checked By.

Dr. NITIN AGARWAL
M B B S, MD (Path)
DMC/R/01436

DR. NITIN AGARWAL
MBBS,MD(PATHOLOGIST)

47, Harsh Vihar, Pitampura, New Delhi-110034 | Ph.: 011-42480101, 9599913051

E-mail: oneplusul@gmail.com | Web.: www.oneplusul.in

Page 4 of 7



OnePLUS Ultrasound Lab

— QUALITY FIRST... ALWAYS! —

Dr. Nitin Agarwal

Pathologist & Director
Ex. Sr. Res. MAMC
& Lok Nayak Hospital

Ex. Chief of Lab Dr. Lal Path Labs.

Dr. Pooja (Garg) Agarwal

Radiologist & Director
MAMC & Lok Nayak Hospital



NAME	:Mr. SUMIT KUMAR	Barcode No	:10139678
AGE/GENDER	:37 YRS/Male	SPECIMEN DATE	:11/Mar/2023 08:54AM
PATIENT ID	:110475	SPECIMEN RECEIVED	:11/Mar/2023 09:04AM
REFERRED BY	:Dr. MEDIWHEEL	REPORT DATE	:11/Mar/2023 03:05PM
CENTRE NAME	:ONEPLUS ULTRASOUND LAB	LAB NO.	:012303110010

Test Name	Result	Unit	Ref. Range	
Parameter	Normal	Desirable	Borderline	High
Total cholesterol	<200		200-239	240
Triglycerides	<150	150-199	200-499	500
LDL	Optimal <100	130-159	160-180	190
	Near Optimal 100-129			
HDL	<40 : LOW 60 : HIGH			

BUN/Creatinine ratio

Bun (blood urea nitrogen)	12.60	mg/dl	8.9-21.6
CREATININE	0.60	mg/dl	0.30-1.10
BUN/Creatinine ratio	21.00		10.0 - 20.0

ENDOCRINOLOGY

THYROID PROFILE(T3,T4,TSH)

Triiodothyronine total [t3]	0.95	ng/dl	0.52-1.9
Thyroxine total [t4]	7.60	µg/dl	4.4 - 10.8
TSH (Thyroid Stimulating Hormone)	3.40	µIU/ml	0.25-5.0

AGE WISE VARIATION IN TSH

AGE	TSH(µIU/ml)	AGE	TSH(µIU/ml)
1-4 weeks	1.00 - 19.0	16-20 yrs	0.25 - 5.0
1-12 mths	1.70 - 9.1	21 - 80 yrs	0.25 - 5.0
1-5 yrs	0.80 - 8.2	I st trimester	0.25 - 5.0
6-10 yrs	0.25 - 5.0	II nd trimester	0.50 - 5.0
11-15 yrs	0.25 - 5.0	III rd trimester	0.4 - 6.0

Reference ranges - Interpretation of Diagnostic tests - (Jacques Wallach)

1. Primary hypothyroidism is accompanied by depressed serum T3 and T4 values and elevated serum TSH level.

Checked By.

Dr. NITIN AGARWAL
M B B S , MD (P)
DMC/R/01436
DR. NITIN AGARWAL
MBBS,MD(PATHOLOGIST)

47, Harsh Vihar, Pitampura, New Delhi-110034 | Ph.: 011-42480101, 9599913051

E-mail: oneplusul@gmail.com | Web.: www.oneplusul.in

Page 5 of 7



OnePLUS
Ultrasound Lab
— QUALITY FIRST... ALWAYS! —

Dr. Nitin Agarwal

Pathologist & Director

Ex. Sr. Res. MAMC

& Lok Nayak Hospital

Ex. Chief of Lab Dr. Lal Path Labs.

Dr. Pooja (Garg) Agarwal

Radiologist & Director

MAMC & Lok Nayak Hospital



NAME	:Mr. SUMIT KUMAR	Barcode No	:10139678
AGE/GENDER	:37 YRS/Male	SPECIMEN DATE	:11/Mar/2023 08:54AM
PATIENT ID	:110475	SPECIMEN RECEIVED	:11/Mar/2023 09:04AM
REFERRED BY	:Dr. MEDIWHEEL	REPORT DATE	:11/Mar/2023 03:05PM
CENTRE NAME	:ONEPLUS ULTRASOUND LAB	LAB NO.	:012303110010

Test Name	Result	Unit	Ref. Range
2. Primary hyperthyroidism is accompanied by elevated serum T3 and T4 levels along with depressed TSH values.			
3. Slightly elevated T3 levels may be found in pregnancy and estrogen therapy, while depressed levels may be encountered in severe illness, renal failure and during therapy with drugs like propranolol and propyl thiouracil.			
4. Although elevated TSH levels are nearly always indicative of primary hypothyroidism, and may be seen in secondary thyrotoxicosis			

CLINICAL PATHOLOGY

URINE ROUTINE

Physical examination

Quantity	20		ML
Colour	PALE YELLOW		
Transparency	CLEAR		CLEAR
Sp.gravity	1.010		1.010-1.030
pH	6.50		
Reaction	ACIDIC		ACIDIC

Chemical examination

Urine protein	NIL		NIL
Urine sugar	NIL		NIL
Bilirubin, urine	NEGATIVE		NEGATIVE
Urobilinogen	NORMAL		NORMAL
Ketones	NEGATIVE		NEGATIVE

Microscopic examination

Pus cells.	1-2	/HPF	0-2
Epithelial cells	1-2	/HPF	NIL
R.B.C.	NIL	/HPF	NIL
Casts	NIL	/HPF	NIL
Crysals	NIL	/HPF	NIL
Bacteria	NIL	/HPF	NIL
Others.	NIL	NIL	NIL

*** End Of Report ***

Checked By.

Dr. NITIN AGARWAL
MBBS, MD (Path)
DMC/R/01436
DR. NITIN AGARWAL
MBBS, MD (PATHOLOGIST)

47, Harsh Vihar, Pitampura, New Delhi-110034 | Ph.: 011-42480101, 9599913051

E-mail: oneplusul@gmail.com | Web.: www.oneplusul.in

Page 6 of 7

Clinical correlation is essential for final diagnosis. • If test results are unsatisfactory please contact personally or on phone. • This report is for perusal of doctors only. • All disputes Subject to Delhi Jurisdiction only. • Not for medicolegal purposes. • All congenital anomalies in a foetus may not be diagnosed in routine obstetric ultrasound.



OnePLUS
Ultrasound Lab
— QUALITY FIRST... ALWAYS! —

Dr. Nitin Agarwal
Pathologist & Director
Ex. Sr. Res. MAMC
& Lok Nayak Hospital
Ex. Chief of Lab Dr. Lal Path Labs.

Dr. Pooja (Garg) Agarwal
Radiologist & Director
MAMC & Lok Nayak Hospital

Name	: Mr. SUMIT KUMAR	Age/Sex	: 37 YRS/Male
Ref. By	: Dr. MEDIWHEEL	Lab No	: 012303110010
Date	: 11-Mar-2023	Patient ID	: LSHHI110475

X-ray-Chest PA view

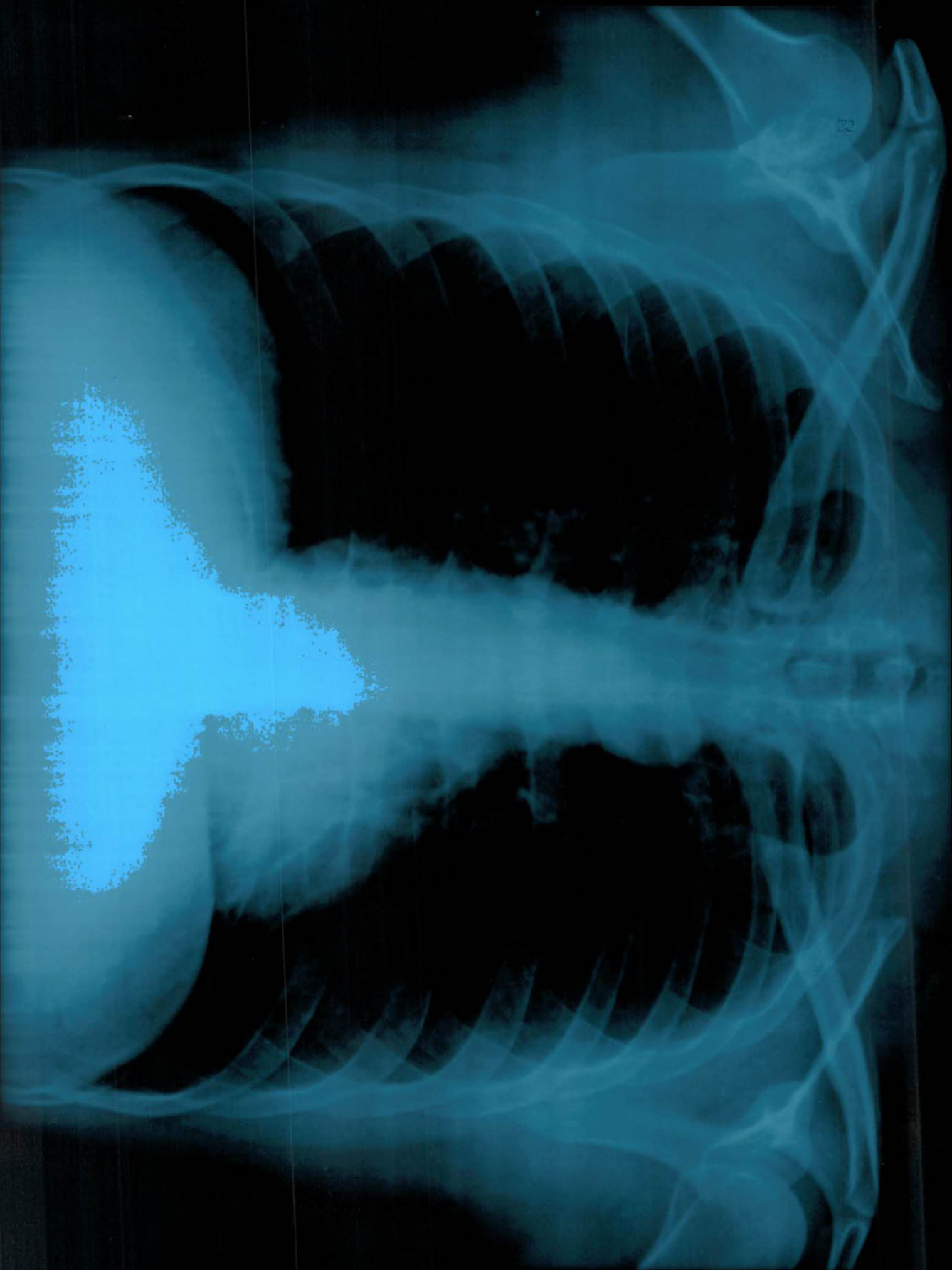
Bony cage and soft tissues are normal.
Cardiothoracic ratio is normal.
Mediastinum is normal.
Both hila are normal.
Both costophrenic angles are clear.
Both domes of diaphragm are normal.
Lung fields are clear. No parenchymal lesion seen.

IMPRESSION: Normal Study.

DR. POOJA GARG
RADIOLOGIST
REG NO. DMC/R/03398

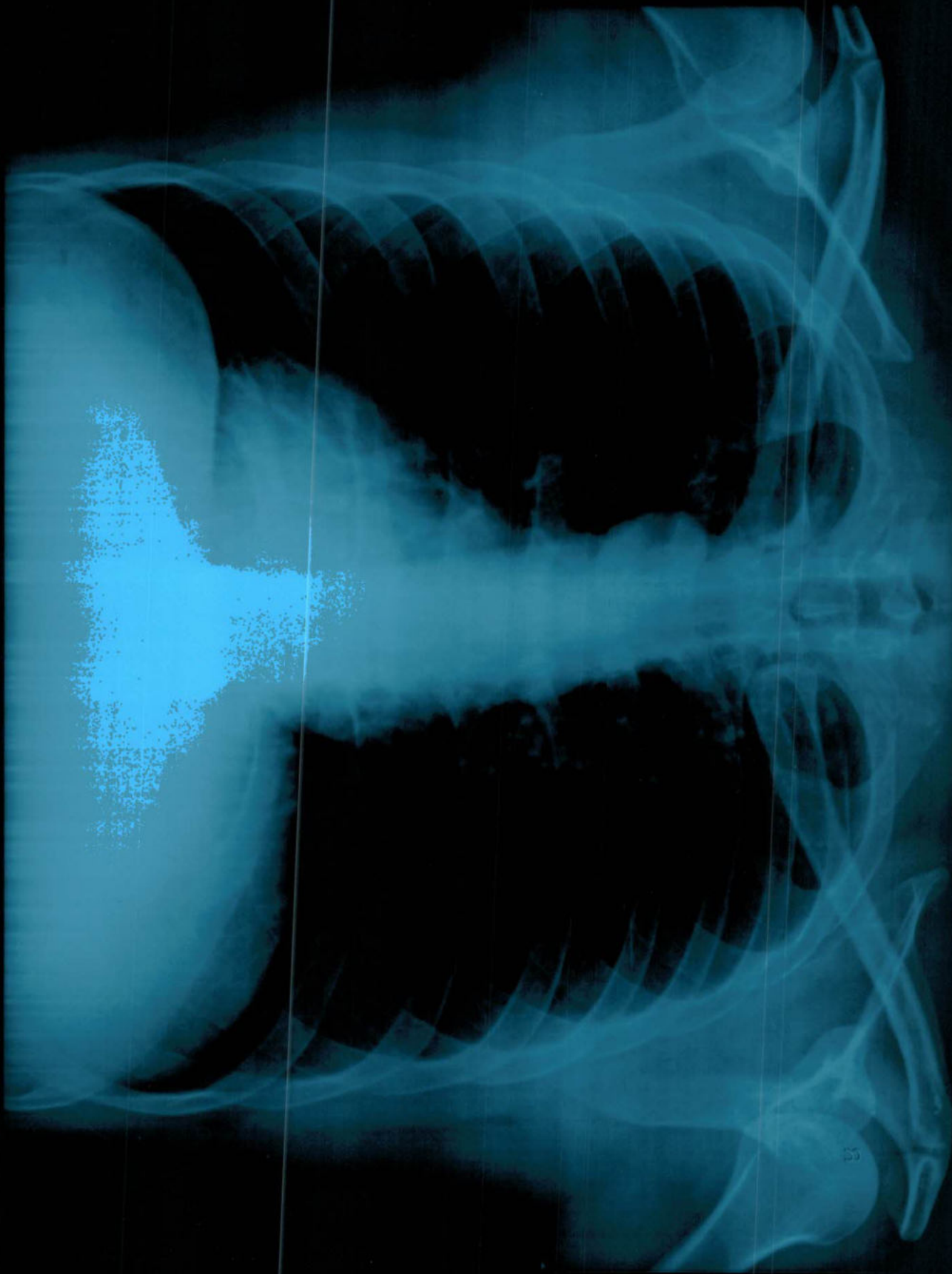
Type By : darshita

47, Harsh Vihar, Pitampura, New Delhi-110034 | Ph.: 011-42480101, 9599913051
E-mail: oneplusul@gmail.com | Web.: www.oneplusul.in



MR SUMIT KUMAR 37 YRS 11-03-2023 M CHEST PA VIEW 3/11/2023
ONEPI US ULTRASOUND LAB 47 HARSH VIHAR PITAMPURA

ОНЕБЛ ПУС Ш ПРАСОУИДИ АВ Ч НАКШН ВИНАВ ПИТАМЬУРА
МЪ СЛИИТ КУИМАЪ 37 УРС 11-03-5053 М ЧЕШТ ПА ВЕМ 31115053



Name	: Mr. SUMIT KUMAR	Age/Sex	: 37 YRS/Male
Ref. By	: Dr. MEDIWHEEL	Lab No	: 012303110010
Date	: 11-Mar-2023	Patient ID	: LSHHI110475

ULTRASOUND EXAMINATION----WHOLE ABDOMEN

Liver is normal in size (13.1 cm) and outline with normal echopattern. No abscess or mass lesion seen. Hepatic veins, portal vein, IVC and aorta are normal. Intrahepatic biliary radicles are not dilated. CBD is normal in caliber.

Gall bladder is not seen (Post op).

Both kidneys are normal in size, shape, position, outline and echopattern. Corticomedullary differentiation is maintained. No pelvicalyceal dilation or calculus or mass lesion is seen.

Spleen is normal in size and echotexture. No mass lesion seen.

Pancreas is normal in size, outline and echotexture .

Urinary bladder is normal in shape and position. No evidence of intravesical stone or mass seen.

Prostate is normal in size, shape and echopattern.

Prostate measures 3.3 x 2.8 x 2.5 cm. **Weight of prostate is 12.5 grams.**

No abnormal bowel wall thickening seen in right iliac fossa.

No free fluid seen anywhere in abdomen.

IMPRESSION: Normal Study.

Dr. POOJA GARG
DR. POOJA GARG
RADIOLOGIST
REG NO. DMC/R/03398

Type By : darshita

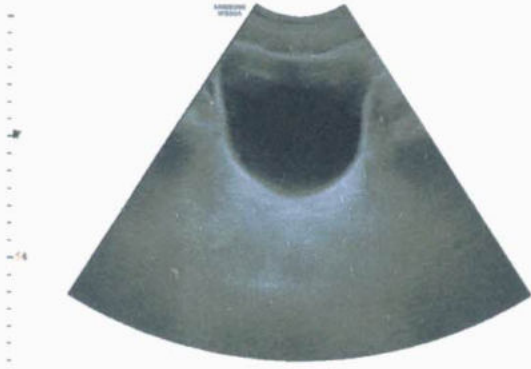47, Harsh Vihar, Pitampura, New Delhi-110034 | Ph.: 011-42480101, 9599913051

E-mail: oneplusul@gmail.com | Web.: www.oneplusul.in

W500A MR SUMIT 37/M OnePlus Ultrasound Lab MI 1.4 11-03-2023
CA1-7A / Abdomen / FR 21Hz Tls 0.1 10:54:14 AM

20 G63 DR135.FA8.P90.Frq.Pan.20.0cm

MR30



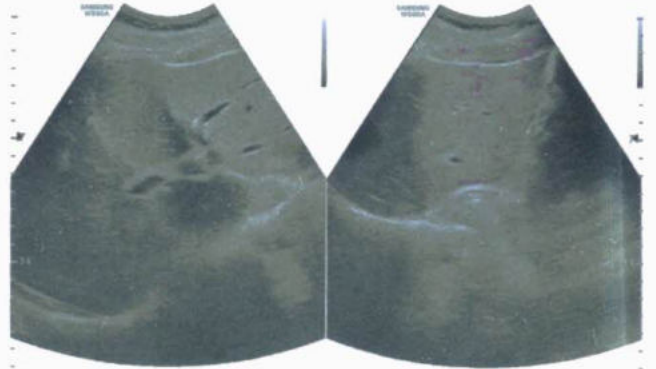
W500A MR SUMIT 37/M OnePlus Ultrasound Lab MI 1.4 11-03-2023
CA1-7A / Abdomen / FR 21Hz Tls 0.1 10:54:40 AM

20 G63 DR135.FA8.P90.Frq.Pan.20.0cm

MR30

20 G63 DR135.FA8.P90.Frq.Pan.20.0cm

MR30



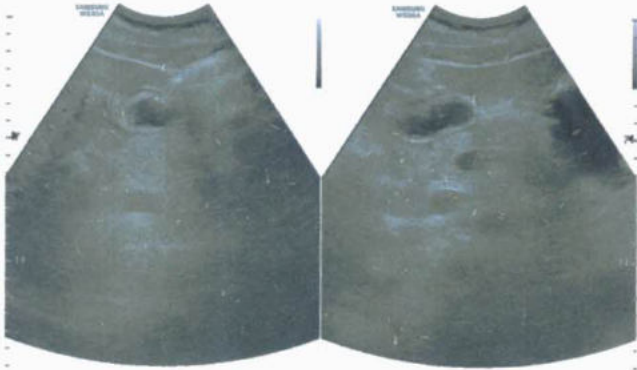W500A MR SUMIT 37/M OnePlus Ultrasound Lab MI 1.4 11-03-2023
CA1-7A / Abdomen / FR 21Hz Tls 0.1 10:54:46 AM

20 G63 DR135.FA8.P90.Frq.Pan.20.0cm

MR30

20 G63 DR135.FA8.P90.Frq.Pan.20.0cm

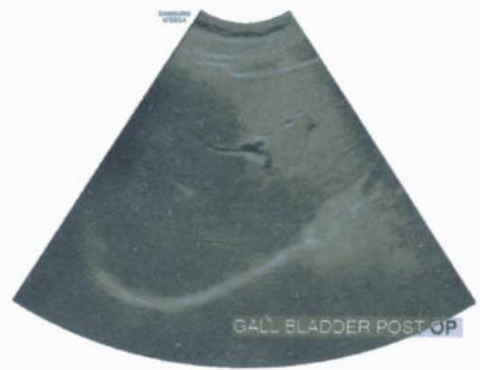MR30



W500A MR SUMIT 37/M OnePlus Ultrasound Lab MI 1.4 11-03-2023
CA1-7A / Abdomen / FR 21Hz Tls 0.1 10:55:04 AM

20 G63 DR135.FA8.P90.Frq.Pan.20.0cm

MR30



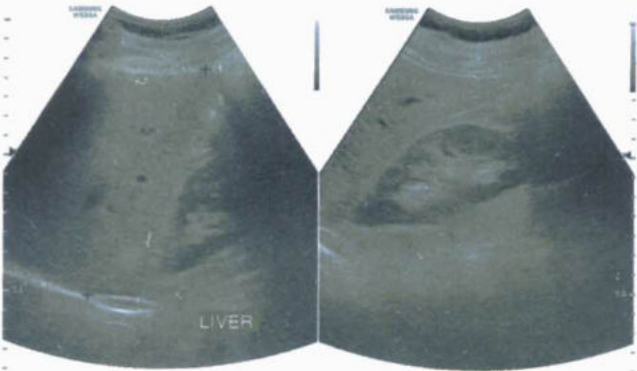W500A MR SUMIT 37/M OnePlus Ultrasound Lab MI 1.4 11-03-2023
CA1-7A / Abdomen / FR 23Hz Tls 0.1 10:55:26 AM

20 G63 DR135.FA8.P90.Frq.Pan.18.0cm

MR30

20 G63 DR135.FA8.P90.Frq.Pan.18.0cm

MR30



LIVER

D1 13.14 cm

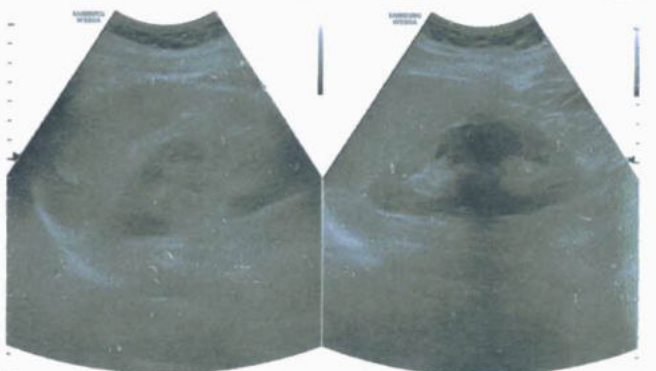W500A MR SUMIT 37/M OnePlus Ultrasound Lab MI 1.4 11-03-2023
CA1-7A / Abdomen / FR 23Hz Tls 0.1 10:55:37 AM

20 G63 DR135.FA8.P90.Frq.Pan.18.0cm

MR30

20 G63 DR135.FA8.P90.Frq.Pan.18.0cm

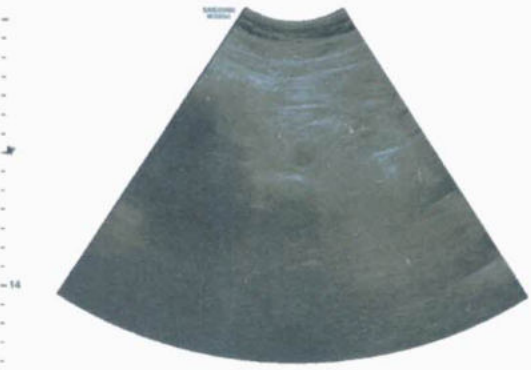
MR30



W500A MR SUMIT 37/M OnePlus Ultrasound Lab MI 1.4 11-03-2023
CA1-7A / Abdomen / FR 23Hz Tls 0.1 10:55:48 AM

20 G60 DR135.FA8.P90.Frq.Pan.18.0cm

MR30



W500A MR SUMIT 37/M OnePlus Ultrasound Lab MI 1.4 11-03-2023
CA1-7A / Abdomen / FR 23Hz Tls 0.1 10:56:28 AM

20 G60 DR135.FA8.P90.Frq.Pan.18.0cm

MR30



E.C.G. REPORT

Patient Name Mr. Surenit Kumar

H. Rate 72/min Age 37/m Date 11/3/23

P-Wave Ⓜ Rhythm Ⓜ Axis Ⓜ

Q-T Ⓜ P-R Interval Ⓜ QRS Ⓜ

Conclusion : Ⓜ S-T Seg Ⓜ T-Wave Ⓜ


CARDIOLOGIST



ELECTRO CARDIO GRAPHIC OBSERVATIONS

Name Mr. Surenit Kumar

Referred By DR.

S. No.
Dated 11/3/23

Facilities:

- Routine Ultrasound
- Real Time 3D/4D/5D Ultrasound
- Color Doppler
- Digital X-Ray
- Amniocentesis, Chorionic Villous Sampling

- ECG • Echo • TMT
- All Lab Tests
- Fully Automated Lab Facility
- Interventional Procedures
- Home Sample Collection Facility

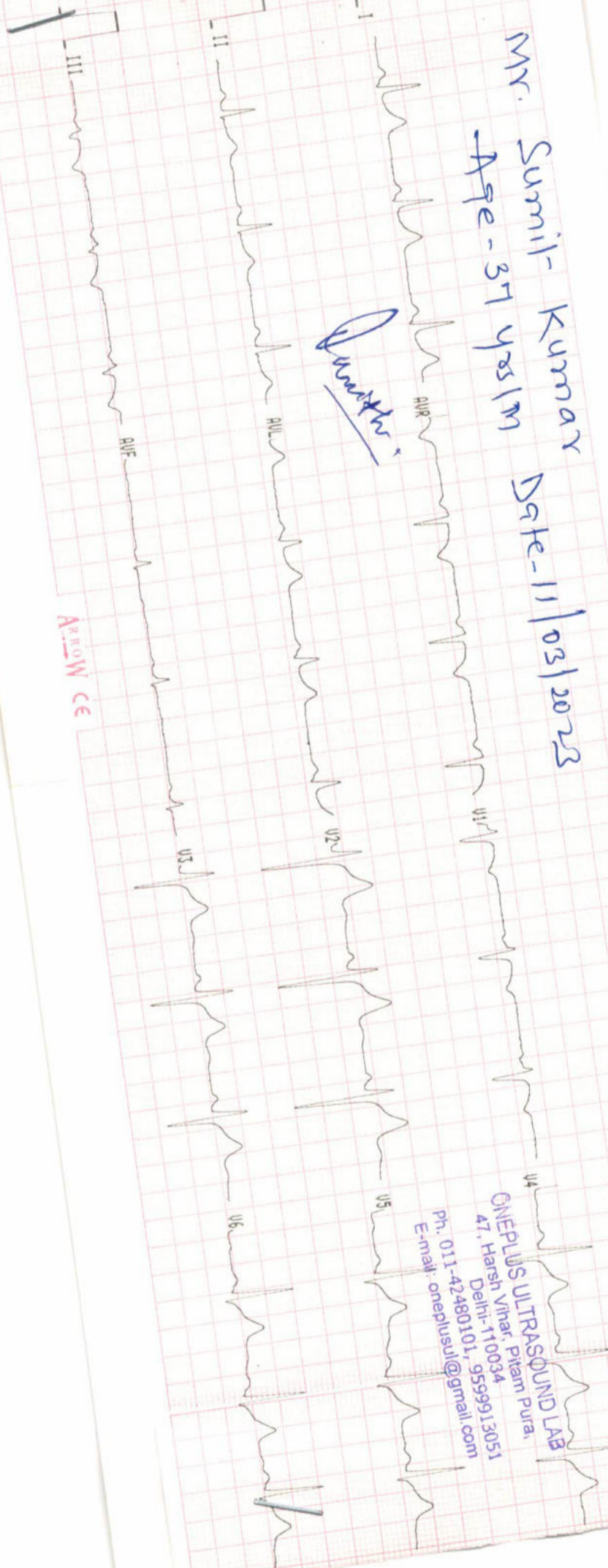47, Harsh Vihar, Pitampura, New Delhi-110034 | Ph.: 011-42480101, 95999913051
E-mail: oneplusul@gmail.com | Website: www.oneplusul.in

MR. Sumit Kumar
Age - 37 yrs | M
DATE - 11/03/2023

Sumit

MEDICARD

25MM/SEC
10MM/MV



Arrow CE

ONEPLUS ULTRASOUND LAB
47, Harsh Vihar, Pitam Pura,
Delhi-110034
Ph. 011-42480101, 9599913051
E-mail: oneplusul@gmail.com