

mediuheel




भारत सरकार
विशेष पहचान आधिकार

भारत सरकार
Unique Identification Authority of India
Government of India

नामांकन क्रम / Enrollment No.: 0648122904102971

To
नवीन हरिचंद्र शेरी
Navina Harishchandra Shetty
W/O Harishchandra Raghu Shetty
12/889 Akhyudaya Nagar
Kadavoli Kalachowki
Cotton Exchange S.O
Tark Road
Mumbai City
Maharashtra 400033
980741617
116160500
AETB16C5003FH



आपका आधार क्रमांक / Your Aadhaar No. :

5404 0586 5028

मेरा आधार, मेरी पहचान



भारत सरकार
Government of India
नवीन हरिचंद्र शेरी
Navina Harishchandra Shetty
दफ्त. निधि / DCB : 31/09/1970
नशिला / Female

5404 0586 5028



Handwritten signature

5/5/2

"DR. PLUS HEALTHCARE CENTRE"
NATHANI HEIGHTS', B-WING,
42, MUMBAI CENTRAL (EAST)

Handwritten signature
DR. HARI GHABLANI
M.B.B.S. (CC.P. (RESP. MEDICINE) PGDIP. (FIDM)S
FELLOW INTENSIVE CARE
MMC REG. NO. - 91702



Dr-Plus Healthcare Centre

NATHANI HEIGHTS, B-Wing, Shop No. 42, Ground Floor, Opp. Mumbai Central Station (East), Mumbai - 400 008.

Full Name

NAVINA SHETTY

51/F

20/03/2022

Life to be assured:

	Type of Test	Actual Reading	Normal Range
1	Fasting Blood Sugar	110.4	70-100 mg%
2	PPBS	138.2	110 TO 140 mg%
3	Total Cholesterol	224	120-200 mg%
4	VERY LOW DENSINTY LEVEL(VLDL)	15	10-30 mg/dl
5	High Density Lipid (HDL)	35	40-60 mg%
6	Low Density Lipid (LDL)	174	Upto 150
7	S. Triglycerides	119.6	50-150 mg%
8	CHOL/HDL	6.4	Upto 5
9	HDL/LDL	0.2	
10	S. Creatinine	0.9	0.5-1.2 mg%
11	Blood Urea Nitrogen (BUN)	16.4	7-21 mg%
12	BUN/CREAT RATIO	18.2	
13	S. Proteins	6.8	6.0-7.9 mg%
14	(a) Albumin	3.6	3.5-5.5 mg%
15	(b) Globulin	3.2	2.0-3.5 mg%
16	A/G RATIO	1.1	
17	S. Bilirubin	0.90	0.3-1.3mg%
18	(a) Direct	0.60	0.0-0.8 mg%
19	(b) Indirect	0.3	0.0-0.5 mg%
20	SGOT (AST)	24.2	05-34 IU
21	SGPT (ALT)	36.4	05-40 IU
22	GGTP (GGT)	35.1	05-50 IU
23	SGOT/SGPT	0.6	
24	HBA1C	6.6	UPTO 6.5
25	S. Alkaline Phosphatase	95.6	30-115 IU
26	T3	160.5	80-180ng/dl
27	T4	5.8	4.6-12 ug/dl
28	TSH	2.81	0.4-4.0 mIU/L
29	SERUM URIC ACID	7.0	2.5-7.2mg/dl
30	URINE SUGAR PP	ABSENT	
31	URINE SUGAR FASTING	ABSENT	
32	BLOOD GROUP	" O POSITIVE "	

DR. RAJESH PATKAR
M.D., D.N.B. (Pathology)
Reg. No. 2013/05/1660



Dr-Plus Healthcare Centre

NATHANI HEIGHTS, B-Wing, Shop No. 42, Ground Floor, Opp. Mumbai Central Station (East), Mumbai - 400 008.

Full Name: NAVINA SHETTY 51/F 20/03/2022
Life to be assured:

HAEMOGRAM

		Normal Range	
1.	Red Blood Cell Count	3.7	[M : 4.5 - 5.6 / F : 3.5 - 5.5/cu.mm]
2.	Hb%	11.2	[M: 14-18 / F : 11-16%]
3.	Hematocrit	36.6	[M : 40-53 / F : 30-47 %]
4.	Indices:		
(a)	MCV(Mean Corpuscular Volume)	87.4	[79-101 cu.mi.]
(b)	MCH(Mean Corpuscular Hb)	30.1	[27-32 pg]
(c)	MCHC(Mean Corpuscular Hb Concentration)	32.5	[32-38%]
5.	Morphology		
	Macrocytes :	--	Microcytes: -- Hypochromia: --
	Poikilocytosis: --	Anisocytosis: --	
6.	Target cells: --		
	Spherocytes: --	Elliptocytes: --	
7.	TOTAL W.B.C.Count	6,500	{4000-11000/cu.mm}
Differential Count			
a)	Neutrophils :	55	[45 - 70%]
b)	Lymphocytes :	35	[20 - 45%]
c)	Eosinophils:	04	[01 - 06%]
d)	Monocytes:	05	[00 - 08%]
e)	Basophils :	01	[00 - 01%]
8.	Platelets :2.98		1.5-4.5 Lacks/cu.mm
9.	Erythrocyte Sedimentation Rate :20	20 mm at end of 1 hour	Method : Westergrens

ROUTINE URINE EXAMINATION (RUA)

1. Physical Examination:

(i)	Colour:	PLAN YELLOW	(ii)	Sediment:	CLEAR
(iii)	Transparency:	CLEAR	(iv)	Reaction:	ACIDIC
(v)	Specific gravity	1.015			

2. Chemical Examination:

(i)	Protein :	NIL	(ii)	Sugar:	NIL
(iii)	Bile salt:	NIL	(iv)	Bile pigment:	NIL


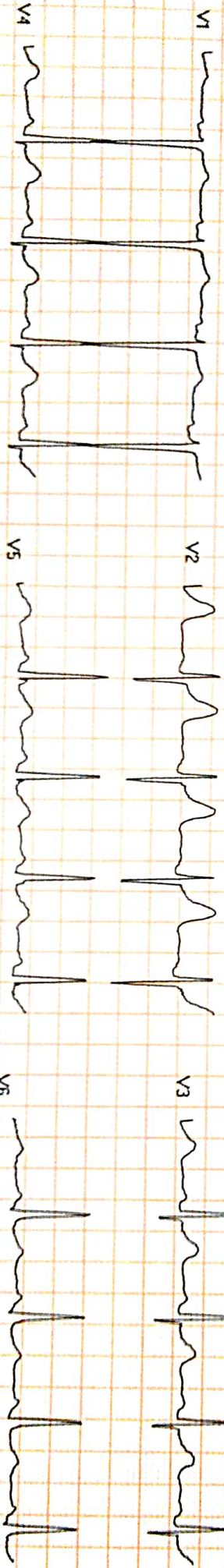
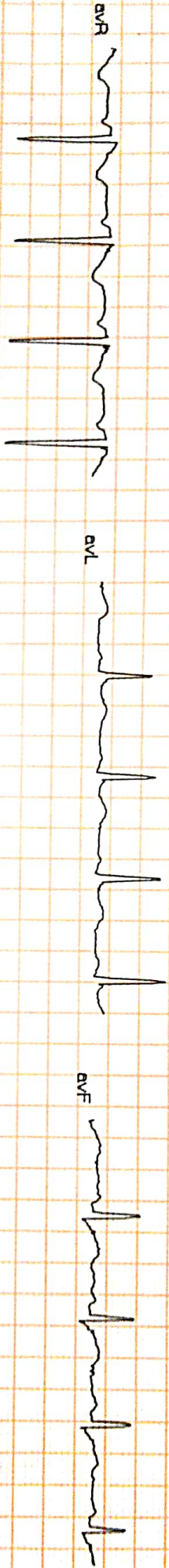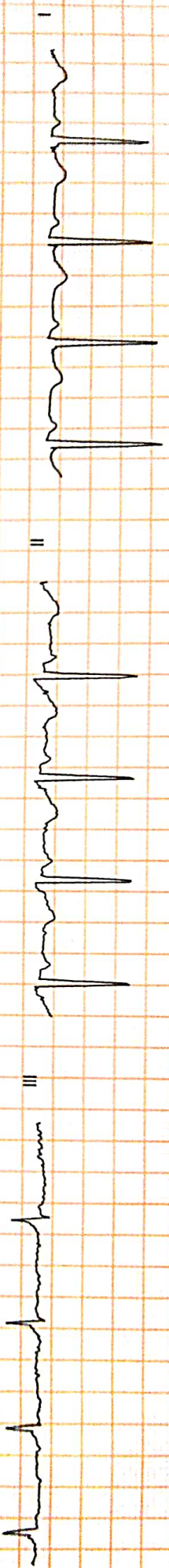
3. Microscopic Examination:

(i)	Red Blood Cells:	ABSENT	(ii)	Epithelial Cells:	1 TO 2/ HPF
(iii)	Crystals:	ABSENT	(iv)	Pus Cells:	2 TO 3/HPF
(v)	Casts:	ABSENT	(vi)	Deposits:	ABSENT
(vii)	Bacteria's :	ABSENT			

DR. RAKESH PATKAR
M.D., D.N.B. (Pathology)
Reg. No. 2013/05/1660

1568 / NAVINA SHETTY / 51 Yrs / F

Heart Rate : 89 bpm / Tested On : 20-Mar-22 10:34:57 / HF 0.05 Hz - LF 100 Hz / Notch 50 Hz / Sn 1.00 Cm/mV / Sw 25 mm/s
/ Refd By: DR. HARI CHHABLANI



7/3/22

DR. PURVI CHHABLANI

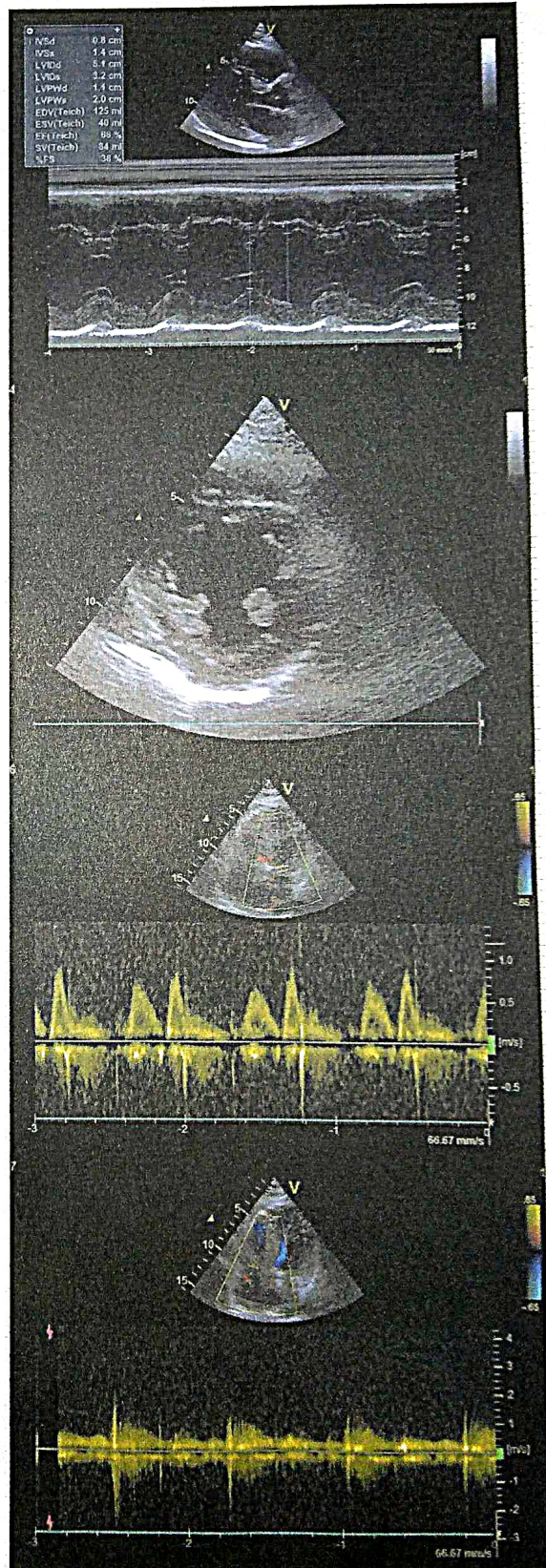
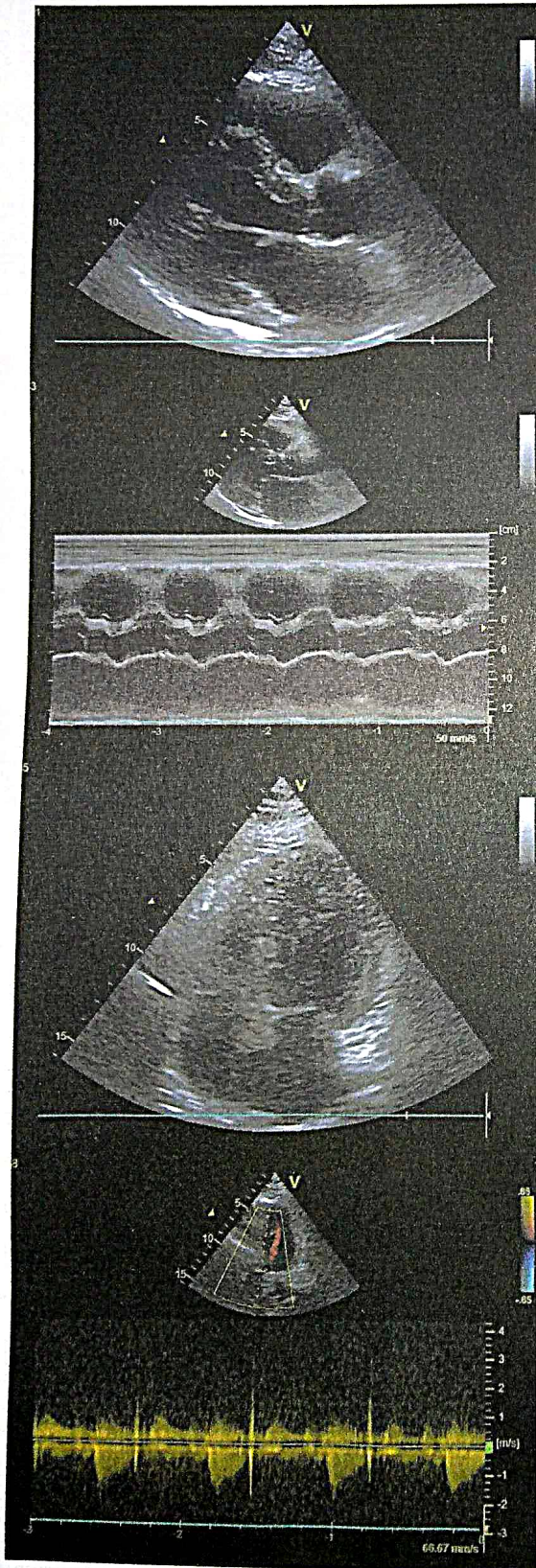
MBBS DNB (Medicine)
Reported By: DR. PURVI CHHABLANI
Mumbai, India

Name NAVINA SHETTY

Sex Female

Age 51

Date 20/03/2022





NAME : NAVINA SHETTY

51/F

DATE:20/03/2022

REF BY : DR. HARI CHHABLANI

2D-ECHO. AND COLOR DOPPLER REPORT

- NORMAL CARDIAC VALVES WITH TRIVIAL TR.
- NORMAL CARDIAC CHAMBERS
- NO E/O REGIONAL WALL MOTION ABNORMALITY. WITH NORMAL LVEF OF 60 %.
- NO E/O PULMONARY HYPERTENSION .PASP 32 mmHg by TR jet.
- NO E/O LEFT VENTRICULAR HYPERTROPHY.
- NO E/O DIASTOLIC DYSFUNCTION.
- NO E/O PERICARDIAL EFFUSION.
- NO E/O INTRACARDIAC CLOT OR VEGETATION
- INTACT IAS / IVS

- CONVENTIONL DOPPLER :

E TO A RATIO IS MORE THAN ONE IN LV INFLOW.

THERE IS NO GRADIENT ACROSS AV,LVOT OR RVOT

PASP FROM TR JET IS 32 mm OF Hg.

- COLOUR DOPPLER:

TRIVIAL TR

EF Slope	108	mm/sec		
Opening Amplitude	21			
Posterior leaflet				
E.P.S.S	02	mm		
Mitral valve prolapse				
Vegetations				
TRICUSPID VALVE	OBSERVED	NORMAL VALUES		
PULMONARY VALVE	OBSERVED	NORMAL VALUES		
EF Slope				
'A' Wave				
Midsystolic notch				
Flutter				
Other Findings				
AORTIC VALVE	OBSERVED	NORMAL VALUES		
Cuspal opening	17	mm		
Closure line	Central			
Eccentricity index	1			
Other Findings				
DIMENSIONS	OBSERVED	NORMAL VALUES		
1. Lvd (Diastolic)	43	26-52		
2. Lvd (Systolic)	28	24-42mm		
3. RVD (Diastolic)	17	7-23mm		
4. IVST (Diastolic)	08	6-11mm		
5. IVST (Systolic)	16			
6. LVPWT (Diastolic)	08	6-11 mm		
7. LVPWT (Systolic)	15			
8. Aortic root	30	22-37mm		
9. left Atrium	35	19-40mm		
	STRUCTURE	REGURGRADING	VELOCITY m/sec	STENOSIS GRADIENT mm/Hg
			Max mean	Peak mean
MITRAL VALVE	NORMAL	0/3	/	/
TRICUSPID VELVE	NORMAL	TRIVIAL	/	/
PULMONARY VELVE	NORMAL	0/4	/	/
AORTIV VALVE	NORMAL	0/4	/	/

DR. PLUS HEALTHCARE CENTRE
 WATHANI HEIGHTS', B-WING,
 42, MUMBAI CENTRAL (EAST)

PH
 DR. P.H. CHHABLANI
 M.B.B.S, DNB. (MEDICINE)
 CONSULTANT PHYSICIAN AND CARDIOLOGIST.

DR. PURVI CHHABLANI
 MBBS, DNB. (Medicine)
 Consultant Physician And Internist
 Reg No 77697



Dr-Plus Healthcare Centre

NATHANI HEIGHTS, B-Wing, Shop No. 42, Ground Floor, Opp. Mumbai Central Station (East), Mumbai - 400 008.

Patient's Name : NAVINA SHETTY

Referred By : SELF

Report Date : 20/03/2022

Age : 51 Years

Sex : FEMALE

X- RAY CHEST

BOTH THE LUNG FIELDS ARE CLEAR.

THE HILAR SHADOWS APPEAR NORMAL.

THE COSTO-PHRENIC ANGLES ARE CLEAR.

THE CARDIAC SHADOWS APPEAR NORMAL.

THE TRACHEAL IS CENTRAL IN POSITION.

THE BONY CAGE APPEARS NORMAL.

DR. A. J. MAZUMDAR

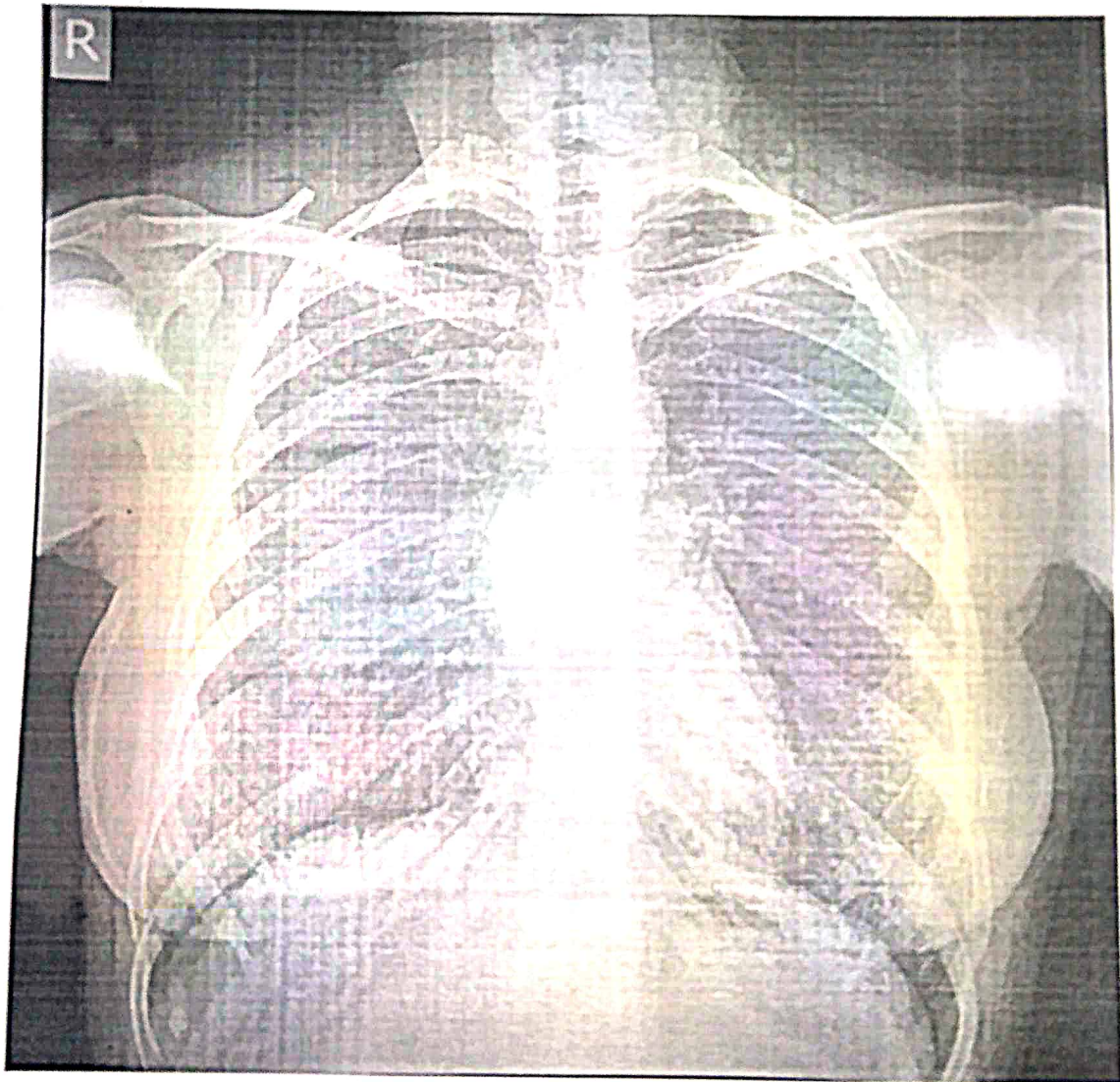
MD. DMRE, MDRD

"DR. PLUS HEALTHCARE CENTRE"
NATHANI HEIGHTS, B-WING,
42, MUMBAI CENTRAL (EAST)

NAME : NAVINA SHETTY

51/F

20/03/2022





Dr-Plus Healthcare Centre

NATHANI HEIGHTS, B-Wing, Shop No. 42, Ground Floor, Opp. Mumbai Central Station (East), Mumbai - 400 008.

Patient Name	:	NAVINA SHETTY	Sex:	Female
Doctor's Name	:	Self	Age:	51 Years
Date	:	20/03/2022		

ULTRASONOGRAPHY OF THE ABDOMEN AND THE PELVIS:

The relevant findings include the following:

HEPATOBIILIARY APPARATUS

Mild hepatomegaly with grade I- fatty liver (17.90 cm). No obvious focal parenchymal lesion is seen. Intrahepatic biliary radicals are not dilated.

The portal vein (1.1 cm) and the common bile duct are normal.

GALL BLADDER

The gall bladder is adequately distended. The wall thickness is normal.

No echogenic contents are noted in its lumen. There is no pericholecystic collection noted.

PANCREAS

The pancreas shows normal echogenicity and size.

No focal or diffuse lesions are noted. No evidence of calcification is noted.

SPLEEN

The spleen appears normal in size and echogenicity.

No focal or diffuse lesions are noted. No evidence of calcification is noted.

KIDNEYS

Right kidney measures : 10.6 x 4.4 cm , Left kidney measures : 10.5 x 5.2 cm.

Both the kidneys appear normal in size, shape and echogenicity. Both the pelvicalyceal system is normal and both corticomedullary differentiations are well maintained.

Right kidney shows 2.7mm calculus in lower calyx with no hydronephrosis .

left kidney shows few calculi in the calyces largest measuring 5.5mm with no hydronephrosis .

There is no obvious focal or diffuse lesion noted.

URINARY BLADDER

The urinary bladder shows anechoic contents. Its wall thickness appears normal.

UTERUS

Uterus measures = 5.45 x 3.9 x 5.7 cms.

Endometrial thickness is 7.4mm

OVARIES


Both ovaries appear normal

Right ovary measures : 2.4 x 1.98 cm , Left ovary measures : 2.5 x 2.2 cm

There is no obvious evidence of abdominal or pelvic lymphadenopathy or ascites noted.

No other obvious pelvic mass is seen. No probe-tenderness is noted.

IMPRESSION: Mild hepatomegaly with grade I- fatty liver.
Bilateral renal non obstructive calculi

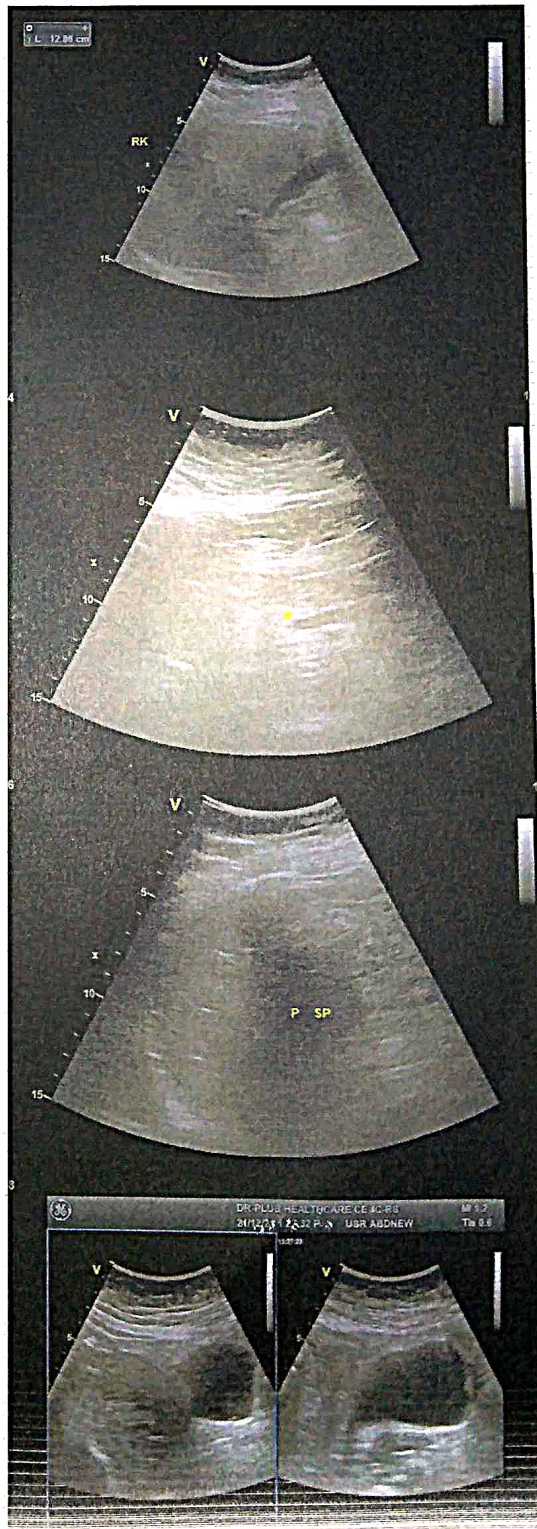
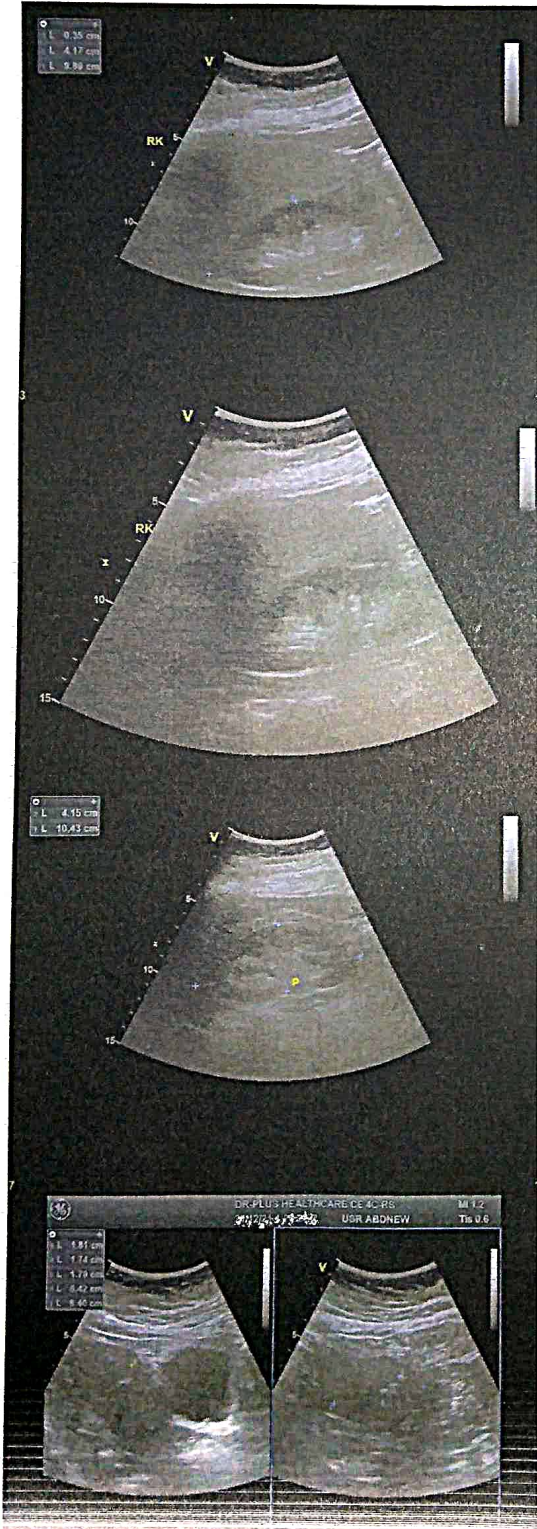

Dr. Parag Jhaveri
MBBS (BOM), DMRE(BOM)
Radio-Sonologist

DR. PLUS HEALTHCARE CENTRE
NATHANI HEIGHTS, B-WING,
42, MUMBAI CENTRAL (EAST)

Name NAVINA SHETTY

Sex Female

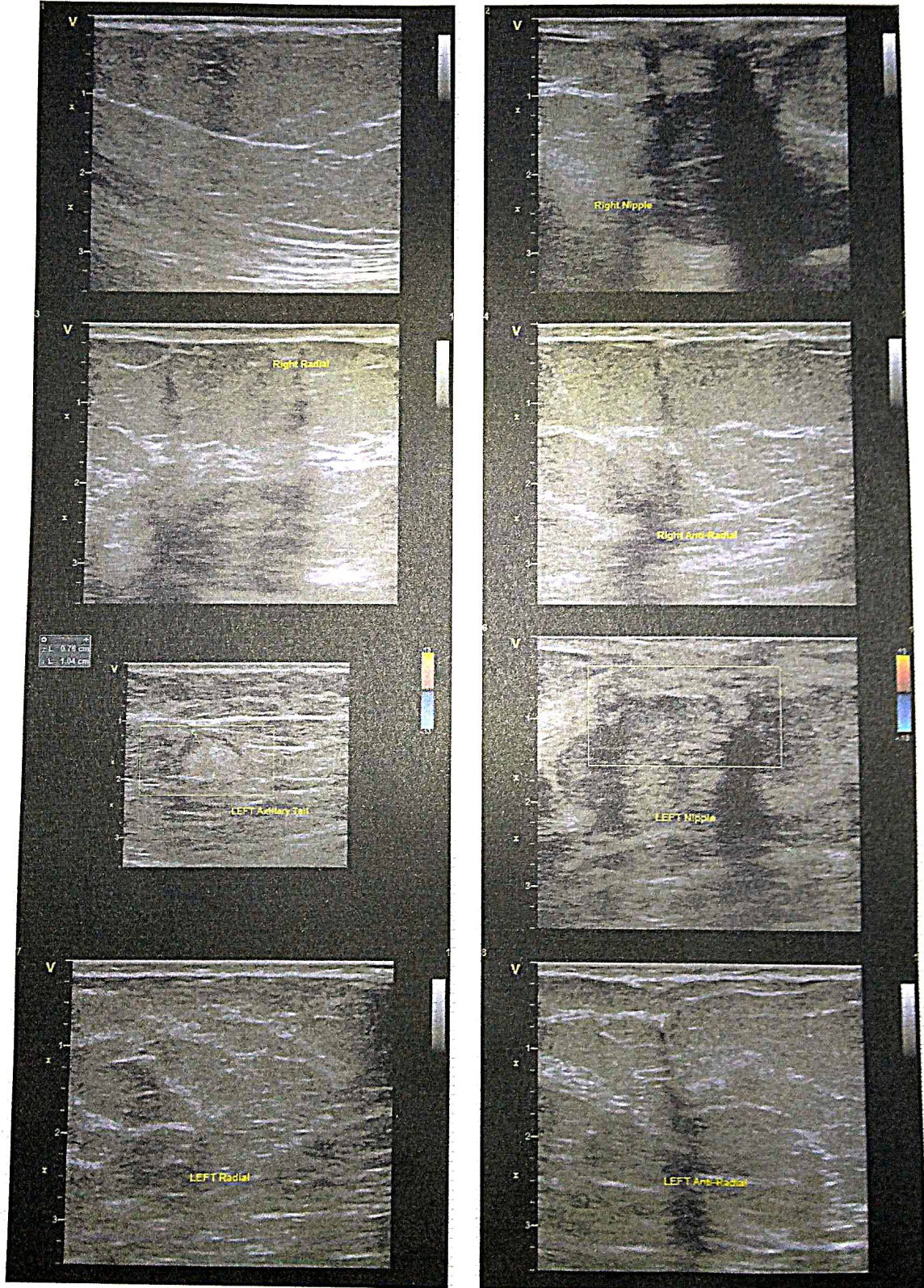
Age 51



Name **NAVINA SHETTY**

Sex **Female**

Age **51**





Dr-Plus Healthcare Centre

NATHANI HEIGHTS, B-Wing, Shop No. 42, Ground Floor, Opp. Mumbai Central Station (East), Mumbai - 400 008.

Patient Name	:	NAVINA SHETTY	Sex:	FEMALE
Doctor's Name	:	DR. HARI CHHABLANI	Age:	51 Years
Date	:	20/03/2022		

BILATERAL MAMMOGRAPHY & ULTRASOUND

Clinical history : Routine screening

Technique : Film screen mammography has been performed using MLO and CC projections.

Findings :

Breast density : Bilateral mixed fibro fatty breast tissue .

No obvious focal lesion , microcalcification seen .

No evidence of any skin thickening or nipple retraction noted


Both axillae normal .

CONCLUSION :

There is no mammographic or ultrasound evidence of malignancy in bilateral breast.

Recommend routine screening mammogram in 1-2 years.

BI-RADS 1 (negative).


Dr. Parag Jhaveri

MBBS (BOM), DMRE(BOM)

Radio-Sonologist

DR. PLUS HEALTHCARE CENTRE
NATHANI HEIGHTS', B-WING,
42, MUMBAI CENTRAL (EAST)



ATTACHED TO : Wockhardt Hospital • Saifee Hospital • Apollo Spectra Hospital

NATHANI HEIGHTS, B-Wing, Shop No. 42, Ground Floor, Opp. Mumbai Central Station (East),
Mumbai - 400 008. • Coll : 98206 46163 • E : drharichhablani@gmail.com

PHYSICIAN REPORT

DATE : 20/03/2022

NAME : NAVINA SHETTY

51/F

PRESENTING COMPLAINS : K/C/O BILATERL RENAL STONE .

K/C/O DYSLIPIDEMIA SINCE 2 YEARS . ON DIET .

TREATMENT : NIL .

PAST HISTORY :NIL

FAMILY HISTORY: NOT SIGNIFICANT

HABITS : NIL.

DENTAL EXAMINATION: NAD

HT.- 170 CM. WT.- 82 Kg. BMI. 28

P: 88/MIN ., REGULAR

BP: 134/80

RS: CLEAR CVS: S1,S2 REGULAR

PA: SOFT

CNS: CLINICALLY NAD

EYE EXAMINATION : NEAR VISION -B/E N6 , DISTANT VISION -BE-- 6/6 , COLOUR VISION - NORMAL

LABS: ATTACHED

ECG: WNL

CHEST X-RAY :WNL

SONOGRAPHY : ATTACHED

2-D-ECHO : WNL

MAMMOGRAPHY : WNL

PAP SMEAR : CLIENT REFUSE FOR PAP SMEAR.

IMPRESSION : FIT ON CLINICAL MEDICAL EXAMINATION .

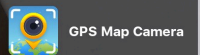DR. HARI CHHABLANI

DR. HARI CHHABLANI

M.B.B.S., F.C.C.P. (RESP. MEDICINE) PGDHHM, PGDMLS

FELLOW INTENSIVE CARE MED

MMC REG. NO. - 91702



Mumbai, Maharashtra, India

Shop No 65, Nathani Heights, Marzban Parsi Colony, Dalal Estate, Mumbai Central, Mumbai, Maharashtra 400008, India

Lat 18.968762°

Long 72.819992°

20/03/22 09:17 AM

