

DATE :- 6/04/2023

HEIGHT - 177 cm.

WEIGHT:- 88.8 Kg.

S/B DR. JAYDEEP BHAMBARE

PATIENT NAME :- Kishor Manohar Khode

AGE/SEX 38/M

BP - 116/79 mm/Hg.  
P - 70 bpm  
SpO2 - 98 %

Hydration maintenance

To loose weight

10-4-23  
LVEF - 60%  
CBC - 13.9 | 6100 | 224  
F/PP - 116 | 124  
Creat - 1.07  
Uric acid - 5.4  
SEPT - 39  
Bili - 0.8  
Proteins - 6.5  
HBAIC - 4.9  
Lipids - 227 | 129 | 151  
ASTH - 1.47

PATIENT NAME:- KISHORE KHODE

AGE/SEX- 38 YRS/M

DATE :-10/04/2023

REF:- MEDIWHEEL INSURANCE

Normal LV Size & Function

No regional wall motion abnormality.

**Normal LV & RV systolic function. LVEF-60%.**

No S/o Diastolic Dysfunction.

Left atrium is normal.

Normal RA and RV size and shape.

Normal RV systolic function.

PASP - 25 mmHg

No Pulmonary Hypertension.

IVC Collapsing with respiration. No Clot/Vegetation.

IVS and IAS are intact.

Normal pericardium. No effusion.

**IMPRESSION:- Good LV Function with LVEF- 60%**

NAME: MR. KISHOR KHODE	DATE: 06/04/2023
AGE/ SEX: 38 YEARS/ MALE	REFERRED BY: HEALTH CHECKUP
<u>ULTRASOUND ABDOMEN &amp; PELVIS</u>	

**Clinical profile- Health checkup**

**Liver:** Normal in size (15 cm), shape and shows normal echotexture. No evidence of any space occupying lesion seen. Intrahepatic biliary radicals are not dilated. Portal vein is normal in caliber.

**Gallbladder:** GB is partially distended. No evidence of any calculus seen. No wall thickening/pericholecystic fluid collection noted. CBD is normal in caliber.

**Pancreas:** Head & part of the body is visualized, appears normal in bulk & echotexture. Rest of the pancreas is obscured by bowel gases.

**Spleen:** Appears normal in size (9 cm), shape and echotexture. No calcification or mass is seen. Splenic vein is not dilated.

**Kidneys:** Right kidney – 11.3 x 4.1 cm. Left kidney - 11.4 x 5.8 cm.

Both kidneys are normal in size, shape, positions and echotexture. Bilateral corticomedullary differentiation appears normal. No hydronephrosis seen. No evidence of any calculus or mass lesion seen.

**Urinary Bladder:** is well distended. No evidence of calculus/ wall thickening noted.

**Prostate** is normal in size and echotexture.

**Free fluid:** No evidence of any free fluid in peritoneal cavity.

**IMPRESSION:**

No significant abnormality seen.

Clinical correlation is suggested.



DR. TRIPTI PAREEK  
(DNB RADIO DIAGNOSIS)

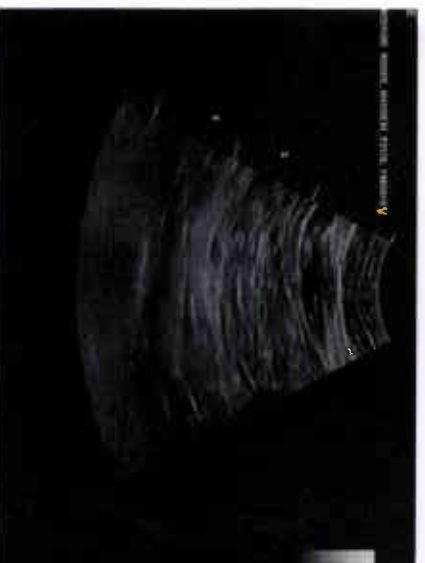
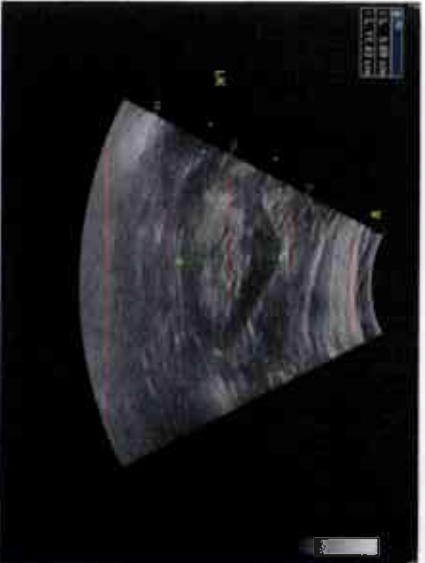
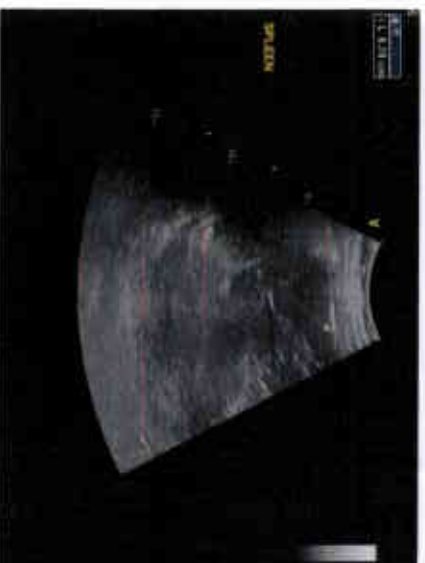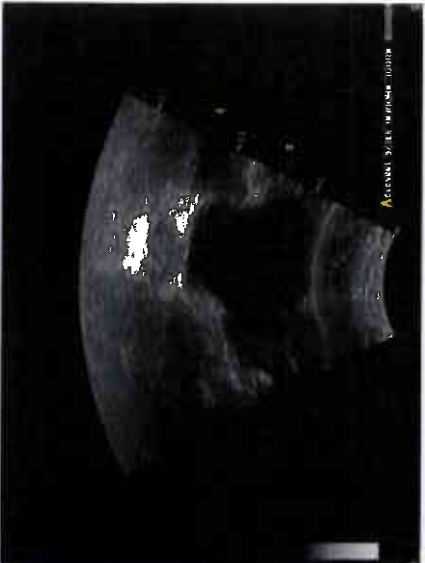
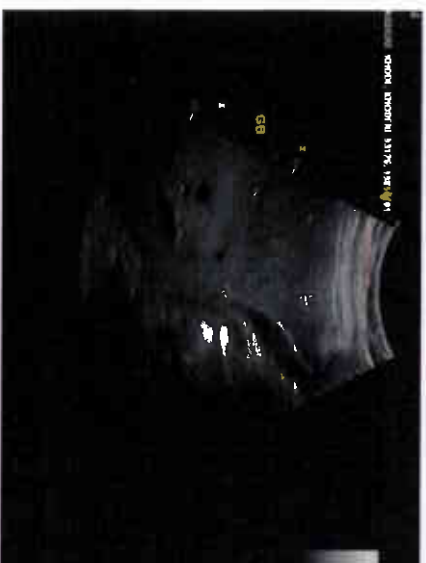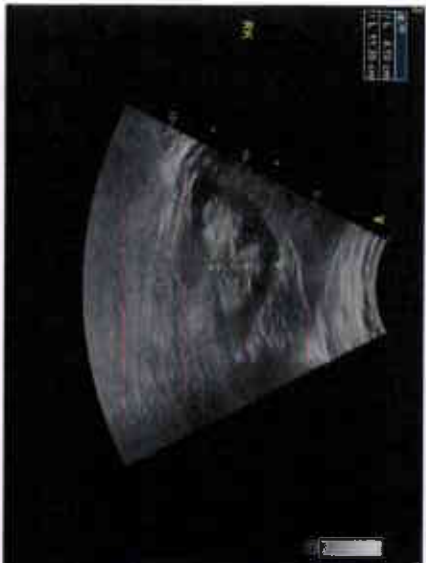
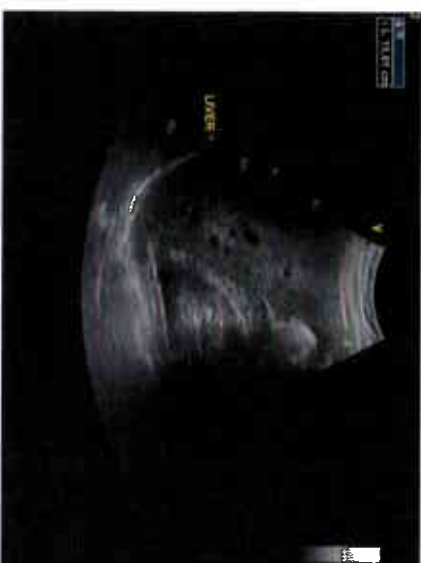
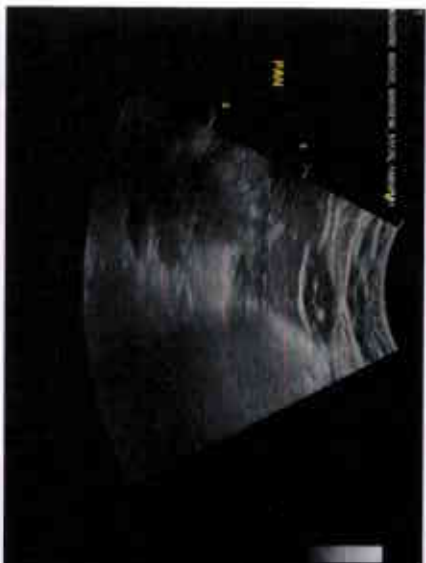**MAGNUM MULTISPECIALITY HOSPITAL**  
**NASIK ROAD, NASHIK**

Name **KHODE, KISHORE**

Sex **Male**

Age **38**

Date **06/04/2023**



NAME: MR.KISHOR KHODE	DATE: 06/04/2023
AGE/ SEX: 38 YEARS / MALE	REFERRED BY: HEALTH CHECKUP

**XRAY CHEST PA (VIEW)**

Both the lungs are clear and do not show any obvious focal lesion.

Bilateral costo-phrenic and cardio-phrenic angles appear clear.

There is no evidence of pleural effusion or pneumothorax on either side.

Both the hilum appear normal.

Domes of diaphragm have normal contours and positions.

Visualised bones and soft tissues reveal no abnormality.

**CONCLUSION:**

No significant abnormality is seen.

DR TRIPTI PAREEK  
(DNB RADIODIAGNOSIS)



**Patient's Name** : Mr. Kishor Khode

**Ref. By**

: Dr. Manoj Chopda (MD,DM)

**Date** : 06/04/2023

**Age/Sex** : 38 yrs /Male

**BLOOD EXAMINATION REPORT**

( By Fully Automated cell counter )

**Haemoglobin** : 13.9 gm % ( 11.0 - 17.0 gm % )

**White Blood Cells**  
**Total Count** : 6100 / cmm ( 4500 - 10500 / cmm )

**Differential Count**

Neutrophils	: 50	%	( 45 - 75 % )
Lymphocytes	: 45	%	( 20 - 48 % )
Eosinophils	: 02	%	( 01 - 04 % )
Monocytes	: 03	%	( 04 - 10 % )
Basophils	: 00	%	( 00 - 01 % )

**Platelets** : 2.24 Lacs/cmm ( 1.5 - 4.5 Lacs/cmm )

<b>R.B.C.</b>	: 3.73	mil/cmm	( 4.00 - 6.00 mil/cmm )
<b>Haematocrit (P.C.V.)</b>	: 36.3	%	( 35 - 50 % )
<b>M.C.V.</b>	: 97	fL	( 80 - 99 fL )
<b>M.C.H.</b>	: 37.2	pg	( 27 - 32 pg )
<b>M.C.H.C.</b>	: 38.2	g/dl	( 31.5 - 36 g/dl )
<b>R.D.W.</b>	: 14.0	%	( 10.0 - 15.0 % )

**E.S.R.** : 05 mm/hrs ( 0 - 15 mm/hrs )

*hsh*

Pathologist  
 Dr. Sudhir Sankalecha  
 MD (Path)

Reg. No. 70409pp.

Bytco Colle, Nashik, Maharashtra, Nashik Road, Nashik, Maharashtra, 422002  
 Phone : 0253 2994030 / 9112291199, Email - info.magnnumhospital@gmail.com

Pathologist  
 Dr. S.A. Sangale  
 MD (Path)



**Patient's Name** : Mr. Kishor Khode      **Date** : 06/04/2023  
**Ref. By** : Dr. Manoj Chopda (MD,DM)      **Age/Sex** : 38 yrs /Male

**LIPID PROFILE REPORT**

<u>TEST</u>	<u>OBSERVED VALUE</u>	<u>NORMAL VALUE</u>
S. Cholesterol	227.8 mg/dl	Up to 200 mg/dl
S. Triglyceride	129.8 mg/dl	Up to 160 mg/dl
HDL Cholesterol	50.3 mg/dl	30 – 65 mg/dl
LDL Cholesterol	151.5 mg/dl	75 – 165 mg/dl
VLDL Cholesterol	26.0 mg/dl	6.0 – 38.0 mg/dl
LDL/HDL Ratio	3.01	2.5 – 4
Chol/HDL Chol Ratio	4.52	3 – 5.5

Pathologist  
Dr. Sudhir Sankalecha  
MD (Path)  
Reg. No. 70405

Check by Technician

Pathologist  
Dr. S.A. Sangale  
MD (Path)  
Reg. No. 2002/07/2718



**Patient's Name** : Mr. Kishor Khode      **Date** : 06/04/2023  
**Ref. By** : Dr. Manoj Chopda (MD,DM)      **Age/Sex** : 38 yrs /Male

**THYROID FUNCTION TEST REPORT**

<u>TEST</u>	<u>OBSERVED VALUE</u>	<u>NORMAL RANGE</u>
T 3	1.38      ng/ml	0.69 – 2.15      ng/ml
T 4	8.04      ug/dl	5.2 – 12.7      ug/dl
TSH	1.47      uIU/ml	0.4 – 4.5      uIU/ml

**METHOD** : By Chemiluminescence System

Pathologist  
Dr. Sudhir Sankalecha  
MD (Path)  
Reg. No. 70405

Check by Technician

Pathologist  
Dr. S.A. Sangale  
MD (Path)  
Reg. No. 2002/07/2718

Patient's Name : Mr. Kishor Khode

Date : 06/04/2023

Ref. By : Dr. Manoj Chopda (MD,DM)

Age/Sex : 38 yrs /Male

**BLOOD EXAMINATION REPORT**

<u>Test</u>	<u>Result</u>
Blood Group	: ' O '
Rh Factor	: Positive

Pathologist  
Dr. Sushir Sankalecha  
MD (Path)  
Reg. No. 70405

Check by Technician  


Pathologist  
Dr. S.A. Sangale  
MD (Path)  
Reg. No. 2002/07/2718



**Patient's Name** : Mr. Kishor Khode

**Ref. By**

: Dr. Manoj Chopda (MD,DM)

**Date** : 06/04/2023

**Age/Sex** : 38 yrs /Male

### URINE EXAMINATION REPORT

#### PHYSICAL CHARACTERISTICS

Volume : 20 ml  
Colour : Yellow

Appearance : Clear  
Reaction : Acidic

#### CHEMICAL EXAMINATION

Albumin : Nil  
Sugar : Nil  
Ketones : Nil

Bile Salts : Absent  
Bile Pigments : Absent

#### MICROSCOPIC EXAMINATION

Epithelial Cells : 2 - 4/hpf  
Pus Cells : 2 - 4/hpf  
Crystals : Absent  
Other : Absent

R.B.C.s : Absent  
Casts : Absent  
Bacilli : Absent

Pathologist  
Dr. Sudhir Sankalecha  
MD (Path)  
Reg. No. 70405

Check by Technician

Pathologist  
Dr. S.A. Sangale  
MD (Path)  
Reg. No. 2002/07/2718



I: 0  
 KISHOR KHODE  
 Male - 38 Years  
 Department: ER  
 06-04-2023 08:57:30 AM  
 HR : 69 bpm  
 P : 116 ms  
 PR : 152 ms  
 QRS : 90 ms  
 QT/QTc : 392/420 ms  
 P/QRS/T : 18/10 °  
 RV5/SV1 : 0.808/0.321 mV

Diagnosis Information:  
 Sinus rhythm  
 Inferior I wave abnormality is nonspecific  
 Borderline ECG  
 Report Confirmed by:

06/19/23  
 Kishor Khode  
 38 yr. M.  
 8:57 AM

