



ओम प्रकाश मेहरा
Om Prakash Mehra
जन्म तिथि/DOB: 14/04/1976
पुरुष/ MALE



3398 4582 8530
VID: 9158 2003 8862 6296

मेरा आधार, मेरी पहचान



भारतीय रिजर्व बैंक
Reserve Bank of India

पता:
S/O: रामदेव, तहसिल बानसुर, धाने रामदेव की गांव कोथल
सन्थालपुर, अलवर,
राजस्थान - 301402

Address:
S/O: Ramdev, tehsil banasur, dhani ramdev
ki gavn kothal, Santhalpur, Alwar,
Rajasthan - 301402



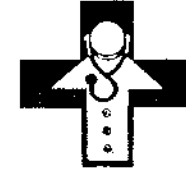QR Code with Photograph

3398 4582 8530
VID: 9158 2003 8862 6296





THAREJA CLINIC



1, Ram Kuteer Company Bagh Road, ALWAR (Raj.) ☎ 2700184, 2331842 (H)

POLY CLINIC EQUIPPED WITH COMPUTERISED AUTOANALYSER, CBC
SONOGRAPHY, X-RAY, OPG, COMPUTERISED ECG, EEG &
DIAGNOSTIC LABORATORY, COMPUTERISED LUNG FUNCTION TEST

DEADDICATION CENTRE

Dr. M.N. Thareja

M.B.B.S., F.C.G.P.

F.R.S.T.M. & H (London)

- ❖ Vice Chairperson of Sex Education & Parenthood International.
- ❖ Vice President of National Sexology Society of India
- ❖ Member of American Association of Sex Educator USA
- ❖ Executive Member of Indian Andro-Pause Society
- ❖ Life Member of Association for Prevention & Control of Rabies in India (APCRI)
- ❖ Life Member of Indian Red Cross Society
- ❖ Life Member of IMA College of General Practitioners
- ❖ Post Graduate Certificate Course of HIV/AIDS & STD Management Counsellor.
- ❖ Post Graduate Certificate Course Environmental & Occupational Health.

ELECTROCARDIOGRAM

Patient Name *Omprakash Mehra*

Date *24/9/22* Age *45* Sex *M*

Referred by Dr. *M.N. Thareja*

Patient name: **Omparakam mehos**

HR	91/min	QRS	23
Intervals:		QRS	15
RR	661 ms	P	7
P	103 ms	P (II)	0.07 mV
PR	147 ms	P (V1)	1.08 mV
QRS	78 ms	R (V5)	1.82 mV
QT	330 ms	Sokol	2.91 mV
QTc	407 ms		

SINUS RHYTHM
NORMAL ECG

UNCONFIRMED REPORT

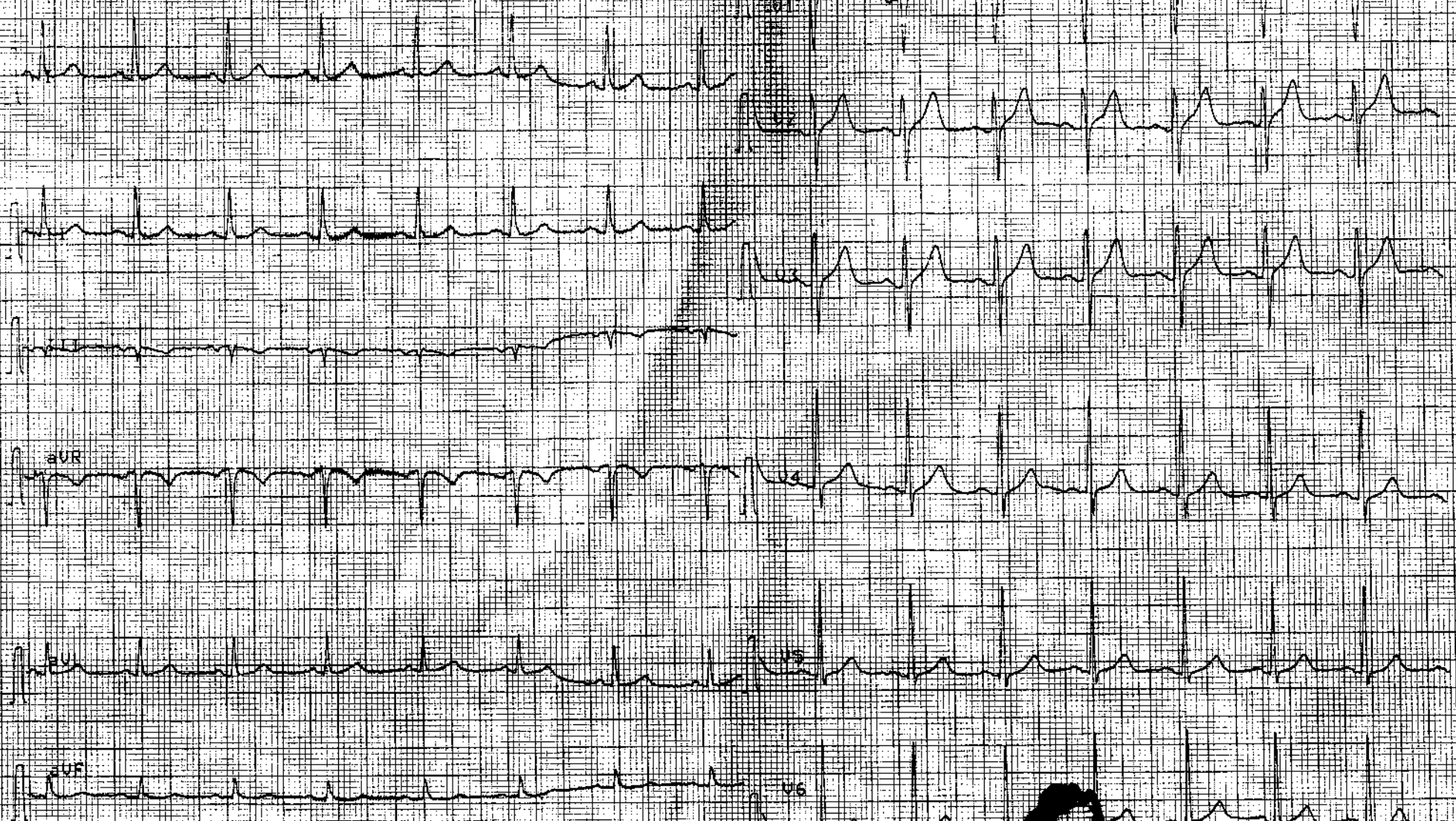
Sex: **MS** Y, F
 cm, kg
 mmHg

24/9/22

10 mm/mV

12 mm/mV

Ⓟ



25 mm/s SCHILLER

0.05-35 Hz F50 S8 24-SEP-22 10:47:33

art No. 2.157017M 0123

S.BA



THAREJA NURSING HOME

1, Ram Kuteer Company Bagh Road, ALWAR - 301001 (Raj.)
Mob. 9982111801, Ph. 0144-2700184, 2331842, Telefax: 0144-2342339
E-mail: drmnthareja@yahoo.com



Name Omparaksh mehra Age 45 Yr OPD/UHID..... Date 24/9/22

Address Mobile No.....

VITALS	B.P.	Pulse	Temp.	Wt.	Ht.	Allergies
--------	------	-------	-------	-----	-----	-----------

Complaints

Routine eye check up

Findings

*VA - 6/6^c glasses $\frac{S/L}{S/L}$
Cornea clear B/E*

Investigation

*- N6 e glasses
- N6*

Treatment

*Color vision - WNL
- WNL
①
Continue glasses*

DR. M.N. THAREJA

7233 (RMC)
Male Infertility Specialist

DR. SAVITA THAREJA

7600 (RMC)
Female Infertility Specialist

DR. JAYANT THAREJA

A-0824 (RSDC)
M.D.S.
Oral & Maxillo - Facial Surgery
Ex Resident Trauma Centre,
AIIMS, Delhi

DR. SHIVANI THAREJA

10807 / 31220 (RMC)
Ophthalmologist
Cornea Specialist

DR. PRERNA THAREJA

A-3574
MDS (Endodontics)
Root Canal Specialist
Ex Resident
AIIMS, Jodhpur

DR. H.R. GUPTA

1744 (RMC)
Senior Consultant
M.S. Gen Surgeon

DR. VARUN SAPRA

Reg. No. 70990 (DMC)
MBBS DNB ORTHO, D.ORTHO
Joint Replacement &
Arthroscopy Surgeon

Shivani
Dr. Shivani Thareja
M.S. (OPHTHAL)
Fellow (CORNEA)
L.V. Prasad Eye Institute
CORNEA CONSULTANT

Pain Scale

0



No Pain

2



Mild Pain

4



Distressing

6



Disressing

8



Intense

10



Excruciating



THAREJA NURSING HOME

1, Ram Kuteer Company Bagh Road, ALWAR - 301001 (Raj.)
Mob. 9982111801, Ph. 0144-2700184, 2331842, Telefax: 0144-2342339
E-mail: drmnthareja@yahoo.com



Name Omprakash Mehra Age 45/M Yr OPD/UHID..... Date 24/9/2022

Address Mobile No.....

VITALS	B.P.	Pulse	Temp.	Wt.	Ht.	Allergies
--------	------	-------	-------	-----	-----	-----------

Complaints

- Regular Dental checkup

Findings

Mantoux good oral hygiene

Investigation

Mild gingival recession
Adv scaling

Treatment

DR. M.N. THAREJA

7233 (RMC)
Male Infertility Specialist

DR. SAVITA THAREJA

7600 (RMC)
Female Infertility Specialist

DR. JAYANT THAREJA

A-0824 (RSDC)
M.D.S.
Oral & Maxillo - Facial Surgery
Ex Resident Trauma Centre,
AIIMS, Delhi

DR. SHIVANI THAREJA

10807 / 31220 (RMC)
Ophthalmologist
Cornea Specialist

DR. PRERNA THAREJA

A-3574
MDS (Endodontics)
Root Canal Specialist
Ex Resident
AIIMS, Jodhpur

DR. H.R. GUPTA

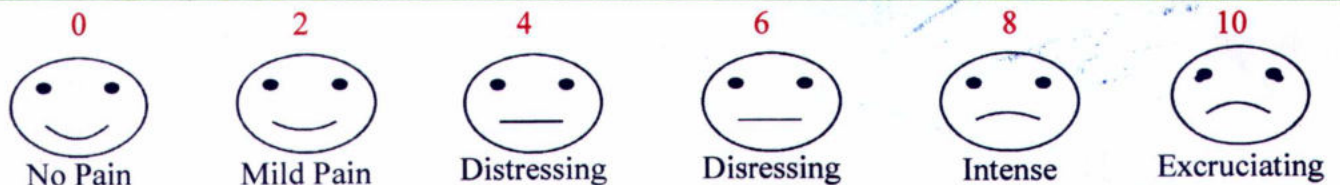
1744 (RMC)
Senior Consultant
M.S. Gen Surgeon

DR. VARUN SAPRA

Reg. No. 70990 (DMC)
MBBS DNB ORTHO, D.ORTHO
Joint Replacement &
Arthroscopy Surgeon

Jayant
Dr. Jayant Thareja
M.D.S.
Oral & Maxillofacial Surgery
Ex-Resident (AIIMS, TRAUMA CENTRE)
09982

Pain Scale





THAREJA NURSING HOME



DIGITAL X-RAY, OPG, COMPUTERISED ECG & EEG, DIAGNOSTIC LABORATORY EQUIPED WITH COMPUTERISED AUTO ANALYZER & CBC

1, Ram Kuteer, Company Bagh Road, ALWAR - 301001 (Raj.) Ph: 0144-2700184, 2331842

PROPOSAL NO. PKG1000228

Patient Name MR OM PRAKSH

Date 24/09/2022

Ref. By Dr. M. N. THAREJA

Age 45 Yrs.

Sex M

Details of packages		Patients report	Units	Normal value
HB		16.0	gm%	M-13.5-18, F-11.5-16.5
TRBC		5.68	million /cu mm	M-4.0-5.5, F-3.9-5.6
TWBC		5600	cu mm	4000-11000
DLC	Polymorphs	55	%	42-75
	Lymphocytes	40	%	20-50
	Eosinophil	05	%	1-6
ESR		03	mm 1 st Hr.	M-0-9, F-0-20
Platelets		139000	Lack / cu mm	1.5-4
PCV		65.0	%	37-54
MCV		79.2	Cubicmicrons	86-98
MCH		28.2	Picograms	26-34
MCHC		35.6	%	32-36
Blood Grouping & Rh Factor		" B "Rh+(POSITIVE)		
BUN		13.0	mg %	M-7-20
S. Creatinine		0.87	Mg/100ml	0.9-1.4 mg /100 ml
HBsAg		-		
HIV I & II		-	Elisa Method	
HbA1C		5.2	%	4-6%
VDRL		-		

Details of packages		Patients report	Units	Normal value	
LFT	GGTP	27	U/L	5-60	
	SGOT	21	Units / ml	Upto 40	
	SGPT	24	Units / ml	Upto 40	
	S. Bilirubin	Total Bilirubin	0.6	mg%	Upto 1.2
		Direct Bilirubin	0.4	mg%	0-0.25
		Indirec Bilirubin	0.2	mg%	
		T. Protein	7.7	Gm%	6.2-8.3
		S. Albumin	4.3	Gm%	3.2-5.3
		Globulin	3.4	Gm%	
		Alkaline phosphate	102	IU/L	60 - 170
	S. Calcium	-	Gm%	8.5-10.5	
	Uric Acid	3.9	Mg%	2.5-7 mg%	
Blood Sugar Fasting		78.0	Mg%	60-110 mg %	
Blood Sugar PP		138.0	Mg%	Upto 160	
Lipid Profile	S. Cholesterol	243.0	mg%	120-220	
	S. Triglycerides	130.0	mg/ml	Upto 170	
	HDL Cholesterol	55.0	IU/L		
	LDL cholesterol	162.0	IU/L	450 at 37° C	
	VLDL	26.0	mg %	Upto 35	

Routine Urine Analysis

Physical/ Chemical	Appearance	Microscopic:	
Appearance	Clear	RBCs	Nil
Specific Gravity	1010	WBCs	2-3/HPF
Ph	ACIDIC	Epith. Cells	1-2/HPF
Albumin	Nil	Casts	Nil
Glucose F	NIL	Crystals	Nil
Ketones	----	Bacteria	Nil
Blood	Nil	Glucose P.P.	NIL

Signature of Technician

Signature of Doctor

This Report is not Valid for Medical Legal Purpose

Thareja Nursing Home Alwar-301001 (Raj.)



THAREJA NURSING HOME



DIGITAL X-RAY, OPG, COMPUTERISED ECG & EEG, DIAGNOSTIC
LABORATORY EQUIPED WITH COMPUTERISED AUTO ANALYZER & CBC

1, Ram Kuteer, Company Bagh Road, ALWAR - 301001 (Raj.) Ph: 0144-2700184, 2331842

Name : **MR OM PRAKASH**

Age : **45**

Sex : **MALE**

Ref. By : **M N THAREJA**

Lab No. :

Date : **September 24, 2022**

Immunology

<u>Test</u>	<u>Value</u>	<u>Units</u>	<u>Biological Ref. Values</u>
Prostate Specific Antigen (PSA)	0.21	ng/mL	< 4 ng/mL

Method : **Fluorescence Immunoassay Technology**

Sample Type : **Serum / Plasma / Whole Blood**

Supported By : **GYRO DIAGNOSTICS, JAIPUR**

Clinical Information :

Prostate Specific Antigen (PSA) is a Neutral Serine Protease with Chymotrypsin-like activity and Composed of a Single Polypeptide chain of 237 Amino Acids. It is an Intracellular Glycoprotein Containing 7-8% Carbohydrate as a Single N-linked Oligosaccharide side Chain, and has a Molecular Weight of Approximately 33 KDa. PSA is Synthesized by the Glandular Epithelium of the Prostate and Present in benign Hyperplastic and Malignant Prostatic Tissue, in Metastatic Prostatic Carcinoma, in Prostatic Fluid, and Seminal Plasma. Low Levels of PSA are Found in the Blood of Normal Male as a Result of Leakage of the Antigen from the Prostate Gland into Circulation. The Elevated Levels of PSA in the Blood are Associated with Prostatic Pathology, including Prostatitis, Benign Prostatic Hyperplasia (BPH), and Prostate Cancer.

Vijay

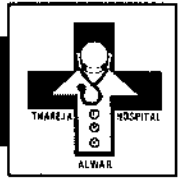Signature of Technician

Dr. *M. N. Thareja*
Signature of Doctor
Thareja Nursing Home
Alwar-301001, (Raj.)

This Report is not Valid for Medical Legal Purpose



THAREJA NURSING HOME



DIGITAL X-RAY, OPG, COMPUTERISED ECG & EEG, DIAGNOSTIC LABORATORY EQUIPED WITH COMPUTERISED AUTO ANALYZER & CBC

1, Ram Kuteer, Company Bagh Road, ALWAR - 301001 (Raj.) Ph: 0144-2700184, 2331842

Name : **OMPRAKASH MEHRA** age **45** Sex : **MALE**

Ref. By : **M.N. THAREJA** Lab No. : Date : **September 24, 2022**

HORMONES & MARKERS

Test	Value	Units	Biological Ref. Values
T3 (Total Triiodothyronine)	1.15	ng/dL	0.60-1.81 ng/dL Adults
T4 (Total Thyroxine)	4.21	µg/dL	3.2-12.60 µg/dL : Adults
TSH (Thyroid Stimulating Hormone)	2.28	µIU/mL	Adults : 0.35-5.50 µIU/mL

Interpretation of TSH :-

Children

0 Days : 1.0~39.0 uIU/mL
 5 days : 1.7~9.1 uIU/mL
 1 year : 0.4~8.6 uIU/mL
 2 years : 0.4~7.6 uIU/mL
 3 years : 0.3~6.7 uIU/mL
 4-19 years : 0.4~6.2 uIU/mL

Adults

20-54 years : 0.35-5.50 uIU/mL
 55-87 years : 0.5-8.9 uIU/mL

Pregnancy

1st Trimester : 0.30 - 4.50 µIU/mL
 2nd Trimester : 0.50 - 4.60 µIU/mL
 3rd Trimester : 0.80 - 5.20 µIU/mL

Interpretation of TSH :-

Children

3.20 - 34.6 µIU/mL 1- 2 Days
 0.70 - 15.4 µIU/mL 3 - 4 Days
 0.70 - 9.10 µIU/mL 15 Days - 5 Months
 0.70 - 6.40 µIU/mL 5 Months - 20 Years

Pregnancy

0.30 - 4.50 µIU/mL 1st Trimester
 0.50 - 4.60 µIU/mL 2nd Trimester
 0.80 - 5.20 µIU/mL 3rd Trimester

Method : **Fluorescence Immunoassay Technology**

Sample Type : **Fresh Blood Serum**

Remarks :

Primary malfunction of the Thyroid gland may result in excessive (hyper) or Low (hypo) release of T3 or T4. In addition, as TSH directly affect thyroid function, malfunction of the pituitary or the hypothalamus influences the thyroid gland activity.

Disease in any portion of the thyroid-pituitary-hypothalamus system may influence the level of T3 and T4 in the blood, in Primary Hypothyroidism,

TSH levels are significantly elevated, while in secondary and tertiary hypothyroidism, TSH levels may be low. In addition, in Euthyroid sick syndrome, multiple alterations in serum thyroid function test findings have been recognized.

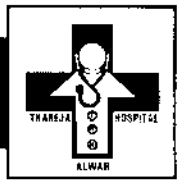Vijay
Signature of Technician

Dr. *M.N.* THAREJA
 Signature of Doctor
 MBBS
 Thareja Nursing Home
 Alwar-301001 (Raj.)

This Report is not Valid for Medical Legal Purpose



THAREJA NURSING HOME



DIGITAL X-RAY, OPG, COMPUTERISED ECG & EEG, DIAGNOSTIC
LABORATORY EQUIPED WITH COMPUTERISED AUTO ANALYZER & CBC

1, Ram Kuteer, Company Bagh Road, ALWAR - 301001 (Raj.) Ph: 0144-2700184, 2331842

PROPOSAL NO.

Date 24/09/2022

Patient Name OM PRAKASH MEHRA


Age 45 Yrs.

Ref. By Dr. M. N. THAREJA

Sex M

PART - X-RAYED : X-RAY CHEST PA VIEW
REPORT : X-RAY CHEST P.A. VIEW
:- Chest is bilaterally symmetrical.
:- C.P. Angles are clear.

CONCLUSSION: Normal Study


Signature of Technician


Dr. M. THAREJA
Signature of Doctor

This Report is not Valid for Medical Legal Purpose Thareja Nursing Home
Alwar-301001, (Raj.)



GUPTA ENT AND HEART CENTRE

Dayanand Marg, Nangli Circle, Alwar (Raj.) Ph. 0144-3591336 | M. 7378184427

Echocardiography Report

Name : Mr. Om Prakash
Age / Sex : 45yrs./male
Refd by : Dr. M.N.Thareja
Date : 24 September 2022

Clinical Diagnosis : For Cardiac Evaluation
2D Echocardiography Findings
Mitral Valve : Normal
Aortic Valve : Normal
Tricuspid Valve : Normal
Pulmonary Valve : Normal
Left Atrium : 4.3cm: Dilated
Left Ventricle : Mild concentric LVH with normal LV systolic function. No RWMA

LVIDd	4.6cm.	IVSd	1.1cm.	EF	60%	Visual
LVIDs	2.5cm.	PWd	1.2cm.	EF	%	F.S.

Right Atrium : Normal
Right Ventricle : Normal
Aorta : 2.8cm: Normal
Pulmonary Artery : Normal
Pulmonary Veins : Normal
Superior Venacava : Normal
Inferior Venacava : Normal
Pericardium : Normal
Intracardiac Masses : No Intracardiac masses seen
IAS/IVS : Intact

Doppler Findings:

Valve	Peak Velocity (cm/s)	Peak Gradient (mmHg)	Mean Gradient (mmHg)	Regurgitation Grade	others/comments
Mitral Valve	E-/A-102/86			Trace MR	
Aortic Valve	119				
Tricuspid Valve				No TR, No PAH.	
Pulmonary Valve					

Diagnosis : Transthoracic echo done in supine position at resting heart rate of 90bpm, shows
Mild concentric LVH with normal LV systolic function.
LVEF~60% (Visual).
No RWMA.
Dilated LA, other cardiac chambers are normal in Size.
Trace MR, No TR, No PAH.
Normal MIP.
No pericardial effusion /Vegetation /Clot Intracardiac masses seen.
Normal left sided arch of aorta, No Coarctation.

Dr. Prachi Gupta
MBBS, PGDCC
(Non-invasive cardiologist)
Gupta ENT and Heart Centre
Nangli Circle, Alwar

Please correlate clinically

This report is not valid for medico legal purpose.

