



ANUBIKSHAN

Diagnostic Centre

Near Asansol District Hospital(Main Gate)
S.B. Gorai Road, Asansol-713301
Email ID : anubikshan.dc@gmail.com
Ph. : 0341-2221195, M. : 9732362727, 7872772680



BANK OF BARODA MEDICAL EXAMINATION REPORT

Client name :- Kalariy Malakar

Ref. No. :-

Date of birth :- 14.03.1994, Sex :- Male / Female

Identification mark on the body :- leucodermat spot all over body

Photo ID Xerox :- Adhar card, No. 541849324276

Date & place of medical examination :- 04.10.21, Asansol

Request for medical exam. of **BANK OF BARODA** through Medi Assist Health Care India (Pvt.) Ltd.

- A) 1. Height :- 161 cm. 2. Weight :- 60 kgs.
3. Chest Inspiration :- 92 cm. 4. Chest Expiration :- 88 cm.
5. Abdomen Girth :- 81 cm. 82
6. Blood Pressure :- I) 123/80 mm. of Hg. II) mm. of Hg.
7. Pulse Rate :- 72 / minute. Character of pulse :- Regular



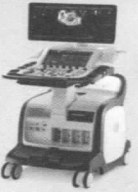- B) 1. Are you now in good health ? Yes
2. Are you currently taking any medicine ? No
- 3.) Are you married ? Yes
4. Have you ever had a positive test for HIV / AIDS / Malignancy ? No
5. Have you ever suffering from sexually transmitted disease or Hepatitis B or C ? No
6. Have you any congenital disorders ? No
7. Have you any respiratory disorders ? No
8. Have you any musculo skeletal disorders ? No
9. Have you CVS disorders ? No
10. Have you GI system disorders ? No
11. Have you urinary system disorders ? No
12. Have you reproductive system disorders ? No



ANUBIKSHAN

Diagnostic Centre

Near Asansol District Hospital (Gate)
S.B. Gorai Road, Asansol-7133
Email ID : anubikshan.dc@gmail.com
Ph. : 0341-2221195, M. : 9732362727, 7872772680



ANUBIKSHAN DIAGNOSTIC CENTRE ANUBIKSHAN DIAGNOSTIC CENTRE ANUBIKSHAN DIAGNOSTIC CENTRE
ANUBIKSHAN DIAGNOSTIC CENTRE ANUBIKSHAN DIAGNOSTIC CENTRE ANUBIKSHAN DIAGNOSTIC CENTRE
ANUBIKSHAN DIAGNOSTIC CENTRE ANUBIKSHAN DIAGNOSTIC CENTRE ANUBIKSHAN DIAGNOSTIC CENTRE
ANUBIKSHAN DIAGNOSTIC CENTRE ANUBIKSHAN DIAGNOSTIC CENTRE ANUBIKSHAN DIAGNOSTIC CENTRE
ANUBIKSHAN DIAGNOSTIC CENTRE ANUBIKSHAN DIAGNOSTIC CENTRE ANUBIKSHAN DIAGNOSTIC CENTRE
ANUBIKSHAN DIAGNOSTIC CENTRE ANUBIKSHAN DIAGNOSTIC CENTRE ANUBIKSHAN DIAGNOSTIC CENTRE
ANUBIKSHAN DIAGNOSTIC CENTRE ANUBIKSHAN DIAGNOSTIC CENTRE ANUBIKSHAN DIAGNOSTIC CENTRE

13. Have you Diabetes / Hypertension / Endocrine disorders? NO

14. Have you ever done any surgical operation? NO

15. Have you any ear problem? NO

16. Have you any eye problem? VA 4/6, Near Vision - Normal, CV - Normal

17. Have you nervous system disorders? NO

18. Have you any abnormal growth? NO

19. Have you any blood disorders? NO

20. What is general appearance of the client? Healthy

21. Does the appearance correspond with the age? Yes

22. Is there any personal peculiarities? NO

23. Tobacco (Stick / gms)- Panmasala/Cigar / Cigarette / Bidi / Gutkha Yes No
Alcohol(ml)- Beer / Wine / Hard Liquor :- Qty./ Day For No. of Yrs



24. Family History	Age if living	Age at death	Present state of health or cause of death
Father	61y	Alive	(Good health)
Mother	50y	Alive	(Good health)
Brother (s)	34y	Alive	(Good health)
Sister (s)	32y	Alive	(Good health)

25. ANY REMARK BY THE MEDICAL EXAMINAR: - TSA - 6.22 otherwise
she is fit and healthy.

Kabery Malakar
Signature of the Client

Dr. S.K. SHAH
Name of the Doctor

Date: - 04/10/21

[Signature]
Signature & Seal of the Doctor

Anjeev Kevin Shah
M.B.B.S., MD (Med.)
Reg. No. 16138

भारत सरकार
Government of India

कबेरी मालाकार
Kabery Malakar
जन्म तिथि / DOB: 14/03/1994
महिला / FEMALE

Issue Date: 16/06/2015

5418 4932 4276

मेरा आधार, मेरी पहचान



✓
Kabery Malakar

Dr. Sanjeev Kevin Shah
M.B.B.S., MD (Med.)
Reg. No. 16138

भारतीय विशिष्ट पहचान प्राधिकरण
Unique Identification Authority of India

पता: W/O बलराम मालाकार, ग्राम-देबियाना, पोस्ट-
देबियाना, देबियाना, धनबाद, झारखण्ड, 828205

Print Date: 05/05/2021

Address: W/O Balaram Malakar, Vill-
Debiyana, Post-Debiyana, Debiana,
Dhanbad, Jharkhand, 828205

5418 4932 4276

1947 help@uidai.gov.in www.uidai.gov.in

B बैंक ऑफ़ बड़ोदा
Bank of Baroda



नाम **मालाकर बलराम**
Name: **MALAKAR BALARAM**
कर्मचारी कुट. क्र. २७७६००
E. C. No. **177600**

जारीकर्ता प्राधिकारी

धारक के हस्ताक्षर

✓
Malakar
04.10.21
Dr. Sanjeev Kevin Shah
M.B.B.S., MD (Med.)
Reg. No. 16138



PATIENT'S NAME: - KABERY MALAKAR

AGE: - 27 YEAR

SEX: - FEMALE

REF. BY DR.: - M.O.BANK OF BARODA

DATE: - 04-10-2021

U. S. G. OF WHOLE ABDOMEN

LIVER

Normal shape and size. Homogeneous echo texture of the liver is seen.
No focal parenchymal lesion is seen. (Measure:- 124.23 mm.)

PORTA

Portal vein at porta hepatis measures:- 4.80 mm. in diameter.
The appearance of porta is normal.

GALL BLADDER

Normal shape, size and position of the Gall Bladder is seen.
No calculus or any intraluminal mass is seen.

COMMON BILEDUCT

Common bile duct is not dilated (1.05mm.)
No calculus or any intraluminal echogenicity.

PANCREAS

Normal echo-texture of the pancreas is seen. No space occupying lesion is seen.
Its relation with the anatomical landmark is normal.

SPLEEN

Normal dimension of the spleen is seen. It shows normal echo-texture.
No space occupying lesion is seen in the spleen. (Measure:- 84.21 mm.)

KIDNEYS

Both the kidneys are normal in shape, size, margin and axis.
Cortico medullary differentiation is normal.
No calculi or any hydronephrotic changes noted.
(Rt. Kidney Measure:- 96.57 mm. and Lt. Kidney Measure:- 101.31 mm. in length.)

URINARY BLADDER

Normal shape and size of the urinary bladder is seen.
No intraluminal echo is noted.

UTERUS

A/V, Bulky. (Measure:- 70.89 mm. x 31.83 mm. x 45.02 mm.)

OVARIES

Normal shape and size of the ovaries are seen.
Normal echo texture is seen.
No space occupying lesion is seen in the ovaries.
(Right ovary measure :- 27.74 mm. x 17.74 mm.)
(Left ovary measure :- 30.15 mm. x 20.93 mm.)

➤ **IMPRESSION :-**
❖ **NORMAL STUDY.**

ADVICE
Clinical co-relation.

DR. DIPANKAR DASGUPTA.
(M.B.B.S., D.M.R.D)
(Regd.No:- WB-34374)

[Handwritten signature]
24/10

PATIENT'S NAME :- KABERI MALAKAR

AGE:- 27 YEAR SEX:- FEMALE

REF BY DR: - M.O. BANK OF BARODA.

DATE:- 04-10-2021

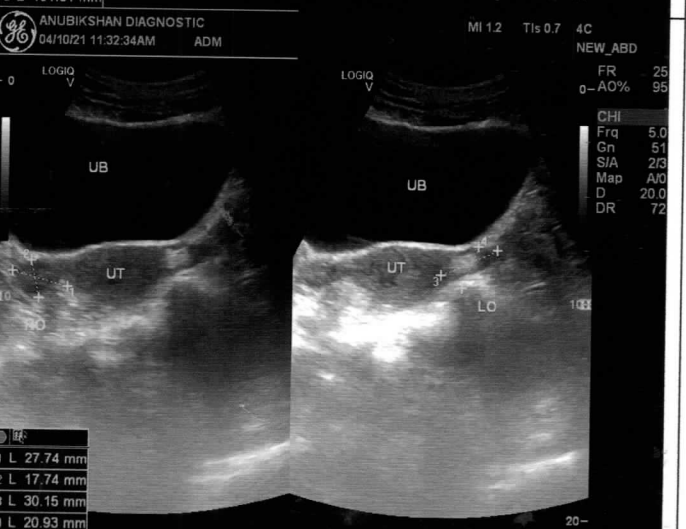
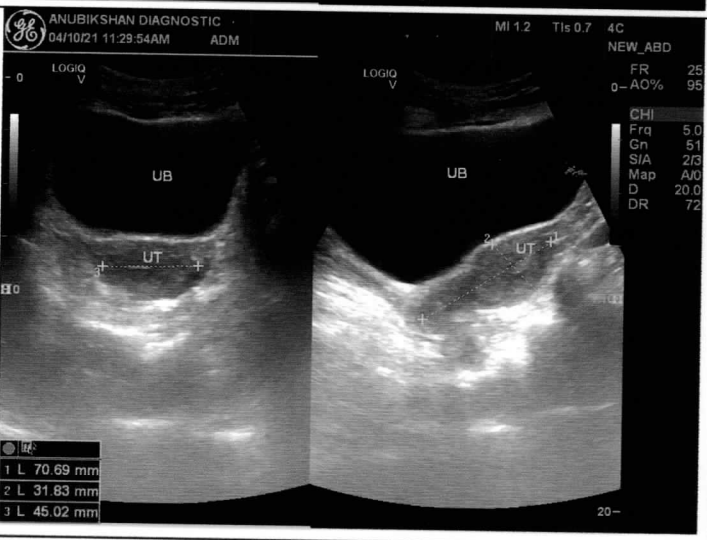
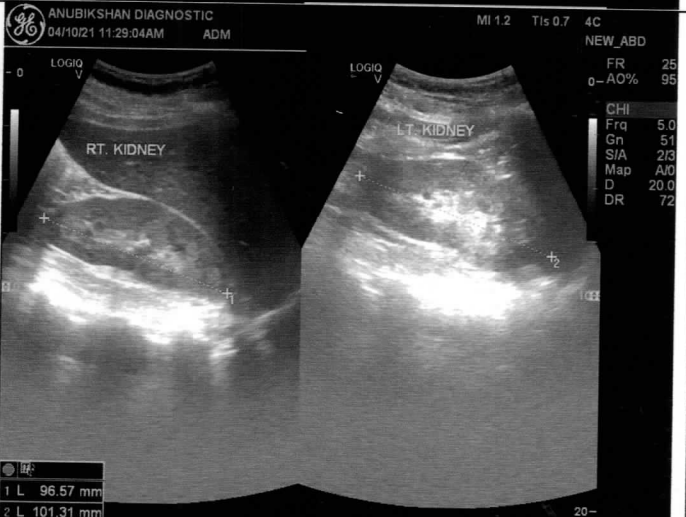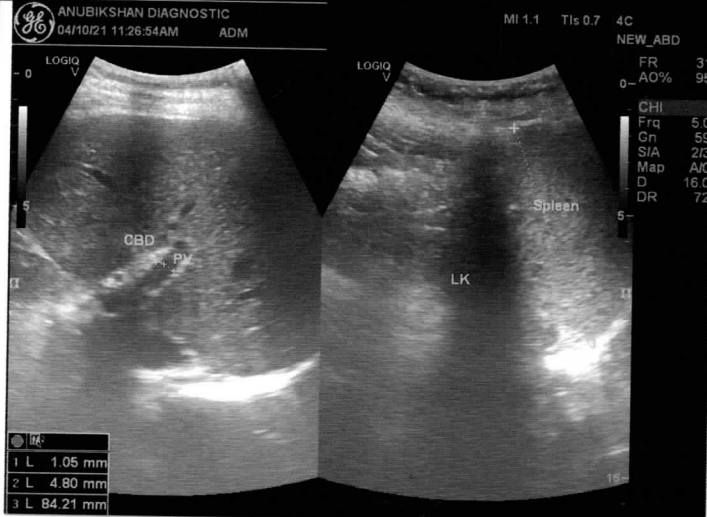
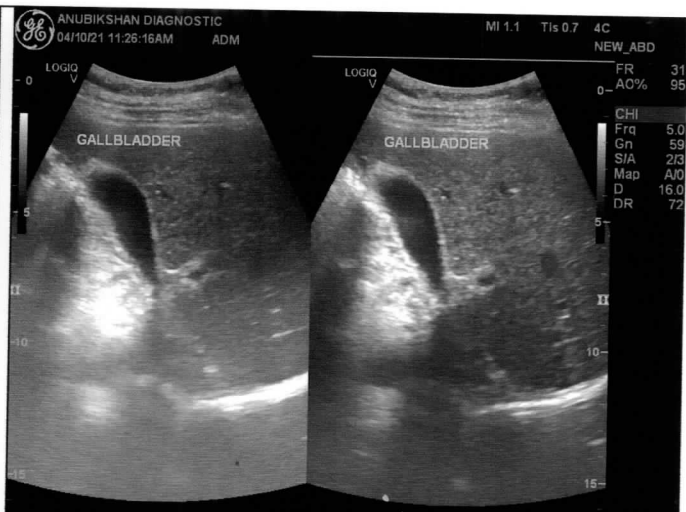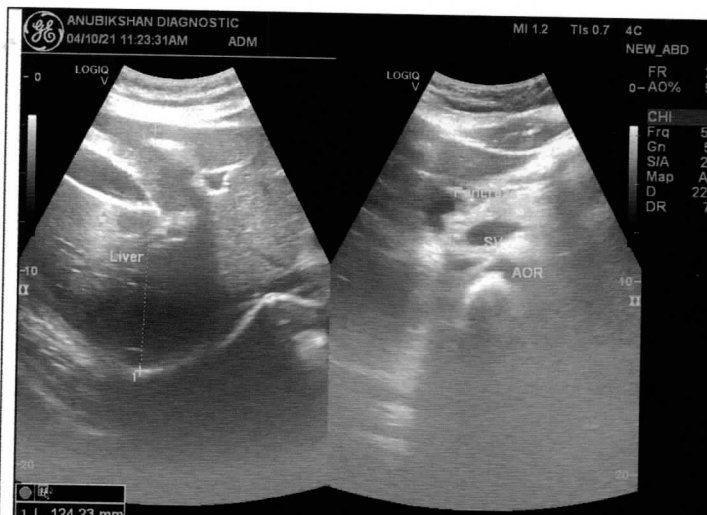
U.S.G. OF WHOLE ABDOMEN

ANUBIKSHAN **DIAGNOSTIC CENTRE**

**NEAR ASANSOL DISTRICT HOSPITAL (MAIN GATE)
S.B.GORAI ROAD (EAST), PIN - 713301**

LANDLINE: - 0341-3590332 // MOB - 7872772680

E- mail add: - anubikshan.dc @ gmail.com



Dr. Rajib Banerjee

B.Sc., B.H.M.S., DOS (Kol)
Consultant Homoeopathic Physician
and optometric Eye Specialist

ADDRESS :

1 No. Mohishila Colony
Bottala Bazar
Asansol - 3
Mob. : 9832197360

Rx

Koberny Malabar

Rt. Eye		Lt. Eye	
Sph	Cyl	Sph	Cyl
Near Add. →		Near Add. →	

VA 6/c
VA 6/c

Near vision N6
CV - Normal

RM
4/10/21



Chamber

Balananda Homoeo Clinic
Khejurtala More
Mohishila - 2, Asansol

Morning : 8.00 a.m. to 9.00 a.m.
Evening : 6.00 p.m. to 9.30 p.m.
Saturday Evening Closed
& Sunday Morning Closed



PATIENT'S NAME :- KABERY MALAKAR

AGE:- 27 YEAR

SEX:- FEMALE

REF. BY DR.:- M.O.BANK OF BARODA

DATE:- 04-10-2021

REPORT

CHEST X – RAY P A VIEW

Soft tissue around chest and bony cage --- normal.

No active lung lesion in either field.

Cardiac configuration normal.

Pleural recesses are clear.

I M P R E S T I O N

✓ **NORMAL SKIAGRAM OF CHEST.**

ADVICE

Clinical co-relation.

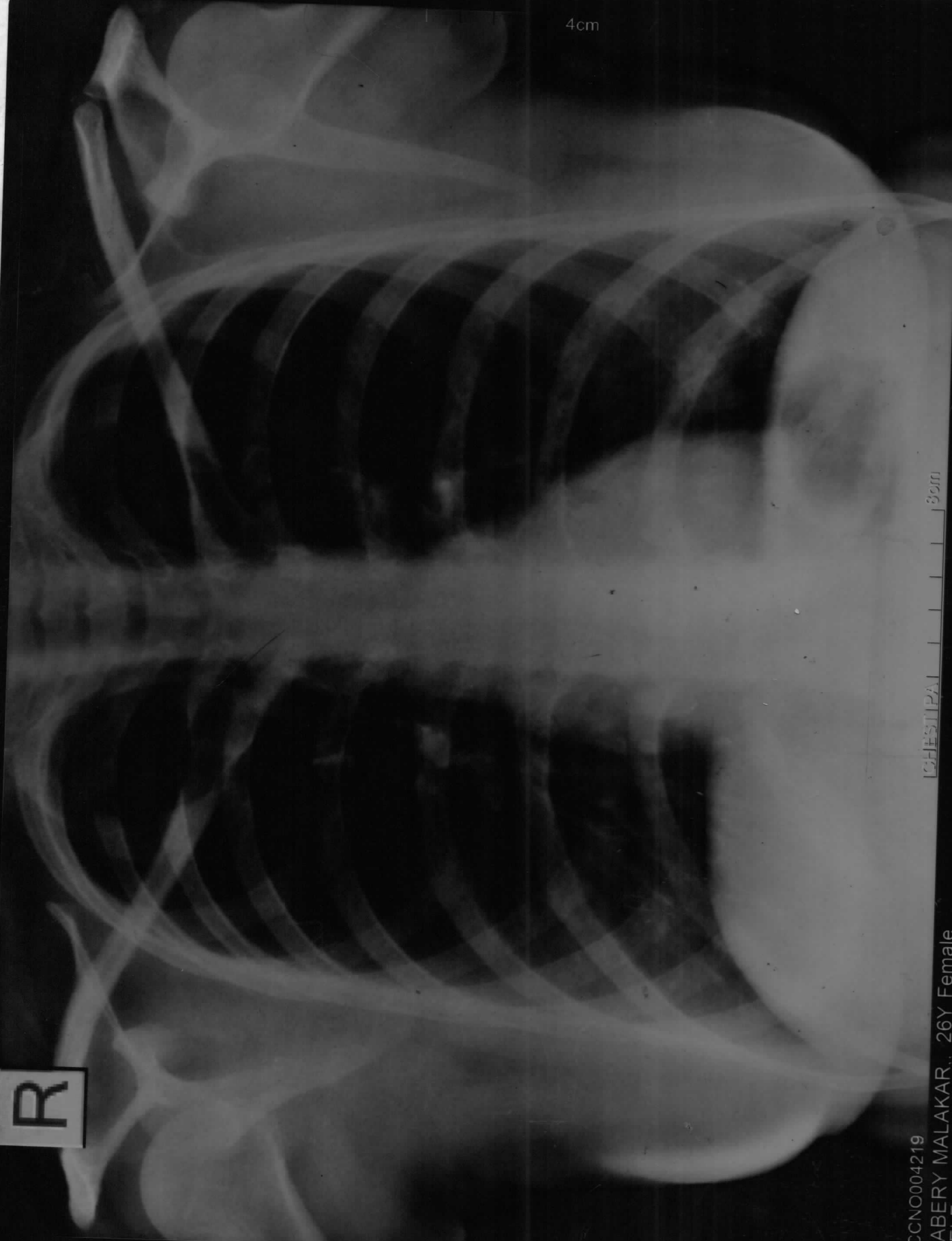
[Handwritten signature]
4/10

DR. DIPANKAR DASGUPTA.

(M.B.B.S., D.M.R.D)

(Regd.No:- WB-34374)

R



4cm

ACCNO004219

KABERY MALAKAR, 26Y Female
SELF

NEW ASANSOL X-RAY CLINIC, MOB -9434236862

125ESTIPA | 3cm

10:06:12 AM
DATE:-04-10-2021