



**Dr. RAJENDRAN'S  
CARE & CURE DENTAL CLINIC**

KHI - 2653/13

OTHALATHUMOOTIL COMMERCIAL COMPLEX (FIRST FLOOR)  
SAMKRANTHI, KOTTAYAM - 686 016, KERALA. Mob: 9446026310

DATE: 10/02/2023

OP NO..... NAME: Renya..... AGE: 46 SEX: F

C/O.....

D/O.....

IND FOR.....

Rx

patient named Renya of age 46 years has undergone routine dental checkup. On Examination caries noted on  $\frac{7}{5}$  and advised to undergo restorative procedure. Missing tooth noted on  $\frac{6}{6}$  and advised to have prosthetic replacement.

Examination Fee: 100/-

Dr. Namitha



**Dr. ANN NAMITHA JACOB, BDS**  
Dental Surgeon  
KDC, Reg.No: 15586/A  
Kottayam, Kerala



If the examinee is suffering from an acute life threatening situation, you may be obliged to disclose the result of the medical examination to the examinee.

1. Name of the examinee	:	Mr./Mrs./Ms. <i>Remya Sunil</i>
2. Mark of Identification	:	(Mole/Scar/any other (specify location)):
3. Age/Date of Birth	:	<i>44/10-04-78</i> Gender: <i>F/M</i>
4. Photo ID Checked	:	(Passport/Election Card/PAN Card/Driving Licence/Company ID) <i>Adhar</i>

**PHYSICAL DETAILS:**

a. Height ..... <i>1.43</i> ..... (cms)	b. Weight ..... <i>50</i> ..... (Kgs)	c. Girth of Abdomen ..... <i>77</i> .... (cms)
d. Pulse Rate ..... <i>71</i> ..... (/Min)	e. Blood Pressure:	Systolic <i>120</i> Diastolic <i>80</i>
	1 <sup>st</sup> Reading	
	2 <sup>nd</sup> Reading	

**FAMILY HISTORY:**

Relation	Age if Living	Health Status	If deceased, age at the time and cause
Father	<i>89</i>	<i>Normal</i>	<i>—</i>
Mother	<i>75</i>	<i>Parkinsons</i>	
Brother(s)	<i>40</i>	<i>Normal</i>	
Sister(s)	<i>47</i>	<i>Normal</i>	

**HABITS & ADDICTIONS: Does the examinee consume any of the following?**

Tobacco in any form	Sedative	Alcohol
<i>✓</i>	<i>✓</i>	<i>✓</i>

**PERSONAL HISTORY**

- |   |   |
|---|---|
| a. Are you presently in good health and entirely free from any mental or Physical impairment or deformity. If No, please attach details. <i>Y/N</i> ✓ | c. During the last 5 years have you been medically examined, received any advice or treatment or admitted to any hospital? <i>Y/N</i> ✓ |
| b. Have you undergone/been advised any surgical procedure? <i>Y/N</i> ✓   | d. Have you lost or gained weight in past 12 months? <i>Y/N</i> ✓   |

**Have you ever suffered from any of the following?**

- |  |   |
|--|---|
| • Psychological Disorders or any kind of disorders of the Nervous System? <i>Y/N</i> ✓ | • Any disorder of Gastrointestinal System? <i>Y/N</i> ✓                               |
| • Any disorders of Respiratory system? <i>Y/N</i> ✓                                    | • Unexplained recurrent or persistent fever, and/or weight loss <i>Y/N</i> ✓          |
| • Any Cardiac or Circulatory Disorders? <i>Y/N</i> ✓                                   | • Have you been tested for HIV/HBsAg / HCV before? If yes attach reports <i>Y/N</i> ✓ |
| • Enlarged glands or any form of Cancer/Tumour? <i>Y/N</i> ✓                           | • Are you presently taking medication of any kind? <i>Y/N</i> ✓                       |
| • Any Musculoskeletal disorder? <i>Y/N</i> ✓   |   |

**DDRC SRL Diagnostics Private Limited**

Corp. Office: DDRC SRL Tower, G- 131, Panampilly Nagar, Ernakulam - 682 036  
Ph No. 0484-2318223, 2318222, e-mail: info@ddrcsrl.com, web: www.ddrcsrl.com

Corp. Office: DDRC SRL Tower, G- 131, Panampilly Nagar, Ernakulam - 682 036, Ph No: 2310688, 231822, web: www.ddrcsrl.com



• Any disorders of Urinary System?

Y/N ✓

• Any disorder of the Eyes, Ears, Nose, Throat or Mouth & Skin

Y/N ✓

**FOR FEMALE CANDIDATES ONLY**

a. Is there any history of diseases of breast/genital organs?

Y/N ✓

d. Do you have any history of miscarriage/abortion or MTP

Y/N ✓

b. Is there any history of abnormal PAP Smear/Mammogram/USG of Pelvis or any other tests? (If yes attach reports)

Y/N ✓

e. For Parous Women, were there any complication during pregnancy such as gestational diabetes, hypertension etc

Y/N ✓

c. Do you suspect any disease of Uterus, Cervix or Ovaries?

Y/N ✓

f. Are you now pregnant? If yes, how many months?

Y/N ✓

**CONFIDENTIAL COMMENTS FROM MEDICAL EXAMINER**

➤ Was the examinee co-operative?

Y/N

➤ Is there anything about the examinee's health, lifestyle that might affect him/her in the near future with regard to his/her job?

Y/N

➤ Are there any points on which you suggest further information be obtained?

Y/N

➤ Based on your clinical impression, please provide your suggestions and recommendations below;

*Dyslipidemia & HT detected - advised physician consultation*

➤ Do you think he/she is **MEDICALLY FIT** or UNFIT for employment.

FIT

**MEDICAL EXAMINER'S DECLARATION**

I hereby confirm that I have examined the above individual after verification of his/her identity and the findings stated above are true and correct to the best of my knowledge.

Name & Signature of the Medical Examiner :

*Dr. Austin Varghees*  
*Austin Varghees*  
*10/11/2023*

Seal of Medical Examiner :

**Dr. Austin Varghees**  
**MBBS**  
**TCMC Reg. No:77017**



Name & Seal of DDRC SRL Branch :

Date & Time :

**DDRC SRL Diagnostics Private Limited**

Corp. Office: DDRC SRL Tower, G- 131, Panampilly Nagar, Ernakulam - 682 036  
Ph No. 0484-2318223, 2318222, e-mail: info@ddrcsrl.com, web: www.ddrcsrl.com

Regd. Office: 4th Floor, Prime Square, Plot No.1, Gaiwadi Industrial Estate, S.V. Road, Goregaon (West), Mumbai - 400062.

## OPHTHALMOLOGY REPORT

ACCESSION NO:4036WB001799

This is to certify that I have examined

MR/MS. Remya ..... Aged 44/F ..... and

His / her visual standard is as follows.

Acuity of Vision

For Far

R ..... 6/6 .....

L ..... 6/6 .....

For Near

R ..... N12 .....

L ..... N12 .....

With Specs R<sub>d</sub> > N6  
L<sub>t</sub> > N6

Colour Vision

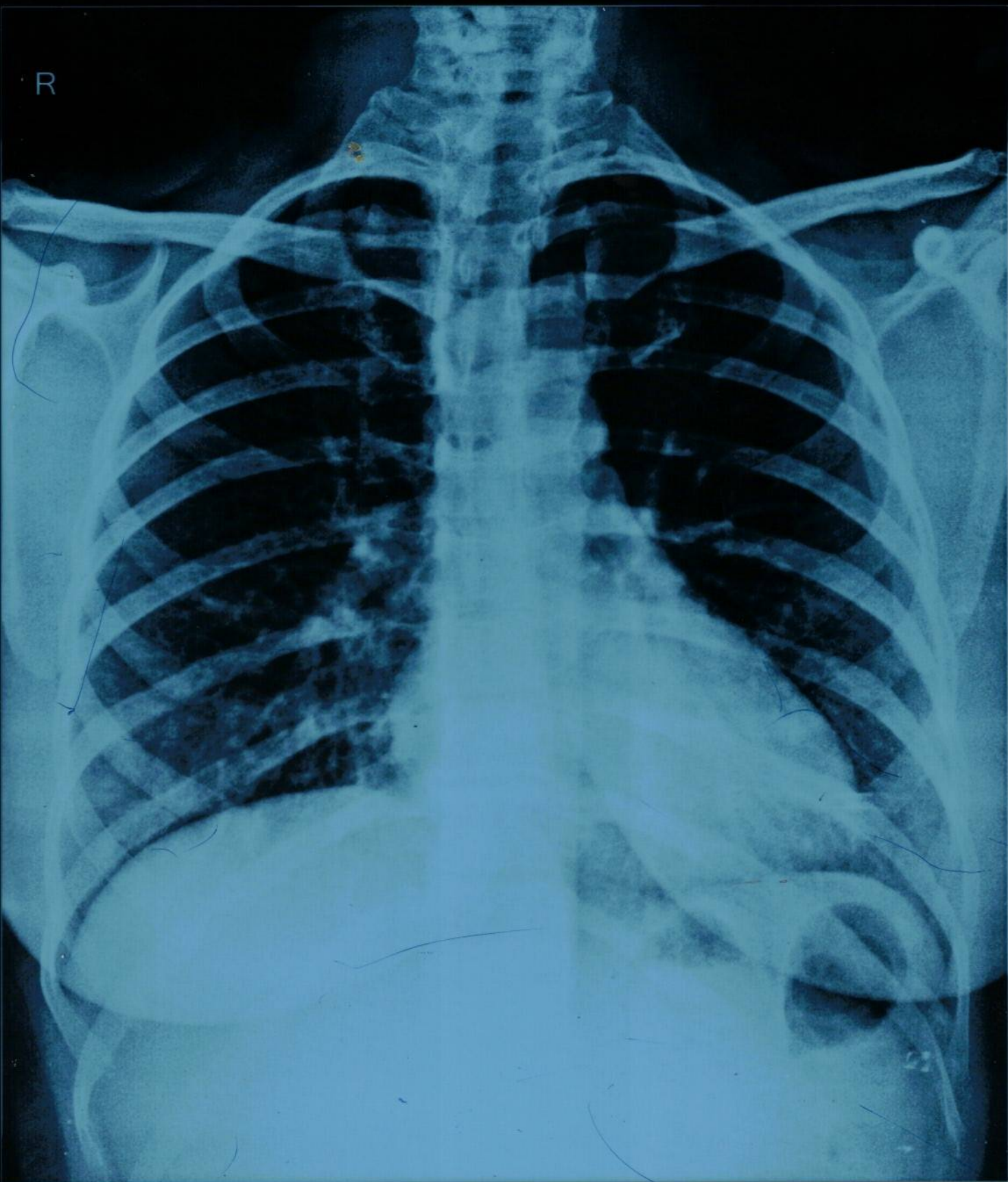
..... NORMAL .....

DATE: 10/02/2023



Amal  
OPTOMETRIST

R



REMYA 44/Y 525 CHEST-PA 10-02-2023

DDRC SRL DIAGNOSTICS, GANDHI NAGAR, KOTTAYAM

10/10/10

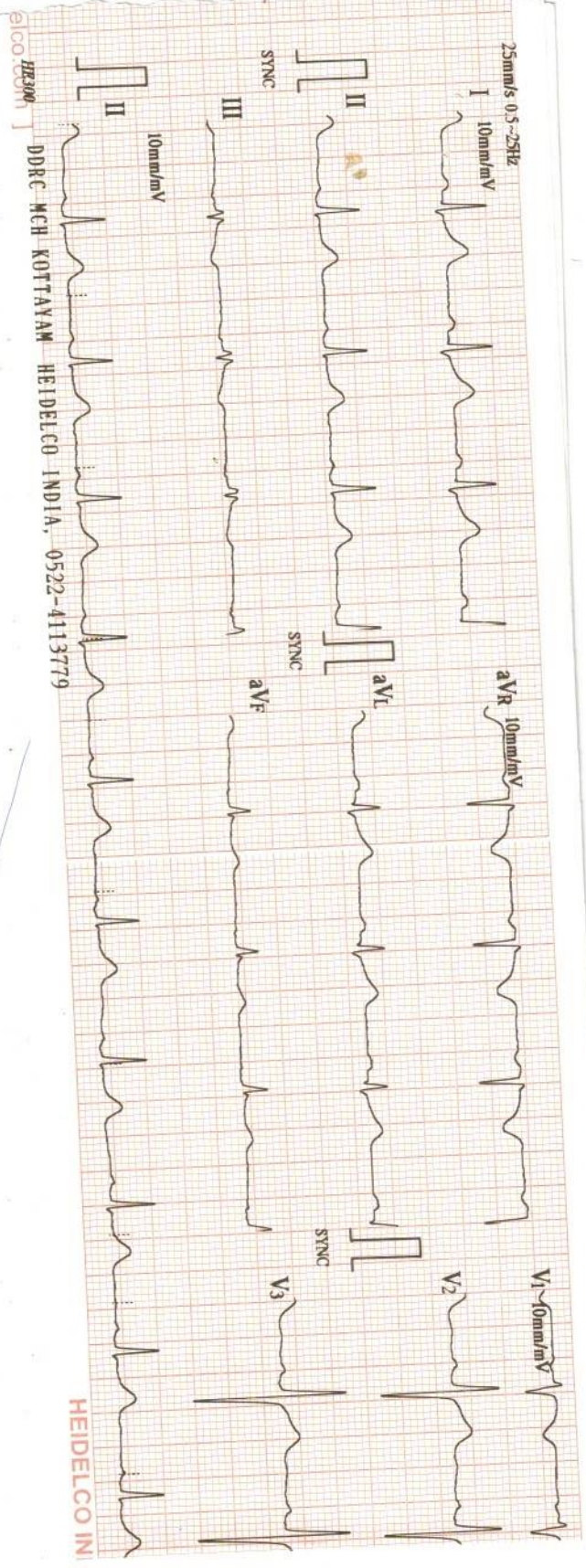
## X - RAY CHEST - REPORT

ACCESSION NO : 4036WB0001799  
 NAME : REMYA  
 AGE : 44  
 SEX : FEMALE  
 DATE : 10.02.2023  
 COMPANY : MEDIWHEEL

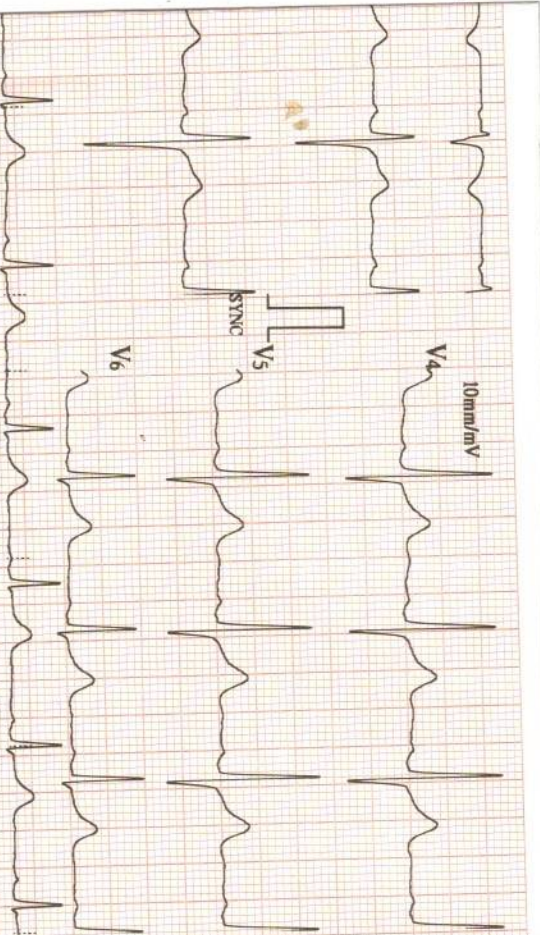
EXPOSURE : *Adequate*  
 POSITIONING : *Central*  
 SOFT TISSUES : *Normal*  
 LUNG FIELDS : *Normal*  
 HEART SHADOW : *Normal*  
 CARDIOPHRENIC ANGLE : *no obliteration*  
 COSTOPHRENIC ANGLE :  
 HILUM : *Normal*  
 OPINION : *Normal chest xray*



  
**Dr. Austin Varghees**  
 MBBS  
 TCMC Reg. No:77017



DIA [ Helpline No +91-522-4113779 | info@heidelco.com ]



10/02/2023 11:12

ID : 1213

Name: REMYA

Sex : Female

Age : 44

HR	: 71	bpm
R-R	: 835	ms
P-R	: 155	ms
QRS	: 98	ms
QT/QTc	: 390/426	ms
P/ORS/T	: -22/47/23	°
RV5/SVI	: 1.320/0.430	mV
RV5+SVI	: 1.750	mV

V2-002(BIOS: V2-004/AMP: V1-006)



\*Machine Interpretation Only\*

Confirm with Physician

Physician:



## ECG REPORT

ACCESSION NO : 4036WB0001799

NAME : REMYA

AGE : 44

SEX : FEMALE

DATE : 10.02.2023

COMPANY : MEDIWHEEL

RATE : 71 bpm

RHYTHM : Normal sinus rhythm

P. WAVE : Normal

P-R INTERVAL : 155ms

Q,R,S,T. WAVES : Normal

AXIS : Normal

ARRHYTHMIAS : Nil

QT INTERVAL : 390ms

OTHERS : Nil

OPINION : Normal ECG



*[Signature]*  
 Dr. Austin Varghees  
 MBBS  
 TCMC Reg. No: 77017



Name: **REMYA SUNIL**  
Age/Sex: **44 yrs/F**  
Accession No: **4036WB001799**

Report Date: **10.02.2023**  
Ref.by: **Mediwheel**

**USG ABDOMEN & PELVIS**

**OBSERVATIONS:**

- Liver: Normal in size. **Shows increased parenchymal echotexture.** No focal parenchymal lesion noted. The biliary radicals appear normal. Portal vein is normal (9 mm).
- Gall bladder: Distended (measures 4 x 1.3 cm) No calculus seen. No e/o of any wall thickening / edema. No e/o any pericholecystic collection.
- CBD: Not dilated (3 mm).
- Spleen: Normal in size (7.3 cm) and echotexture. No focal lesion.
- Pancreas: Head ( 2 cm) and body ( 1 cm) appear normal. Tail obscured by bowel gas. No focal lesion. No calcification or duct dilatation noted.
- Kidneys: Right kidney length measures 10.1 cm. Parenchymal thickness 1.6 cm Normal in position & size. Cortical echogenicity is normal. There is good cortico-medullary differentiation. No calculus or mass lesion seen. No hydronephrosis.  
Left kidney length measures 10.1 cm. Parenchymal thickness 1.3 cm Normal in position & size. Cortical echogenicity is normal. There is good cortico-medullary differentiation. No calculus or mass lesion seen. No hydronephrosis.
- Ureters: Not dilated.
- Urinary Bladder: Distended, No luminal or wall abnormality noted.
- Uterus (tvs): Is anteverted and mildly enlarged in size measures **8.4 x 5.1 x 4.3 cm.** **Intramural fibroid measuring 3.2 x 2.8 cm is noted in the anterior wall.** Endometrial echo is normal. ET- 5.6 mm. Cavity is empty.
- Ovaries: Right ovary: 2.7 x 1 cm Left ovary: 2.4 x 1.7 cm  
Normal in size and morphology on both sides.
- Adnexa: No adnexal lesions.
- Others: No evident lymphadenopathy. No evidence of bowel wall thickening/echogenic mesentery/dilated bowel loops. Normal peristalsis seen. No free fluid in the peritoneal cavity. No pleural effusion noted.

**IMPRESSION:**

- **Grade I fatty changes in liver.**
- **Uterine fibroid.**



**Dr. Deepak.V, MBBS, DMRD**  
Radiologist

Note: This is radiological opinion and not the final diagnosis. Ultrasound is limited by patient adiposity, bowel gas and correlate clinically and investigate further as needed.

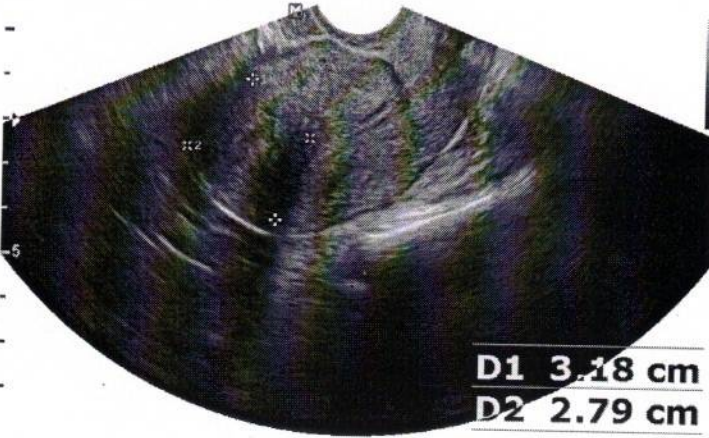
## Patient

## Exam

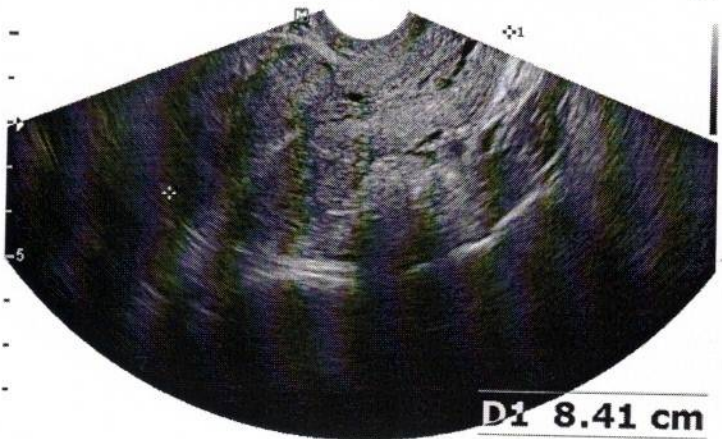
ID 10-02-2023-0009  
Name  
Birth Date  
Gender Other

Accession #  
Exam Date 10022023  
Description  
Sonographer

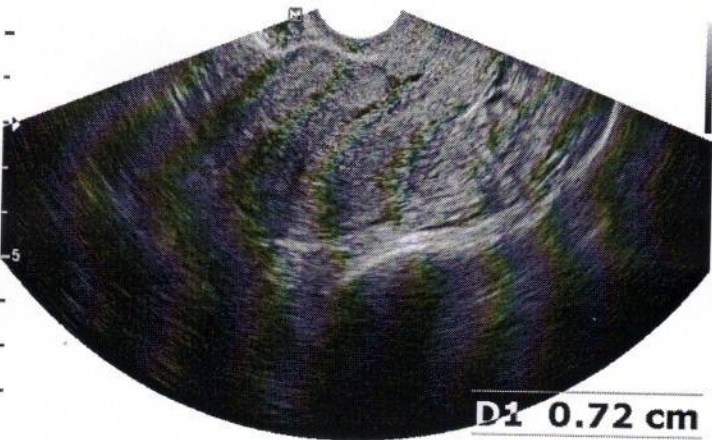
[2D] G20/99dB/FA11/P90/FSI 1



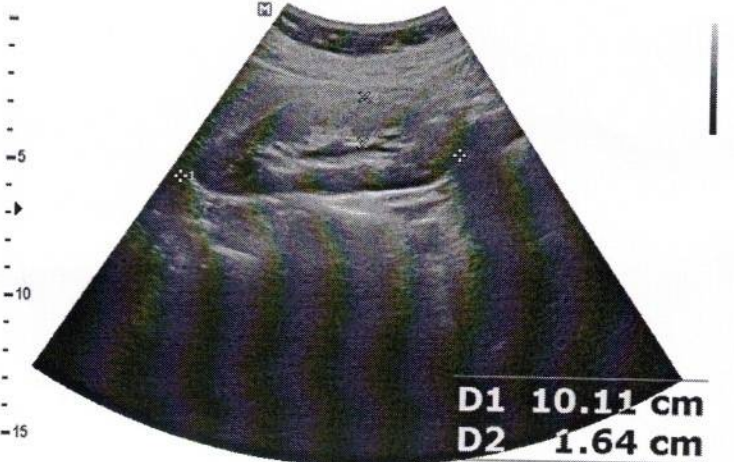
[2D] G20/99dB/FA11/P90/FSI 1



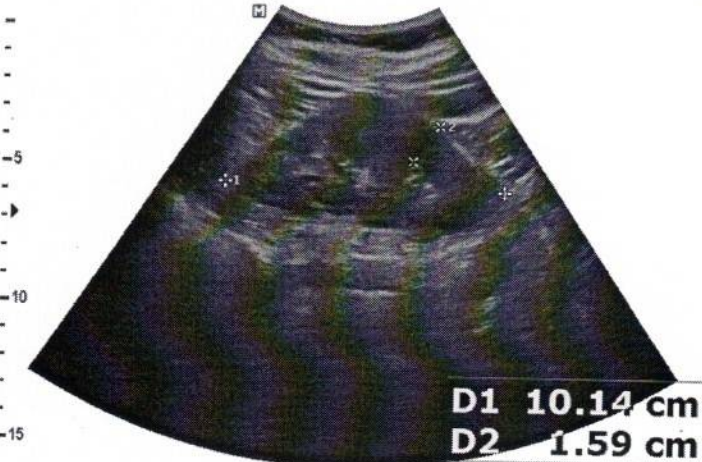[2D] G20/99dB/FA11/P90/FSI 1



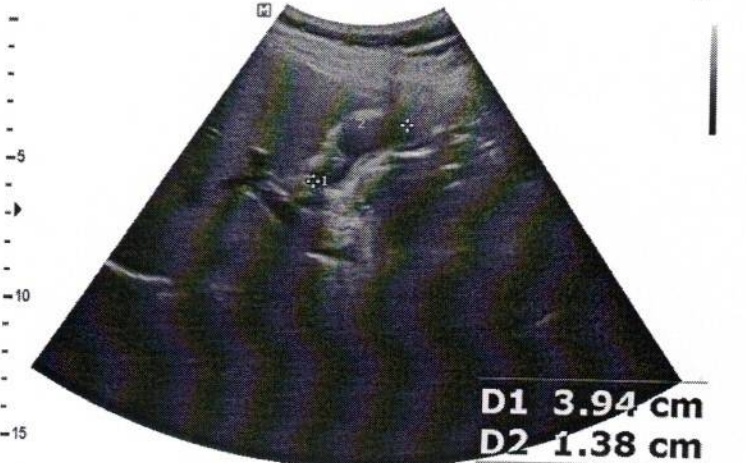[2D] G34/118dB/FA10/P90/HAR/FSI 1



[2D] G23/118dB/FA10/P90/HAR/FSI 1



[2D] G36/118dB/FA10/P90/HAR/FSI 1





Name: REMYA SUNIL  
Age/Sex: 44 yrs/F  
Accession No: 4036WB001799

Report Date: 10.02.2023  
Ref.by: Mediwheel

**MAMMOGRAM REPORT (BOTH BREASTS)**

Cranio-caudal and Medio-lateral oblique views of both breasts were taken.

**Right breast:**

No evidence of any mass lesion / asymmetric density noted.  
No clustered pleomorphic microcalcifications visualized.  
No evidence of any architectural distortion seen.  
There is no skin thickening or nipple retraction.  
No obvious lymph nodes seen in the axillary region.

**High frequency Sonography:** Reveals no focal / diffuse mass lesion or obviously dilated ducts.

**Left breast:**

There is mild asymmetric density noted in the lower quadrants however USG breast is normal, likely to be due to focal increased breast density.  
No clustered pleomorphic microcalcifications visualized.  
No evidence of any architectural distortion seen.  
There is no skin thickening or nipple retraction.  
No obvious lymph nodes seen in the axillary regions.

**High frequency Sonography:** Reveals no focal / diffuse mass lesion or obviously dilated ducts.

**IMPRESSION:**

- **No significant abnormality detected.**

**Dr. Deepak.V, MBBS, DMRD**  
Radiologist

**Encl: Film**

This is a professional opinion based on imaging findings and not a diagnosis by itself. Please correlate clinically and with other imaging / laboratory investigations.



# DDRC SRL KOTTAYAM

## Patient Details

Name: REMYA ID: 194  
Age: 44 y

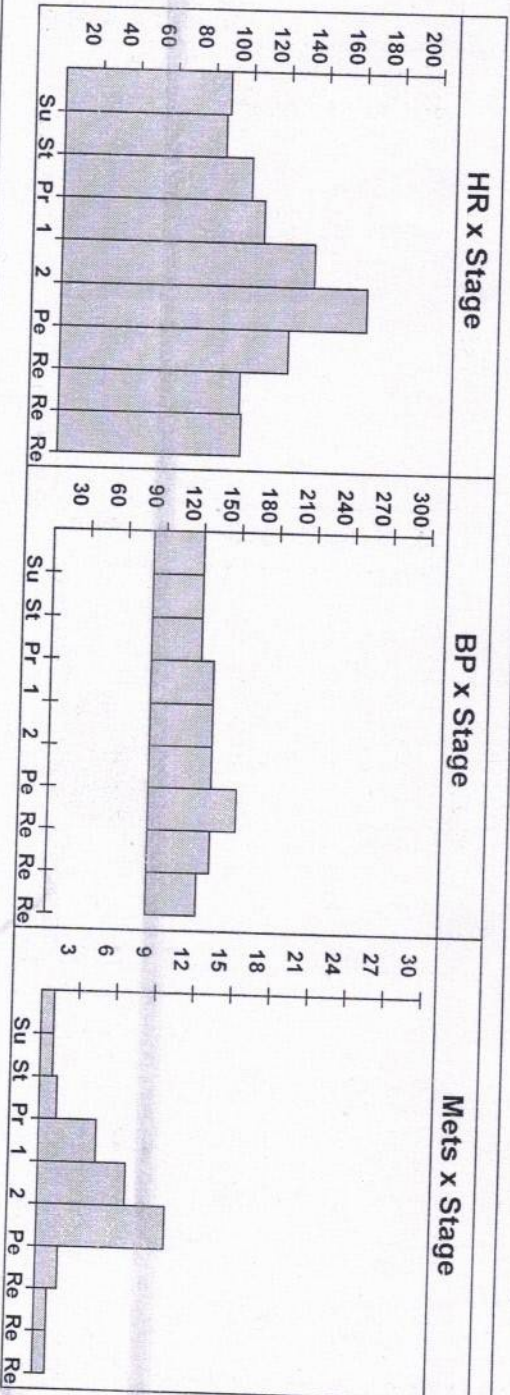
Date: 10-Feb-23

Sex: F

Time: 11:13:47

Height: 143 cms

Weight: 50 Kgs



### Interpretation

STRESSED UPTO 8 MTS ON BRUCE PROTOCOL AND ATTAINED 92% OF THR AT HR OF 162 BPM WITH A WORKLOAD OF 9 METS. RPP- 24300.  
NORMAL HR AND BP RESPONSE.  
NO ANGINA/ARRHYTHMIA.  
BASELINE ECG SHOWS SR WITH REPOLARIZATION ABNORMALITY.  
NO SIGNIFICANT ST SHIFT.

IMP:- TEST IS NEGATIVE FOR INDUCIBLE ISCHEMIA.  
GOOD EFFORT TOLERANCE.



*Dr. Austin Varghese*  
Dr. Austin Varghese  
MBBS  
TCMC Reg. No: T7017

## DDRC SRL KOTTAYAM

**Patient Details**

Date: 10-Feb-23

Time: 11:13:47

Name: REMYA ID: 194

Age: 44 y

Sex: F

Height: 143 cms

Weight: 50 Kgs

Clinical History: THYROID DX, FOR CARDIAC EVALUATION

Medications: T. THYROXIN 25

**Test Details**

Protocol: Bruce

P.r.MHR: 176 bpm

THR: 158 (90 % of Pr.MHR) bpm

Total Exec. Time: 8 m 0 s

Max. HR: 162 ( 92% of Pr.MHR ) bpm

Max. Mets: 10.20

Max. BP: 150 / 80 mmHg

Max. BP x HR: 24300 mmHg/min

Min. BP x HR: 6880 mmHg/min

Test Termination Criteria: FATIGUE

**Protocol Details**

Stage Name	Stage Time (min : sec)	Mets	Speed (mph)	Grade (%)	Heart Rate (bpm)	Max. BP (mm/Hg)	Max. ST Level (mm)	Max. ST Slope (mV/s)
Supine	4 : 33	1.0	0	0	88	120 / 80	-5.73 I	5.66 I
Standing	0 : 30	1.0	0	0	86	120 / 80	-0.64 aVR	-1.06 aVR
1	3 : 0	4.6	1.7	10	107	130 / 80	-0.85 aVR	1.77 II
2	3 : 0	7.0	2.5	12	134	130 / 80	-1.06 aVR	2.48 II
Peak Ex	2 : 0	10.2	3.4	14	162	130 / 80	-1.27 aVR	5.66 V4
Recovery(1)	1 : 6	1.8	1	0	121	150 / 80	-2.12 aVR	5.66 II
Recovery(2)	2 : 0	1.0	0	0	96	130 / 80	-1.70 aVR	5.66 V4
Recovery(3)	1 : 2	1.0	0	0	97	120 / 80	-0.85 aVR	1.77 II



REMYA (44 F)

DDRC SRL KOTTAYAM

ID: 194

Date: 10-Feb-23

Exec Time : 0 m 0 s Stage Time : 4 m 7 s

HR: 94 bpm

Protocol: Bruce

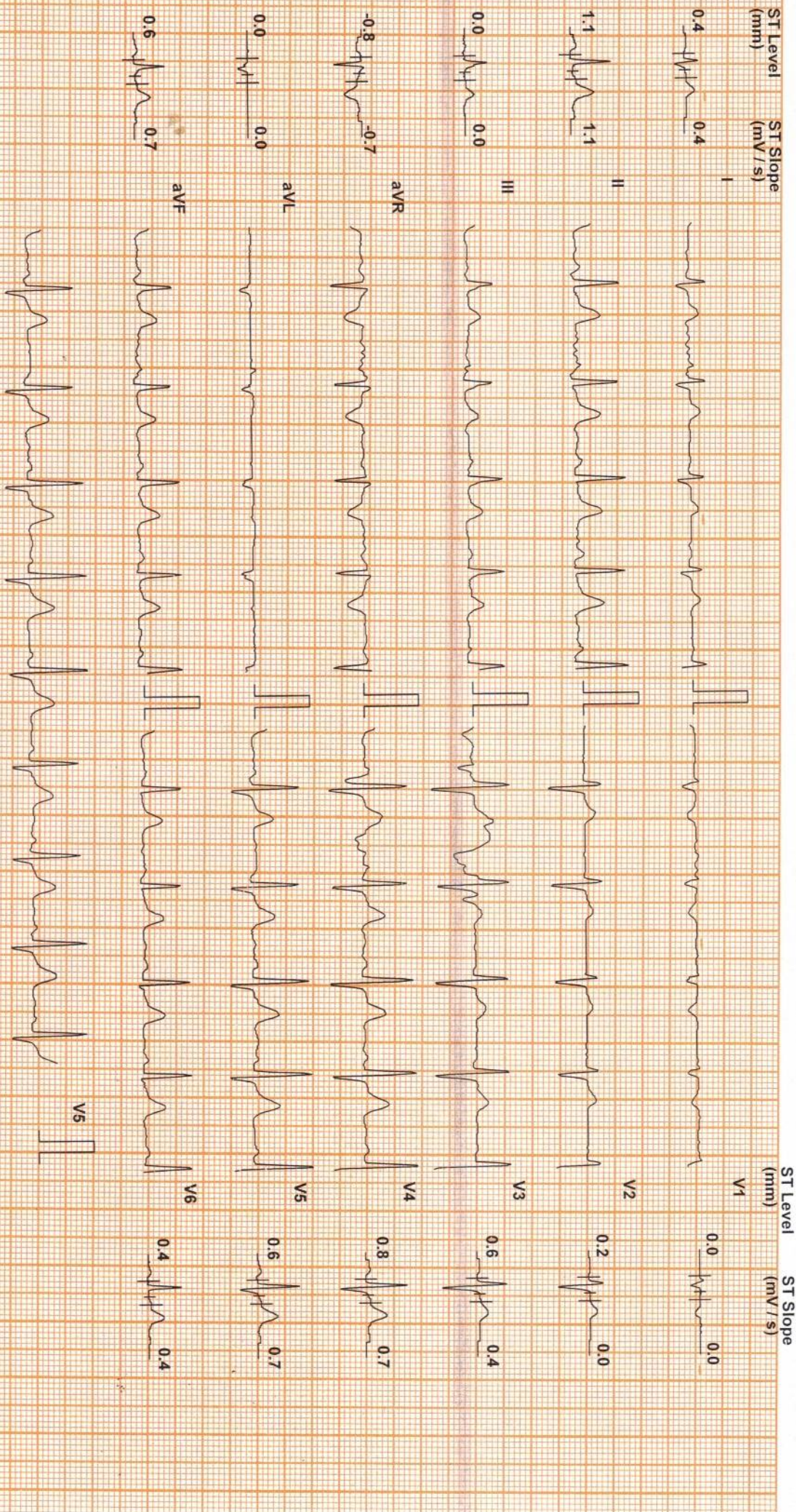
Stage: Supine

Speed: 0 mph

Grade: 0 %

(THR: 158 bpm)

B.P: 120 / 80



ST Level (mm)

ST Level (mm)

ST Slope (mV/s)

Chart Speed: 25 mm/sec

Filter: 35 Hz

Mains Filt: ON

Amp: 10 mm

ISO = R - 60 ms

J = R + 60 ms

Post J = J + 60 ms

Schiller Spandan V 4.7

REMYA (44 F)

Protocol: Bruce

DDRC SRL KOTTAYAM

ID: 194

Date: 10-Feb-23

Exec Time : 0 m 0 s

Stage Time : 0 m 27 s

HR: 87 bpm

Stage: Standing

Speed: 0 mph

Grade: 0 %

(THR: 158 bpm)

B.P: 120 / 80

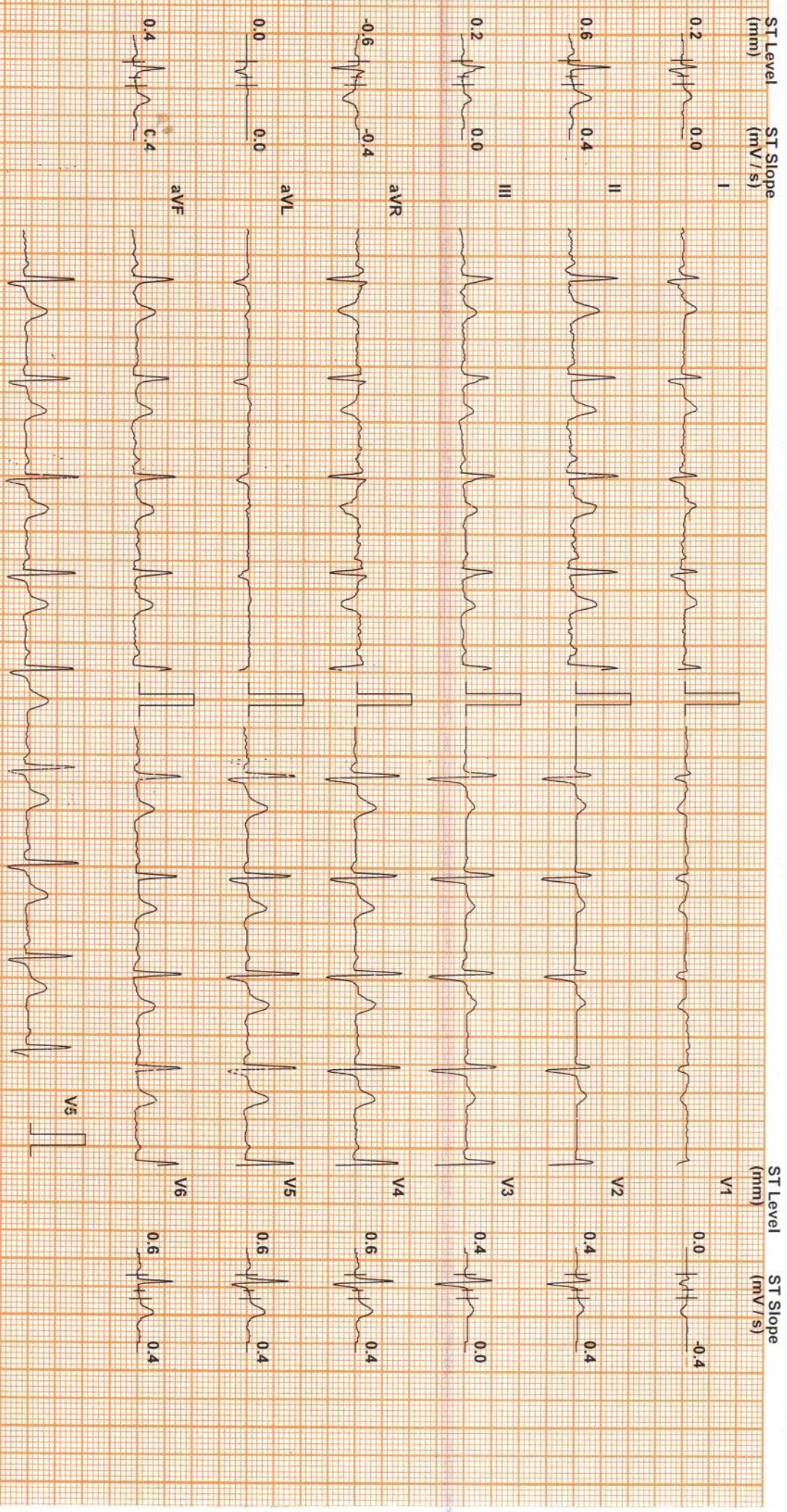


Chart Speed: 25 mm/sec

Filter: 35 Hz

Mains Fil: ON

Amp: 10 mm

ISO = R - 60 ms

J = R + 60 ms

Post J = J + 60 ms

Schiller Spandan V 4.7



REMYA (44 F)

ID: 194

Date: 10-Feb-23

Exec Time : 3 m 0 s

Stage Time : 3 m 0 s

HR: 107 bpm

Protocol: Bruce

Stage: 1

Speed: 1.7 mph

Grade: 10 %

(THR: 158 bpm)

B.P: 130 / 80

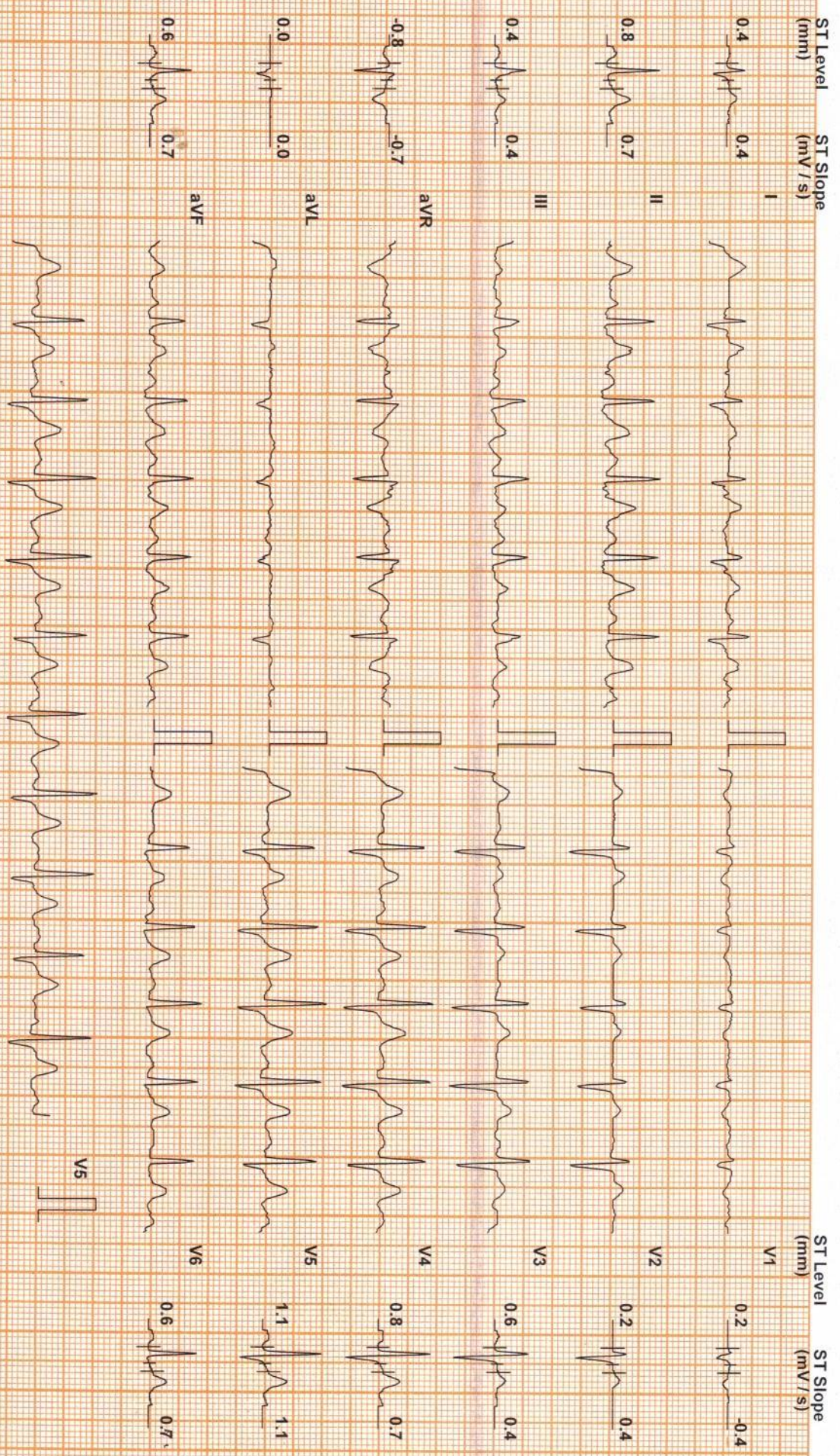


Chart Speed: 25 mm/sec  
Schiller Spanden V 4.7

Filter: 35 Hz

Mains Fil: ON

Amp: 10 mm

iso = R - 60 ms

J = R + 60 ms

Post J = J + 60 ms

DDRC SRL KOTTAYAM

REMYA (44 F)

ID: 194

Date: 10-Feb-23

Exec Time : 6 m 0 s

Stage Time : 3 m 0 s

HR: 134 bpm

Protocol: Bruce

Stage: 2

Speed: 2.5 mph

Grade: 12 %

(THR: 158 bpm)

B.P: 130 / 80

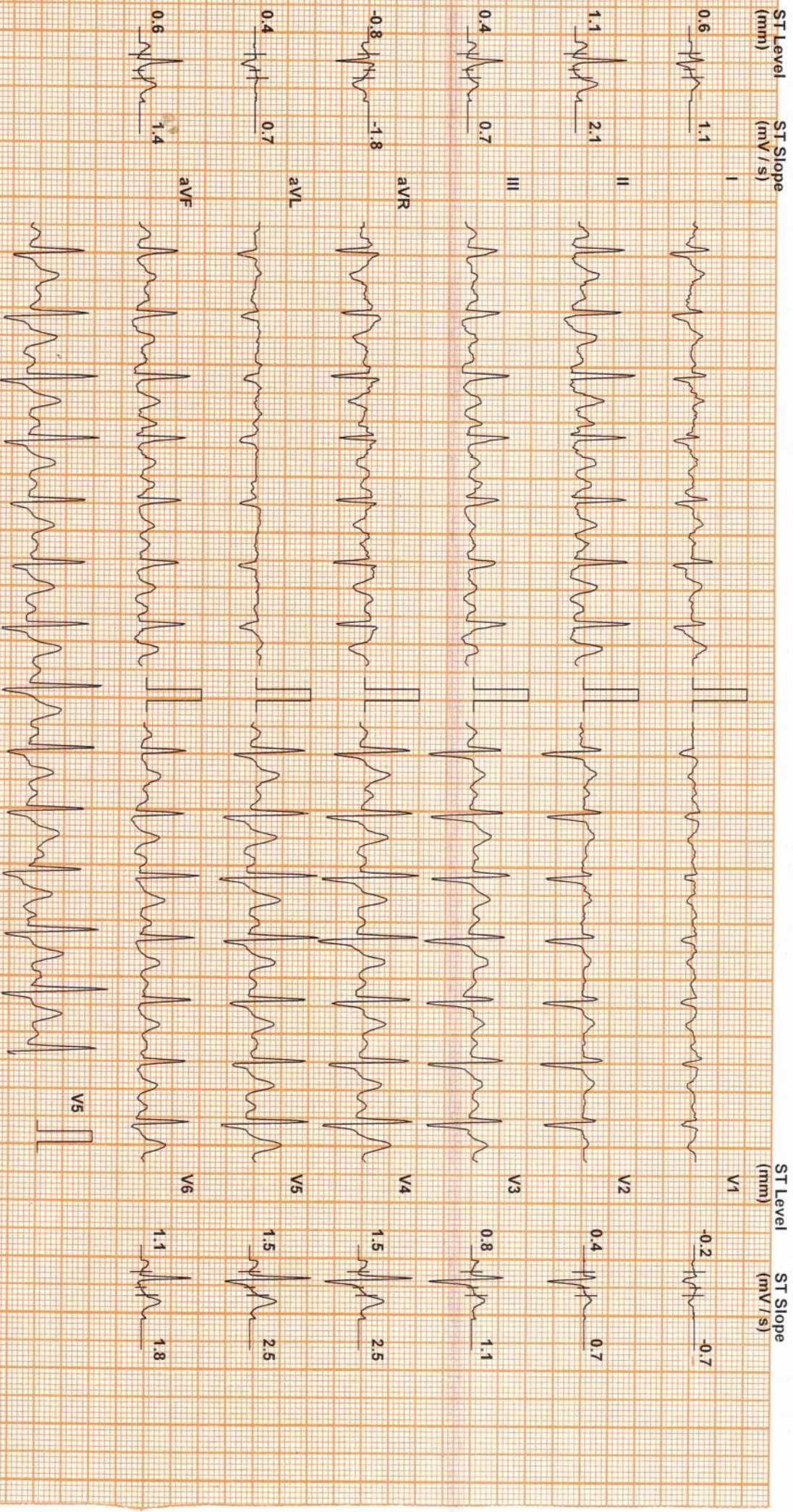


Chart Speed: 25 mm/sec  
Schlier Spandan V 4.7

Filter: 35 Hz

Mains Filt: ON

Amp: 10 mm

Iso = R - 60 ms

J = R + 60 ms

Post J = J + 60 ms

REMYA (44 F)

DDRC SRL KOTTAYAM

ID: 194

Date: 10-Feb-23

Exec Time : 8 m 0 s

Stage Time : 2 m 0 s

HR: 162 bpm

Protocol: Bruce

Stage: Peak Ex

Speed: 3.4 mph

Grade: 14 %

(THR: 158 bpm)

B.P: 130 / 80

ST Level (mm)

ST Slope (mV/s)

0.6 1.8

-0.4 -1.1

1.3 3.9

1.1 1.8

0.6 2.1

2.1 3.5

-1.1 -2.8

3.0 5.7

0.2 0.0

2.5 5.0

1.1 2.8

1.3 3.2

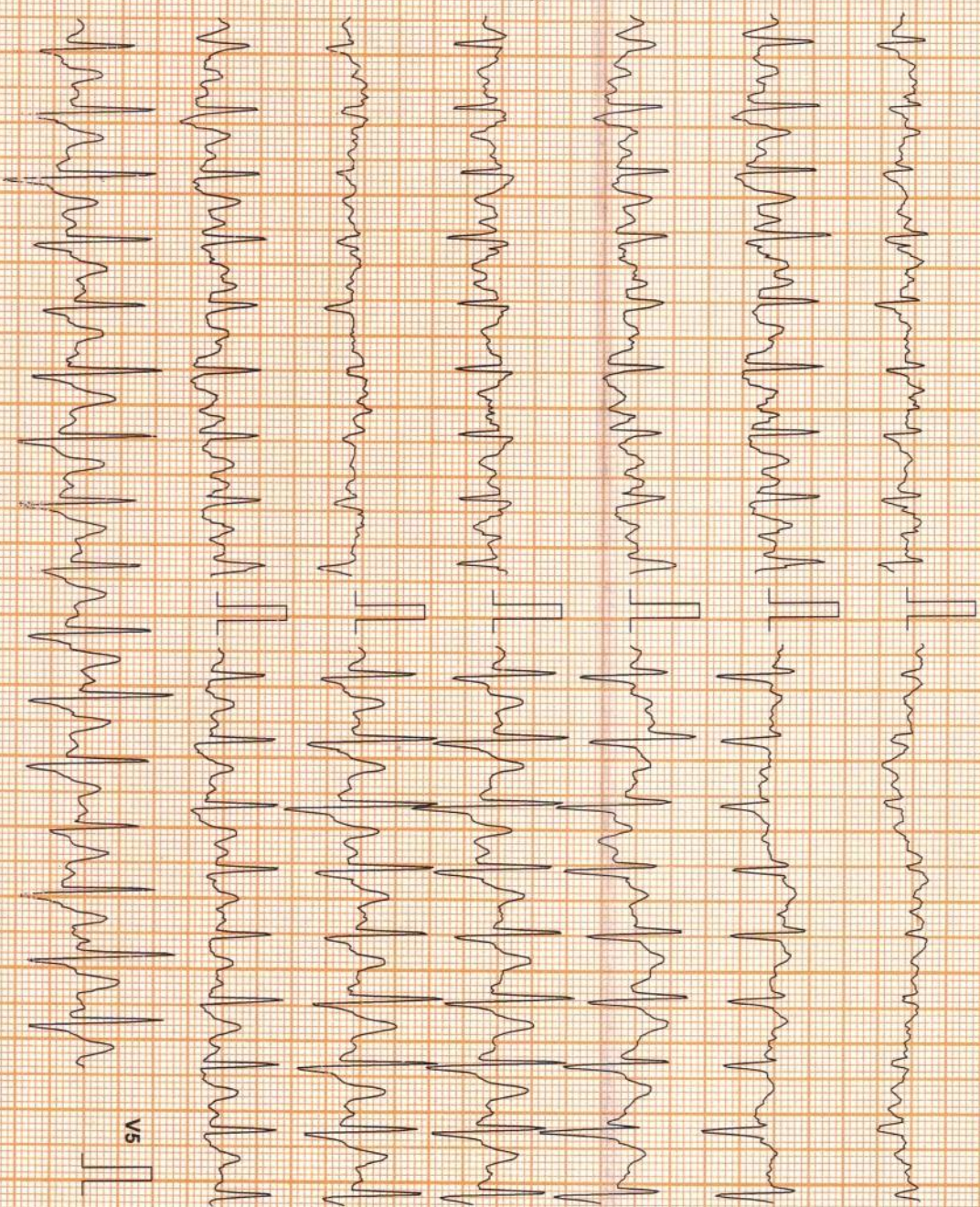


Chart Speed: 25 mm/sec  
Schlier Spannen V 4.7

Filter: 35 Hz

Mains Fil: ON

Amp: 10 mm

ISO = R - 60 ms

J = R + 60 ms

Post J = J + 60 ms

DDRC SRL DIAGNOSTICS (P) LTD. TRIVANDRUM, KOTTAYAM, COCHIN, CALICUT.

REMYA (44 F)

DDRC SRL KOTTAYAM

ID: 194

Date: 10-Feb-23

Exec Time : 8 m 0 s

Stage Time : 1 m 6 s

HR: 121 bpm

Protocol: Bruce

Stage: Recovery(1)

Speed: 0 mph

Grade: 0 %

(THR: 158 bpm)

B.P: 150 / 80

ST Level (mm) ST Slope (mV/s)

ST Level (mm) ST Slope (mV/s)

0.6 1.1

-0.2 -1.1

2.5 3.9

1.1 1.4

1.3 2.1

3.0 3.9

-1.2 -2.8

4.0 5.7

-0.2 -0.4

3.4 5.0

1.7 2.3

1.7 2.8

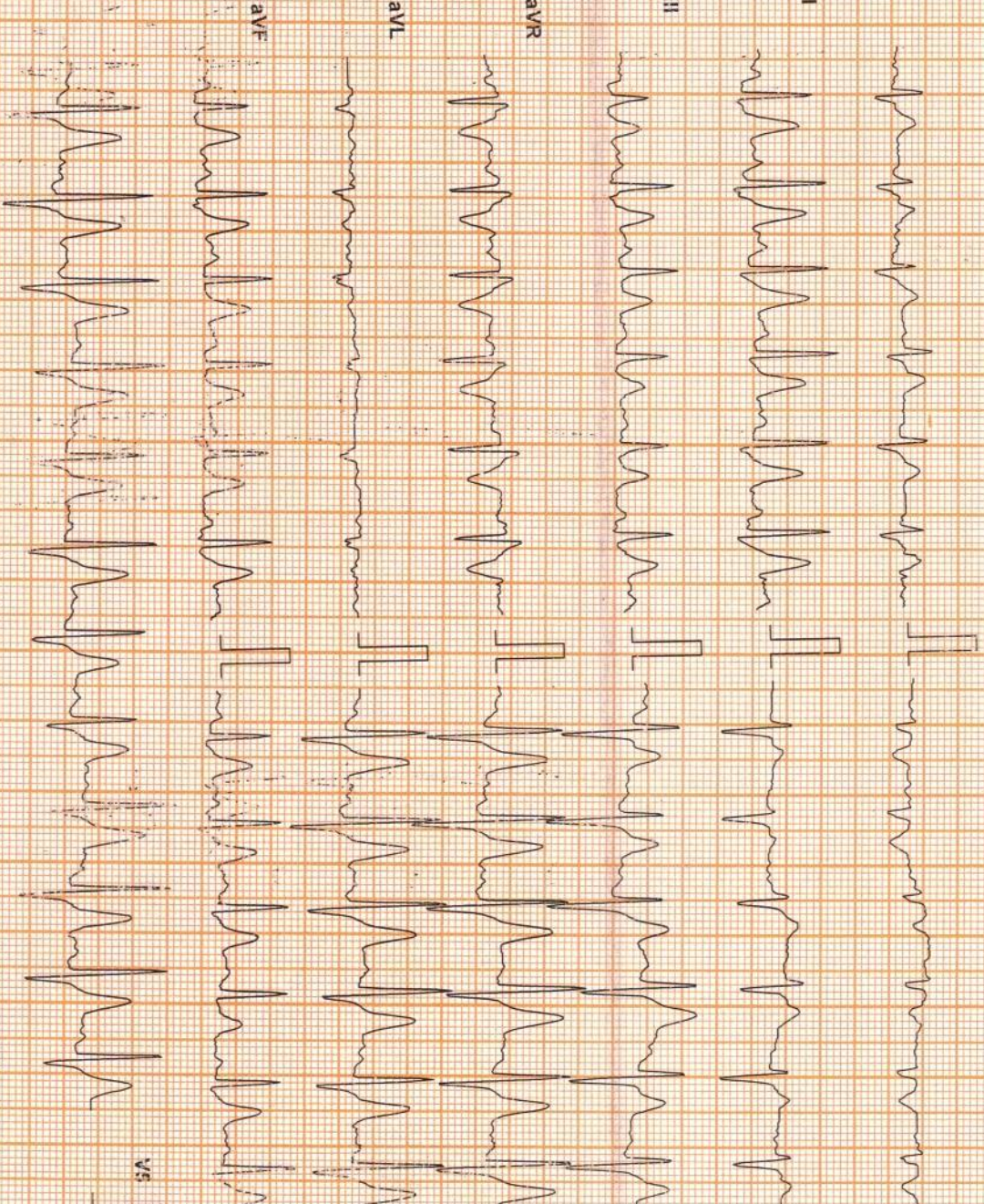


Chart Speed: 25 mm/1sec

Filter: 35 Hz

Mains Fil: ON

Amp: 10 mm

Iso = R - 60 ms

J = R + 60 ms

Post J = J + 60 ms

Schiller Spardan V 47

REMYA (44 F)

Protocol: Bruce

DDRC SRL KOTTAYAM

ID: 194

Date: 10-Feb-23

Exec Time : 8 m 0 s

Stage Time : 2 m 0 s

HR: 96 bpm

Stage: Recovery(2)

Speed: 0 mph

Grade: 0 %

(THR: 158 bpm)

B.P: 130 / 80

ST Level (mm) ST Slope (mV/s)

ST Level (mm) ST Slope (mV/s)

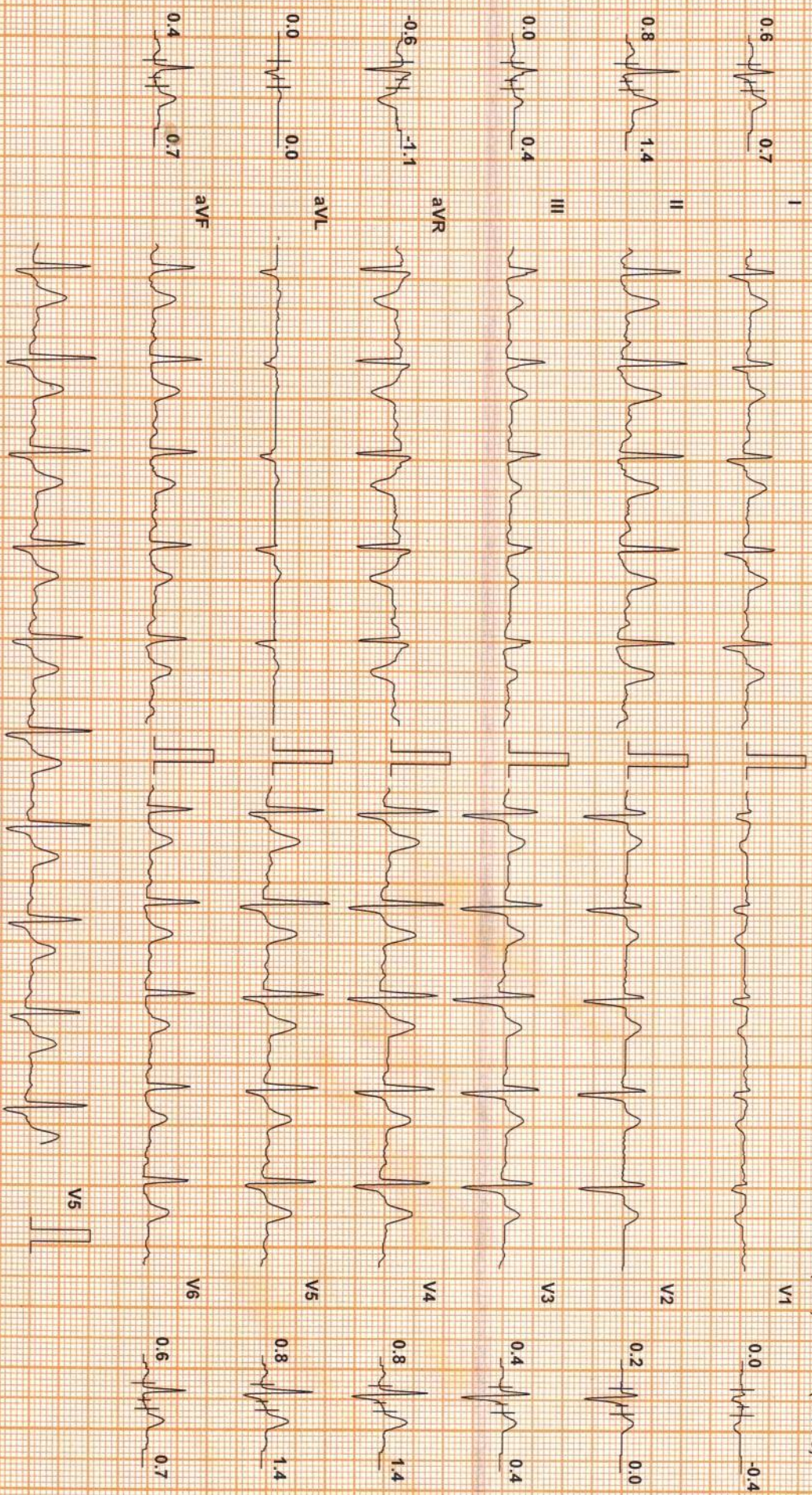


Chart Speed: 25 mm/sec  
Schiller Spandan V 4.7

Filter: 35 Hz

Mains Fil: ON

Amp: 10 mm

Iso = R - 60 ms

J = R + 60 ms

Post J = J + 60 ms

REMYA (44 F)

Protocol: Bruce

DDRC SRL KOTTAYAM

ID: 194

Date: 10-Feb-23

Exec Time : 8 m 0 s

Stage Time : 1 m 1 s

HR: 97 bpm

Stage: Recovery(3)

Speed: 0 mph

Grade: 0 %

(THR: 158 bpm)

B.P: 120 / 80

ST Level (mm) ST Slope (mV/s)

ST Level (mm) ST Slope (mV/s)




Chart Speed: 25 mm/sec  
Schiller Spandem V 4.7

Filter: 35 Hz

Mains Filt: ON

Amp: 10 mm

iso = R - 60 ms

J = R + 60 ms

Post J = J + 60 ms

To DDRC

Remeja Sursil; Bank of paroda ceos  
Medi claims - ~~objekt~~ paps mee  
& steel test ~~objekt~~ ~~objekt~~

Remeja Sursil  
Remeja

