



# PARKLINE DIAGNOSTICS PVT. LTD.

L.G. 3, 4 & 5, Bhavana Towers, S.D. Road, Secunderabad - 500 003.  
Tel : +91 40-2784 5852, 6649 1787, 7995421787, 7093445852, Fax : +91 40 2784 7864  
Email parklinediagnostics@gmail.com www.parklinediagnostics.com




NABL Accredited  
Certificate No.MC-2566

## MEDICAL EXAMINATION REPORT

Name	Mr. Sardar Singh posika		Date : 26/03/2022
Company	Olo. mediwhee1		Reg. No. : 1907309
Contact No.	7675074984		Sex <input checked="" type="checkbox"/> M Age : <input checked="" type="checkbox"/> 44
Type	Pre-Emp		Emp. No.: spouse
	Overseas		Height 162 cms
	Annual	<input checked="" type="checkbox"/>	Weight 68 kgs
Remarks	↑ Ted TSH level. Advice follow up. - Rest all clinical & lab parameters within (N) limits.		
Fitness Status	Medically Fit / Unfit	DR. PRIYANKA SANNIDHI MBBS Regn. No : 11351	
		Physician's Signature	

# COMPREHENSIVE MEDICAL EXAMINATION REPORT



NAME Mr. SARDAR SINGH

AGE 44 yrs / male

MARITAL STATUS Married CHILDREN : M  F

IDENTIFICATION (IF ANY) A mole on the LT side of neck.

## PAST HISTORY

Any family H/o : High Blood Pressure, Heart Disease, Tuberculosis, Diabetes, Asthma, Cancer

Father

Any personal H/o Major illness like : Typhoid.....NIL Jaundice.....NIL Etc.

Any H/o STD.....NIL Skin infection.....NIL

H/o Blood Transfusion.....NIL Recent Vaccination.....Allergic rashes for sawtooth

H/o Epilepsy.....NIL Giddiness.....NIL

H/o Surgery.....fracture # 2002 Fracture in the past.....fracture # 2002  
had fracture done.

Any Personal H/O.

High Blood Pressure, Heart Disease Tuberculosis, Diabetes, Asthma, Cancer

9. x 8 yrs

Drug Abuse, Drug Allergy, Micturition, Bowels, Alcohol, Smoking, Sleep, MC, Wt. Loss/Wt. Gain

Present illness / Medication Hypothyroid, T. THYRONORM, T. CILAMET. 20/50 mg  
37 mg

## GENERAL EXAMINATION

Conjunctiva :	}	NAD	Bone, Joints :	<u>(N)</u>
Skin :			Nutritional Status :	<u>well nourished</u>
Ears :			Lymph Nodes :	<u>NPD</u>
Nose :			Edema Feet :	<u>NIL</u>
Throat & Oral Cavity :			Varicose Veins :	<u>NIL</u>

**Distant Vision : Near Vision :**

Right Eye: 6/6

With glasses / Without glasses

left Eye : 6/6

with glasses / without glasses

Colour Vision : BE normal

**Right Ear**

Hearing : (N)

Rinee's Test ;

Weber Test :

Discharge : NIL

Right Eye: neg

With glasses / Without glasses

left Eye : neg

with glasses / without glasses

Ophthalmologist's Signature

**Left Ear**

Hearing : (N)

Discharge : NIL

DR. KATTA  
MBBS, D.O., FR.F  
R.S. (AMU)

**SYSTEMIC EXAMINATION**

Pulse :

B.P. :

Lungs : A. Shape of Chest B/c symmetrical  
B. Breath Sounds B/c clear ⊕  
C. Adventitious Sounds no

Heart : A. Sounds S1 S2 ⊕  
B. Murmurs no murmurs

**Nervous System**

Abdomen : A. Liver NPD  
B. Spleen NPD  
C. Piles NIL  
D. Any Lump no

A. Higher Function :  
B. Cranial Nerves :  
C. Sensory System : (2)  
D. Motor System :  
E. Jerks :

General : A. Hernia  
B. Hydrocele  
C. Varicocele NPD

Breast : Rt \_\_\_\_\_ Lt. \_\_\_\_\_

## CANDIDATE'S DECLARATION

I hereby solemnly declare that I am not suffering from Asthma, Hypertension, Diabetes, Occult Psychological disorders or any other ailment which can be suppressed without my voluntary declaration.

Date :

  
Signature

Place :

Note : General Physical Examination and Investigation included in the health check-up Have certain limitations and may not be able to detect all latent and asymptomatic diseases. Any new symptoms developing after the health check-up or persisting thereafter should be brought to the attention of the treating physician.



# PARKLINE DIAGNOSTICS PVT. LTD.

L.G. 3, 4 & 5, Bhuvana Towers, S.D. Road, Secunderabad - 500 003. Tel : +91 40-2784 5852, 6649 1787, 7995421787, 7093445852, Fax : +91 40 2784 7864 Email parklinediagnostics@gmail.com www.parklinediagnostics.com



NABL Accredited  
Certificate No.MC-2566

## ENT CONSULTATION

S.No. 1907309

Emp.No.

Date 26/3/

Name Mr. Sardar Singh  
Posika

Age 44 Yrs

Sex M/F

### EARS :

### Right

### Left

EAC : Patent, no Cerumen - do.

TM : Patent, pearly white. - do.

TFT : Cone of light (+)  
Rinne's +ve Rinne's +ve

Weber's - Central

### NOSE

: Septum (+). Bil. S. S. (+). P. S. (+) normal

### THROAT

: Oropharynx (+). Bil. v. c. (+) moving

### NECK

: (+) Anyt. (+) Bil.

### IMPRESSION:

EAD's Clinically NAD.

Dr. D. Hari Krishna Reddy  
MS (ENT)  
Head & Neck Surgeon  
Reg. No: 88379



# PARKLINE DIAGNOSTICS PVT. LTD.

L.G 3, 4 & 5, Bhuvana Towers, Sarojini Devi Road, Secunderabad - 500 003.  
Tel. +91 40 2784 5852, 6649 1787, 77995421787, 7093445852, Fax : + 91 40 2784 7864  
Email : parklinediagnostics@gmail.com, www.parklinediagnostics.com



NABL Accredited  
Certificate No.: MC-2566

## TEST REPORT

Name : Mr . SARDAR SINGH PORIKA [SPOUSE]  
Age / Gender : 44 Years / Male  
Ref.By : Medi Wheel  
Req. No : BIL1907309

TID : UMR0752995  
Registered on : 26-Mar-2022 08:39 AM  
Reported On : 26-Mar-2022 01:20 PM

### DEPARTMENT OF ULTRASOUND Ultrasound Whole Abdomen

**LIVER** is normal shape, size ( 13.4 cms) and increased echopattern with focal sparing near gall bladder.  
No intrahepatic biliary ductal dilatation.  
Hepatic and portal vein radicals are normal.

**GALL BLADDER** shows normal shape and has clear contents.  
Gall bladder wall is of normal thickness.  
CBD is of normal calibre.

**PANCREAS** has normal shape, size and uniform echopattern.  
No evidence of ductal dilatation or calcification.

**SPLEEN** shows normal shape, size and echopattern.

**KIDNEYS** move well with respiration and have normal shape, size and echopattern.  
Cortico- medullary differentiations are well madeout.  
No evidence of calculus or hydronephrosis.  
Right.kidney measures 9.2 x 4.3 cms; Left kidney measures 9.0 x 4.3 cms.

**URINARY BLADDER** shows normal shape and wall thickness.  
It has clear contents. No evidence of diverticula.


**PROSTATE** shows normal shape, size and echopattern.

No evidence of free fluid in the abdomen

#### IMPRESSION:

\* Grade I Fatty liver with focal sparing near gall bladder.

Suggested clinical correlation and follow up

  
Dr. Abid Yazgen  
Consultant Radiologist

The Test marked with\*are not accredited by NABL

Lab Timings (Weekdays) : 7.00 am to 8.30 pm  
Sundays & Holidays : 7.00 am to 1.00 pm

Radiologists Timings (Weekdays) : 7.30 am to 1.30 pm  
& 5.30 pm to 7.45 pm  
Sundays & Holidays : 7.30 am to 9.30 am

7799686970

Name : sarobe singh ..... Sex : M ..... Age : 44 .....


Date : 20/3/22 .....

OPD No : 534 .....

PDC int  


Dr.

Adv. opG.

  
 MULTI SPECIALITY DENTAL CLINIC  
 Smile Confidentially... Not Confidentially...  
 B.D.S, IMPLANTOLOGIST (USA)  
 1-3-1, Rajamudaliar Street, Kalasiguda,  
 Secunderabad, Cell : 807791

--	--	--	--	--	--

--	--	--	--	--	--



# PARKLINE DIAGNOSTICS PVT. LTD.

L.G 3, 4 & 5, Bhuvana Towers, Sarojini Devi Road, Secunderabad - 500 003.  
Tel. +91 40 2784 5852, 6649 1787, 77995421787, 7093445852, Fax : + 91 40 2784 7864  
Email : parklinediagnostics@gmail.com, www.parklinediagnostics.com



NABL Accredited  
Certificate No.: MC-2566

## TEST REPORT

Name	: Mr . SARDAR SINGH PORIKA [SPOUSE]	TID	: UMR0752995
Age / Gender	: 44 Years / Male	Registered on	: 26-Mar-2022 08:39 AM
Ref.By	: Medi Wheel	Reported On	: 26-Mar-2022 10:12 AM
Req. No	: BIL1907309		

### X-RAY CHEST PA VIEW

Lung fields are clear.

Cardia is normal.

Hila are normal.


C P angles are free.

Bony cage is normal.

Soft tissues are normal.

**IMPRESSION : NORMAL CHEST X-RAY**



  
**Dr. D.J. MOHAN**  
MD DMRD  
(Reg No. 8995)  
Consultant Radiologist

*The Test marked with\*are not accredited by NABL*

Lab Timings (Weekdays) : 7.00 am to 8.30 pm  
Sundays & Holidays : 7.00 am to 1.00 pm

Radiologists Timings (Weekdays) : 7.30 am to 1.30 pm  
& 5.30 pm to 7.45 pm  
Sundays & Holidays : 7.30 am to 9.30 am

Page 1 of 1



ID: 1907309

26-03-2022 09:21:17 AM

CARDIART

MR.SARDAR SINGH PORIKA

Male 44Years

HR : 73 bpm  
P : 108 ms  
PR : 156 ms  
QRS : 95 ms  
QT/QTc : 380/419 ms  
P/QRS/T : 51/39/23 °  
RV5/SV1 : 1.317/0.307 mV

Diagnosis Information:  
Sinus Rhythm  
\*\*\*Normal ECG\*\*\*

NSA  
Dr. NAVEEN KUMAR .C  
M.D., D.M.  
Consultant Cardiologist  
Reg. No. 52291

Report Confirmed by:

PATIENT SUMMARY REPORT

RKLINE DIAGNOSTICS PVT.LTD

LT

: 1907309  
ME : MR.SARDAR SINGH PORIKA  
E / SEX : 44 / MALE

HEIGHT (cm) : 162  
WEIGHT (kg) : 68  
PROTOCOL : BRUCE

REF. BY : MEDIWHEEL  
DONE BY : DR.NAVEEN KUMAR C  
TECHNICIAN : G.M.SURESH

022, 09:43:

ASE HISTORY :

EDICATION :

BJECT OF TEST : Routine Check Up.

SK FACTOR : Hypertension.

CTIVITY : Very Active.

OTHER INVESTIGATION : ECG

ASON FOR TERMINATION : THR ACHIEVED

ERCISE TOLERANCE : Good (> 10 METS).

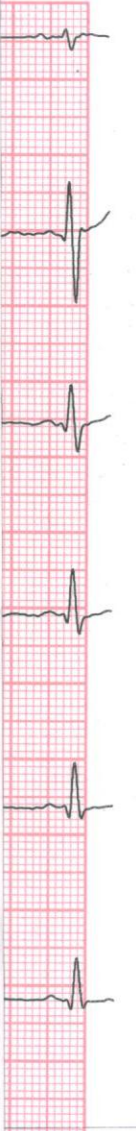ERCISE INDUCED ARRHYTHMIAS : No.

AEMO RESPONSE : Normal.

HRONO RESPONSE : Normal.

INAL IMPRESSION :  
negative for inducible ischemia

TRA COMMENTS :



Dr. NAVEEN KUMAR .C  
M.D., D.M.  
Consultant Cardiologist  
Reg. No. 52291

Confirmed By: \_\_\_\_\_

Signature