

**OUT PATIENT BILL**

Visit No. :	OP3.0029689	Bill Date & Time :	12/08/2023 09:03 AM
UHID :	WHN2.0000343136	Bill No. :	OCR3/24/0002138
Patient Name :	MR. PRAVIN GADBAIL	Bill Type :	Credit
Age/Gender :	34 Yrs/Male	Hospital GSTIN :	27AAACW3342G1ZH
Consultant :	Dr. WOCKHARDT DOCTOR	Department :	Health Check Up
Hospital PAN No. :	AAACW3342G	Name of Company :	MEDIWHEEL
Mobile No. :	9359383305	Name of TPA/insurance :	CORPORATE
Doctor Code :	1127	Ref. Doctor :	

Sr. No.	Service Name	Qty.	Amount
1	MEDIWHEEL FULL BODY HCU MALE AND FEMALE BELOW 40	1	2200.00
<b>Total Amount (Rs.) :</b>			<b>2200.00</b>
<b>Net Amount (Rs.) :</b>			<b>2200.00</b>

Amount In Words : Rs. TWO THOUSAND TWO HUNDRED ONLY

Received with thanks from -

Remark :

Payer/Patient	Bill Amt.	GST At Bill	Disc.	Deposit	Receipt	Refund	TDS	Credit Note	Debit Note	Balance
MEDIWHEEL	2200.00	0.00	0.00	0.00	0.00	0.00	0.00	0.00	0.00	2200.00
Patient	0.00	0.00	0.00	0.00	0.00	0.00	0.00	0.00	0.00	0.00
<b>Total</b>	<b>2200.00</b>	<b>0.00</b>	<b>0.00</b>	<b>0.00</b>	<b>0.00</b>	<b>0.00</b>	<b>0.00</b>	<b>0.00</b>	<b>0.00</b>	<b>2200.00</b>

**Total : 2200.00**

Cashier : VINAY ZADE

Print Date & Time : 12/08/2023 09:04 AM

I have persued the above mentioned bill and acquiesce to the same. I undertake to make the payment immediately and this undertaking will be binding upon me and/or my legal heirs for any non-payment of the bill. This undertaking shall be enforceable till the full and final amount is realized.



User : VINAY ZADE

VINAY ZADE

Prepared By

Printed By

Authorised By

Patient / Attendant Sign



**WOCKHARDT HOSPITALS, NAGPUR**

1643, North Ambazari Road, Nagpur - 440 010. Tel : (0712) 6624444, 6624100

Website : www.wockhardthospitals.com

Registered Office : A/501, 5th Floor, Kanakia Zillion, Next to Kuria Bus Depot, Kuria, Mumbai - 400070, India. Tel: +91-22-2653 6917

CIN : U85100MH1991PLC063096

*10/10/10*  
**Blood Pressure** : 150/80 mm of Hg

**Height** : 171 cm

**Weight** : 72 Kg

**Body Mass Index** : 24.6

**EMERGENCY**

**ACCIDENT & TRAUMA UNIT**

---



Medicine Delivery at Your Doorstep Call.:  
**07720965555**

**DEPARTMENT OF LABORATORY MEDICINE**

**HEMATOLOGY**

**Final Report**

<b>Patient Name</b> : MR. PRAVIN GADBAIL	<b>Order Date</b> : 12/08/2023 09:03 AM
<b>Age / Sex</b> : 34 Years / Male	<b>Sample Collection</b> : 12/08/2023 09:12 AM
<b>UHID</b> : WHN2.0000343136	<b>Report Date</b> : 12/08/2023 10:18 AM
<b>Primary Consultant</b> : DR. WOCKHARDT DOCTOR	<b>Specimen</b> : EDTA Blood
<b>Order No.</b> : 19201	
<b>Bill No.</b> : OCR3/24/0002138	

PARAMETER	METHOD	RESULT	UNIT	B.R.I
<b>MEDIWHEEL FULL BODY HCU MALE AND FEMALE BELOW 40</b>				
<b>Complete Blood Count (With ESR)- EDTA Blood</b>				
Haemoglobin	SLS Method	14.0	g%	11-15
Haematocrit	RBC Pulse Height Detection	42.6	%	40 - 50
MCV	Calculated	85.2	fl	83-101
MCH	Calculated	28.0	pg	27-32
MCHC	Calculated	32.9	g/dl	32-35
RBC Count	DC Detection	5.00	Million/ul	4.5-5.5
RDW-CV	Calculated	12.6	%	12-14
WBC Total Count ( TLC )	Electrical Impedance	9230	Cells/cumm	4000 - 10000
Neutrophils	Hydrodynamic Focussing And Microscopy	62	%	40-80
Lymphocytes	Hydrodynamic Focussing And Microscopy	26	%	20-40
Monocytes	Hydrodynamic Focussing And Microscopy	08	%	2-10
Eosinophils	Hydrodynamic Focussing And Microscopy	04	%	0-6
Basophils	Hydrodynamic Focussing And Microscopy	00	%	0-2
Platelet Count	Hydrodynamic Focussing DC	302	Thou/Cumm	150-450
MPV	Calculated	8.4	fl	9.4 -12.3
Neutrophil Lymphocyte Ratio		2.38		
Blood ESR	Westergren Method	15	mm/hr	0-15

--- END OF REPORT ---



**SONAL SINGH**  
Verified By

Nagpur  
**Dr. LAXMI LOKESH**  
Consultant Pathologist  
MDPATH

Partial Reproduction of Report not permitted. This Report Relates to Sample received by Laboratory  
\* B.R.I : BIOLOGICAL REFERENCE INTERVAL      \*\* Test not in Scope of Accreditation



**WOCKHARDT HOSPITALS, NAGPUR**

1643, North Ambazari Road, Nagpur - 440 010. Tel : (0712) 6624444, 6624100

Website : [www.wockhardthospitals.com](http://www.wockhardthospitals.com)

Registered Office: A/501, 5th Floor, Kanakia Zillion, Next to Kurla Bus Depot, Kurla, Mumbai - 400070, India. Tel: +91-22-2653 0691

CIN : U85100MH1991PLC063096



**DEPARTMENT OF LABORATORY MEDICINE**

**BIOCHEMISTRY**

**Final Report**

**Patient Name** : MR. PRAVIN GADBAIL  
**Age / Sex** : 34 Years / Male  
**UHID** : WHN2.0000343136  
**Primary Consultant** : DR. WOCKHARDT DOCTOR  
**Order No.** : 19201  
**Bill No.** : OCR3/24/0002138  
**Order Date** : 12/08/2023 09:03 AM  
**Sample Collection** : 12/08/2023 09:12 AM  
**Report Date** : 12/08/2023 10:02 AM  
**Specimen** : Serum

PARAMETER	METHOD	RESULT	UNIT	B.R.I
<b>MEDIWHEEL FULL BODY HCU MALE AND FEMALE BELOW 40</b>				
Serum Urea	Urease-GLDH	21.3	mg/dL	1-50
Blood Urea Nitrogen	Calculated	9.95	mg/dL	6-20
<b>Creatinine- Serum</b>				
Creatinine	Enzymatic colorimetric	0.79	mg/dL	0.67-1.17
<b>Plasma Glucose</b>				
Plasma Glucose - Fasting.	Enzymatic Hexokinase	96.7	mg/dL	74-109
Urine Sugar Fasting	Double Sequential Enzyme Reaction - GOD/ POD	Absent		
<b>Uric Acid- Serum</b>				
Uric Acid	Enzymatic colorimetric	6	mg/dL	3.4-7
<b>Lipid Profile</b>				
Cholesterol	Colorimetric - Cholesterol Oxidase	<b>173.09</b>	mg/dL	0-200
Triglycerides	Enzymatic colorimetric	73	mg/dL	0-150
HDL Cholesterol - Direct	Direct Homogenous Enzymatic Colorimetric	39		1. No Risk: >65 2. Moderate Risk: 45 - 65 3. High Risk: <45
LDL-Cholesterol -Direct	Direct Homogenous Enzymatic Colorimetric	<b>119.49</b>	mg/dL	0-100
VLDL Cholesterol	Calculated	14.6	mg/dL	10-35
Chol/HDL Ratio		<b>4.43</b>		1.Low Risk: 3.3-4.4 2.Average Risk: 4.4-7 .1 3.Moderate Risk: 7.1-11.0 4.High Risk: >11.0



**DEPARTMENT OF LABORATORY MEDICINE**

**BIOCHEMISTRY**

Final Report

Patient Name : MR. PRAVIN GADBAIL  
 Age / Sex : 34 Years / Male  
 UHID : WHN2.0000343136  
 Primary Consultant : DR. WOCKHARDT DOCTOR  
 Order No. : 19201  
 Bill No. : OCR3/24/0002138  
 Order Date : 12/08/2023 09:03 AM  
 Sample Collection : 12/08/2023 09:12 AM  
 Report Date : 12/08/2023 10:02 AM  
 Specimen : Serum

PARAMETER	METHOD	RESULT	UNIT	B.R.I
-----------	--------	--------	------	-------

**MEDIWHEEL FULL BODY HCU MALE AND FEMALE BELOW 40**

**Liver Function Test (L.F.T.)**

Alkaline Phosphatase	Colorimetric IFCC	72.1	U/L	40-129
S.G.O.T (AST)	IFCC Without Pyridoxal 5 Phosphate	15.6	U/L	0-40
S.G.P.T (ALT)	IFCC Without Pyridoxal 5 Phosphate	14.6	U/L	0-50
Total Protein (Serum)	Colorimetric - Biuret Method	7.26	g/dL	6.4-8.3
Albumin, BCG	Colorimetric - Bromo-Cresol Green	5.02	g/dL	3.5-5.2
Globulin	Calculated	2.24	g/dL	1.9-3.5
Albumin/Globulin Ratio	Calculated	2.24		0.9-2
Serum Total Bilirubin	Colorimetric Diazo	0.55	mg/dL	0-1.2
Serum Direct Bilirubin	Colorimetric Diazo	0.24	mg/dL	0-0.4
Serum Indirect Bilirubin	Calculated	0.31	mg/dL	0-1

--- END OF REPORT ---

**SONAL SINGH**  
Verified By

  
**Dr. LAXMI LOKESH**  
 Consultant Pathologist  
 MDPATHI

Partial reproduction of Report not permitted. This Report Relates to Sample received by Laboratory  
 \* B.R.I : BIOLOGICAL REFERENCE INTERVAL \*\* Test not in Scope of Accreditation

**DEPARTMENT OF LABORATORY MEDICINE**

**BIOCHEMISTRY**

Final Report

<b>Patient Name</b> : MR. PRAVIN GADBAIL	<b>Order Date</b> : 12/08/2023 09:03 AM
<b>Age / Sex</b> : 34 Years / Male	<b>Sample Collection</b> : 12/08/2023 09:12 AM
<b>UHID</b> : WHN2.0000343136	<b>Report Date</b> : 12/08/2023 10:35 AM
<b>Primary Consultant</b> : DR. WOCKHARDT DOCTOR	<b>Specimen</b> : EDTA Blood
<b>Order No.</b> : 19201	
<b>Bill No.</b> : OCR3/24/0002138	

PARAMETER	METHOD	RESULT	UNIT	B.R.I
-----------	--------	--------	------	-------

**MEDIWHEEL FULL BODY HCU MALE AND FEMALE BELOW 40**

**Glycosylated Haemoglobin- EDTA Blood**

Glycosylated Haemoglobin	HPLC	5.8	%	Action required: 7.0-8.0% Good control: 6.5-7.0% Normal control: 4.8-6.4% Poor control: >8.0%
Estimated Mean glucose	Calculated	129.18	mg/dL	

--- END OF REPORT ---

**SONAL SINGH**

Verified By

  
**Dr. LAXMI LOKESH**  
Consultant Pathologist  
MDPATH

Partial Reproduction of Report not permitted. This Report Relates to Sample received by Laboratory  
\* B.R.I : BIOLOGICAL REFERENCE INTERVAL \*\* Test not in Scope of Accreditation



**WOCKHARDT HOSPITALS, NAGPUR**

1643, North Ambazari Road, Nagpur - 440 010. Tel : (0712) 6624444, 6624100

Website : www.wockhardthospitals.com

Registered Office : A/501, 5th Floor, Kanakia Zillion, Next to Kurla Bus Depot, Kurla, Mumbai - 400070, India. Tel: +91-22-2653 6917

CIN : U85100MH1991PLC063096

**DEPARTMENT OF LABORATORY MEDICINE**

**IMMUNOLOGY**


Final Report

<b>Patient Name</b> : MR. PRAVIN GADBAIL	<b>Order Date</b> : 12/08/2023 09:03 AM
<b>Age / Sex</b> : 34 Years / Male	<b>Sample Collection</b> : 12/08/2023 09:12 AM
<b>UHID</b> : WHN2.0000343136	<b>Report Date</b> : 12/08/2023 10:12 AM
<b>Primary Consultant</b> : DR. WOCKHARDT DOCTOR	<b>Specimen</b> : Serum
<b>Order No.</b> : 19201	
<b>Bill No.</b> : OCR3/24/0002138	

PARAMETER	METHOD	RESULT	UNIT	B.R.I
<b>MEDIWHEEL FULL BODY HCU MALE AND FEMALE BELOW 40</b>				
TOTAL T3	ECLIA	142.6	ng/dl	80-200
TOTAL T4	ECLIA	8.7	ug/dl	4.5-11.7
TSH	ECLIA	2.27	μIU/mL	0.2-4.2

--- END OF REPORT ---

**VAISHALI CHALSE**  
Verified By

  
**Dr. LAXMI LOKESH**  
Consultant Pathologist  
MDPATH

Partial Reproduction of Report not permitted. This Report Relates to Sample received by Laboratory  
\* B.R.I : BIOLOGICAL REFERENCE INTERVAL      \*\* Test not in Scope of Accreditation



**DEPARTMENT OF LABORATORY MEDICINE**

**CLINICAL PATHOLOGY**

Final Report

**Patient Name** : MR. PRAVIN GADBAIL  
**Age / Sex** : 34 Years / Male  
**UHD** : WHN2.0000343136  
**Primary Consultant** : DR. WOCKHARDT DOCTOR  
**Order No.** : 19201  
**Bill No.** : OCR3/24/0002138  
**Order Date** : 12/08/2023 09:03 AM  
**Sample Collection** : 12/08/2023 09:12 AM  
**Report Date** : 12/08/2023 10:18 AM  
**Specimen** : Urine

PARAMETER	METHOD	RESULT	UNIT	B.R.I
-----------	--------	--------	------	-------

**MEDIWHEEL FULL BODY HCU MALE AND FEMALE BELOW 40**


**Urine Routine**

Physical Examination

Colour		Pale Yellow		
Appearance		Clear		
Urinalyser (Roche UriSys 1100)				
Specific Gravity		1.015		1.003 - 1.035
Reaction ( pH )		6.5		
Leukocytes, microscopy		neg	/hpf	
Erythrocytes, microscopy		neg	/hpf	
Nitrite, urinalyser		neg		
Protein, urinalyser		neg		
Glucose, urinalyser		neg		
Ketone, urinalyser		neg		
Urobilinogen urinalyser		neg		
Bilirubin urinalyser		neg		

--- END OF REPORT ---

**SONAL SINGH**  
Verified By

  
**Dr. LAXMI LOKESH**  
 Consultant Pathologist  
 MDPATH

Partial reproduction of Report not permitted. This Report Relates to Sample received by Laboratory  
 \*B.R.I : BIOLOGICAL REFERENCE INTERVAL \*\* Test not in Scope of Accreditation



**Dr Sheela S. Mundhada**

MD, MBBS, MHA&M  
Consultant Transfusion Medicine  
Fellow UICC trained at MD Anderson Cancer Centre, USA  
Medical Director  
Mobile: 9422113811  
E-mail: jjbb21@hotmail.com

**Dr. Ravi Wankhede**

Ex Sqn Ldr (IAF), MBBS, DCP  
Consultant Transfusion Medicine  
Medical Director  
Mobile: 9423683350  
Email: raviwankhede@gmail.com

**Blood Group Report****Name of the Patient :** PRAVIN . GADBAIL**Age :** 34 Year **Gender :** Male**Patient Sample ID :** JJ23-R09914**Hospital IP NO:** 343136**Reffered By Hospital :** Wockhardt Super Speciality Hosp**Sample Received :** EDTA / PLAIN**Date & Time of Sample Receiving :** 12/Aug/2023 11:12 AM**Adequacy of Sample :** Adequacy**Investigation Required :** Blood Group**Date of Release of Report :** 12/Aug/2023 11:52 AM**Report****Forward Red Cell Blood Group :** A**Reverse Serum Blood Group :** A**Rh Typing :** Rh Positive**Final Blood Group:** A Rh Positive

**Opinion :** If there is any Blood group discrepancy, it may be because of the irregular antibody present in the blood. This requires proper evaluation of Antibody Identification and Rh Phenotyping.

**Remark :****Principle of the Test :**

As the Matrix gel card containing red blood cells is centrifuged under specific conditions, the red blood cells sensitized with antibody will agglutinate in the presence of the Anti- Human Globulin reagent in the gel matrix and will be trapped in the gel column. The red blood cells, which do not react are not trapped in the gel matrix and are pelleted at the bottom of the column.

The reactions are then read and graded according to their reactivity pattern.

**End of Report****Tested By :** Prema**Verified By :** Dr. Deepika J Jain

**DEPARTMENT OF RADIO DIAGNOSTICS**

Patient Name : MR. PRAVIN GADBAIL

Age/Sex : 34 Yrs / Male

Order Date : 12/08/2023 09:03 AM

UHID : WHN2.0000343136

Referred by :

Reporting Date : 12/08/2023 10:53 AM

Order No. : 7860

Bill No. : OCR3/24/0002138

CHEST X-RAY PA VIEW :

Both lung fields are clear.

The costophrenic angles and domes of diaphragm appear normal.

No hilar or mediastinal lesion seen.

Cardiac silhouette is within normal limits.

Visualised bony thorax and soft tissues appear normal.

Impression:

Normal Chest X-Ray.



Dr. NITIN DEVKATE  
M.B.B.S., M.D.  
RADIOLOGIST



**WOCKHARDT HOSPITALS, NAGPUR**

1643, North Ambazari Road, Nagpur - 440 010. Tel: (0712) 6624444, 6624100

Website : [www.wockhardthospitals.com](http://www.wockhardthospitals.com)

Registered Office : A/501, 5th Floor, Kanakia Zillion, Next to Kuria Bus Depot, Kuria, Mumbai - 400070, India. Tel: +91-22-26538697

CIN : U85100MH1991PLC063096

**2D ECHOCARDIOGRAPHY & DOPPLER REPORT**

Name : Mr. Praveen Gadbail                      Age / Sex : 34 yrs / Male  
Done by : Dr. Dinesh Padole                      Date : August 12, 2023  
UHID NO : 343136                                      OPD

**2D Echo :**

**CHAMBERS**                      → Normal in size  
**RWMA**                              → No RWMA  
**LVEF**                                → 62 %  
**VALVES**                            → Valves are normal structurally  
**SEPTAE**                            → Intact  
**PERICARDIUM**                  → No pericardial effusion  
**CLOTS/VEGETATIONS** → Absent  
**IVC**                                 → Normal

**DOPPLER**

**E > A**  
**Flow across valves** → Normal

**CONCLUSION :**

Good LV systolic function  
LVEF - 62 %  
No regional wall motion abnormality is present  
No diastolic dysfunction  
No pulmonary hypertension

**Dr. Dinesh Padole**  
**MBBS, MD (Gen. Med.), DNB (Cardiology)**  
**Consultant - Interventional Cardiologist**



**WOCKHARDT HOSPITALS, NAGPUR**

1643, North Ambazari Road, Nagpur - 440 010. Tel : (0712) 6624444, 6624100

Website : [www.wockhardthospitals.com](http://www.wockhardthospitals.com)

Registered Office : A/501, 5th Floor, Kanakia Zillion, Next to Kuria Bus Depot, Kuria, Mumbai - 400070, India. Tel: +91-22-6624444 6917

CIN : U85100MH1991PLC063096



Sex: M

cm

Birth date: / /

mmHg

years

1100 Sinus rhythm  
9110 \*\* normal ECG \*\*

kg

Medication:  
Symptoms:

History:

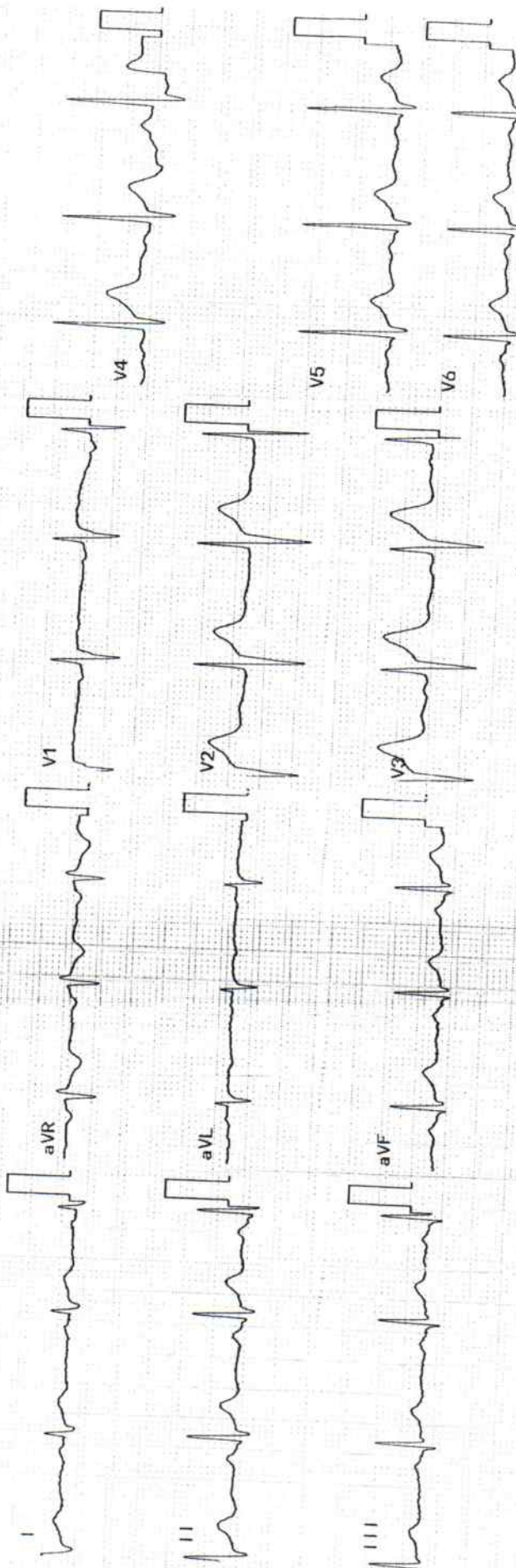
Vent. rate	83	bpm
PR int	142	ms
QRS dur	96	ms
QT/QTc(E) int	350/ 390	ms
P/QRS/T axis	58/ 72/ 61	°
RV5/SV1 amp	1.43/ 0.67	mV
RV5+SV1 amp	2.11	mV

10 mm/mV 25 mm/s Filter: H50 D 35 Hz 10 mm/mV

Unconfirmed Report  
Reviewed by:

10 mm/mV

10 mm/mV



Rhythm [V6] 10 mm/mV

Z350K 03-04 04-05

Dept.:

Exam: wockhardt-hospitals

Name : *Pravin Gadbur* Age/ Sex : yrs / Date: *12/8/25*

**Fundus Examination**  
(Direct Ophthalmoscopy)

	Right	Left
<b>Media</b>	<i>ce</i>	<i>ce</i>
<b>Optic Disc</b>		
Colour		
Size		
Shape		
Margin		
NRR		
C:D	<i>0.31</i>	<i>0.31</i>

**Blood Vessels**  
A:V ratio  
Abnormalities

**Macula**  
FR  
Abnormalities

**Periphery**

**Impression**

*(B) Full unc*  
✓

**Dr. NITIN DHOK**  
9096377550  
Consultant Ophthalmology



**WOCKHARDT HOSPITALS, NAGPUR**

1643, North Ambazari Road, Nagpur - 440 010. Tel : (0712) 6624444, 6624100

Website : www.wockhardthospitals.com

Registered Office : A/501, 5th Floor, Kanakia Zillion, Next to Kuria Bus Depot, Kuria, Mumbai - 400070, India. Tel: +91 22 653 16917  
CIN : U85100MH1991PLC063096

Dr. Vaibhav Parekh.

B.D.S., Cert. In Implantology.

Consultant - Dentist

M.S.D.C Reg No. A-19780

**WOCKHARDT**  
HOSPITALS

**LIFE**  
**WINS**

Date: 12/8/23

Name: Praveen Gadgil

UHID: 34/M

Primary Diagnosis:

Chief Complaints: Dental checkup.

T-Afe: <u>        </u> / <u>        </u> / <u>        </u>
P- <u>        </u> / <u>        </u> / <u>        </u>
R- <u>        </u> / <u>        </u> / <u>        </u>
B.P.- <u>        </u> / <u>        </u> / <u>        </u>
Pain - Yes / No <u>        </u>
Fail Risk: Yes / No <u>        </u>

R<sub>x</sub> O/E. Carious = 6/

Stains ++

Calculus ++

Adv. complete scaling.  
restorat<sup>n</sup> = 6/

7  
@

FOLLOW UP AFTER

\_\_\_\_\_ M/S



**WOCKHARDT HOSPITALS, NAGPUR**

1643, North Ambazari Road, Nagpur - 440 010. Tel: (0712) 6624444, 6624100

Fax: (0712) 2261266 Website: www.wockhardthospitals.com

Registered Office Address :- Wockhardt Towers, BKC, Bandra (East) Mumbai 400051

**DEPARTMENT OF RADIO DIAGNOSTICS**

Patient Name : MR. PRAVIN GADBAIL  
Age/Sex : 34 Yrs / Male  
UHID : WHN2.0000343136  
Reporting Date : 12/08/2023 11:33 AM  
Bill No. : OCR3/24/0002138  
Order Date : 12/08/2023 09:03 AM  
Referred by :  
Order No. : 7860

**USG ABDOMEN WITH PELVIS :**

Real time sonography of the abdomen and pelvis was performed using the 3.5 MHz transducer.

The liver is normal in size and shows bright echotexture suggesting fatty infiltration. No focal parenchymal lesion noted. Intrahepatic biliary tree and venous radicles are normal.

The portal vein and CBD appear normal in course and calibre.

The gall bladder is normal in size with a normal wall thickness and there are no calculi noted within.

The pancreas is normal in size and echotexture. No evidence of focal lesion or calcification or duct dilatation seen.

The spleen is normal in size and echotexture.

Both kidneys are normal in size, position and echogenecity.

Cortical thickness and corticomedullary differentiation are normal.

No hydronephrosis or calculi noted.

The bladder is normal in contour, capacity and wall thickness. No vesical calculi noted.

The prostate is normal in size and homogenous in echotexture.

There is no evidence of ascites.

**Impression :**

Grade I fatty infiltration of liver.

Suggested clinical and lab correlation.



Dr. NITIN DEVKATE  
M.B.B.S., M.D.  
RADIOLOGIST

