



# Mittal Hospital

## ਮਿੱਤਲ ਹਸਪਤਾਲ

For Appointment PH: 01679-237777  
For Emergency M: 99142-16070  
mittal\_parshant@yahoo.com

ਡਾ. ਪ੍ਰਸ਼ਾਂਤ ਮਿੱਤਲ

ਨੇੜੇ ਪਨਸਪ ਗੈਸ ਏਜੰਸੀ, ਨੇੜੇ ਆਰੀਆ ਮਹਿਲਾ ਕਾਲਜ, ਰਾਮ ਬਾਗ ਰੋਡ, ਬਰਨਾਲਾ

Near Pansup Gas Agency, Near LBS College,  
Ram Bagh Road, BARNALA-148101 (Pb.)

ਐਮ.ਡੀ. ਮੈਡੀਸਨ (ਡੀ.ਐਮ.ਸੀ. ਲੁਧਿਆਣਾ)  
ਐਕਸ ਮੈਡੀਕਲ ਅਫਸਰ, ਸਿਵਲ ਹਸਪਤਾਲ, ਬਰਨਾਲਾ  
ਐਕਸ ਸੀਨੀਅਰ ਰਜਿਸਟਰਾਰ, ਫੋਰਟੀਜ਼ ਹਸਪਤਾਲ, ਮੁਹਾਲੀ  
ਐਕਸ ਸਪੈਸ਼ਲਿਸਟ, ਰਾਧਾ ਸੁਆਮੀ ਹਸਪਤਾਲ, ਬਿਆਸ  
(ਦਿਲ, ਪੇਟ, ਛਾਤੀ, ਸ਼ੂਗਰ ਅਤੇ ਕਾਲੇ ਪੀਲੀਏ ਦੇ ਮਾਹਿਰ)  
PMC Regd. No. 37514

ਡਾ: ਪ੍ਰੀਆ ਗਰਗ

ਐਮ.ਡੀ. ਐਨਸਥੀਜ਼ੀਆ (ਡੀ.ਐਮ.ਸੀ. ਲੁਧਿਆਣਾ)  
ਐਕਸ ਸੀਨੀਅਰ ਰਜਿਸਟਰਾਰ ਡੀ ਐਮ ਸੀ, ਲੁਧਿਆਣਾ  
ਐਕਸ ਸੀਨੀਅਰ ਰਜਿਸਟਰਾਰ ਪੀ ਜੀ ਆਈ, ਚੰਡੀਗੜ੍ਹ  
ਐਕਸ ਕਨਸਲਟੈਂਟ ਰਾਧਾ ਸੁਆਮੀ ਹਸਪਤਾਲ, ਬਿਆਸ  
(ਆਈ.ਸੀ.ਯੂ. ਅਤੇ ਕਰੀਟੀਕਲ ਕੇਅਰ ਸਪੈਸ਼ਲਿਸਟ)  
PMC Regd. No. 36677

Name.....Age.....Sex.....Dated.....

Name- PARVESHDEEP SINGH  
Age/sex - 36/M

Ref by: Dr. PARSHANT MITTAL  
Date-February 11, 2023

### USG WHOLE ABDOMEN

**Liver-** is normal in size (14.1 cm), shape, position and echotexture. No obvious focal lesion is seen. Intrahepatic biliary radicals are not dilated. Portal vein is normal in course and caliber.

**Gall Bladder** is normally distended. Wall thickness is normal. No evidence of calculus. **Common bile duct** is normal in course and caliber.

**Pancreas** is normal in size and echotexture. Main pancreatic duct is not dilated.

**Right Kidney** is normal in size, position and echotexture. Corticomedullary differentiation maintained. No evidence of calculus/ hydronephrosis.

**Left Kidney** is normal in size, position and echotexture. Corticomedullary differentiation maintained. No evidence of calculus/ hydronephrosis.

**Spleen** is normal in size, shape and echotexture. Splenic vein is normal in caliber.

**Urinary bladder** is distended. Wall thickness is normal. No evidence of calculus.

**Prostate** ~ measures cc in volume and shows normal echopattern.

No e/o free fluid in peritoneal cavity.

**IMPRESSION-** USG abdomen reveals- Normal study

Kindly correlate clinically/Lab parameters (CBC, Urine C/E).

Dr. Parshant Mittal DR. PARSHANT MITTAL  
M.D. Medicine M. D. MEDICINE  
PMC Regd. No. 37514  
Mittal Hospital, Barnala



# Mittal Hospital

For Appointment PH: 01679-23777  
For Emergency M: 99142-1607  
mittal\_parshant@yahoo.com

## ਮਿੱਤਲ ਹਸਪਤਾਲ

ਡਾ. ਪ੍ਰਸ਼ਾਂਤ ਮਿੱਤਲ

ਨੇੜੇ ਪਨਸਪ ਗੈਸ ਏਜੰਸੀ, ਨੇੜੇ ਆਰੀਆ ਮਹਿਲਾ ਕਾਲਜ, ਰਾਮ ਬਾਗ ਰੋਡ, ਬਰਨਾਲਾ

ਐਮ.ਡੀ. ਮੈਡੀਸਨ (ਡੀ.ਐਮ.ਸੀ. ਲੁਧਿਆਣਾ)  
ਐਕਸ ਮੈਡੀਕਲ ਅਫਸਰ, ਸਿਵਲ ਹਸਪਤਾਲ, ਬਰਨਾਲਾ  
ਐਕਸ ਸੀਨੀਅਰ ਰਜਿਸਟਰਾਰ, ਵੋਰਟੀਜ਼ ਹਸਪਤਾਲ, ਮੁਹਾਲੀ  
ਐਕਸ ਸਪੈਸ਼ਲਿਸਟ, ਰਾਧਾ ਸੁਆਮੀ ਹਸਪਤਾਲ, ਬਿਆਸ  
(ਦਿਲ, ਪੇਟ, ਛਾਤੀ, ਸ਼ੂਗਰ ਅਤੇ ਕਾਲੇ ਪੀਲੀਏ ਦੇ ਮਾਹਿਰ)  
PMC Regd. No. 37514

Near Pansup Gas Agency, Near LBS College,  
Ram Bagh Road, BARNALA-148101 (Pb.)

ਡਾ: ਪ੍ਰੀਆ ਗਰਗ

ਐਮ.ਡੀ. ਐਨਸਥੀਜ਼ੀਆ (ਡੀ.ਐਮ.ਸੀ. ਲੁਧਿਆਣਾ)  
ਐਕਸ ਸੀਨੀਅਰ ਰਜਿਸਟਰਾਰ ਡੀ ਐਮ ਸੀ, ਲੁਧਿਆਣਾ  
ਐਕਸ ਸੀਨੀਅਰ ਰਜਿਸਟਰਾਰ ਪੀ ਜੀ ਆਈ, ਚੰਡੀਗੜ੍ਹ  
ਐਕਸ ਕਨਸਲਟੈਂਟ ਰਾਧਾ ਸੁਆਮੀ ਹਸਪਤਾਲ, ਬਿਆਸ  
(ਆਈ.ਸੀ.ਯੂ. ਅਤੇ ਕਰੀਟੀਕਲ ਕੇਅਰ ਸਪੈਸ਼ਲਿਸਟ)  
PMC Regd. No. 36677

Name..... Age..... Sex..... Dated.....


### X-RAY REPORT

Name: PARVESHDEEP SINGH 36/M  
Dr.: PARSHANT MITTAL

Date: 11/02/23

#### X- Ray Report: Chest pa view:

Bony cage and ribs are unremarkable.  
Both CP angles are clear.  
Trachea is central.  
Cardiac silhouette and size are normal.  
Lungs show normal parenchyma with no other active lesion.  
No scar mark present.  
No other abnormality seen.

  
DR. PARSHANT MITTAL  
M. D. MEDICINE

Dr. Parshant Mittal  
M.D. Medicine  
PMC Regd. No. 37514  
Mittal Hospital, Barnala



# MITTAL HOSPITAL

Near Pansup Gas Agency, Near LBS College, Ram Bagh Road, BARNALA-148101 (Pb.)

For Appointment  
Ht 01679-237777

For Emergency  
M: 99142-16070

*Dr. Parshant Mittal*

mittal\_parshant@yahoo.com

*Dr. Priya Garg*

M.D. Medicine (D.M.C. Ludhiana)  
Ex. Medical Officer, Civil Hospital, Barnala  
Ex. Sen. Registrar, Fortis Hospital, Mohali  
Ex. Specialist, Radha Soami Hospital, Beas  
PMC Regd. No. 37514

M.D. Anaesthesiology  
Consultant Anaesthesiology  
Ex. Registrar DMC, Ludhiana  
Ex. Sr. Registrar PGI, Chandigarh  
Ex. Consultant Radha Soami Hospital, Beas  
PMC Regd. No. 36677

## **ECHOCARDIOGRAPHY REPORT**

Name: PARVESHDEEP SINGH

Date: 11.02.2023

AGE: 36 YEARS

Sex: MALE

Done by: Dr. Parshant Mittal

	<u>MEASUREMENT</u>	<u>NORMAL ADULT VALUES</u>
AORTIC ROOT	: 29.3	(22 – 37 mm)
LEFT ATRIUM	: 33.6	(20 – 40 mm)
RVID (D)	: 10.7	(10 – 20 mm)
IVST (D)	: 08.6	(07 – 11 mm)
IVST (S)	: 11.4	(07 – 11 mm)
LVID (D)	: 46.4	(35 – 55 mm)
LVID (S)	: 29.3	(25 – 42 mm)
LVPW (D)	: 10.0	(07 – 11 mm)
LVPW (S)	: 10.7	(07 – 11 mm)
	<u>L.V. FUNCTION</u>	
EJECTION FRACTION	: 60.42%	(50 – 80%) (mod. simpson)
FRACTIONAL SHORTENING	: 36.92%	(28 – 40%)

**Mitral Valve** : Thin, opens normally. No regurgitation present.  
MVA=3.53cm<sup>2</sup>, EPSS=0.50, MAPSE=11mm. "E" wave more than "A".  
E/A ratio=1.27

**Aortic Valve** : Thin, tricuspid, opens normally.  
No aortic regurgitation present.

**Tricuspid Valve** : Thin, opens normally.  
No tricuspid regurgitation present.

**Pulmonary Valve** : Thin, opens normally.

**Pericardium** : No pericardial effusion present.

**Wall Motion Abnormalities:** No regional wall motion abnormalities present.

**Cardiac Chambers** : All the cardiac chambers are normal in size.

### DOPPLER EVALUATION

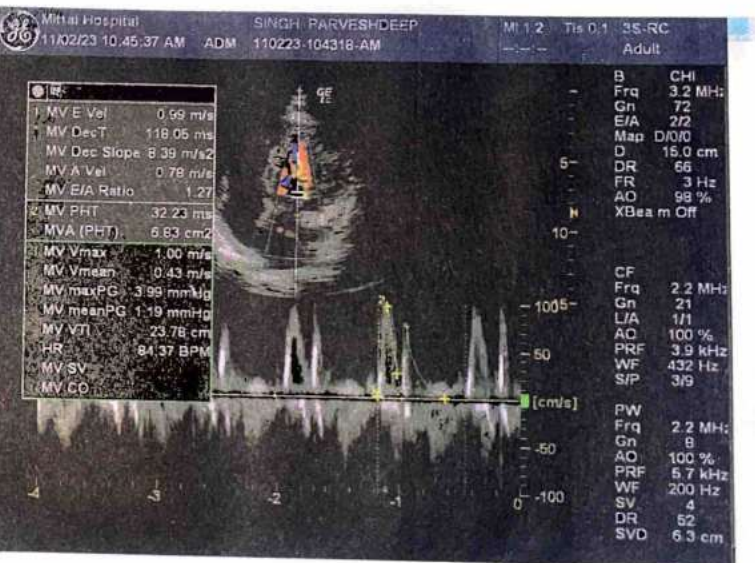
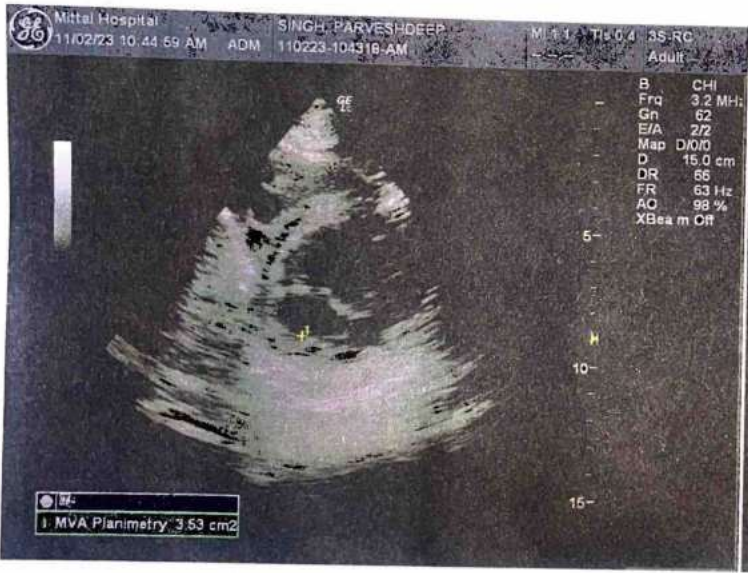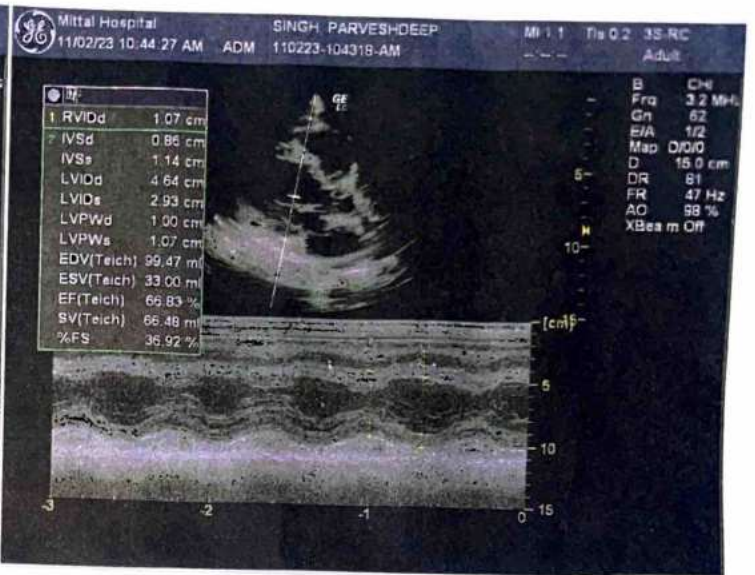
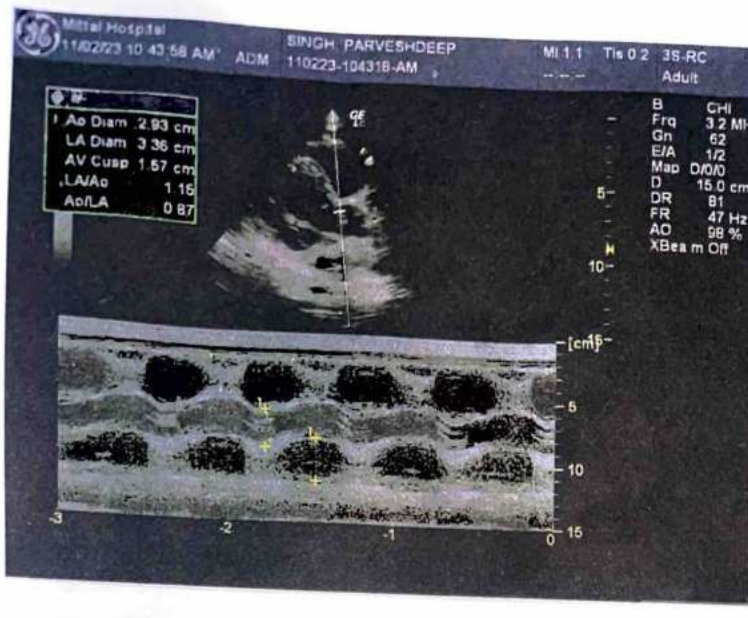
VELOCITY (GRADIENT)		(GRADE)
MV : E=99    A=78	cm/sec.	MR : NIL
AV : 111	cm/sec.	AR : NIL
TV :	cm/sec.	TR : NIL
PV :	cm/sec	PR : NIL

➤ **NO REGIONAL WALL MOTION ABNORMALITIES PRESENT WITH NORMAL LV SYSTOLIC FUNCTION (EF=60.42%).**

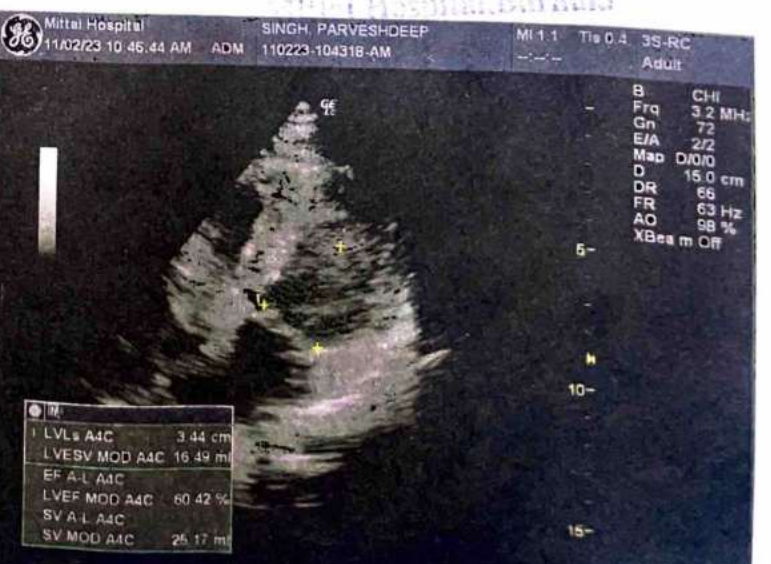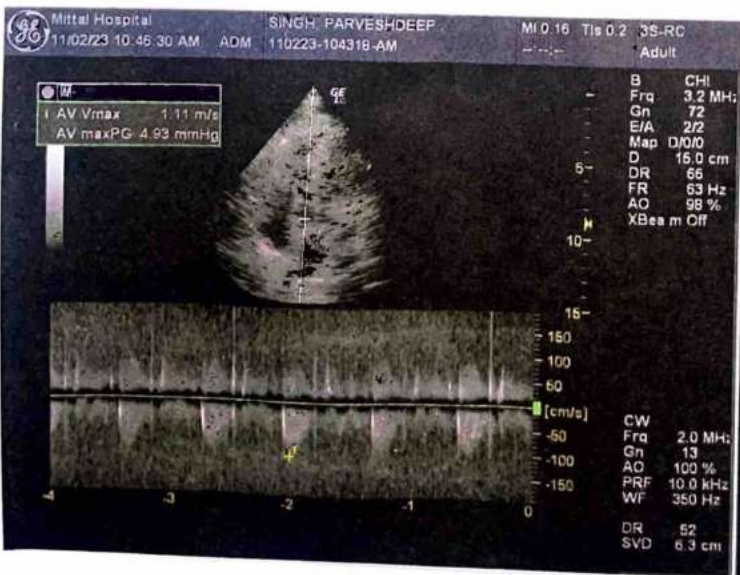


PARSHANT MITTAL  
MITTAL HOSPITAL, BARNALA  
MD (MEDICINE)

Dr. Parshant Mittal  
M.D. Medicine  
FMC Regd. No. 37514  
Mittal Hospital, Barnala



Dr. Parshant Mittal  
D.D. Medicine  
PMC Regd. No. 37514  
Mittal Hospital, Barnala



**MITTAL COMPUTERISED LAB.**

Inside Mittal Hospital, BARNALA-148101

Patient's Name PARVESHDEEP SINGH 36/M Ref. By Dr. PARSHANT MITTAL Dated 11-02-2023**HEMATOLOGY**

TEST	RESULT	NORMAL RANGE
Haemoglobin	13.9 gm/dl	Male 12.0-15.5 gm/dl Female 10-13.5 gm/dl
T.L.C.	5800 /cumm	4000-11000/cumm
<b>D.L.C. (Different Leucocyte Count)</b>		
Neutrophils	59 %	40-75%
Lymphocytes	32 %	20-45%
Eosinophils	04 %	1-6%
Monocytes	05 %	2-10%
Basophils	00 %	0-1%
MCV	89	80-99 fL
MCH	30	26-32 pg
MCHC	34	32-36 gm/dl
RDW	42	37-54 fL
Hematocrit	46	37-52
ESR (Westergreen)	04 mm. 1st Hr.	Male upto 10mm. 1st Hour. Female upto 20mm. 1st Hour.
Platelet Count	298000 /cumm.	1,50000-4,00000/cu.mm.
T Eosinophil Count	/Cumm	40-440 Cell/cumm
Total RBC COUNT	5.7	4.7-6.2 to 10 <sup>6</sup> /µl

**SEROLOGY**

Widal Test	1:20	1:40	1:80	1:160	1:320	1:640
S. Typhi O	-	-	-	-	-	-
S. Typhi H	-	-	-	-	-	-
S. Paratyphi AH	-	-	-	-	-	-
S. Paaratyphi BH	-	-	-	-	-	-
Dengue NS1						
Dengue IgM/IgG						
TSH:	2.68	(0.550-4.780 uIU/ml)				
S. T4 LEVEL:	86.7	(77-155 nmol/l)				
S. T3 LEVEL:	3.73	(0.3-4 mU/l)				
S. Vitamin D LEVEL:		(30-100 ng/mL)				

**URINE EXAMINATION**

ROUTINE EXAMINATION	
Appearance :	CLEAR
Colour :	STRAW
Sp. Gravity :	1.025
Reaction :	ACIDIC
Albumin :	NIL
Sugar :	NIL
Bile Salts:	NIL
Bile Pigments :	NIL
MICROSCOPIC EXAMINATION	
RBC	NIL
Pus Cells	RARE
Epithelial Cells	0-1/hpf
Calcium Oxalate	NIL
Spermatozoa	
URINE FOR MICROALBUMIN :	(0.00-25.0 mg/l)
URINE FOR NICOTINE:	(<5ng/ml)

**BIO-CHEMISTRY**

TEST	RESULT	NORMAL RANGE
Blood Sugar Fasting	78 mg/dl.	80-120 mg/dl.
Blood Sugar PP/Random	89 Mg/dl.	Upto 140 mg/dl.
Blood Urea Nitrogen	13 Mg/dl.	10-20 mg/dl.
S. Creatinine	0.6 mg/dl.	0.8-1.4 gm/dl.
S. Uric Acid	2.3 mg/dl.	Male 2-5 mg/dl. Female 2-4.5 mg/dl.
Blood Group	A	

**LIVER FUNCTION TEST**

S. Bilirubin (Total)	0.54 mg/dl.	0.2-1.0 mg/dl.
Conjugated	0.26	0.1-0.4 mg/dl
Unconjugated	0.28	0.1-0.6 mg/dl
S. Alkaline Phosphatase	77 U/L	37-147U/L
S.G.O.T.	19 U/L	10-40 Units/ml
S.G.P.T.	25 U/L	10-35 Units/ml
G.G.T.P	17	0-40 U/L
AUSTRALIA ANTIGEN		(Hbs Ag) Test
HBeAg		
Total Serum Proteins	7.9 gm/dl.	6.0-8.0 gm/dl.
Albumin	4.7 Gm/dl.	3.5-5.0 gm/dl.
Globulin	3.2 gm/dl.	2.0-3.5 gm/dl
S. Lipase	U/L	20-85 U/L
S. Amylase	U/L	25-80 U/L

**LIPIDOGRAM**

S. Cholesterol	163 mg/dl.	130-240 mg/dl.
S. Triglycerides	147 mg/dl.	60-170 mg/dl.
S. HDL Cholesterol	44 mg/dl.	30-60 mg/dl.
S. LDL Cholesterol	83 Mg/dl.	Upto 150 mg/dl
S. VLDL Cholesterol	27 Mg/dl.	Upto 45 mg/dl.

**ELECTROLYTES TEST**

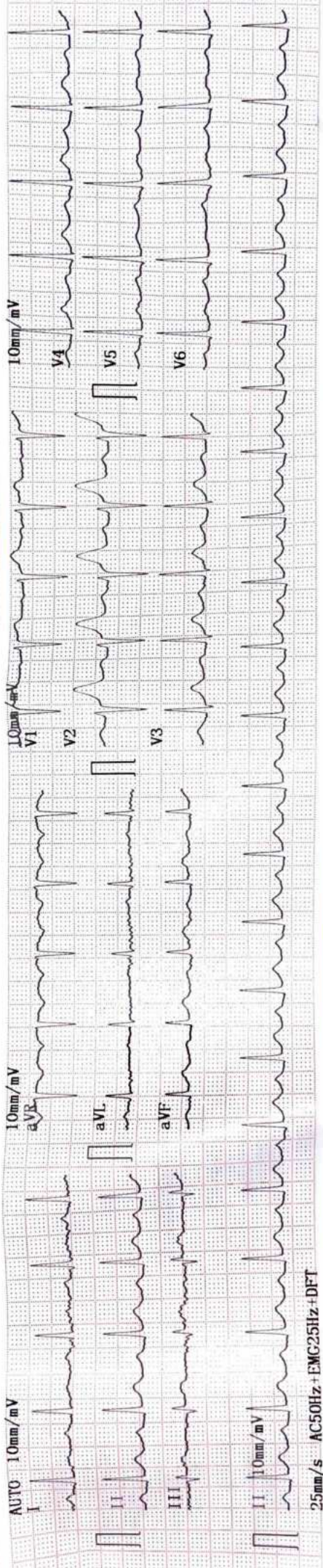
S. Chloride	mmol/L.	96-106 mmol/L.
S. Sodium	Mmol/L	135-155 mmol/L
S. Potassium	mmol/L	3.5-5.5 mmol/L

**GLYCOSYLATED HEMOGLOBIN (HbA1c)**

Reference Range	4.0 - 6.0 %	5.3 %
Good Diabetic Control	6.0 - 7.0 %	
Fair Control	7.0 - 8.0 %	
Poor Control	Above 8.0 %	
HbA1C test Value in %		Mean Plasma Glucose Level
12.0		345
11.0		310
10.0		275
9.0		240
8.0		205
7.0		170
6.0		135
5.0		100

  
 Medical Technologist

Dr. Sawan Kumar  
 M.D. Pathology  
 Reg. No. 45679



25mm/s AC50Hz+EMG25Hz+DFT

MITTAL HOSPITAL  
1970-06-18 18:09

ID: Name: PAVESH MADDIPATI / 1977  
Sex: M Age: 36 Weight:      kg  
Height:      cm  
SYS:      mmHg  
DIA:      mmHg

HR [bpm] : 99  
PR Interval [ms] : 200  
P Duration [ms] : 145  
QRS Duration [ms] : 80  
T Duration [ms] : 220  
QT/QTc [ms] : 322/415  
P/QRS/T Axis [deg] : 34.9/37.3/65.1  
R (V5)/S (V1) [mV] : 1.19/0.97  
R (V5)+S (V1) [mV] : 2.16

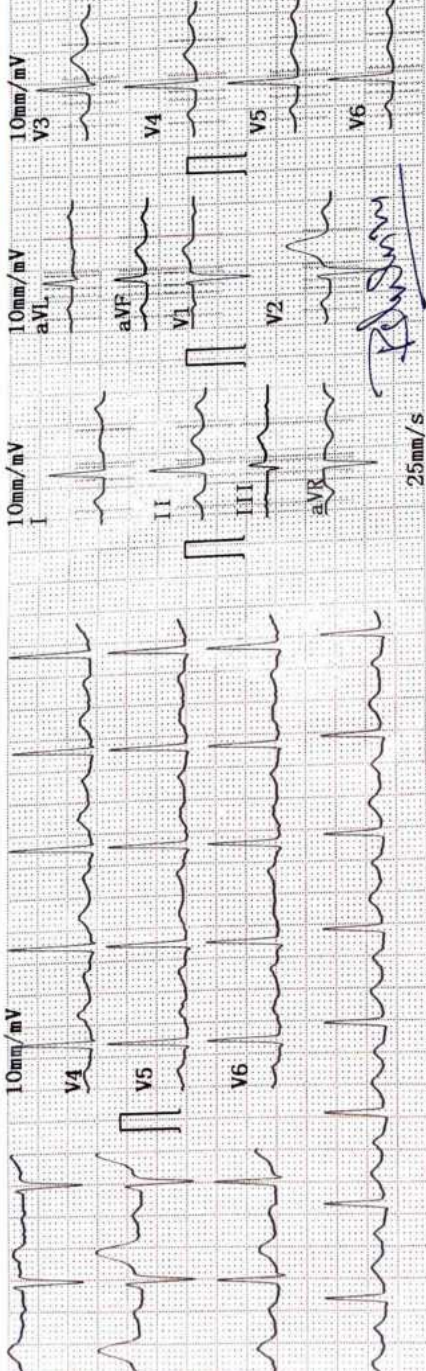
<< Conclusions >>  
Normal Sinus Rhythm.  
Normal Cardiac Electric Axis.  
I aVL V6 Abnormal T wave.

\*\*Report need physician confirm\*\*

Normal ECG

11/2/73

Physician









भारत सरकार

GOVERNMENT OF INDIA



**Parveshdeep Singh Aulakh**


ਜਨਮ ਮਿਤੀ / DOB: 08/02/1987

ਮਰਦ / MALE

Mobile No.: 9888250700

**5645 0019 6519**

VID : 9140 0526 4030 4689



**ਮੇਰਾ ਆਧਾਰ, ਮੇਰੀ ਪਛਾਣ**




भारतीय विशिष्ट पहचान प्राधिकरण  
UNIQUE IDENTIFICATION AUTHORITY OF INDIA

Generation Date: 2/10/21/2012


**Address:**

S/O Bikkar Singh Aulakh, H.NO.B-XIII-  
1223, Sahid Bhagat Singh Nagar,  
Barnala, Barnala, Punjab - 148101

QR Code with Photograph




**5645 0019 6519**  
VID : 9140 0526 4030 4689



  
1947  
1800 300 1947

  
help@uidai.gov.in

  
www.uidai.gov.in

  
P.O. Box No. 1947,  
Bengaluru-560 001