

Facilities:
 All clinical Biomedical & Hematology Investigations
 including Bone Marrow Examination
 VPT, Podiascan & Complete Foot Care (First Time in Purvanchal)
 All Hormonal Investigation by Chemiluminescent Method
 Visceral Fat by (AB-140) Ambulatory BP Monitoring
 CGMS & Insulin Pump Available
 PFT, 2D-ECHO (Color Doppler), Holter, TMT, Cardiac-3 available
 VIA, VILI, Colposcopy available
 Special Endocrinological Investigation Protocols.

ISO 9001:2008 Certified
 Mobile: 9389994334, 9554572190, 9453837595



Panacea Pathology Clinical Reference Lab

Persistence, Preparedness and Precision
 EQAS (CMC Vellore Attached) & IQAS System
 पूर्वांचल की सर्वोत्तम गुणवत्ता वाली पैथोलॉजी

PATIENT NAME : POOJA PANDEY	AGE/GENDER : 26 YRS/FEMALE
REFD BY DR. : ARCO FEMI HEALTHCARE LTD.	RECEIVED DATE : 11-12-2022 (09:45 AM)
SAMPLE : BLOOD & URINE	REPORT DATE : 11-12-2022 (18:15 PM)

PATHOLOGY REPORT

COMPLETE BLOOD COUNT (CBC)

TEST	LAB TEST VALUES	NORMAL RANGE
HEMOGRAM		
HEMOGLOBIN (FLOW CYTOMETRY)	12.9	13 – 16 gm/dl
TOTAL LEUCOCYTE COUNT (TLC)	8300	4000 – 11000
RBC COUNT	5.01	3.5 – 5.5
PCV (HCT)	40.4	37 – 47
MCV	80.6	80 – 95
MCH	25.7	28 – 34
MCHC	31.9	30 – 36
PLATELET COUNT	2.92000	1,50,000 – 4,00,000
E.S.R. (WINTROBE FIRST HOURS)	12.0	20 mm/1 st hr
DIFFERENTIAL LEUCOCYTE		
NEUTROPHILS	73	40 – 75%
LYMPHOCYTES	21	20 – 45%
EOSINOPHILS	04	1 – 6%
MONOCYTES	02	2 – 8%
BASOPHILS	00	< 2 %

RENAL & KIDNEY PROFILE, SERUM

TEST	LAB TEST VALUES	NORMAL RANGE
RENAL FUNCTION TESTS		
BLOOD UREA NITROGEN (BUN)	11.6	10 – 50 mg/dl
SERUM CREATININE	0.73	0.60 – 1.60 mg/dl
URIC ACID	4.2	3.60 – 7.70 mg/dl
ALKALINE PHOSPHATASE (ALP)	68.0	142 – 353 mg/dl
TOTAL PROTIENS	7.08	0 – 39 mg/dl
ALBUMIN	3.09	3.8 – 5.4 mg/dl
SERUM GLOBULIN	3.0	2.1 – 3.5 mg/dl
CALCIUM	10.0	8.80 – 10.20
PHOSPHORUS	3.92	2.50 – 5.00
SERUM SODIUM NA+	140.0	135.00 – 155.00 mEq/Ltr
SERUM POTASIUM K+	4.09	3.60 – 5.50 mEq/Ltr
ICALCIUM	1.10	1.10 – 1.35 mmol/L
SERUM CHLORIDE CL+	101.3	98.00 – 110.00 mEq/Ltr

PAGE 1

Lab Technician

M.D., Pathology

Timing : 8.00 a.m. to 9.00 p.m. (Sunday 8.00 a.m. to 3.00 p.m.)

This Report is not valid for medico legal purpose

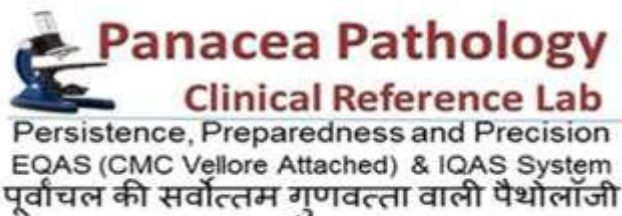
Note: These tests have technical limitations. Clinico-pathological interpretation is necessary. In case of any disparity test may be repeated immediately.

Address : 36/44 FK Kabir Nagar, Durgakund, Varanasi – 221005

Email: dramishra@gmail.com, drpallaviojha@gmail.com Website: panaceahospital.org

Facilities:
 All clinical Biomedical & Hematology Investigations
 including Bone Marrow Examination
 VPT, Podiascan & Complete Foot Care (First Time in Purvanchal)
 All Hormonal Investigation by Chemiluminescent Method
 Visceral Fat by (AB-140) Ambulatory BP Monitoring
 CGMS & Insulin Pump Available
 PFT, 2D-ECHO (Color Doppler), Holter, TMT, Cardiac-3 available
 VIA, VILI, Colposcopy available
 Special Endocrinological Investigation Protocols.

ISO 9001:2008 Certified
 Mobile: 9389994334, 9554572190, 9453837595



PATIENT NAME : POOJA PANDEY	AGE/GENDER : 26 YRS/FEMALE
REFD BY DR. : ARCO FEMI HEALTHCARE LTD.	RECEIVED DATE : 11-12-2022 (09:45 AM)
SAMPLE : BLOOD & URINE	REPORT DATE : 11-12-2022 (18:15 PM)

PATHOLOGY REPORT

LIPID PROFILE, SERUM

TEST	LAB TEST VALUES	NORMAL RANGE
BLOOD CHEMISTRY		
TOTAL CHOLESTEROL (SERUM)	145.0	Desirable:- < 200 mg/dl Borderline:- 200 – 239 mg/dl High:- > 240 mg/dl
TRIGLYCERIDES (SERUM)	135.0	35 – 170 mg/dl
HDL CHOLESTEROL (SERUM)	32.0	35.30 – 79.50 mg/dl
LDL CHOLESTEROL (SERUM)	86.0	< 130 mg/dl
VLDL	27.0	< 40 mg/dl
NON HDL	70.0	0.00 – 100.00 mg/dl
CHOLESTROL/HDL RATIO	4.53	< 3.0 Low Risk Ratio 3.0 – 5.0 Avg Risk < 5.0 High Risk
LDL/HDL RATIO	2.68	< 3 Ratio

BLOOD GROUP

TEST	LAB TEST VALUES
BLOOD GROUP ABO & RH FACTOR	
BLOOD GROUP	"A"
RH FACTOR	POSITIVE

GLYCOSYLATED HEMOGLOBIN (HBA1C)

TEST	LAB TEST VALUES	NORMAL RANGE
HBA1C	5.7	Normal : <5.97 % Good Control : 5.97 – 6.81% Fair Control : 6.81 – 7.65% Poor Control : >7.65%

THYROID PROFILE (T3, T4, TSH)

TEST	LAB TEST VALUES	NORMAL RANGE
THYROID FUNCTION TEST		
T3	1.21	0.60 – 1.81 ng/ml
T4	7.42	4.50 – 10.90 ug/dl
TSH	3.16	0.39 – 6.10 uIU/mL

PAGE 2

Lab Technician

M.D., Pathology

Timing : 8.00 a.m. to 9.00 p.m. (Sunday 8.00 a.m. to 3.00 p.m.)

This Report is not valid for medico legal purpose


Note: These tests have technical limitations. Clinico-pathological interpretation is necessary. In case of any disparity test may be repeated immediately.

Address : 36/44 FK Kabir Nagar, Durgakund, Varanasi – 221005

Email: dramishra@gmail.com, drpallaviojha@gmail.com Website: panaceahospital.org

Facilities:
 All clinical Biomedical & Hematology Investigations
 including Bone Marrow Examination
 VPT, Podiascan & Complete Foot Care (First Time in Purvanchal)
 All Hormonal Investigation by Chemiluminescent Method
 Visceral Fat by (AB-140) Ambulatory BP Monitoring
 CGMS & Insulin Pump Available
 PFT, 2D-ECHO (Color Doppler), Holter, TMT, Cardiac-3 available
 VIA, VILI, Colposcopy available
 Special Endocrinological Investigation Protocols.

ISO 9001:2008 Certified
 Mobile: 9389994334, 9554572190, 9453837595



Panacea Pathology
Clinical Reference Lab
 Persistence, Preparedness and Precision
 EQAS (CMC Vellore Attached) & IQAS System
 पूर्वांचल की सर्वोत्तम गुणवत्ता वाली पैथोलॉजी

PATIENT NAME : POOJA PANDEY	AGE/GENDER : 26 YRS/FEMALE
REFD BY DR. : ARCO FEMI HEALTHCARE LTD.	RECEIVED DATE : 11-12-2022 (09:45 AM)
SAMPLE : BLOOD & URINE	REPORT DATE : 11-12-2022 (18:15 PM)

PATHOLOGY REPORT

LIVER PROFILE TEST, SERUM

TEST	LAB TEST VALUES	NORMAL RANGE
BIO CHEMISTRY		
TOTAL BILIRUBIN	0.68	0.0 – 1.1 mg/dl
DIRECT BILIRUBIN	0.28	0.0 – 0.2 mg/dl
INDIRECT BILIRUBIN	0.40	< 0.90 mg/dl
SGOT (AST)	18.6	0 – 52 mg/dl
SGPT (ALT)	22.5	0 – 39 mg/dl
GGT (GYT)	26.0	< 55 U/L

URINE ROUTINE EXAMINATION

TEST	LAB TEST VALUES	NORMAL RANGE
PHYSICAL EXAMINATION		
QUANTITY	30	ML
COLOUR	STRAW	PALE YELLOW
APPEARANCE	CLEAR	CLEAR
SPECIFIC GRAVITY	1.010	1.01 – 1.03
PH	5.5	4.7 – 7.5
CHEMICAL EXAMINATION		
GLUCOSE	Not Detected	Not Detected
PROTEIN	NIL	Not Detected
MICROSCOPIC EXAMINATION		
PUS CELLS	1-2	0-5
RBC	Not Detected	Not Detected
EPITHELIAL CELLS	1-2	0-5
CASTS	Not Detected	Not Detected
CRYSTALS	Not Detected	Not Detected
BACTERIA	Not Detected	Not Detected

FASTING/RANDOM BLOOD SUGER

TEST	LAB TEST VALUES	NORMAL RANGE
FBS/RBS		
FASTING BLOOD SUGER	94.0	110-125 mg/dl
RANDOM BLOOD SUGER	110.0	125-140 mg/dl

----- End of Report -----

Lab Technician

M.D., Pathology

Timing : 8.00 a.m. to 9.00 p.m. (Sunday 8.00 a.m. to 3.00 p.m.)

This Report is not valid for medico legal purpose

Note: These tests have technical limitations. Clinico-pathological interpretation is necessary. In case of any disparity test may be repeated immediately.

Address : 36/44 FK Kabir Nagar, Durgakund, Varanasi – 221005

Email: dramishra@gmail.com, drpallaviojha@gmail.com Website: panaceahospital.org



11
SHRIST

PANACEA HOSPITAL

B 36/44 F.K KABIR NAGAR, DURGAKUND
TOLLFREE NO-18001233070.
Whatsapp No - 8795832852
www.piire.org



OP Slip

Print Date : 10-Dec-2022 10:02AM



UHID No	:- UD-22230002875	OP No	:- OP-22230010799	OP Date	:- 10 Dec 2022 10:02AM
Patient Name	:- Mrs POOJA PANDEY	Age/Sex	:- 26 Y/Female	Mobile No	:- 9934637463
Husband	:-	Department	:- DIABETES, ENDOCRINOLOGY & METABOLIC PHYSICIAN		
Pay Type	:- Cash	Consultant	:- Dr ASHUTOSH MISHRA (MD(MEDICINE), IMS, BHU)		
Token No	:- NOR. - 12	Paid/Bal	:- 0.00 / 500.00		
Patient Type	:- Normal				
Address	:- CHIITUPUR, varanasi				

BP :- 110/70
height :- 154
Weight (kg) :- 65.5
BMI :- 27.6

SpO₂ - 99
PR - 90
NC - 34
WC - 88

Rx
c/o
Dry cough x 7 days
Dry sleeplessness

Past H/O - No
Allergy H/O - (+nt)
Seasonal variation (+nt)
Family H/O - No
Menses H/O - Regular
Medicine H/O -

Kevo Arbu PR (200)

Rx. Tab. Doxolin (400)

Tab. Montom-As 1/2

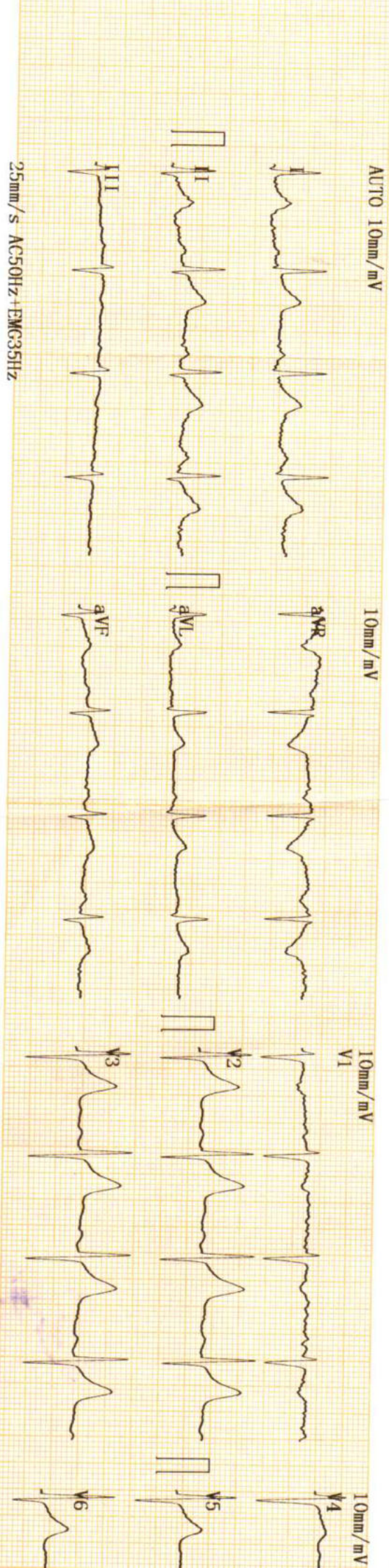
Tab. Ezolent-pls 1/2

Advent (60) A/D x 10

(SUN 17/10)

RAA Dmuth

Printed By : Mr NITIN YADAV
Created By : Mr NITIN YADAV



AUTO 10mm/mV

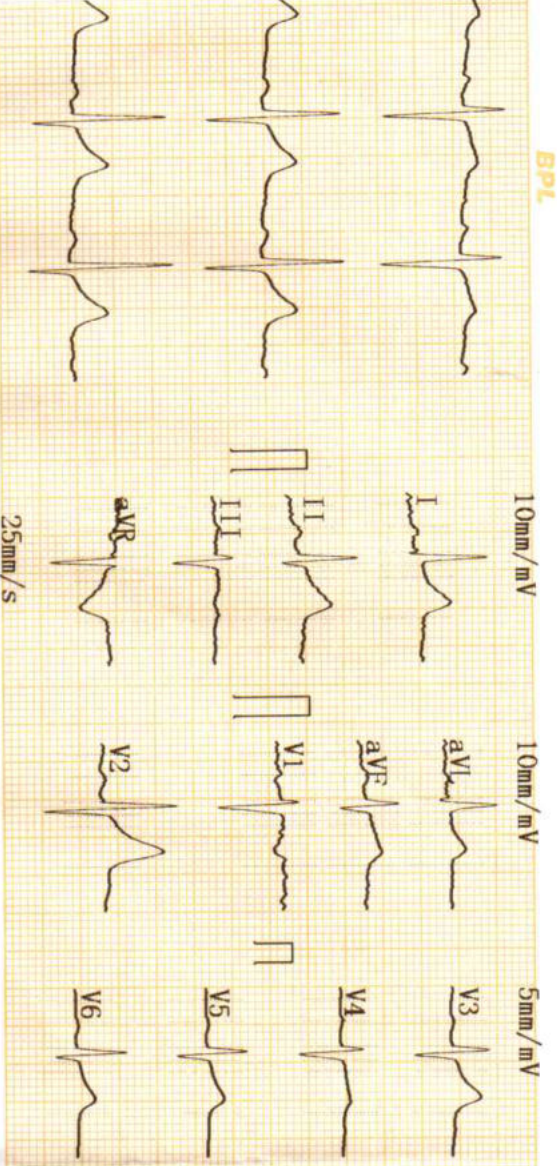
10mm/mV

10mm/mV
V1

10mm/mV
V4

25mm/s AC50Hz+EMG35Hz

CARDIART



BpL

10mm/mV

10mm/mV

5mm/mV

2022-12-10 10:35

ID

Name

Sex

Height

SYS

DIA

: 77

: 257

: 120

: 73

: 218

: 354/401

: -152.7/6.3/33.0

: 1.05/0.82

: 1.87

Age

Weight

<< Conclusions >>

Longitudinal left axis deviation;

I AV block;

Report need physician confirm

DR. PALLAVI MISHRA
 MBBS, MD (GENERAL MEDICINE)
 MCI Reg. No. 52033

Physician



PANACEA HOSPITAL

A shelter for many hearts A Home for many lives

(An ISO 9001:2008 Certified Organisation)

Lab Attached with CMC Vellore Under EQAS Scheme

Name	MR.POOJA PANDEY	Sex /Age	26/F	Date	10/12/2022
Ref. by	Dr.Pallavi Mishra(MD)	BSA - m ²		Echo window	fair

Echo - Cardiography

MITRAL VALVE Doppler	AML - normal morphology MV Flow - E - 0.7 A-0.5 E/A=1.35	PML - normal morphology MVA - 3.0 cm ² Mitral Regurgitation - No
TRICUSPID VALVE Doppler	Normal TV Flow -No	Tricuspid Regurgitation -No
PULMONARY VALVE Doppler	Normal PV Flow -No	Pulmonary Regurgitation - No
AORTIC VALVE Doppler	Trileaflet-No AV Flow - no	Aortic Regurgitation - no
MEASUREMENT	Aorta - 28.0 (20-38) mm IVS ed - 7.4 (6 -12) mm LVID ed - 48.8 (35 - 55) mm LVPW ed - 16.0 (6 -12) mm OA - 7 (> 5) mm	LA - 30.0 (24-32) mm IVS es -18.8 (6 - 12) mm LVID es - 29.7 (24 - 40) mm LVPW es - 13.7 (6 -12) mm EPSS - 5 (< 9) mm

CONCLUSION

All cardiac chamber dimensions are WNL
No valvular abnormalities
Good LV systolic function present Modified Simpson's method (4C, 2C) (LVEF-68%)
No diastolic dysfunction present (E/A = 1.35) by tissue Doppler (E/e'=680)
No RWMA
No pericardial effusion
Intact IAS / IV
No PAH
No intra cardiac mass /thrombus /vegetation

IMPRESSION

Normal Echocardiogram

Niraj Mishra
Physician Assistant
(PIIRE)

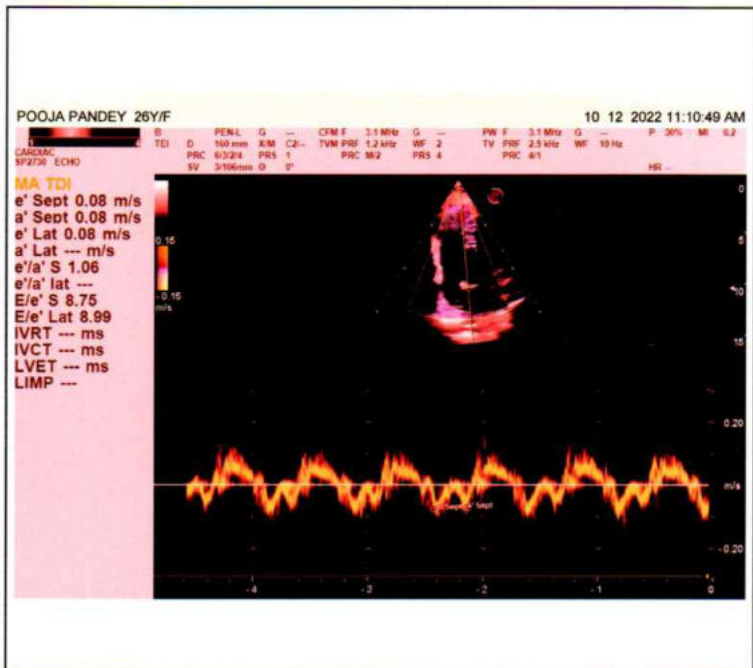
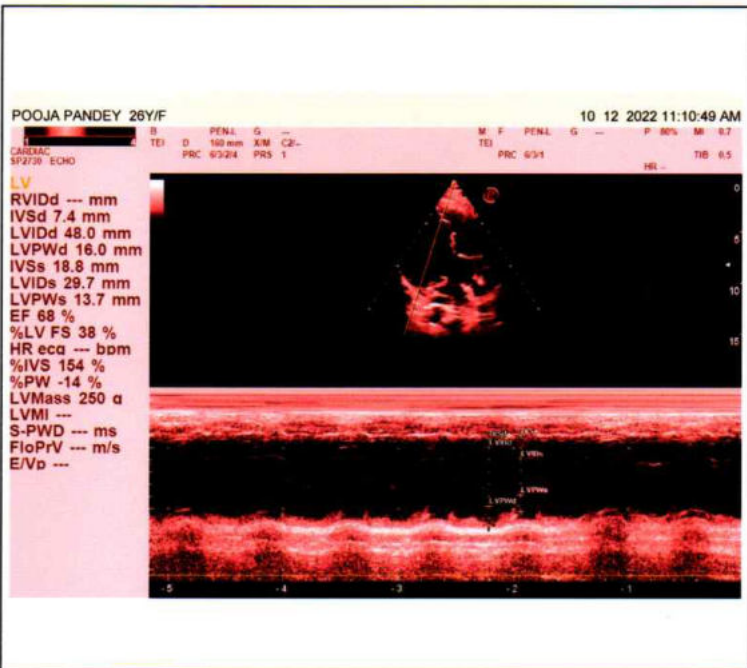
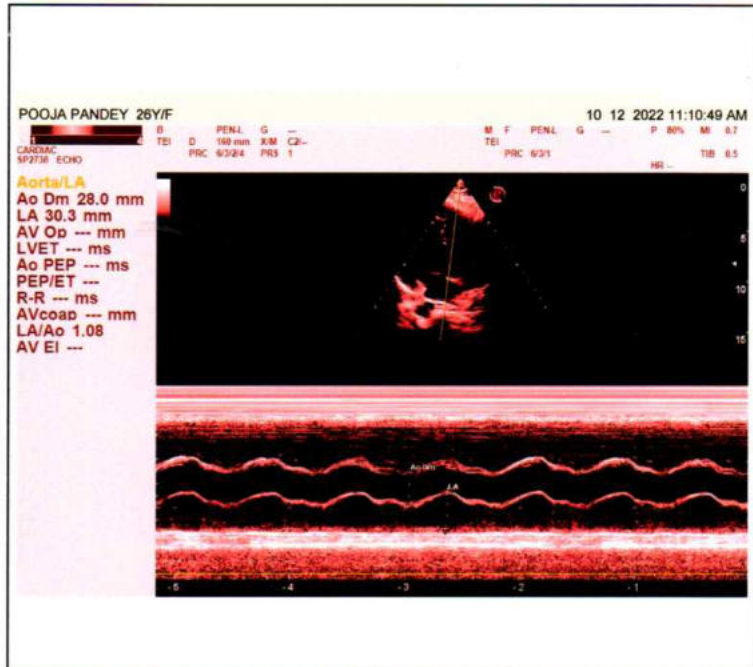
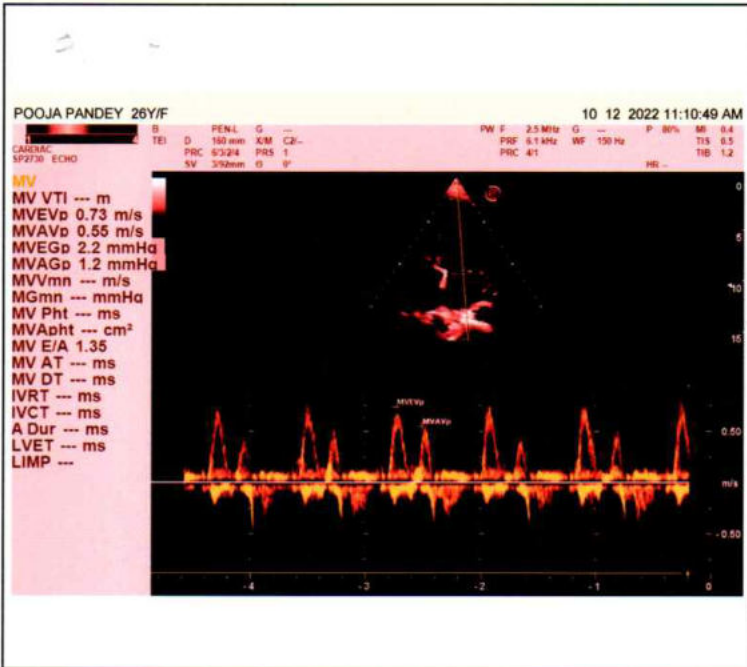
Pallavi
DR. PALLAVI MISHRA
S.S.MD (GENERAL MEDICINE)
MCI Reg.No. 52033

Dr. Pallavi Mishra
MBBS, MD (MED) Lucknow
Echocardiography Specialist, MIAE
Non-invasive cardiologist
Women Cardiologist
Diabetocardiologist

Address : Kabir Nagar (Near Sanjay Shiksha Niketan), Durgakund, Varanasi

Mobile : 9554572190 / 9453837595 / Recpn. 9389994334

E-mail : dramishra@gmail.com, drpallaviojha@gmail.com, Website: www.piire.org





PANACEA HOSPITAL

A shelter for many hearts A Home for many lives

(An ISO 9001:2008 Certified Organisation)

Lab Attached with CMC Vellore Under EQAS Scheme

NAME: MRS. POOJA PANDEY

AGE/SEX: 26 YRS / FEMALE

REF BY: DR. ASHUTOSH MISHRA (MD)

DATE: 10 /12/2022

ULTRA SOUND FOR ABDOMAN REPORT

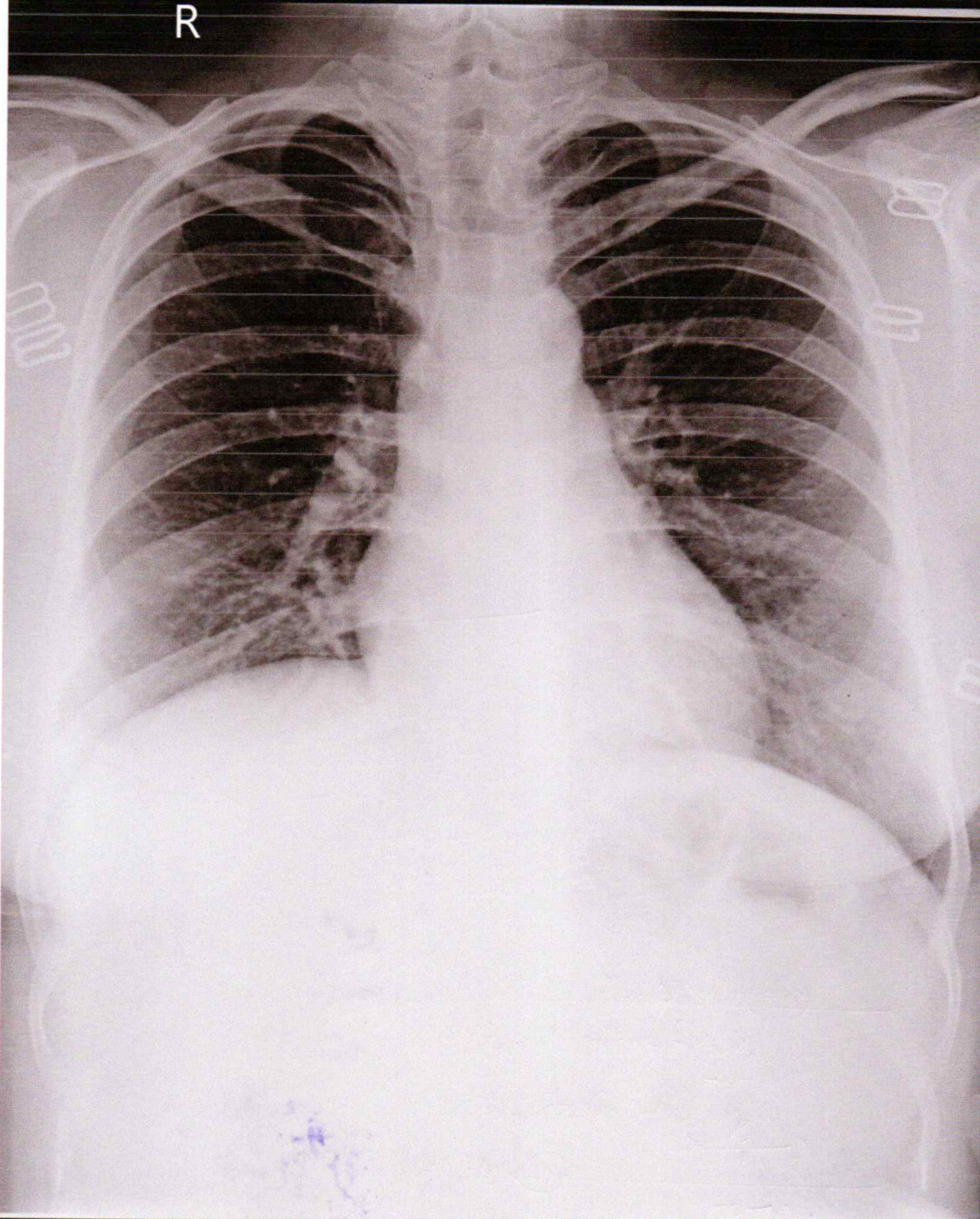
- Liver:** Normal in shape and size(10.6cm) and shows smooth and regular margin.
No diffuse/focal lesion seen.
- Gall bladder** Normal distended with normal wall thickness and echo-free lumen.
- CBD** Visualized part normal in course & caliber.
- Pancreas:** Normal in size, shape & echogenicity.
Margins are smooth & regular.
No diffuse/ focal lesion seen. Pancreatic tail obscured.
- Spleen:** Normal in size(10.6 cm) shape & echogenicity.
Margins are smooth & regular. No diffuse / focal lesion seen.
Splenic vessels at hilum is normal.
- Kidney:** Right kidney: 9.7 X 4.4cm
Left kidney: 10.2 X 5.0 cm
Normal cortical echogenicity with well maintained Cortical-medullary differentiation.
Pelvicalyceal system normal.
No calculus/mass lesion seen.
No hydronephrosis/ hydroureter seen.

Address : Kabir Nagar (Near Sanjay Shiksha Niketan), Durgakund, Varanasi

Mobile : 9554572190 / 9453837595 / Recpn. 9389994334

E-mail : dramishra@gmail.com, drpallaviojha@gmail.com, Website: www.piire.org

R



POOJA PANDEY 26Y/F 2875 O CHEST P.A. 10-Dec-22 10:41 AM

PANACEA HOSPITAL, KABIR NAGAR, DURGAKUND, VARANASI



Call Now - 1800-123-3070

PANACEA HOSPITAL

A shelter for many hearts A Home for many lives

(An ISO 9001:2008 Certified Organisation)

Lab Attached with CMC Vellore Under EQAS Scheme

NAME: MRS.POOJA PANDEY

AGE/SEX: 26 YRS / FEMALE

REF BY: DR.ASHUTOSH MISHRA(MD)

DATE: 10/12/2022

X-RAY CHEST PA

BOTH LUNG FIELDS AND PLEURAE:

Both lungs show normal bronchovascular pattern.

Right & left hila are normal

No focal mass or calcification is seen

There is no evidence of any fluid in the both the pleural cavities.

Both domes of diaphragms are normal in position.

MEDIASTINUM:

Trachea is central in position.

Cardiac silhouette is of normal size and configuration.

No evidence of pericardial effusion.

No significant lymphadenopathy is seen.

Visualized skeleton is normal.

NO SIGNIFICANT RADIOGRAPHIC ABNORMALITY

DR. ALPANA PATHAK
MD, RADIOLOGY
REG. NO. 45455
REPORTED BY

DR. ALPANA PATHAK
MBBS (HONS, GOLD MEDALIST) PMCH, PATNA
MD RADIODIAGNOSIS (GOLD MEDALIST) IMS BHU
EX-SR, IMS BHU, VARANASI

Address : Kabir Nagar (Near Sanjay Shiksha Niketan), Durgakund, Varanasi

Mobile : 9554572190 / 9453837595 / Recpn. 9389994334

E-mail : dramishra@gmail.com, drpallaviojha@gmail.com, Website: www.piire.org