

Linked Medians Report

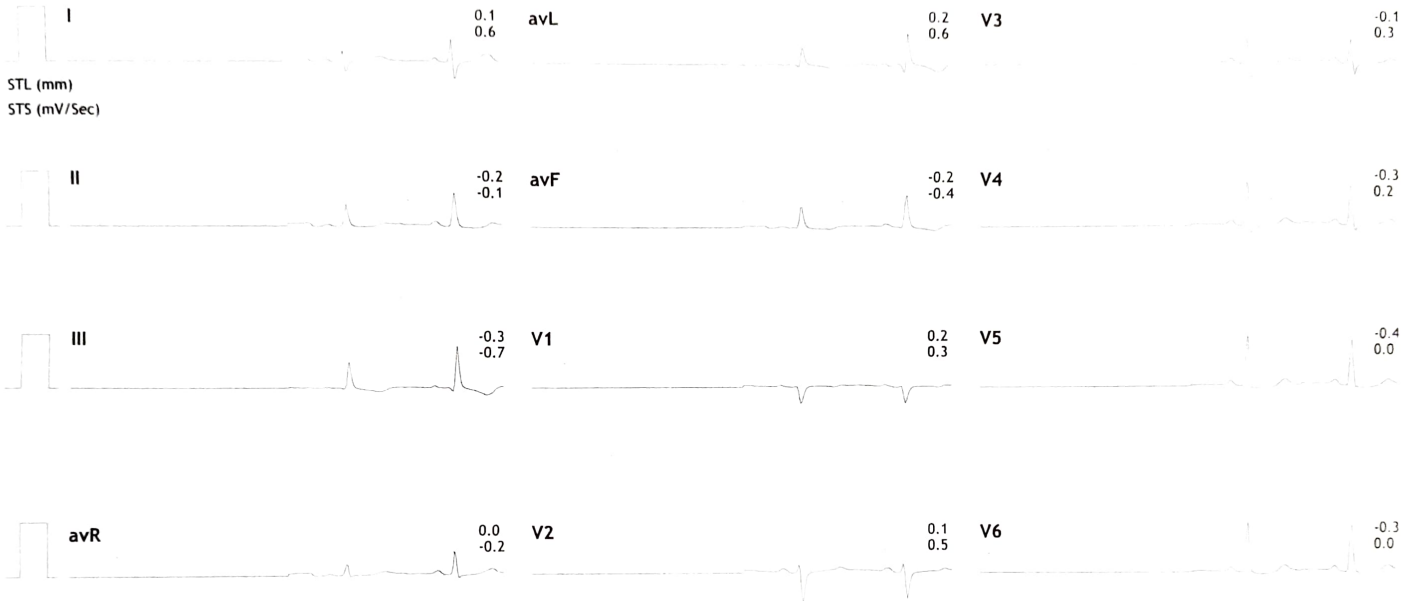199130/PIYUSHA HUKERHR: 79 bpm
47 Yrs/Female METS: 1.0
68 Kg/158 Cms BP: ---/---
Date: 14-Mar-2022 01:50:06 PM

Hardev Health Care LLP Mulund

MPHR: 45% of 173 BRUCE
Speed: 0.0 mph (1.0-100)Hz
Grade: 0.0%


Ex Time 00:34
BLC :On
Notch :On

PRE_EX
10.0 mm/mV
25 mm/Sec.



III Raw Rhythm





6L Frontal

199130/PIYUSHA HUKERHR: 79 bpm
47 Yrs/Female METS: 1.0
68 Kg/158 Cms BP: ---/---
Date: 14-Mar-2022 01:50:06 PM

Hardev Health Care LLP
Mulund

MPHR: 45% of 173
Speed: 0.0 mph
Grade: 0.0%

Raw ECG
BRUCE
(1.0-100)Hz

Ex Time 00:36
BLC : On
Notch : On

PRE_EX
10.0 mm/mV
25 mm/Sec.





Hardev Health Care

12 Lead + Comparison

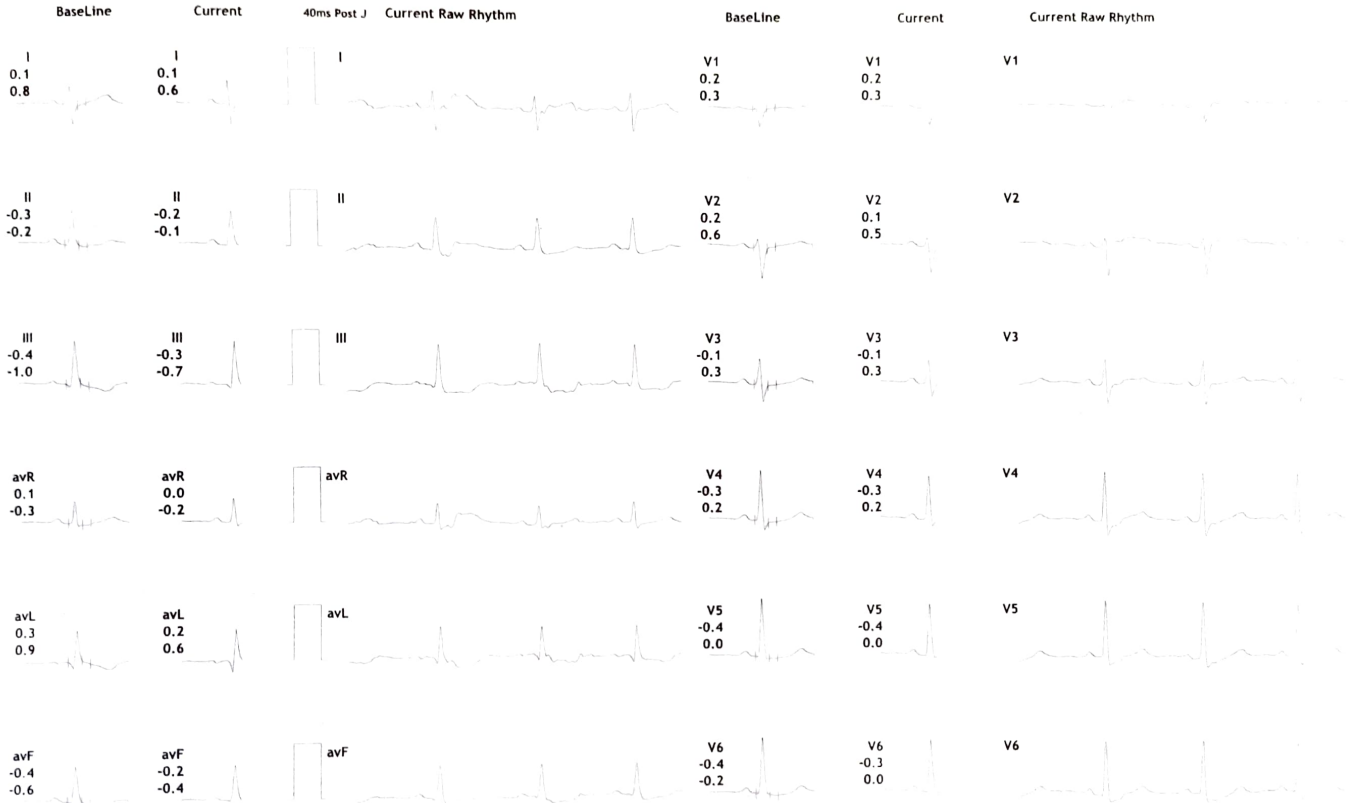
199130/PIYUSHA HUKERHR: 79 bpm
47 Yrs/Female METS: 1.0
68 Kg/158 Cms BP: ---/---
Date: 14-Mar-2022 01:50:06 PM

Hardev Health Care LLP Mulund

MPHR: 45% of 173
Speed: 0.0 mph
Grade: 0.0%
Raw ECG
BRUCE
(1.0-100)Hz

Ex Time 00:34
BLC : On
Notch : On

PRE_EX
10.0 mm/mV
25 mm/Sec





Hardev Health Care

6L PreCordial

Hardev Health Care LLP
Mulund

199130/PIYUSHI HUKERHR: 79 bpm
47 Yrs/Female METS: 1.0
68 Kg/158 Cms BP: / /
Date: 14-Mar-2022 01:50:06 PM

MPHR: 45% of 173
Speed: 0.0 mph
Grade: 0.0%

Raw ECG
BRUCE
(1.0-100)Hz

Ex Time 00:36
BLC : On
Notch : On

PRE_EX
10.0 mm/mV
25 mm/Sec.





Hardev Health Care

12L Rhythm

199130/PIYUSHA HUKERHR: 79 bpm
47 Yrs/Female METS: 1.0
68 Kg/158 Cms BP: ---/---
Date: 14-Mar-2022 01:50:06 PM


Hardev Health Care LLP Mulund

MPCR: 45% of 173
Speed: 0.0 mph
Grade: 0.0%

Raw ECG
BRUCE
(1.0-100)Hz

Ex Time 00:36
BLC :On
Notch :On

PRE_EX
10.0 mm/mV
25 mm/Sec.





Hardev Health Care

Average

Hardev Health Care LLP


Mulund

199130/PIYUSHA HUKERI 47 Yrs/Female 68 Kg/158 Cms


Date: 14-Mar-2022 01:50:06 PM

I II III avR avL avF V1 V2 V3 V4 V5 V6


Supine




Standing




HV




ExStart



Stage 1



Stage 2





Comparison Report (Supine Vs Supine)

Hardev Health Care LLP

Mulund

199130/PIYUHA HUKERI 47 Yrs/Female 68 Kg/158 Cms

Protocol: BRUCE
Date: 17 Mar 2022 01:50:06 PM

Supine :	PhTime 0:34	StageTime 0:01	0.0 mph	0.0%	1.0 METs	79 bpm	---/---	@73ms Post J
Supine :	PhTime: 0:34	StageTime: 0:01	0.0 mph	0.0%	5.5 METs	79 bpm	---/---	@73ms Post J

Supine

Supine

Supine

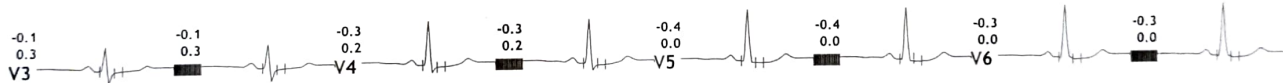
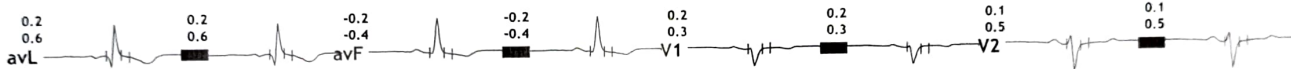
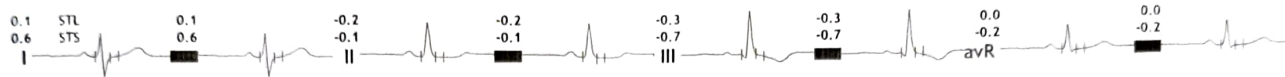
Supine

Supine

Supine

Supine

Supine

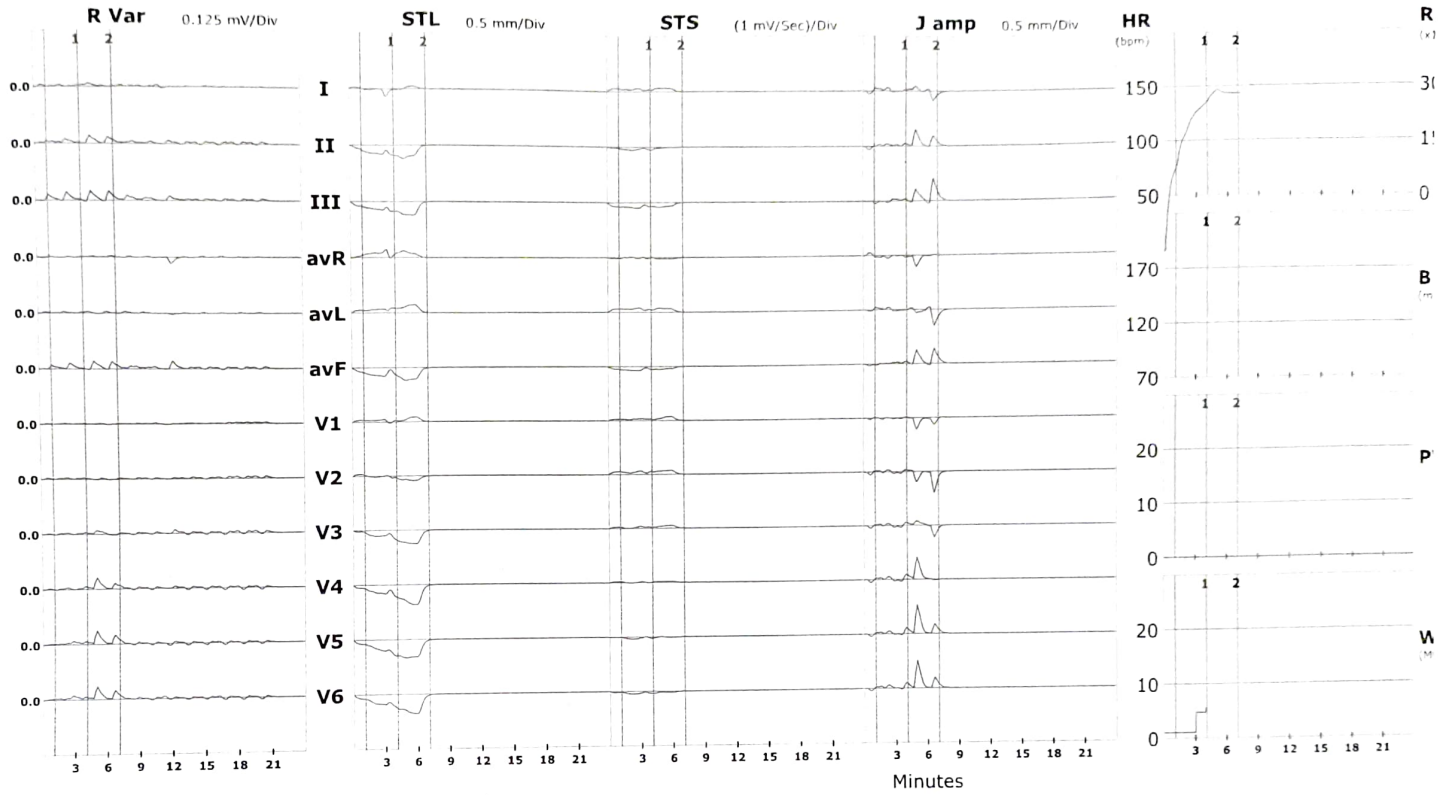




Trends

Hardev Health Care LLP
Mulund

199130/PIYUSHA HUKERI
47 Yrs/Female
68 Kg/158 Cms
Date: 14-Mar-2022 01:50:06 PM





ST Summary

Hardev Health Care LLP
Mulund

199130/PIYUSHA HUKERI 47 Yrs/Female 68 Kg/158 Cms
Date: 14-Mar-2022 01:50:06 PM

Protocol : BRUCE

		I	II	III	avR	avL	avF	V1	V2	V3	V4	V5	V6
STL (mm) 40 mSecs Post J	Supine	0.1	-0.2	-0.3	0.0	0.2	-0.2	0.2	0.1	-0.1	-0.3	-0.4	-0.3
	Standing	0.1	-0.2	-0.3	0.0	0.2	-0.2	0.2	0.1	-0.1	-0.3	-0.4	-0.3
	HV	0.1	-0.3	-0.4	0.1	0.3	-0.4	0.2	0.2	-0.1	-0.3	-0.4	-0.4
	ExStart	0.1	-0.3	-0.4	0.1	0.3	-0.4	0.2	0.3	-0.1	-0.2	-0.4	-0.3
	Stage 1	-0.1	-1.0	-0.9	0.5	0.4	-1.0	0.2	0.0	-0.8	-1.3	-1.5	-1.4
	Stage 2	0.0	0.0	0.0	0.0	0.0	0.0	0.0	0.0	0.0	0.0	0.0	0.0
	STS mV/Sec.	Supine	0.6	-0.1	-0.7	-0.2	0.6	-0.4	0.3	0.5	0.3	0.2	0.0
Standing	0.6	-0.1	-0.7	-0.2	0.6	-0.4	0.3	0.5	0.3	0.2	0.0	0.0	
HV	0.8	-0.2	-1.0	-0.3	0.9	-0.6	0.3	0.6	0.3	0.2	0.0	-0.2	
ExStart	0.5	-0.2	-0.7	-0.1	0.6	-0.4	0.3	0.6	0.3	0.2	0.0	-0.1	
Stage 1	0.3	-0.7	-1.1	0.2	0.7	-0.9	0.7	0.8	0.4	0.1	-0.2	-0.5	
Stage 2	0.0	0.0	0.0	0.0	0.0	0.0	0.0	0.0	0.0	0.0	0.0	0.0	
STI μ Vs	Supine	0.0	-0.9	-0.7	0.5	0.5	-0.8	0.8	0.1	-1.4	-1.8	-2.3	-1.8
	Standing	0.0	-0.9	-0.7	0.5	0.5	-0.8	0.8	0.1	-1.4	-1.8	-2.3	-1.8
	HV	-0.9	-2.0	-1.1	1.5	0.2	-1.6	0.8	0.5	-1.0	-2.2	-2.3	-2.3
	ExStart	0.0	-1.9	-1.8	1.0	0.9	-1.8	1.0	0.7	-0.9	-1.8	-2.3	-2.1
	Stage 1	-1.4	-4.5	-3.2	2.9	0.9	-3.8	0.5	-1.1	-5.4	-7.4	-8.7	-7.3
	Stage 2	0.0	0.0	0.0	0.0	0.0	0.0	0.0	0.0	0.0	0.0	0.0	0.0



Linked Median Report

Hardev Health Care LLP

Mulund

199130/PIYUSHA HUKERI 47 Yrs/Female 68 Kg/158 Cms

Date: 14-Mar-2022 01:50:06 PM

Time (Min.)	HR (Bpm)	PR Int (mS)	QRS Wid (mS)	QRS Axis (Deg.)	QTC (mS)	P(µV) (Max)	R(µV) (Max)	S(µV) (Min)	T(µV) (Max)	Min. J (µV)	Leads for (J & PJ)	Min. Post (µV)	JRR Var (%)	PVC (Counts)	Missed Beats (Counts)
00 : 30	77	137	77	95	350	56	520	-284	79	-14	V6	-43	8.84	-	-
01 : 00	80	140	77	90	449	53	507	-279	72	-41	V5	-41	5.15	-	-
01 : 30	106	167	113	90	508	67	501	-287	80	-41	III	-71	7.39	-	-
02 : 00	112	160	73	96	444	82	498	-308	-84	-59	V6	-85	3.21	-	-
02 : 30	125	133	90	98	433	86	484	-320	-91	-83	V5	-100	2.05	-	-
03 : 00	129	130	90	100	423	93	476	-318	-95	-106	V5	-114	3.50	-	-
03 : 30	132	97	77	180	390	121	466	-322	-114	-212	I	-161	2.90	-	-
04 : 00	137	113	90	103	406	102	488	-334	-260	-177	V5	-167	3.01	-	-
04 : 30	144	103	110	105	408	94	494	-354	-123	-136	V6	-163	3.08	-	-
05 : 00	149	110	90	106	418	113	474	-344	-113	-171	V6	-177	2.48	-	-
05 : 30	149	110	90	106	418	113	474	-344	-113	-171	V6	-177	3.20	-	-
06 : 00	149	110	90	106	418	113	474	-344	-113	-171	V6	-177	0.00	-	-
06 : 30	149	110	90	106	418	113	474	-344	-113	-171	V6	-177	0.00	-	-
07 : 00	149	110	90	106	418	113	474	-344	-113	-171	V6	-177	0.00	-	-

Total Disclosure

Hardev Health Care LLP

Mulund

199130/PIYUSHA HUKERI 47 Yrs/Female 68 Kg/158 Cms

Date: 14-Mar-2022 01:50:06 PM



avL

00:00

00:46

01:33

02:19

03:06

03:52

04:39

05:26

06:12

06:59

Dr. Ameya S. Chavan (MD, DM Cardiology)

PERIODIC MEDICAL EXAMINATION REPORT

Name	: Piyusha D Hukeri	Test Code	: AHC-25
Emp Code	:	Test Date	: 12-03-2022
Age	: 47 Years	Sex	: Female
Contact No	: 0	Dep. Name	: --
Company Name	: Arcofemi Health Care Ltd.	Job Nature	: --


PHYSIOLOGICAL DATA

Height : 158	Cms	Weight : 68	Kgs	Expected Weight : 55	Kgs
B.P : 100/70	mmHg	PULSE : 76	/min	Body Mass Index : 27.24	



MEDICAL HISTORY

<input checked="" type="checkbox"/> NO Frequent Cold	<input checked="" type="checkbox"/> NO Frequent Sneezing	<input checked="" type="checkbox"/> NO Joint Pain
<input checked="" type="checkbox"/> NO Shortness of breath	<input checked="" type="checkbox"/> NO Frequent Headache	<input checked="" type="checkbox"/> NO Chronic Cough
<input checked="" type="checkbox"/> NO Backache	<input checked="" type="checkbox"/> NO Intestinal trouble	<input checked="" type="checkbox"/> NO Ear Discharge
<input checked="" type="checkbox"/> NO Impaired Hearing	<input checked="" type="checkbox"/> NO Chest Pain Or Pressure	<input checked="" type="checkbox"/> NO Diabetes
<input checked="" type="checkbox"/> NO Recent Loss Of Weight	<input checked="" type="checkbox"/> NO Allergy To Drugs / Chemical	<input checked="" type="checkbox"/> NO High BP



PAST OPERATIVE HISTORY

<input checked="" type="checkbox"/> NO Hydrocele	<input checked="" type="checkbox"/> NO Renal Calculus	<input checked="" type="checkbox"/> NO Duodenal Ulcer
<input checked="" type="checkbox"/> NO Hernia	<input checked="" type="checkbox"/> NO Tonsillitis	<input checked="" type="checkbox"/> NO Appendicitis
<input checked="" type="checkbox"/> NO Cataract	<input checked="" type="checkbox"/> NO DNS	<input checked="" type="checkbox"/> NO Piles



OTHER PAST OPERATIVE HISTORY : No

OTHER COMPLAINTS : No

PAST HISTORY : No

FAMILY HISTORY : No

ADDICTIONS : Smoke : No | Drinks : No | Diet : Veg | Pan : No | Tobacco : No | Gutka : No

VISION

WITHOUT GLASSES

NEAR R L

FAR R L

WITH GLASSES

NEAR R L

FAR R L

COLOUR BLINDNESS



VISION REMARK : NORMAL WITH GLASS

Medical Test Date : 12-03-2022 Test Code : AHC-25
Name : Piyusha D Hukeri Emp Code :

CLINICAL EXAMINATION

GENERAL & DERMATOLOGY EXAMINATION

General Condition : Good	Nails : NAD
Oedema Feet : Absent	Skin : Normal
Temperature : Normal	Deformities : None

CARDIOVASCULAR

Heart Sound : Normal

ABDOMEN

Liver : Not Palpable	Spleen : Not Palpable
	Other Masses : NAD

GENITO URINARY

Ext. Genitalia : Normal	Discharge : No
	Hydrocele : Normal

LYMPHATIC AND ENDOCRINE

Lymph Nodes : Not Palpable	Thyroid : Not Palpable
----------------------------	------------------------

MUSCULO SKETAL

Bones : NAD	Joints : NAD
	Posture Spine : Normal

NERVOUS SYSTEM

Sensory System : Normal	Reflexes : Normal
	Motor System : Normal

EYE CHECKUP

Conjunctiva : Normal	Cornea : Normal
Pupil : Normal	Fundus : NAD

E.C.G : Within Normal Limits

PFT : NA

ADVICE : Normal Health.

RESULT : This is to certify that the employee is free from contagious and obnoxious disease including skin & Tuberculosis. Hence found to be fit for the respective job.

*NAD - No Abnormality Ditected
NA - Not Applicable

Dr. Rahul S. Deshpande
M.B.B.S. Ortho (Mumbai)
J.B.S. D. 3d. No
HARDEV HEALTHCARE ARBE

Rahul Deshpande
Dr. Rahul Deshpande
M.B.B.S., ORTHO, A.F.I.H. (C.L.I)
Industrial Health Consultant

Medical Test Date : 12-03-2022

Test Code : AHC-25

Name : Piyusha D Hukeri

Emp Code :

BLOOD GROUP & RH FACTOR

Blood Group : 'O' Rh Typing : 'Positive'


EXAMINATION OF HEMATOLOGY

NAME	RESULT	UNITS	NORMAL RANGE
Haemoglobin	14.1	mg/dl	12 - 15
RBC	5.16	mill/cumm	4.3 - 5.3
PCV / HCT	42.2	%	36 - 46
MCV	81.8*	fl	83 - 101
MCH	27.3	pj	27 - 32
MCHC	33.4	g/dl	31.5 - 34.5
RDW	14.8*	%	11.6 - 14
Total WBC Count	7500	mill/cumm	4000 - 10000
Neutrophils	54	%	40 - 80
Lymphocytes	43*	%	20 - 40
Monocytes	02	%	2 - 10
Eosinophils	01	%	1 - 6
Basophils	00	%	0 - 1
Platelet Count	285000	per cu. mm.	150000 - 410000
ESR	09	mm	0 - 20
DIABETIC PROFILE	RESULT	UNITS	NORMAL RANGE
HbA1c	7.98*	mgdl	4 - 6.5
Blood sugar fasting	88	mg/dl	70 - 120
Blood sugar post lunch	75*	mg/dl	80 - 160
KIDNEY FUNCTION TEST			
S. creatinine	0.87	mg/dl	0.5 - 1.5
Uric acid	4.6	mg/dl	4.5 - 6.7
Urea	26.98	mg/dl	14 - 40
Blood urea nitrogen	12.6	mg/dl	6 - 21
Bun/Creatinine Ratio	31.0*	--NA--	10 - 30

EXAMINATION OF URINE

PHYSICAL EXAMINATION		CHEMICAL EXAMINATION		MICROSCOPIC EXAMINATION	
Quantity	: 20ml	Proteins	: Absent	Erythrocytes	: Absent
Color	: Pale Yellow	Glucose	: Absent	Epithelial Cell	: 4-5 hpf
Appearance	: Clear	Specific Gravity	: 1.030	Pus Cell	: 6-7 hpf
Deposite	: Absent	Ketones	: Absent	Bacteria	: Not seen
Urobilinogen	: Absent	Occult Blood	: Negative	Casts	: Not seen
		Nitrite	: Absent	Crystals	: Not seen
				A. Material	: Not seen


N.B. Above investigation have their limitations and should be interpreted by referring physician accordingly. Solitary Rediological/Pathological and other investigations do not confirm the final diagnosis of disease.



Medical Test Date : 12-03-2022 Test Code : AHC-25
 Name : Piyusha D Hukeri Emp No :

BIOCHEMICAL EXAMINATION

LIPID PROFILE	RESULT	UNITS	NORMAL RANGE
Total cholesterol	168.0	mg/dl	130 - 200
Hdl cholesterol	49	mg/dl	40 - 60
Ldl cholesterol	92.2*	mg/dl	95 - 145
VLDL	26.8	mg/dL	2 - 30
LDL/HDL RATIO	1.88	--NA--	0.5 - 3.5
Triglycerides	134.9	mg/dl	70 - 140
Cholesterol/HDL Ratio	3.10	mg/dl	0 - 4.5
LIVER FUNCTIN TEST			
Total bilirubin	0.6	mg/dl	0.2 - 1.2
Direct bilirubin	0.4	mg/dl	0 - 0.5
Indirect bilirubin	0.2	mg/dl	0 - 0.3
SGOT	28.95	/ml	0 - 40
SGPT	22.76	/ml	0 - 40
Protein	6.4	g/dl	6 - 8
Albumin	4.2	g/dl	3.5 - 5.5
S. Globulin	2.2*	g/dl	2.5 - 3.5
Alkaline phosphatase	96.67	u/l	50 - 150
GGT	26.7	u/l	10 - 50



Dr. Surya N. Tripathi
 Consulting Pathologist
 Reg No - 2000/04/1994

TEST DATE : 12-03-2022
REF. BY : HARDEV HEALTH CARE
EMP CODE :
NAME : Piyusha D Hukeri
TEST ASKED: TSH

TEST NAME	TECHNOLOGY	VALUE	UNITS	REFERENCE RANGE
T3	C.L.I.A.	138.0	ng/dl	60 - 200
T4	C.L.I.A.	9.3	µg/dl	4.5 - 12
Thyroid Stimulating Hormone (TSH)	C.L.I.A.	3.08	µIU/mL	0.3 - 5.5

Comments : ***

Please correlate with clinical conditions.

Method :

TSH - ULTRA SENSITIVE SANDWICH CHEMI LUMINESCENT IMMUNO ASSAY

--End Of Report--

Sample Collected on (SCT) : 12-03-2022
Sample Received on (SRT) : 13.03.2022
Report Released on (RRT) : 14 March 2022
Sample Type : SERUM
Labcode : 110741711/AND45
Test Code : AHC-25

Dr.Durgaprasad N Agrawal MD Dr.Caesar Sengupta MD

Medical Test Date : 12-03-2022

Test Code : AHC-25

Name : Piyusha D Hukeri

Emp Code :

X-RAY OF THE CHEST P.A. VIEW

There is no mediastinal shift.

The heart and aorta appears to be normal.

No pleural abnormality is noted.

The bony thorax is normal.

IMPRESSION : Normal Study**SUGGEST** : Clinico pathological correlation & sos f/u.

Please note that imaging conclusion need to be correlated with clinical findings & other investigations for final diagnosis.



Dr. N.P. CHHALLANI.
MBBS., DMRE, AFIH
TMC/MOH/PNDT/234

Medical Test Date : 12-03-2022

Test Code : AHC-25

Name : Piyusha D Hukeri

Emp Code :

3ch x 4 + (1ch)

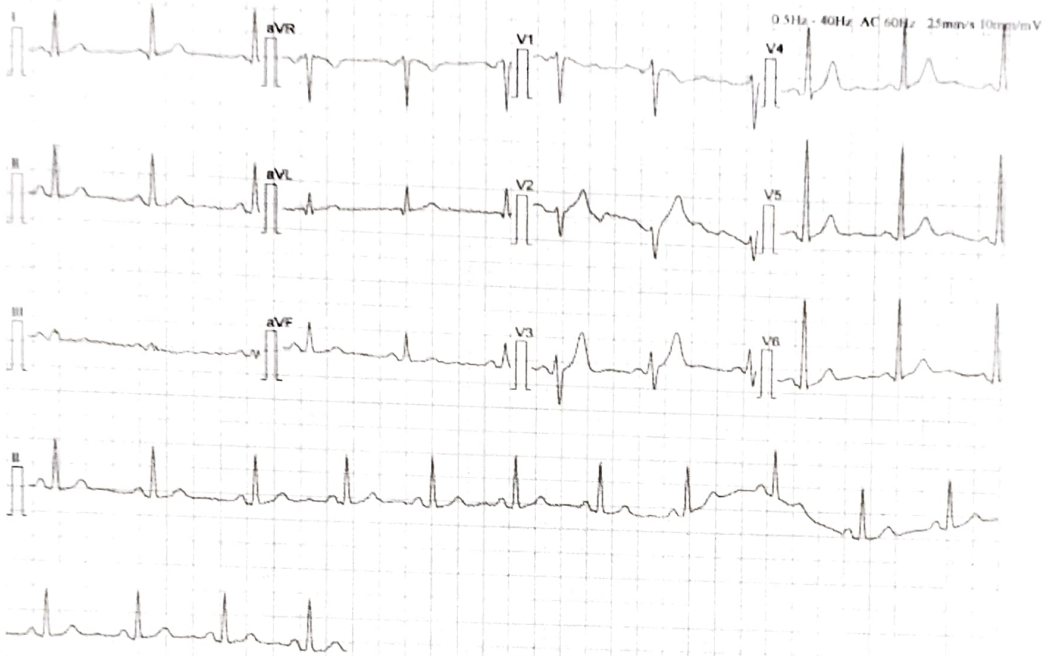Name: AHC-25

ID: 20210221004632

Sex: Female

Date of Birth: 1974/05/03 (47yrs)

Hospital
Department



[Measurement]				
HR: 88 bpm	P	Width: 76 ms	RVS/SV1: 1.856/-0.983 mV	
P Axis: 67 deg	PR	Interval: 114 ms	RV5+SV1: 2.839 mV	
QRS Axis: 41 deg	QRS	Duration: 88 ms		
T Axis: 29 deg	QT/QTc	Interval: 304/368 ms		

[Analysis Result]

-- normal ECG --

Sinus rhythm

Reporter


Notice: All the parameters and conclusions should be confirmed by doctor

Dr. Kailash Changani
M.D.(Med)
Reg No - 58574

Date : 12-03-2022

FITNESS CERTIFICATE

This is to certify that **Ms. Piyusha D Hukeri** Emp. No. age **47** Yrs. has undergone the medical examination with us on **12-03-2022**. based on examination and investigation results she is free from infection / Contagious disease including skin & Tuberculosis for which diagnostic tests has been carried out and She is medically fit to continue her duties.


Dr. Rahul S. Deshmande
(Mumbai)


Authorised Medical Practitioner

DR. RAJAT BALIGA

MBBS, M. D. (Radiology), D. N. B.

CONSULTANT RADIOLOGIST & SONOLOGIST

RADIANCE SONOGRAPHY CENTRE



RADIANCE DIAGNOSTIC CENTRE

19, Shree Mangal Karyalay,
Opp. Shree Nagar Vidya Mandir, Shree Nagar,
Wagle Estate, Thane - 400 604 • Tel.: 7208542237

.... Experience the Difference

3, Durvankur, Near Panch Parmeshwar Mandir,
Kishan Nagar 1, Wagle Estate, Thane - 400 604.
Tel.: 7208542237

NAME : PIYUSHA HUKERI	AGE/SEX : 47Y/F
REF BY : HARDEV HOSPITAL	DATE: 12/03/2022

REAL TIME ABDOMINAL ULTRASOUND REPORT

LIVER :

Normal size liver with normal parenchymal echo pattern. No evidence of any solid or cystic intra- hepatic lesion is noted. The portal and hepatic veins appear normal. No evidence of any dilated intra or extra hepatic biliary radicals noted. CBD is not dilated.

GALL-BLADDER:

The physiologically dilated gall bladder is visualized and appears normal. No evidence of any gall stones noted. No e/o wall thickening or peri-cholecystic free fluid.

PANCREAS :

It is normal in size and reflectivity. No evidence of peripancreatic collection. MPD is not dilated.

SPLEEN :

The spleen is normal in size and shows normal parenchymal echo pattern.

KIDNEYS :

Both kidneys are normal in size No evidence of any renal mass, hydronephrosis or renal calculi noted. Cortico-medullary differentiation is maintained on both sides. Bilateral renal parenchymal thickness appears normal. No e/o renal scarring
The right kidney measures 9.5 x 4.2 cms.
The left kidney measures 9.8 x 4.0 cms.

No evidence of ascites or significant para aortic lymphadenopathy. Bowel loops are not dilated .

Anatomically normal urinary bladder. No e/o calculus or wall thickening or debris seen.


Normal anteverted uterus measuring 7.3 x 3.2 x 3.2 cms. Myometrial echotexture is smooth and homogenous.. The endometrium is homogenous and measures 5 mm. There is fundal uterine wall subserosal fibroid seen measuring 12.3 x 7.4 x 11.0 cms

The right ovary shows a simple cyst of size 3.8 x 3.3 cms. No e/o septations or solid components seen within cyst

The left ovary measures 2.5 x 2.2 cms.

CONCLUSION :

- Uterine subserosal fibroid
- Right simple ovarian cyst


DR. RAJAT BALIGA
MBBS, MD (Radiology), DNB

DR. RAJAT BALIGA

MBBS, M. D. (Radiology), D. N. B.

CONSULTANT RADIOLOGIST & SONOLOGIST

RADIANCE SONOGRAPHY CENTRE



RADIANCE DIAGNOSTIC CENTRE

19, Shree Mangal Karyalay,
Opp. Shree Nagar Vidya Mandir, Shree Nagar,
Wagle Estate, Thane - 400 604 • Tel.: 7208542237

..... Experience the Difference

3, Durvankur, Near Panch Parmeshwar Mandir,
Kishan Nagar I, Wagle Estate, Thane - 400 604.
Tel.: 7208542237

NAME : PIYUSHA HUKERI 2	AGE/SEX : 47Y/F
REF BY : HARDEV HOSPITAL	DATE:12/03/2022

SONOGRAPHY BOTH BREAST

Both breasts reveal predominance of glandular tissue.

No focal solid or cystic mass lesion is seen. Breast axillary tail appears normal.

Few dilated ducts largest measuring 3.6 mm in AP diameter seen over 4 o clock and 6 o clock position of left breast in peri-areolar region . No e/o intraductal lesion is noted.

No e/o any abscess or radiological signs of mastitis.

No e/o any skin thickening .

Both axillae are normal. No e/o significant axillary lymphadenopathy.

CONCLUSION:

Few dilated ducts seen over 4 o clock and 6 o clock position of left breast in peri-areolar region . No e/o intraductal lesion is noted.

BIRADS 2 (benign)

DR. RAJAT BALIGA
MBBS, MD (Radiology), DNB