




Mediwheel


 भारत सरकार  
 Government of India


 आधार



अक्षय शेकर पूजारी

Akshay Shekar Poojari

जन्म तारीख / DOB : 26/06/1991

पुरुष / MALE

01/12/2012

5788 5584 6151

माझे आधार, माझी ओळख


L Jhu

DR. PLUS HEALTHCARE CENTRE  
 NATHANI HEIGHTS, BAYROAD  
 42, MUMBAI CENTRAL (EAST)

(30/M)

DR. HARI CHHABLA  
 M.B.B.S., F.C.C.P. (RESP. MEDICINE) PGDIPHM, I  
 FELLOW INTENSIVE CARE  
 MMC REG. NO. - 91702

5788 5584 6151



पत्ता: 9/301 शान्ति गार्डन सेक्टर 4, सुर्या  
 श्यामपूजा सेक्टर समोर, मीरा-भायंदर, ठाणे,  
 महाराष्ट्र, 401107

Address: 9/301 shanti garden Sector 4, opp  
 surya shopping center, Mira-Bhayander,  
 Thane, Maharashtra, 401107

भारतीय विशिष्ट ओळख प्राधिकरण  
 Unique Identification Authority of India

1947 help@uidai.gov.in www.uidai.gov.in



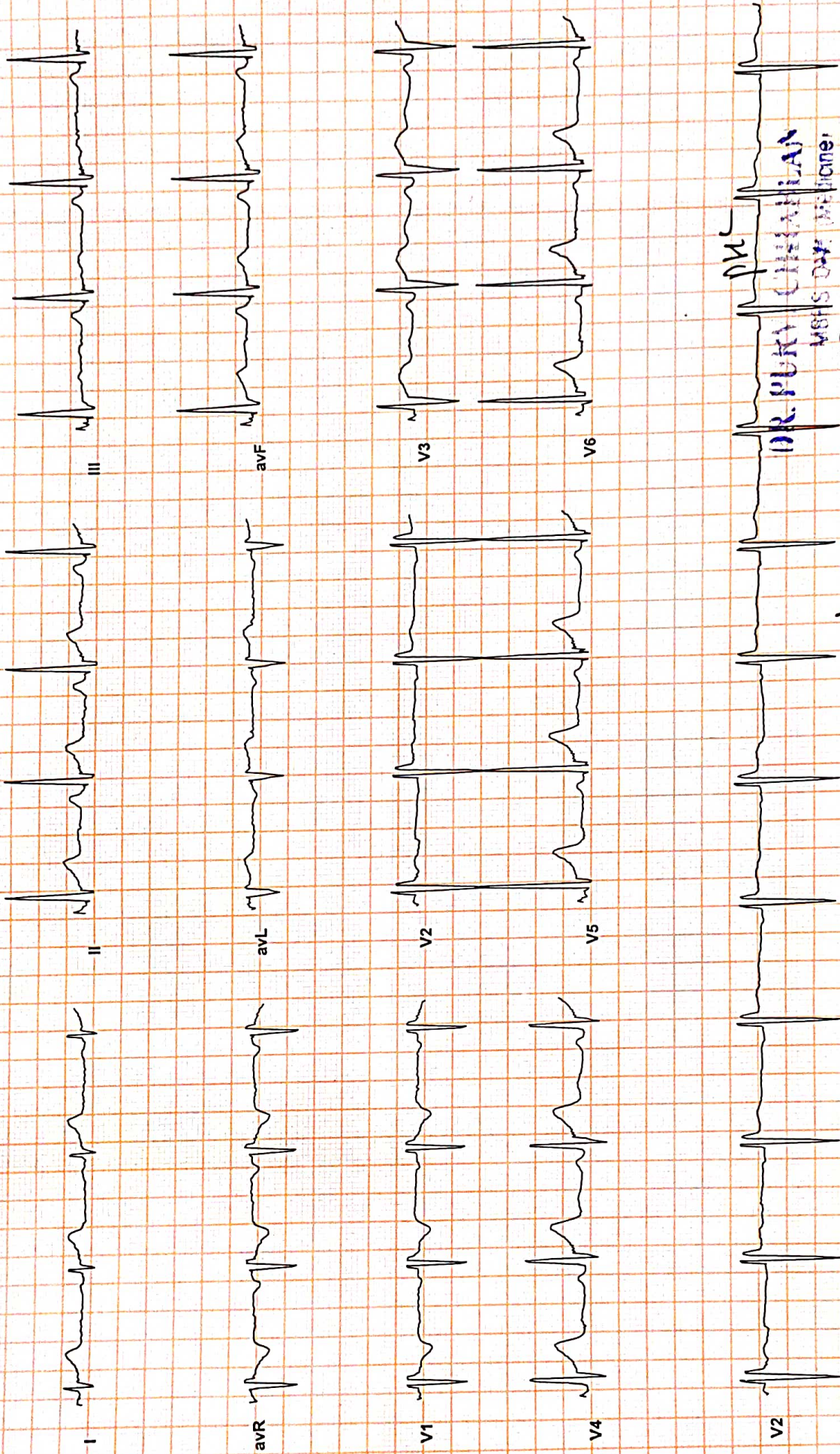
# DR PLUS HEALTHCARE CENTRE- MUMBAI CENTRAL

1898 / AKSHAY POOJARI / 30 Yrs / M

Heart Rate : 71 bpm / Tested On : 11-Jun-22 15:29:14 / HF 0.05 Hz - LF 100 Hz / Notch 50 Hz / Sn 1.00 Cm/mV / Sw 25 mm/s

/ Refd By.: DR. HARI CHHABLANI

# ECG



DR. PURVI CHHABLANI

MBBS Doctor  
onsite Physician and Intensive

Reg No 77896  
Reported By: DR. PURVI CHHABLANI

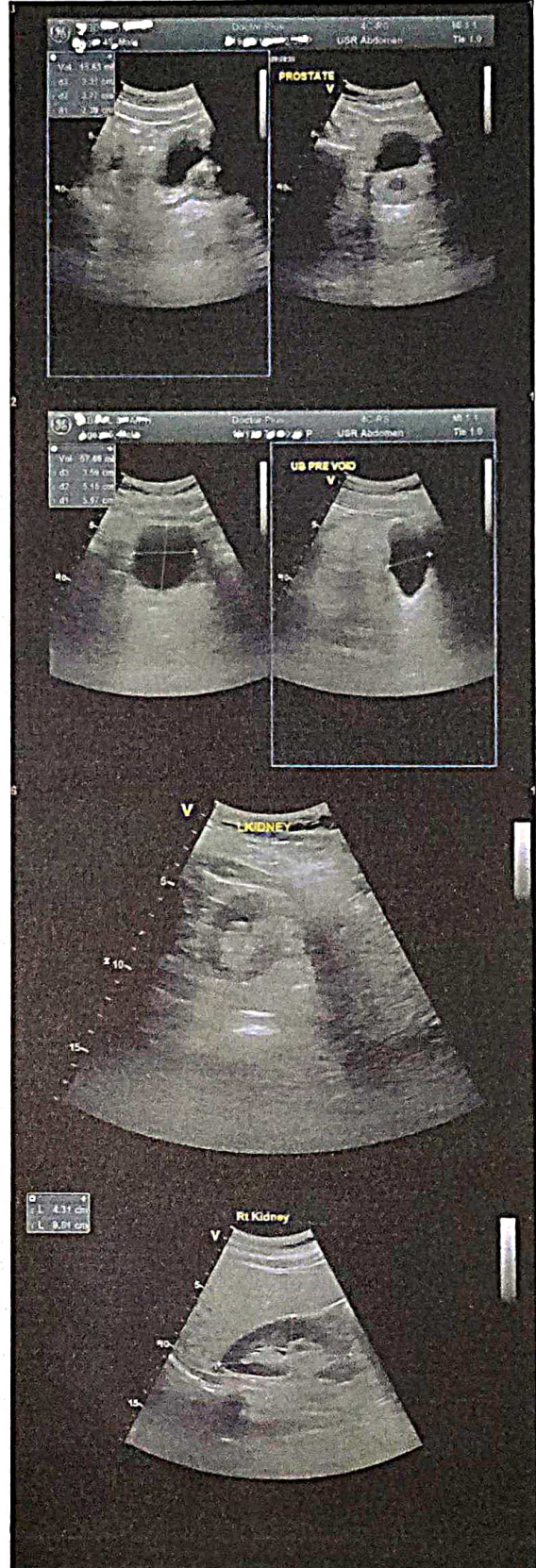
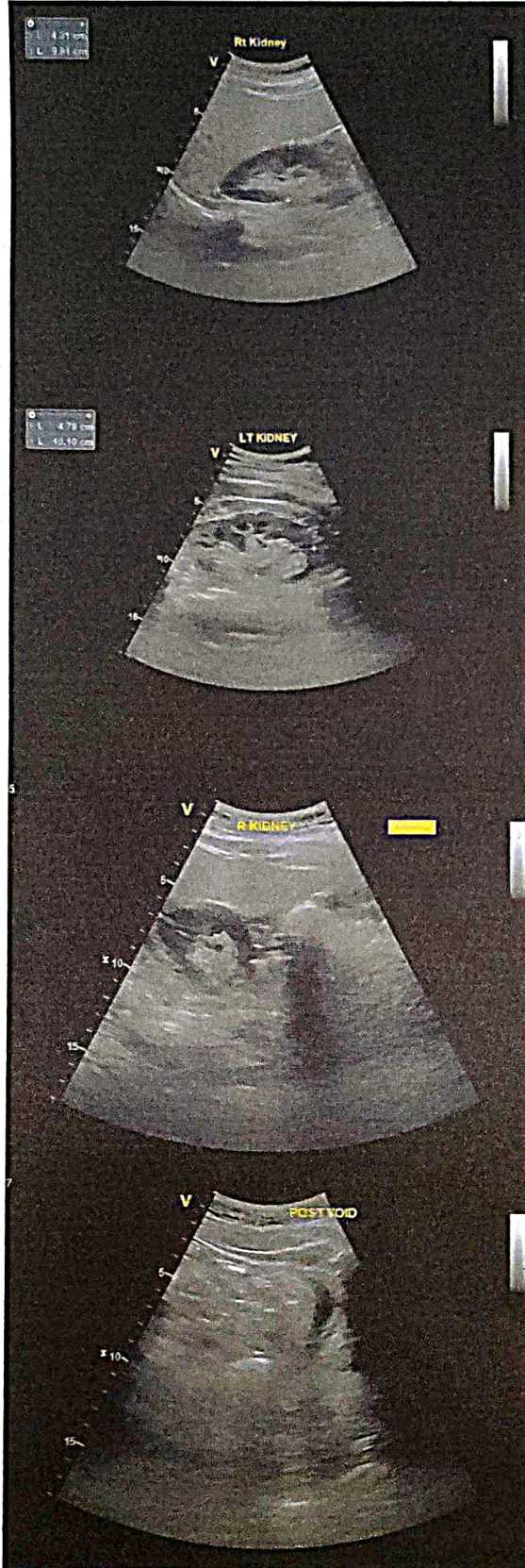WNL



Name AKSHAY POOJARI

Sex Male

Age 30







# Dr-Plus Healthcare Centre

NATHANI HEIGHTS, B-Wing, Shop No. 42, Ground Floor, Opp. Mumbai Central Station (East), Mumbai - 400 008.

Patient Name	:	AKSHAY POOJARI	Sex:	Male
Doctor's Name	:	SELF	Age:	30 Years
Date	:	11/06/2022		

## ULTRASONOGRAPHY OF THE ABDOMEN AND THE PELVIS:

The relevant sonographic findings include the following:

### HEPATOBIILIARY APPARATUS

The liver is normal in size and echogenicity. No obvious focal parenchymal lesion is seen. Extrahepatic biliary radicals are not dilated. The portal vein and the common bile duct are normal.

### GALL BLADDER

The gall bladder is adequately distended. The wall thickness is normal. No echogenic contents are noted in its lumen. There is no pericholecystic collection noted.

### PANCREAS

The pancreas shows normal echogenicity and size. No focal or diffuse lesions are noted. No evidence of calcification is noted.

### SPLEEN

The spleen appears normal in size and echogenicity. No focal or diffuse lesions are noted. No evidence of calcification is noted.

### KIDNEYS

Right Kidney measure: 11.0 x 5.3 cm, Left kidney measure: 10.9 x 5.6 cm  
Both the kidneys appear normal in size, shape and echogenicity. Both the pelvicalyceal system is normal and both corticomedullary differentiations are well maintained. There is no obvious focal or diffuse lesion noted.  
No evidence of any calculus seen in either kidney.

### URINARY BLADDER

The urinary bladder shows anechoic contents. Its wall thickness appears normal. No significant post void residue.

### PROSTATE

The Prostate appears normal and shows a normal echogenicity.

No evidence of calcification is seen.

There is no obvious evidence of abdominal or pelvic lymphadenopathy or ascites noted.

**IMPRESSION: No significant abnormality is detected.**

  
Dr. VICTOR X. COUTINHO  
MBBS, DMRE  
Radio-Sonologist

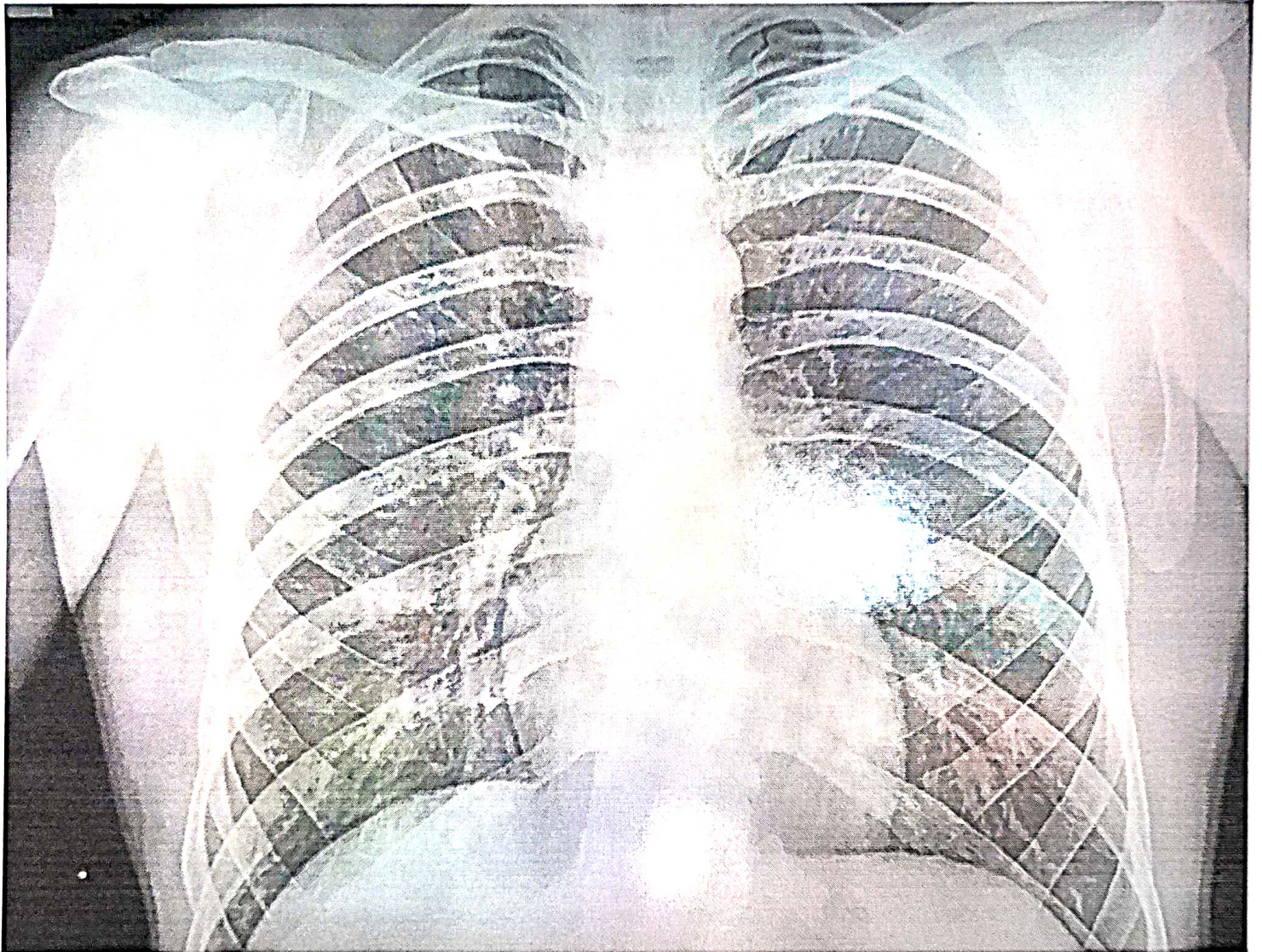




AKSHAY POOJARI

30/M

11/06/22



DR. PLUS HEALTHCARE CENTRE  
KATHANI HEIGHTS, B-WING,  
MUMBAI CENTRAL (EAST)





# Dr-Plus Healthcare Centre

NATHANI HEIGHTS, B-Wing, Shop No. 42, Ground Floor, Opp. Mumbai Central Station (East), Mumbai - 400 008.

Patient's Name : AKSHAY POOJARI

Report Date : 11/06/2022

Referred By : SELF

Age : 30 Years

Sex : MALE

## X- RAY CHEST

BOTH THE LUNG FIELED ARE CLEAR.

THE HILAR SHADOWS APPEAR NORMAL.

THE COSTO-PHRENIC ANGELS ARE CLEAR.

THE CARDIAC SHADOWS APPEAR NORMAL.

THE TRACHEAL IS CENTRAL IN POSITION.

THE BONY CAGE APPEARS NORMAL.

DR. A. J. MAZUMDAR

MD. DMRE, MDRD

DR. A. J. MAZUMDAR  
MD. DMRE, MDRD  
42, NATHANI HEIGHTS, B-WING  
OPP. MUMBAI CENTRAL STATION (EAST)  
MUMBAI - 400 008



# Dr-Plus Healthcare Centre

NATHANI HEIGHTS, B-Wing, Shop No. 42, Ground Floor, Opp. Mumbai Central Station (East), Mumbai - 400 008.

AKSHAY POOJARI

30/M

11/06/2022

Full Name

Life to be assured:

## HAEMOGRAM

### Normal Range

1.	Red Blood Cell Count	4.5	[M : 4.5 – 5.6/ F : 3.5 – 5.5/cu.mm]
2.	Hb%	15.3	[M: 14-18 / F : 11-16%]
3.	Hematocrit	45.9	[M : 40-53 / F : 30-47 %]
4.	Indices:		
(a)	MCV(Mean Corpuscular Volume)	89.6	[79-101 cu.mi.]
(b)	MCH(Mean Corpuscular Hb)	30.8	[27-32 pg]
(c)	MCHC(Mean Corpuscular Hb Concentration)	34.6	[32-38%]
5.	Morphology		
	Macrocytes : --	Microcytes: --	Hypochromia: --
	Piokilocytosis: --	Anisocytosis: --	
6.	Target cells: --		
	Spherocytes: --	Elliptocytes: --	
7.	<b>TOTAL W.B.C.Count</b>	7,500	{4000-1100/cu.mm}
Differential Count			
a)	Neutrophils :	60	[45 -70%] c) Eosinophils: 05 [01 - 06%]
b)	Lymphocytes :	30	[20 - 45%] d) Monocytes: 05 [00 - 08%]
e)	Basophils :	00	[00 - 01%]
8.	<b>Platelets</b> :2.99		1.5-4.5 Lacks/cu.mm
9.	<b>Erythrocyte Sedimentation Rate:-14</b>		20 mm at end of 1 hour Method : Westergrens

## ROUTINE URINE EXAMINATION (RUA)

### 1. Physical Examination:

(i)	Colour :	PALE YELLOW	(ii)	Sediment:	CLEAR
(iii)	Transparency:	CLEAR	(iv)	Reaction:	ACIDIC
(v)	Specific gravity	1.015			

### 2. Chemical Examination:

(i)	Protein :	NIL	(ii)	Sugar:	NIL
(iii)	Bile salt:	NIL	(iv)	Bile pigment:	NIL

### 3. Microscopic Examination:

(i)	Red Blood Cells:	ABSENT	(ii)	Epithelial Cells:	2 TO 3/ HPF
(iii)	Crystals:	ABSENT	(iv)	Pus Cells:	2 TO 3/HPF
(v)	Casts:	ABSENT	(vi)	Deposits:	ABSENT
(vii)	Bacteria's :	ABSENT			

DR. RAKESH PATKAR  
M.D., D.N.B. (Pathology)  
Reg. No. 2013/05/1660





# Dr-Plus Healthcare Centre

NATHANI HEIGHTS, B-Wing, Shop No. 42, Ground Floor, Opp. Mumbai Central Station (East), Mumbai - 400 008.

Full Name  
Life to be assured:

AKSHAY POOJARI

30/M

11/06/2022

	Type of Test	Actual Reading	Normal Range
1	Fasting Blood Sugar	80.6	70-100 mg%
2	PPBS	110.9	110 TO 140 mg%
3	Total Cholesterol	167.1	120-200 mg%
4	VERY LOW DENSITY LEVEL(VLDL)	12.4	10-30 mg/dl
5	High Density Lipid (HDL)	42.3	40-60 mg%
6	Low Density Lipid (LDL)	112.4	<u>Upto 150</u>
7	S. Triglycerides	115.1	50-150 mg%
8	CHOL/HDL	3.9	Upto 5
9	HDL/LDL	0.3	
10	S. Creatinine	0.8	0.5-1.2 mg%
11	Blood Urea Nitrogen (BUN)	14.6	7-21 mg%
12	BUN/CREAT RATIO	18.2	
13	S. Proteins	6.6	6.0-7.9 mg%
14	(a) Albumin	3.6	3.5-5.5 mg%
15	(b) Globulin	3.0	2.0-3.5 mg%
16	A/G RATIO	1.2	
17	S. Bilirubin	1.0	0.3-1.3mg%
18	(a) Direct	0.6	0.0-0.8 mg%
19	(b) Indirect	0.4	0.0-0.5 mg%
20	SGOT (AST)	22.0	05-34 IU
21	SGPT (ALT)	34.5	05-40 IU
22	GGTP (GGT)	40.2	05-50 IU
23	SGOT/SGPT	0.6	
24	HBA1C	5.5	UPTO 6.5
25	S. Alkaline Phosphatase	99.9	30-115 IU
26	T3	166.4	80-180ng/dl
27	T4	5.8	4.6-12 ug/dl
28	TSH	2.5	0.4-4.0 mIU/L
29	SERUM URIC ACID	6.6	2.5-7.2mg/dl
30	URINE SUGAR PP	ABSENT	
31	URINE SUGAR FASTING	ABSENT	
32	BLOOD GROUP	" O POSITIVE "	

DR. RAKESH PATKAR  
M.D., D.N.B. (Pathology)  
Reg. No. 2013/05/1660





**Dr. Hari Chhablani**

Cardiometabolic Physician & Intensivist  
M.B.B.S., F.C.C.P. (RESP. MED.), PGDHHM,  
PGDMLS, FELLOW INTENSIVE CARE MED.

ATTACHED TO: Wockhardt Hospital • Saifee Hospital • Apollo Spectra Hospital

NATHANI HEIGHTS, B-Wing, Shop No. 42, Ground Floor, Opp. Mumbai Central Station (East),  
Mumbai - 400 008. • Cell : 98206 46163 • E : drharichhablani@gmail.com

## PHYSICIAN REPORT

DATE : 11/06/2022

NAME : AKSHAY POOJARI 30/M

PRESENTING COMPLAINS : NIL

TREATMENT : NIL

PAST HISTORY : COVID POSITIVE MAY - 2021 .  
BOTH EYE LASIK DONE .

FAMILY HISTORY: NOT SIGNIFICANT

HABITS : NIL.

DENTAL EXAMINATION: NAD

HT.- 175 CM. WT.-63 Kg.

P: 72/MIN., REGULAR

BP: 120/84

RS: CLEAR CVS: S1,S2 REGULAR

PA: SOFT

CNS: CLINICALLY NAD

EYE EXAMINATION : NEAR VISION -B/E 86 , DISTANT VISION -BE-- 6/12 , COLOUR VISION - NORMAL

LABS: ATTACHED

ECG: WNL

CHEST X-RAY :WNL

SONOGRAPHY : ATTACHED

2-D- ECHO : ATTACHED

IMPRESSION : FIT ON CLINICAL MEDICAL EXAMINATION .

  
DR.HARI CHHABLANI

DR. HARI CHHABLANI  
M.B.B.S., F.C.C.P. (RESP. MED.), PGDHHM, PGDMLS  
FELLOW INTENSIVE CARE  
MMC REG. NO. - 91702