

Dr. Ajay jaiswal

MBBS, MRSH

Dr. Abhitesh Kumar

MBBS, DMRD

Dr. A. P. Singh

MD, DMRD

**ANUPAM M.R.I  
& C.T. SCAN CENTRE**  
Equipped With 16 Slice High Speed Ct Scanner

Name	: Madhu Lata	Age/ Sex	: Y/F
Part scanned	: X-Ray Chest PA View	Date/Time	: 23.08.2021
Refd.by Dr.	: Parashar Hospital Muz.	ID No-	: 1506

X - RAY REPORT

*Lung fields appear clear on both side.*

*Both CP angles is clear.*

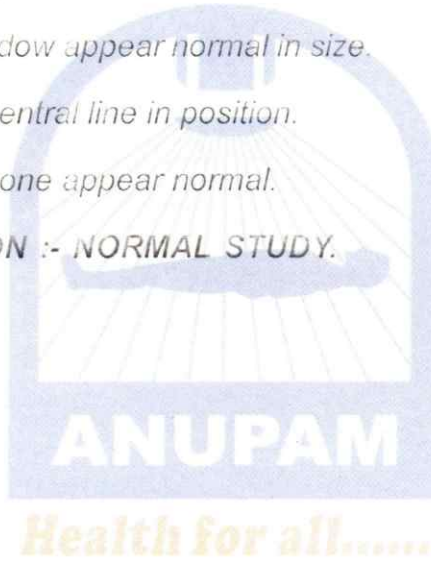
*Both hila appear normal.*

*Cardiac shadow appear normal in size.*

*Trachea is central line in position.*

*Visualized bone appear normal.*

**IMPRESSION :- NORMAL STUDY.**



*Please correlate clinically.*

On request

Not valid for medico-legal purpose.

  
Dr. Abhitesh Kumar  
MBBS, DMRD.  
Radiologist.





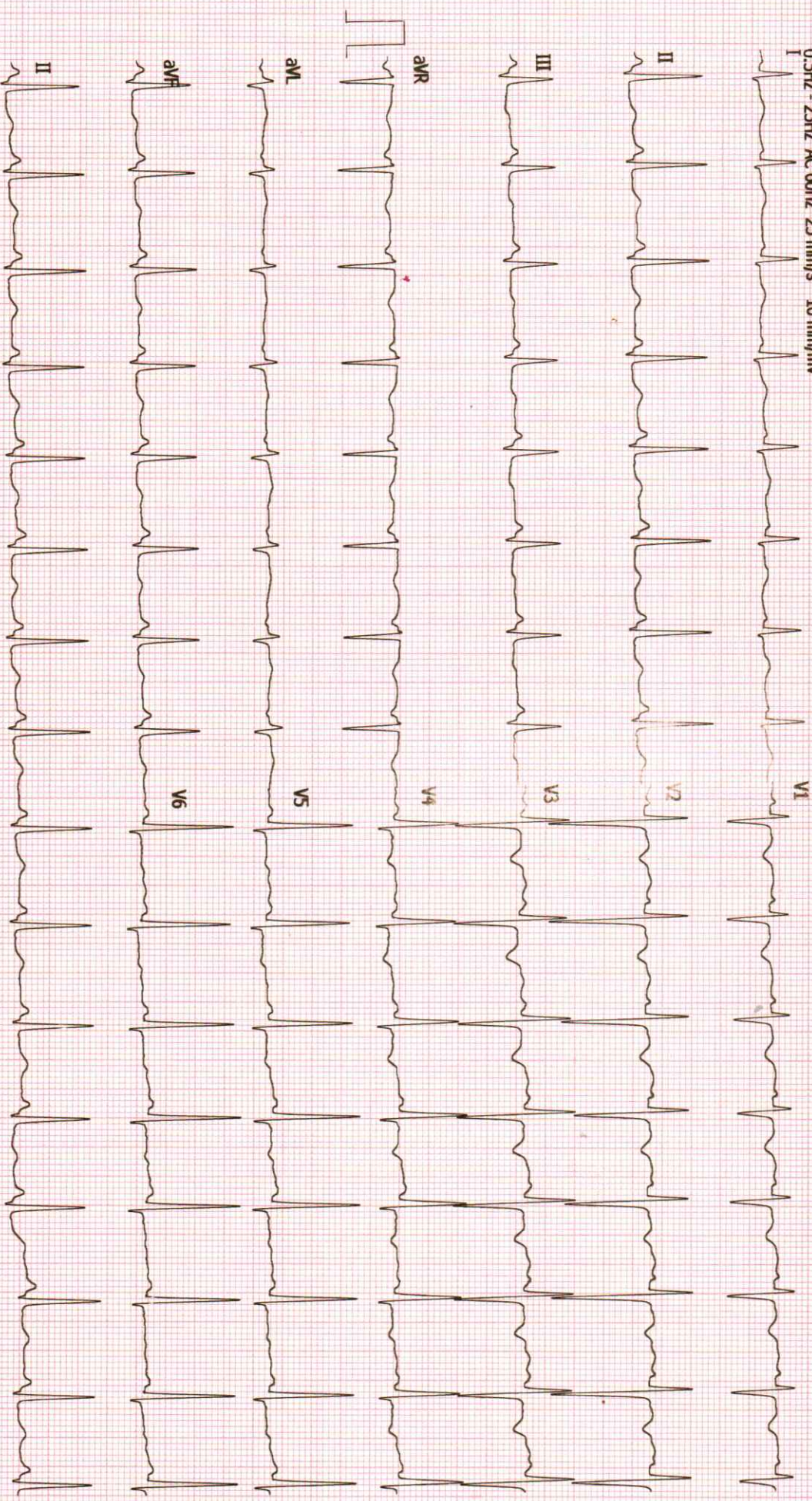
ID : 20210819123204  
 Name : Kumari Madhulata  
 Age : 24  
 Sex : Female  
 Hospital :  
 Department :

HR : 93 bpm  
 PR : 104 ms  
 QRS : 98 ms  
 QT/QTc : 352/438 ms  
 P/QRS/T : 82/64/-8 °  
 RV5/SV1 : 1.460/-0.745 mV  
 RV5+SV1 : 2.205 mV

**\*\* borderline ECG \*\***  
 Sinus rhythm  
 Short PR interval  
 Nonspecific T wave abnormality

Need to be confirmed by doctor. Doctor Name: \_\_\_\_\_

0.5Hz - 25Hz AC 60Hz 25 mm/s 10 mm/mv







Thanks for referral

# ANUPAM

## ULTRASOUND & COLOR DOPPLER CENTRE

ROAD NO. 1, JURAN CHAPRA, MUZAFFARPUR - 842 00  
Phones : 0621 - 2224133, 9525971756, E-mail : anupct1@gmail.com

Dr. Ajay Jaiswal  
MBBS, MRSH

Dr. A. K. Sha  
PGDM (Sonology)

U/S Reg. No- 07/2001

Reg. No- BMR- 16156

Name : Mrs. Madhu Lata  
Part scanned : Whole Abdomen  
Refd. by Dr. : Parashar Hospital  
Muz.

Age/ Sex : Y/F  
ID No - : 409  
Date/ Time : 23.08.2021

### USG OF WHOLE ABDOMEN REPORT

Liver is normal in size with uniform parenchymal echotexture. There is no focal lesion or dilatation of intrahepatic biliary radicles, portal vein is normal.

Gall bladder shows normal wall thickness and echofree lumen. C.B.D. is normal in caliber.

Pancreas is normal in size, shape and echotexture. Spleen is normal in size .

There is no abdominal lymphadenopathy seen.

Both kidneys are normal in size, shape & position. The C.M. differentiation is well maintained . There is no hydronephrosis and cast shadow.

No evidence of ascites/ pleural effusion.

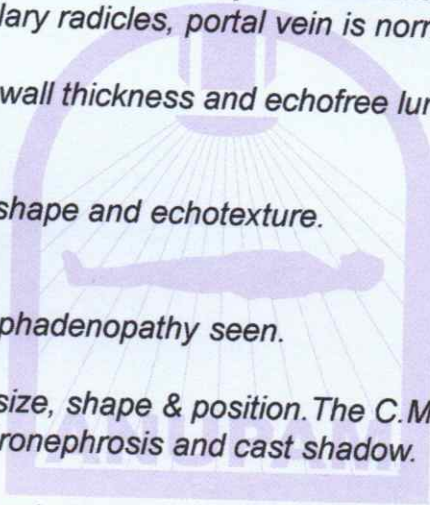
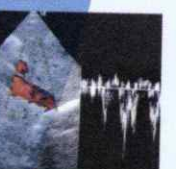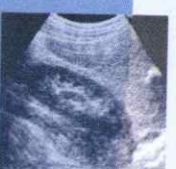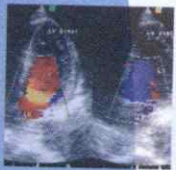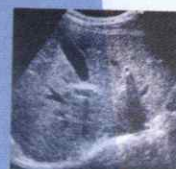Urinary bladder is smooth in outlined. There is no calculus within.

Uterus is normal in size and normal in echotexture.

Both ovaries shows follicles.

No collection or mass seen in RIF.

**OPINION: Normal USG of Whole Abdomen**



Health for all.....

Sonologist

On request

Not valid for medico-legal purpose



# ANUPAM

## ULTRASOUND & COLOR DOPPLER CENTRE

ROAD NO. 1, JURAN CHAPRA, MUZAFFARPUR - 842 001  
Phones : 0621 - 2224133, 9525971756, E-mail : anupct1@gmail.com

Dr. Ajay Jaiswal  
MBBS, MRSH

Dr. A. K. Shahi  
PGDM (Sonologist)

U/S Reg. No- 07/2001

Reg. No- BMR- 16156

Name : Mrs. Madhu Lata  
Part scanned : Echocardiography  
Refd. by Dr. : Parashar Hospital  
Muz.

Age/ Sex : Y/F  
ID No - : 408  
Date - : 23.08.2021

### ECHOCARDIOGRAM REPORT

2D echo / color doppler studies done in parasternal long and short axis, apical and subcostal view.

The aortic valves appears normal. There is no aortic regurgitation. The aorta appears normal and its dimension is 2.73cm. Aortic valve opening dimension 1.55cm in begning and 1.51 cm at end. The doppler velocity of aortic valve is 0.99m/sec. The mitral valves appears normal . There is no mitral regurgitation, the velocity of mitral valve is 0.89m/sec and valve leaflets excursion (D - DE -1.48cm, and V -EF - 0.21m/sec ). Tricuspid valves are thick. There is trivial tricuspid regurgitation. The doppler velocity of TV is 0.82m/sec.

Pulmonary valve is normal.

The left atrium appears normal and its dimension is 2.89 cm. There is no atrial fibrillation seen.

Left ventricle is normal and the dimation of L.V.C is 5.04cm at the end of diastole . Left ventricular E/F at rest is about 57%.

Right ventricle is normal and its dimation is 2.73 cm. Right atrium is normal . No VSD or ASD seen .

No segemental wall motion abnormality are seen at rest .

There is no intracardiac thrombi or clot seen .

There is no pericardial effusion seen.

On TVI the mean velocity of early systole S early diastole E and Late diastole A wave at basal ant and basal lat wall appears normal

M mode measurement : IVSD -0.73cm, LVIDd - 5.04cm, LVPWd - 0.71cm, IVSs - 0.96cm, LVIDs -3.53cm, LVPWs -0.89cm, EDV- 120.48ml, SV - 68.62ml, ESV-51.87ml, EF - 56.95%.

OPINION - Trivial TR.

Sonologist



Reg. No.- 815

# PARASHAR HOSPITAL

(A Unit of Vijayesh Kumar & Sons Pvt Ltd.)

MURLI MANOHAR COMPLEX, KHADI BHANDAR CHOWK, MUZAFFARPUR-842002 (BIHAR)

Mob.: 6200471018, 7992247583 E-mail : parashar.hospital@gmail.com

Kumari Madhuchitra, Sitamadhvi

Date: 24/10/2021

24/F

BP - 120/76

Go: Regular check up

E/E = Anaemia

Clust = clear

Haemogram - Normal  
Except haemoglobin

Ryoprofert - 50

127

27 biotin L.

or Pepsin L dy

24/10/21





Reg. No.- 815

# PARASHAR HOSPITAL

(A Unit of Vijayesh Kumar &amp; Sons Pvt Ltd.)

MURLI MANOHAR COMPLEX, KHADI BHANDAR CHOWK, MUZAFFARPUR-842002 (BIHAR)

Mob.: 6200471018, 7992247583 E-mail : parashar.hospital@gmail.com

Date : .....

PATIENT NAME : KUMARI MADHULATA  
AGE/SEX : 24Y/Adult-F  
REF. BY DR. : DR. PARASAR HOSPITAL

REF. NO : 23/08/21CP/48  
TEST. DATE : 23/08/2021  
RPT. DATE : 23/08/2021

INVESTIGATIONS	VALUE	REF. RANGE	UNIT
----------------	-------	------------	------

## HAEMATOLOGY

### CBC (COMPLETE BLOOD COUNT)

RBC (Red Blood Cells)	3.90	3.8-6.5	M/uL
Hb (Heamoglobin)	9.6	11-14.8	gm/dl
HCT (Haematocrit)	28.8	37-54	%
MCV	73.8	76-96	fL
MCH	24.6	27-32	Pg
MCHC	33.4	31-36	gm%
TC of WBC	5,100	4500-10500	/cumm
DC of WBC			
Neutrophil (seg)	60	50 - 70	%
Lymphocyte	34	20 - 40	%
Eosinophil	05	1 - 6	%
Monocyte	01	2 - 8	%
Basophil	00	0 - 1	%
Platelets	0.91	1.5-3.5	lakh/cumm
Red Cell Distribution Width (RDW)	12.6	11.5-14.5	fL
ESR (DONE BY AUTO ANALYZER)	22	0-20	mm/hr

## IMMUNOLOGY


### Blood Group

ABORH

"A" POSITIVE

## BIOCHEMISTRY

Plasma Glucose (Fasting)	78	70-110	mg/dl
Plasma Glucose (Post Prandial)	110	100-140	mg/dl
LIPID PROFILE			
Serum Total Cholesterol	180	50-230	mg/dl
Serum HDL Cholesterol Direct	38	30-65	mg/dl

  
Dr. Sima Kumari

Ph.D (Micro)

M.Sc. (Micro)

Ex. Project Trainee

AIIMS New Delhi (Lab. Medicine Dept.)

  
Dr. R.K. Narayan

M.D. (Path.)

Regd. No. 14962



Reg. No.- 815

# PARASHAR HOSPITAL

(A Unit of Vijayesh Kumar &amp; Sons Pvt Ltd.)

MURLI MANOHAR COMPLEX, KHADI BHANDAR CHOWK, MUZAFFARPUR-842002 (BIHAR)


Mob.: 6200471018,7992247583 E-mail : parashar.hospital@gmail.com

Date : .....

PATIENT NAME : KUMARI MADHULATA  
AGE/SEX : 24Y/Adult-F  
REF. BY DR. : DR. PARASAR HOSPITAL

REF. NO : 23/08/21CP/48  
TEST. DATE : 23/08/2021  
RPT. DATE : 23/08/2021

INVESTIGATIONS	VALUE	REF. RANGE	UNIT
<b>SERUM ELECTROLYTE</b>			
Sodium (Na)+	143.4	135-150	m mol/L
Potassium (K)+	3.5	3.5-5.1	m mol/L
Chloride (Cl)-	106.7	97-111	m mol/L



Dr. Sima Kumari

Ph.D (Micro)

M.Sc (Micro)

Ex. Project Trainee

AIIMS New Delhi (Lab. Medicine Dept.)



Dr. R.K. Narayan

M.D. (Path.)

Regd. No. 14962



# PARASHAR HOSPITAL

(A Unit of Vijayesh Kumar &amp; Sons Pvt Ltd.)

MURLI MANOHAR COMPLEX, KHADI BHANDAR CHOWK, MUZAFFARPUR-842002 (BIHAR)


Mob.: 6200471018, 7992247583 E-mail : parashar.hospital@gmail.com

Date : .....

PATIENT NAME : KUMARI MADHULATA  
 AGE/SEX : 24Y/Adult-F  
 REF. BY DR. : DR. PARASAR HOSPITAL

REF. NO : 23/08/21CP/48  
 TEST. DATE : 23/08/2021  
 RPT. DATE : 23/08/2021

INVESTIGATIONS	VALUE	REF. RANGE	UNIT
Serum Triglycerides	86	25-200	mg/dl
Serum LDL Cholesterol	124.80	95-130	mg/dl
Serum VLDL Cholesterol	17.20	7-32	mg/dl
TC/HDL Cholesterol Ratio	4.74	3.0-5.0	Ratio
LDL/HDL Ratio	3.28:1	1.5-3.5	Ratio
<b>LIVER PROFILE</b>			
Serum Bilirubin	.		
Total	0.6	0.1-1.2	mg%
Direct	0.3	0-0.3	mg%
Indirect	0.30	0-0.6	mg%
Serum SGPT (ALAT)	28	9-38	IU/L
Serum SGOT (ASAT)	23	10-40	IU/L
Alkaline Phosphatase	166	64-306	U/L
<b>Total Protien</b>			
Protein	7.0	6.0-8.0	g/dl
Albumin	3.9	3.7-5.3	g/dl
Globulin	3.10	2.3-3.6	g/dl
A:G Ratio	1.26:1	1.0-2.3	Ratio
Gamma Glutamyl transferase (GGT)	22	9-58	U/L
<b>RENAL FUNCTION TEST (RFT)</b>			
Serum Creatinine	0.9	0.6-1.4	mg/dl
Blood Urea Nitrogen (Bun)	12.14	7-21	mg/dl
Serum Uric Acid	6.3	2.5-6.8	mg/dl
Serum Calcium (Total)	9.0	8.7-11.0	mg/dl
Blood Urea	26	13-45	mg/dl

  
 Dr. Sima Kumari

Ph.D (Micro)

M.Sc. (Micro)

Ex. Project Trainee

AIIMS New Delhi (Lab. Medicine Dept.)

  
 Dr. R.K. Narayan

M.D. (Path)

Regd. No. 14962





Reg. No.- 815

# PARASHAR HOSPITAL

(A Unit of Vijayesh Kumar & Sons Pvt Ltd.)

MURLI MANOHAR COMPLEX, KHADI BHANDAR CHOWK, MUZAFFARPUR-842002 (BIHAR)

Mob.: 6200471018, 7992247583

E-mail : parashar.hospital@gmail.com

Date : .....

PATIENT NAME : KUMARI MADHULATA

REF. NO : 23/08/21CP/48

AGE/SEX : 24Y/Adult-F

TEST. DATE : 23/08/2021

REF. BY DR. : DR. PARASAR HOSPITAL

RPT. DATE : 23/08/2021

INVESTIGATIONS

VALUE

REF. RANGE


UNIT

HbA1c

5.4

4.2-6.0

Good Diabetic Control 5.5 - 6.8 Fair Control 6.8 - 7.6 Poor Control Above 7.6

  
Dr. Sima Kumari

Ph.D (Micro)

M.Sc. (Micro)

Ex. Project Trainee

AIIMS New Delhi (Lab. Medicine Dept.)

  
Dr. R.K. Narayan

M.D. (Path.)

Regd. No. 14962



Reg. No.- 815

# PARASHAR HOSPITAL

(A Unit of Vijayesh Kumar &amp; Sons Pvt Ltd.)

MURLI MANOHAR COMPLEX, KHADI BHANDAR CHOWK, MUZAFFARPUR-842002 (BIHAR)

Mob.: 6200471018, 7992247583 E-mail : parashar.hospital@gmail.com

Date : .....

PATIENT NAME : KUMARI MADHULATA  
AGE/SEX : 24Y/Adult-F  
REF. BY DR. : DR. PARASAR HOSPITAL

REF. NO : 23/08/21CP/48  
TEST. DATE : 23/08/2021  
RPT. DATE : 23/08/2021

INVESTIGATIONS	VALUE	REF. RANGE	UNIT
----------------	-------	------------	------

**URINE ROUTINE****Physical Examination**

Colour : Pale Straw  
Appearance : Clear

**Chemical Examination**

PH : Acidic  
Specific Gravity : 1.015  
Sugar : Negative  
Albumin : Negative

**Microscopic Examination**

Crystal : Nil  
RBC : Nil  
WBC : 0-1/HPF  
Epithelial Cells : A Few  
Granular Cast : Absent  
Bacteria : Absent  
Cast : Absent  
Other : NIL

  
**Dr. Sima Kumari**

Ph.D (Micro)

M.Sc.(Micro)

Ex. Project Trainee

AIIMS New Delhi(Lab.Medicine Dept.)

  
**Dr. R.K. Narayan**

M.D.(Path.)

Regd.No. 14962





Reg. No.- 815

# PARASHAR HOSPITAL

(A Unit of Vijayesh Kumar & Sons Pvt Ltd.)

MURLI MANOHAR COMPLEX, KHADI BHANDAR CHOWK, MUZAFFARPUR-842002 (BIHAR)

Mob.: 6200471018,7992247583 E-mail : parashar.hospital@gmail.com

Date : .....

PATIENT NAME : KUMARI MADHULATA  
AGE/SEX : 24Y/Adult-F  
REF. BY DR. : DR. PARASAR HOSPITAL

REF. NO : 24/08/21CP/64  
TEST. DATE : 24/08/2021  
RPT. DATE : 24/08/2021

INVESTIGATIONS	VALUE	REF. RANGE	UNIT
----------------	-------	------------	------

### ROUTINE

#### Stool Examination.

Colour	Yellow
Consistency	Semi Solid
Reducing Sugar	Nil
Mucus	Nil
Epithelial Cells	NIL
* Occult Blood	Negative
Parasites	Round Worm(+)
RBC	Nil
Undigested Food Particles	Absent
WBC	Nil
CYSTS	NIL

**Dr.Sima Kumari**  
Ph.D (Micro)  
M.Sc.(Micro)  
Ex.Project Trainee

**Dr.R.K. Narayan**  
M.D.(Path.)  
Regd.No.14962