

Name : Mr. RANJEET KUMAR (35 /M)
 Address : AHMEDABAD, AHMADABAD, AHMADABAD, GUJARAT, INDIA
 Examined by: Dr .AHC DOCTOR
 Package : MEDIWHEEL-FULL BODY CHK-BELOW40-MALE
Approved by Joint Commission International

Date : 30/01/2023
 UHID : AHCC 0000126851
 AHC No : AHCCA4355



CHIEF COMPLAINTS

For Annual health checkup
 No specific complaints

PRESENT KNOWN ILLNESS

No history of - Diabetes mellitus,
 Hypertension,
 Dyslipidemia, Thyroid
 disorder, Stroke

DRUG ALLERGY

NO KNOWN ALLERGY :30/01/2023

SYSTEMIC REVIEW

Cardiovascular system

- Nil Significant

Respiratory system

- Nil Significant

Oral and dental

- Nil Significant

Gastrointestinal system

- Nil Significant

Genitourinary system

- Nil Significant

Gynaec history

- Nil Significant

Central nervous system

- Nil Significant

Eyes

- Nil Significant

ENT

- Nil Significant

Musculoskeletal system

Spine and joints
 - Nil Significant

Skin
 - Nil Significant

General symptoms
 - Nil Significant

Past medical history

Do you have any allergies? - No
 Allergies - Nil
 Past medical history - nil significant
 Covid 19 - No
 Post detection (3 Weeks) - No
 Hospitalization for Covid 19 - No

Surgical history

Surgical history - Nil

Personal history

Ethnicity - Indian Asian
 Marital status - Married
 No. of children - 2
 Male - 2
 Diet - Mixed Diet
 Alcohol - does not consume alcohol
 Smoking - No
 Chews tobacco - No
 Physical activity - Sedentary

Family history

Father - alive
 Mother - alive
 Brothers - 2
 Diabetes - father
 Coronary artery disease - none

Name : Mr. RANJEET KUMAR (35 /M)

UHID : AHCC.0000126851

Date : 30/01/2023

Package : MEDIWHEEL-FULL BODY CHK-BELOW40-MALE

AHC No : AHCCAH4355



Organization is Accredited
by Commission International

Cancer - None

PHYSICAL EXAMINATION

General

General appearance - normal
Build - normal
Height - 165.8
Weight - 72.7
BMI - 26.45
Pallor - No
Oedema - no

Cardiovascular system

Heart rate (Per minute) - 61
Rhythm - Regular
Systolic(mm of Hg) - 120
Diastolic(mm of Hg) - 82
- B.P. Sitting
Heart sounds - S1S2+

Respiratory system

Breath sounds - Normal vesicular breath sounds

Abdomen

Organomegaly - No
Tenderness - No

Printed By : BHAWANA DAGA

Page 2 of 7

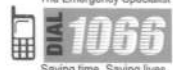For Enquiry/Appointments Contact +91 76988 15003 / +91 79 66701880

Apollo Hospitals International Limited
Plot No.-1A Bhat, GIDC, Gandhinagar, Gujarat - 382428, India.
Phone : +91 79 66701800 | Fax No. : +91 79 66701843
E-mail : info@apolloahd.com | www.ahmedabad.apollohospitals.com

Apollo Hospitals - City Centre (NON NABH-JCI)
1, Tulsibaug Society, Nr. Parimal Garden, Ahmedabad.
Phone : +91 79 66305800 / 01 or +91 76988 15148
E-mail : infoahcc@apolloahd.com

Regd. Office
19, Bishop Gardens, R.A. Puram, Chennai - 600 028
CIN No. : U85110TN1997PLC039016 | GSTin : 24AABCA4150H2Z5
For online appointment : www.askapollo.com

The Emergency Specialist



For online appointment : www.askapollo.com
Keep the records carefully and bring them along during your next visit to our Hospital

Saving time. Saving lives.

Name : Mr. **RANJEET KUMAR (35 /M)**

UHID : **AHCC.0000126851**

Date : **30/01/2023**

Package : **MEDIWHEEL-FULL BODY CHK-BELOW40-MALE**

AHC No : **AHCCA4355**



Organization is Accredited

STOOL ROUTINE

| Test Name | Result | Unit | Level | Range |
|------------------|------------|------|---------|-------|
| Colour: | Brown | | | |
| Consistency : | Semi Solid | | | |
| Mucus: | Absent | | | |
| Blood: | Negative | | | |
| Occult Blood | Negative | | | |
| Pus: | Nil | | 2-3 | |
| RBC | Nil | /hpf | 0-5/hpf | |
| Epithelial Cells | Absent | | | |
| Yeast Cells | Absent | | | |
| Vegetable Matter | Present | | | |
| Neutral Fat | Absent | | | |
| Starch Granules | Absent | | | |
| Trophozoite | Absent | | | |
| Ova: | Absent | | | |
| Cysts: | Absent | | | |

COMPLETE BLOOD COUNT WITH ESR

| Test Name | Result | Unit | Level | Range |
|--|--|------------|-------|---------------|
| Hemoglobin (Photometric Measurement) | 13.6 | gm% | ● | 13.0-17.0 |
| Packed cell volume(Calculated) | 41 | % | ● | 40-50 |
| RBC COUNT (Impedance) | 4.46 * | Million/ul | ● | 4.5-5.9 |
| MCV (From RBC Histogram) | 91.9 | fl | ● | 80-100 |
| MCH(Calculated) | 30.4 | pg | ● | 27-32 |
| MCHC(Calculated) | 33 | % | ● | 31-36 |
| RDW(Calculated) | 13.8 | % | ● | 11.5-14.5 |
| WBC Count (Impedance) | 6500 | /cu mm | ● | 4000-11000 |
| Neutrophils | 71 | % | ● | 40-75 |
| Lymphocytes | 23 | % | ● | 20-40 |
| Monocytes | 04 | % | ● | 2-10 |
| Eosinophils | 02 | % | ● | 01-06 |
| Basophils | 00 | % | ● | 0-1 |
| Platelet Count (Impedance) | 130000 * | /cu mm | ● | 150000-450000 |
| MPV (Calculated) | 11.9 * | fl | ● | 7-11 |
| Platelets: | Giant platelets noted~Thrombocytopenia noted | | | |
| ERYTHROCYTE SEDIMENTATION RATE (ESR) (Automated/ optic-electronic) | 06 | mm/1st hr | ● | 0-15 |
| SUGGEST : | Please correlate clinically | | | |

URINE FOR ROUTINE EXAMINATION

| Test Name | Result | Unit | Level | Range |
|------------------|-------------|----------|---------|-------|
| Specific Gravity | 1.010 | | | |
| Colour: | Pale-Yellow | | | |
| Transparency: | Clear | | | |
| pH | 6 | | | |
| Protein : | Nil | | | |
| Sugar: | Nil | | | |
| Blood: | Negative | | | |
| Ketone | Absent | | | |
| Bile Pigments: | Absent | | | |
| Urobilinogen | Normal | E.U./d L | | |
| Nitrite | Negative | | | |
| Pus Cells | Occassional | | 0-5 | |
| RBC | Nil | /hpf | 0-5/hpf | |
| Epithelial Cells | Occassional | | | |
| Casts: | Absent | | | |
| Crystals: | Absent | | | |

BLOOD GROUPING AND TYPING (ABO and Rh)

| Test Name | Result | Unit | Level | Range |
|--------------|------------|------|-------|-------|
| BLOOD GROUP: | O Positive | | | |

LFT (LIVER FUNCTION TEST)

| Test Name | Result | Unit | Level | Range |
|----------------------------|--------|------|-------|-------|
| ALT(SGPT) - SERUM / PLASMA | 39 | U/L | ● | 0-50 |

● Within Normal Range ● Borderline High/Low ● Out of Range

Name : Mr. RANJEET KUMAR (35 /M)

UHID : AHCC.0000126851

Date : 30/01/2023

Package : MEDIWHEEL-FULL BODY CHK-BELOW40-MALE

AHC No : AHCCA4355



| Test Name | Result | Unit | Level | Range |
|-------------------------------------|--------|-------|-------|--|
| ALKALINE PHOSPHATASE - SERUM/PLASMA | 113 | U/L | ● | Adult(Male): 40 - 129 |
| AST (SGOT) - SERUM | 28 | U/L | ● | > 1 year Male : <40 |
| Total Bilirubin | 0.548 | mg/dL | ● | 0.300-1.200 |
| Direct Bilirubin | 0.188 | mg/dL | ● | Upto 0.3 mg/dl |
| Indirect Bilirubin | 0.36 | mg/dL | ● | 1 Day ≤5.1 mg/dL 2 Days ≤7.2 mg/dL 3-5 Days ≤10.3 mg/dL 6-7 Days ≤8.4 mg/dL 8-9 Days ≤6.5 mg/dL 10-11 Days ≤4.6 mg/dL 12-13 Days ≤2.7 mg/dL 14 Days - 9 Years 0.2-0.8 mg/dL 10-19 Years 0.2-1.1 mg/dL ≥20 Years 0.2-1.2 mg/dL |

GLUCOSE - SERUM / PLASMA (POST PRANDIAL) - PPBS

| Test Name | Result | Unit | Level | Range |
|----------------------------------|--------|-------|-------|--------|
| Glucose - Plasma (Post Prandial) | 131 | mg/dL | ● | 70-140 |
| Urine Glucose (Post Prandial) | Nil | | | |

GLYCOSYLATED HEMOGLOBIN (HBA1C) - WHOLE BLOOD

| Test Name | Result | Unit | Level | Range |
|---------------------------------|--------|------|-------|--------------|
| Glycosylated Hemoglobin (HbA1c) | 4.98 | % | ● | Normal < 5.7 |

%Increased risk for Diabetes 5.7 - 6.4%
Diabetes ≥= 6.5%

CREATININE - SERUM / PLASMA

| Test Name | Result | Unit | Level | Range |
|-----------------------------|--------|-------|-------|-----------------------|
| CREATININE - SERUM / PLASMA | 0.85 | mg/dL | ● | Adult Male: 0.6 - 1.3 |

LFT (LIVER FUNCTION TEST)

| Test Name | Result | Unit | Level | Range |
|---|--------|------|-------|-----------------------------------|
| GGTP: GAMMA GLUTAMYL TRANSPEPTIDASE - SERUM | 24 | U/L | ● | Male : 10 - 71 Female : 6 - 42 |

GLUCOSE - SERUM / PLASMA (FASTING)

| Test Name | Result | Unit | Level | Range |
|-----------|--------|------|-------|-------|
|-----------|--------|------|-------|-------|

Monitoring criteria for Diabetes Mellitus
<7.0 : Well Controlled
7.1 – 8.0 : Unsatisfactory Control
> 8.0 : Poor Control & Needs Immediate Treatment

● Within Normal Range ● Borderline High/Low ● Out of Range

Name : Mr. RANJEET KUMAR (35 /M)
 Package : MEDIWHEEL-FULL BODY CHK-BELOW40-MALE

UHID : AHCC.0000126851

Date : 30/01/2023

AHC No : AHCCAH4355



Glycosylated Hemoglobin (HbA1c)

4.98 % ● Normal < 5.7
 %Increased risk for Diabetes 5.7 - 6.4%
 Diabetes >= 6.5%
 Monitoring criteria for Diabetes Mellitus
 <7.0 : Well Controlled Diabetes
 7.1 – 8.0 : Unsatisfactory Control
 > 8.0 : Poor Control & Needs Immediate Treatment

| Test Name | Result | Unit | Level | Range |
|-------------------|--------|-------|-------|------------------------------------|
| URIC ACID - SERUM | 6.9 | mg/dL | ● | Male : 3.4-7.0 Female : 2.4-5.7 |

BUN (BLOOD UREA NITROGEN)

| Test Name | Result | Unit | Level | Range |
|---------------------------|--------|-------|-------|---------|
| BUN (BLOOD UREA NITROGEN) | 11 | mg/dL | ● | 6-20 |
| UREA - SERUM / PLASMA | 24 | mg/dL | ● | 15 - 50 |

LIPID PROFILE - SERUM

| Test Name | Result | Unit | Level | Range |
|-------------------|--------|-------|-------|---|
| Total Cholesterol | 193 | mg/dl | ● | 0 - 200 : Desirable 200 - 240 : Borderline High 240 - 280 : High > 280 : Very High |

| | | | | |
|--|-------|-------|---|--|
| Triglycerides - Serum | 292 * | mg/dL | ● | 0-150 |
| HDL CHOLESTEROL - SERUM / PLASMA (Direct Enzymatic Colorimetric) | 44 * | mg/dL | ● | < 40 : Major risk factor for heart disease 40 - 59 : The higher The better. >=60 : Considered protective against heart disease |

| | | | | |
|------------------------------|-----|-------|---|---|
| LDL Cholesterol (Direct LDL) | 105 | mg/dL | ● | 100 : Optimal 100-129 : Near Optimal 130-159 : Borderline High 160-189 : High >=190 : Very High |
|------------------------------|-----|-------|---|---|

| | | | | |
|------------------|------|--|---|------------|
| VLDL CHOLESTEROL | 58 * | | ● | < 40 mg/dl |
| C/H RATIO | 4.4 | | ● | 0-4.5 |

USG WHOLE ABDOMEN

● Within Normal Range ● Borderline High/Low ● Out of Range

LFT (LIVER FUNCTION TEST)

| Test Name | Result | Unit | Level | Range |
|--------------------------------|--------|------|-------|------------------------------|
| PROTEIN TOTAL - SERUM / PLASMA | 7.15 | g/dL | ● | 6.00-8.00 |
| ALBUMIN - SERUM | 4.72 | g/dL | ● | Adult(18 - 60 Yr): 3.5 - 5.2 |
| Globulin-Serum/Plasma | 2.4 | | ● | 2.20-4.20 |
| A/G ratio | 1.9 | | ● | 1.00-2.00 |

THYROID PROFILE (T3,T4 AND TSH)

| Test Name | Result | Unit | Level | Range |
|--|--------|--------|-------|----------------------------|
| TOTAL T3: TRI IODOTHYRONINE - SERUM | 1.31 | ng/mL | ● | 0.8 - 2.0 |
| TOTAL T4: THYROXINE - SERUM | 8.17 * | ug/dL | ● | 5.1 - 14.1 |
| TSH: THYROID STIMULATING HORMONE - SERUM | 2.14 | µIU/mL | ● | 14-120 years : 0.27 - 4.20 |

URIC ACID - SERUM

Name : Mr. RANJEET KUMAR (35 /M)

UHID : AHCC.0000126851

Date : 30/01/2023

Package : MEDIWHEEL-FULL BODY CHK-BELOW40-MALE

AHC No : AHCCAH4355



Organization is Accredited

Liver appears normal in size and shows uniform normal echotexture. No evidence of focal or diffuse pathology seen. Intra and extra hepatic biliary radicals are not dilated. Portal vein is normal in caliber. Intrahepatic portal radicals appear normal.

Gall bladder appears normal with no evidence of calculus. Wall thickness appears normal. No evidence of pericholecystic collection.

Visualized pancreas appear normal in size and echotexture. No focal lesions identified. Visualize pancreatic duct appears normal in caliber.

Spleen is normal in size and shows uniform echotexture.

Both kidneys are normal in size and show normal echopattern with good corticomedullary differentiation. Cortical outlines appear smooth. No evidence of calculi. Pelvicalyceal system on both sides appears normal.

No evidence of ascites or significant lymphadenopathy. Visualized bowel loops are unremarkable.

Urinary bladder is normal in contour and outline. Wall thickness appears normal. No evidence of any intraluminal pathology seen.

Prostate (volume 16 cc) is normal in size and echopattern.

IMPRESSION:

No significant abnormality.

X-RAY CHEST PA

NORMAL STUDY.

INVESTIGATIONS NOT DONE / NOT YET REPORTED / NOT PART OF PACKAGE (LAB, RADIOLOGY & CARDIOLOGY)

Haematology

URINE GLUCOSE (FASTING)

URINE GLUCOSE (POST PRANDIAL)

CARDIOLOGY

ECHO/TMT

ECG

● Within Normal Range ● Borderline High/Low ● Out of Range

Name : Mr. RANJEET KUMAR (35 /M)

UHID : AHCC.0000126851

Date : 30/01/2023

Package : MEDIWHEEL-FULL BODY CHK-BELOW40-MALE

AHC No : AHCCAH4355



Organization Accredited

Executive Summary

ALL FINDINGS ARE WNL.

Printed By : BHAWANA DAGA



AHC Physician / Consultant Internal Medicine

Note :- The Health Check-up examinations and routine investigations have certain limitations and may not be able to detect all the diseases. Any new or persisting symptoms should be brought to the attention of the Consulting Physician. Additional tests, consultations and follow up may be required in some cases.

For Enquiry/Appointments Contact +91 76988 15003 / +91 79 66701880

Apollo Hospitals International Limited
Plot No. -1A, Bhat, GIDC, Gandhinagar, Gujarat - 382428, India.
Phone : +91 79 66701800 | Fax No. : +91 79 66701843
E-mail : info@apolloahd.com | www.ahmedabad.apollohospitals.com

Apollo Hospitals - City Centre (NON NABH-JCI)
1, Tulsibaug Society, Nr. Parimal Garden, Ahmedabad.
Phone : +91 79 66305800 / 01 or +91 76988 15148
E-mail : infoahcc@apolloahd.com

Regd. Office
19, Bishop Gardens, R.A. Puram, Chennai - 600 028
CIN No. : U85110TN1997PLC039016 | GSTin : 24AABCA4150H2Z5
For online appointment : www.askapollo.com

The Emergency Specialist



For online appointment : www.askapollo.com
Keep the records carefully and bring them along during your next visit to our Hospital

Saving time. Saving lives.



Organization is Accredited
by Joint Commission International

DEPARTMENT OF HAEMATOLOGY



Name : **Mr. RANJEET KUMAR** Age : **35Yr 11Mth 12Days** Gender : **Male**
 UHID : **AHCC.0000126851 / AHCCA4355** W/BNo/RefNo : **AHC**
 SIN \LRN : **3713252 \ 1593011**
 Specimen : **Whole Blood (EDTA)**
 Ref Doctor : **Mr. AHC DOCTOR**



Collected on : **30-JAN-2023 09:06:12 AM** Received on : **30-JAN-2023 09:39:49 AM** Reported on : **30-JAN-2023 06:26:45 PM**

MEDIWHEEL-FULL BODY CHK-BELOW40-MALE

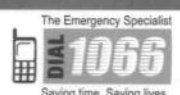| TEST NAME | RESULT | BIOLOGICAL REFERENCE INTERVALS | UNITS |
|--|---|--------------------------------|------------|
| COMPLETE BLOOD COUNT WITH ESR | | | |
| Hemoglobin (Photometric Measurement) | 13.6 | 13.0 - 17.0 | gm% |
| Packed cell volume(Calculated) | 41 | 40 - 50 | % |
| RBC COUNT (Impedance) | 4.46 * | 4.5 - 5.9 | Million/ul |
| MCV (From RBC Histogram) | 91.9 | 80 - 100 | fl |
| MCH(Calculated) | 30.4 | 27 - 32 | pg |
| MCHC(Calculated) | 33 | 31 - 36 | % |
| RDW(Calculated) | 13.8 | 11.5 - 14.5 | % |
| WBC Count (Impedance) | 6500 | 4000 - 11000 | /cu mm |
| Differential Count (VCS Technology and Microscopy) | | | |
| Neutrophils | 71 | 40 - 75 | % |
| Lymphocytes | 23 | 20 - 40 | % |
| Monocytes | 04 | 2 - 10 | % |
| Eosinophils | 02 | 01 - 06 | % |
| Basophils | 00 | 0 - 1 | % |
| Platelet Count (Impedance) | 130000 * | 150000 - 450000 | /cu mm |
| MPV (Calculated) | 11.9 * | 7 - 11 | fl |
| PERIPHERAL SMEAR(Microscopy) | Giant platelets noted,Thrombocytopenia noted | | |
| Platelets: | 06 | 0 - 15 | mm/1st hr |
| ERYTHROCYTE SEDIMENTATION RATE (ESR) (Automated/ optic-electronic) | | | |
| SUGGEST : | Please correlate clinically | | |

For Enquiry/Appointments Contact +91 76988 15003 / +91 79 66701880

Apollo Hospitals International Limited
 Plot No.-1A, Bhat, GIDC, Gandhinagar, Gujarat - 382428, India.
 Phone : +91 79 66701800 | Fax No. : +91 79 66701843
 E-mail : info@apolloahd.com | www.ahmedabad.apollohospitals.com

Apollo Hospitals - City Centre (NON NABH-JCI)
 1, TulsiBaag Society, Nr. Parimal Garden, Ahmedabad.
 Phone : +91 79 66305800 / 01 or +91 76988 15148
 E-mail : infoahcc@apolloahd.com

Regd. Office
 19, Bishop Gardens, R.A. Puram, Chennai - 600 028
 CIN No. : U85110TN1997PLC039016 | GSTin : 24AABCA4150H225
 For online appointment : www.askapollo.com





Organization is Accredited
by Joint Commission International



DEPARTMENT OF HAEMATOLOGY

Name : Mr. RANJEET KUMAR
 Age : 35Yr 11Mth 12Days Gender : Male
 UHID : AHCC.0000126851 / AHCCAH4355
 W/BNo/RefNo : AHC
 SIN \LRN : 3713252 \ 1593011
 Specimen : Whole Blood (EDTA)
 Ref Doctor : Mr. AHC DOCTOR



Collected on : 30-JAN-2023 09:06:12 AM Received on : 30-JAN-2023 09:39:49 AM Reported on : 30-JAN-2023 06:26:45 PM

'30/01/2023
 Report Status:Final

* END OF REPORT *

CHECKED BY : 1010616
 724146

Printed On : 30-JAN-2023 08:17:53 PM

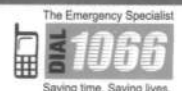Dr.RAVISH SHAH
MD PATHOLOGY

For Enquiry/Appointments Contact +91 76988 15003 / +91 79 66701880

Apollo Hospitals International Limited
 Plot No. -1A, Bhat, GDC, Gandhinagar, Gujarat - 382428, India.
 Phone : +91 79 66701800 | Fax No. : +91 79 66701843
 E-mail : info@apolloahd.com | www.ahmedabad.apollohospitals.com

Apollo Hospitals - City Centre (NON NABH-JCI)
 1, TulsiBaag Society, Nr. Parimal Garden, Ahmedabad.
 Phone : +91 79 66305800 / 01 or +91 78988 15148
 E-mail : infoahcc@apolloahd.com

Regd. Office
 19, Bishop Gardens, R.A. Puram, Chennai - 600 028
 CIN No. : U85110TN1997PLC039016 | GSTIn : 24AAABCA4150H225
 For online appointment : www.askapollo.com






Organization is Accredited
by Joint Commission International

DEPARTMENT OF BIOCHEMISTRY AND IMMUNOLOGY



Name : Mr. RANJEET KUMAR
 UHID : AHCC.0000126851 / AHCCAH4355
 SIN / LRN : 3713254 \ 3713255 \ 3713253 \ 3713261 \
 Specimen : 1593011
 Ref Doctor : Mr. AHC DOCTOR

Age : 35Yr 11Mth
 Gender : Male
 W/BNo/RefNo : AHC
 12Days



Collected on : 30-JAN-2023 09:06:13 AM Received on : 30-JAN-2023 09:40:05 AM Reported on : 30-JAN-2023 12:21:13 PM

MEDIWHEEL-FULL BODY CHK-BELOW40-MALE

| TEST NAME | RESULT | BIOLOGICAL REFERENCE INTERVALS | UNITS |
|--|--------|--|-------|
| GLYCOSYLATED HEMOGLOBIN (HBA1C) - WHOLE BLOOD (Immuno-turbidimetric) | 4.98 | Normal < 5.7% Increased risk for Diabetes 5.7 - 6.4% Diabetes >= 6.5% Monitoring criteria for Diabetes Mellitus <7.0 : Well Controlled Diabetes 7.1 – 8.0 : Unsatisfactory Control > 8.0 : Poor Control & Needs Immediate Treatment | % |
| Mean Blood Sugar GLUCOSE - SERUM / PLASMA (FASTING) (Hexokinase) | 96 | 70 - 100 : Normal 100 - 125 : Impaired Glucose Tolerance >= 126 : Diabetes Mellitus Adult Male : < 45 | mg/dL |
| ALT(SGPT) - SERUM / PLASMA (UV without P5P) | 39 | Adult(Male): 40 - 129 | U/L |
| ALKALINE PHOSPHATASE - SERUM/PLASMA (PNP AMP BUFFER) | 113 | > 1 year Male : <40 | U/L |
| AST (SGOT) - SERUM | 28 | | |

For Enquiry/Appointments Contact +91 76988 15003 / +91 79 66701880

Apollo Hospitals International Limited
 Plot No.-1A, Bhat, GIDC, Gandhinagar, Gujarat - 382428, India.
 Phone : +91 79 66701800 | Fax No. : +91 79 66701843
 E-mail : info@apolloahd.com | www.ahmedabad.apollohospitals.com

Apollo Hospitals - City Centre (NON NABH-JCI)
 1, Tulsibaug Society, Nr. Parimal Garden, Ahmedabad.
 Phone : +91 79 66305800 / 01 or +91 76988 15148
 E-mail : infoahcc@apolloahd.com

Regd. Office
 19, Bishop Gardens, R.A. Puram, Chennai - 600 028
 CIN No. : U85110TN1997PLC039016 | GSTin : 24AABCA4150H225
 For online appointment : www.askapollo.com



For online appointment : www.askapollo.com
 Keep the records carefully and bring them along during your next visit to our Hospital

The Emergency Specialist
 Saving time. Saving lives.



Organization is Accredited
by Joint Commission International

DEPARTMENT OF BIOCHEMISTRY AND IMMUNOLOGY



Name : Mr. RANJEET KUMAR
 UHID : AHCC.0000126851 / AHCCA4355
 SIN \ LRN : 3713254 \ 3713255 \ 3713253 \ 3713261 \
 Specimen : Serum
 Ref Doctor : Mr. AHC DOCTOR

Age : 35Yr 11Mth
 Gender : Male
 W/BNo/RefNo : AHC
 12Days



Collected on : 30-JAN-2023 09:06:13 AM
 Received on : 30-JAN-2023 09:40:05 AM
 Reported on : 30-JAN-2023 12:21:13 PM

| (UV without P5P) | | | |
|--|--------------|--|-------|
| BILIRUBIN (DIRECT/INDIRECT/TOTAL) - SERUM | | | |
| (Diazotization) | | | |
| Bilirubin Total | 0.548 | 0-1 days : 0 - 6mg/dl 1-2 days : 0 - 8mg/dl 2-5 days : 0 - 12mg/dl 5days - 4 months : 0.3 -1.2mg/dl >4 months : 0.3-1.2 mg/dl | mg/dL |
| Direct Bilirubin | 0.188 | Upto 0.3 mg/dl | mg/dL |
| Indirect Bilirubin | 0.36 | 1 Day ≤5.1 mg/dL 2 Days ≤7.2 mg/dL 3-5 Days ≤10.3 mg/dL 6-7 Days ≤8.4 mg/dL 8-9 Days ≤6.5 mg/dL 10-11 Days ≤4.6 mg/dL 12-13 Days ≤2.7 mg/dL 14 Days - 9 Years 0.2-0.8 mg/dL 10-19 Years 0.2-1.1 mg/dL ≥20 Years 0.2-1.2 mg/dL | mg/dL |
| CREATININE - SERUM / PLASMA | 0.85 | Adult Male: 0.6 - 1.3 | mg/dL |
| (Alkaline picrate - kinetic rate blanked) | | | |
| GGTP: GAMMA GLUTAMYL TRANSPEPTIDASE - SERUM | 24 | Male : 10 - 71 Female : 6 - 42 | U/L |
| (IFCC) | | | |
| PROTEIN TOTAL - SERUM / PLASMA | 7.15 | >2 Year: 6.0 - 8.0 | g/dL |
| (Biuret) | | | |
| ALBUMIN - SERUM | 4.72 | Adult(18 - 60 Yr): 3.5 - 5.2 | g/dL |

For Enquiry/Appointments Contact +91 76988 15003 / +91 79 66701880

Apollo Hospitals International Limited
 Plot No.-1A, Bhat, GDC, Gandhinagar, Gujarat - 382428, India.
 Phone : +91 79 66701800 | Fax No. : +91 79 66701843
 E-mail : info@apolloahd.com | www.ahmedabad.apollohospitals.com

Apollo Hospitals - City Centre (NON NABH-JCI)
 1, TulsiBaag Society, Nr. Parimal Garden, Ahmedabad.
 Phone : +91 79 66305800 / 01 or +91 76988 15148
 E-mail : infoahcc@apolloahd.com

Regd. Office
 19, Bishop Gardens, R.A. Puram, Chennai - 600 028
 CIN No. : U85110TN1997PLC039016 | GSTin : 24AABCA4150H225
 For online appointment : www.askapollo.com






Organization is Accredited
by Joint Commission International

DEPARTMENT OF BIOCHEMISTRY AND IMMUNOLOGY



Name : Mr. RANJEET KUMAR
 UHID : AHCC.0000126851 / AHCCA4355
 SIN \ LRN : 3713254 \ 3713255 \ 3713253 \ 3713261 \ 1593011
 Specimen : Serum
 Ref Doctor : Mr. AHC DOCTOR

Age : 35Yr 11Mth
 Gender : Male
 W/BNo/RefNo : AHC
 12Days



Collected on : 30-JAN-2023 09:06:13 AM Received on : 30-JAN-2023 09:40:05 AM Reported on : 30-JAN-2023 12:21:13 PM

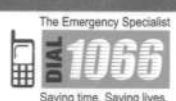| | | | |
|--|--------|---|--------|
| Globulin-Serum/Plasma | 2.4 | 2.2 - 4.2 | |
| A/G ratio | 1.9 | 1.00 - 2.00 | |
| TOTAL T3: TRI IODOTHYRONINE - SERUM (Electrochemiluminescence:ECLIA) | 1.31 | 0.8 - 2.0 | ng/mL |
| TOTAL T4: THYROXINE - SERUM (Electrochemiluminescence:ECLIA) | 8.17 * | 5.1 - 14.1 | ug/dL |
| TSH: THYROID STIMULATING HORMONE - SERUM (Electrochemiluminescence:ECLIA) | 2.14 | 14-120 years : 0.27 - 4.20 | µIU/mL |
| URIC ACID - SERUM (Uricase, colorimetric) | 6.9 | Male : 3.4-7.0 Female : 2.4-5.7 | mg/dL |
| BUN (BLOOD UREA NITROGEN) (Histology) | 11 | Adult : 6 - 20 | mg/dL |
| UREA - SERUM / PLASMA | 24 | 15 - 50 | mg/dL |
| LIPID PROFILE - SERUM | | | |
| TOTAL CHOLESTEROL (CHOD POD) | 193 | 0 - 200 : Desirable 200 - 240 : Borderline High 240 - 280 : High > 280 : Very High | mg/dl |
| TRIGLYCERIDES - SERUM (Enzymatic Endpoint) | 292 * | Normal: <150 High: 150 - 199 Hypertriglyceridemic: 200 - 499 Very High: >=500 | mg/dL |
| HDL CHOLESTEROL - SERUM / PLASMA (Direct Enzymatic Colorimetric) | 44 * | < 40 : Major risk factor for heart disease 40 - 59 : The higher The better. | mg/dL |

For Enquiry/Appointments Contact +91 76988 15003 / +91 79 66701880

Apollo Hospitals International Limited
 Plot No.-1A, Bhat, GIDC, Gandhinagar, Gujarat - 382428, India.
 Phone : +91 79 66701800 | Fax No. : +91 79 66701843
 E-mail : info@apolloahd.com | www.ahmedabad.apollohospitals.com

Apollo Hospitals - City Centre (NON NABH-JCI)
 1, TulsiBaag Society, Nr. Parimal Garden, Ahmedabad.
 Phone : +91 79 66305800 / 01 or +91 76988 15148
 E-mail : infoahcc@apolloahd.com

Regd. Office
 19, Bishop Gardens, R.A. Puram, Chennai - 600 028
 CIN No. : U85110TN1997PLC039016 | GSTin : 24AABCA4150H225
 For online appointment : www.askapollo.com



For online appointment : www.askapollo.com
 Keep the records carefully and bring them along during your next visit to our Hospital

The Emergency Specialist
 Saving time. Saving lives.




Organization is Accredited
by Joint Commission International

DEPARTMENT OF BIOCHEMISTRY AND IMMUNOLOGY



Name : Mr. RANJEET KUMAR
 Age : 35Yr 11Mth Gender : Male
 UHID : AHCC.0000126851 / AHCCA4355
 W/BNo/RefNo : AHC
 SIN \ LRN : 3713254 \ 3713255 \ 3713253 \ 3713261 \
 Specimen : Serum
 Ref Doctor : Mr. AHC DOCTOR



Collected on : 30-JAN-2023 09:06:13 AM Received on : 30-JAN-2023 09:40:05 AM Reported on : 30-JAN-2023 12:21:13 PM

| | | | |
|--|------|---|-------|
| LDL CHOLESTEROL - SERUM / PLASMA (Direct LDL) | 105 | >=60 : Considered protective against heart disease < 100 : Optimal 100-129 : Near Optimal 130-159 : Borderline High 160-189 : High >=190 : Very High | mg/dL |
| VLDL CHOLESTEROL (Calculated) | 58 * | < 40 mg/dl | |
| C/H RATIO (Calculated) | 4.4 | < 4.5 | |
| GLUCOSE - SERUM / PLASMA (POST PRANDIAL) - PPBS (Hexokinase) | | | |
| GLUCOSE - SERUM / PLASMA (POST PRANDIAL) | 131 | 70 - 140 | mg/dL |
| URINE GLUCOSE(POST PRANDIAL):(Strip Method) | Nil | Nil | |

30/01/2023
 Report Status:Final

* END OF REPORT *

CHECKED BY 1010616
 717880



Printed On : 30-JAN-2023 03:41:51 PM

Dr.HARDIK KOSHTI
 MD PATHOLOGY,
 CONSULTANT

For Enquiry/Appointments Contact +91 76988 15003 / +91 79 66701880



Organization is Accredited
by Joint Commission International



DEPARTMENT OF CLINICAL PATHOLOGY

Name : Mr. RANJEET KUMAR
 Age : 35Yr 11Mth 12Days Gender : Male
 UHID : AHCC.0000126851 / AHCCA4355
 W/BNo/RefNo : AHC
 SIN \LRN : 3713259 \ 3713256 \ 1593011
 Specimen : Stool
 Ref Doctor : Mr. AHC DOCTOR



Collected on : 30-JAN-2023 09:06:13 AM Received on : 30-JAN-2023 01:31:03 PM Reported on : 30-JAN-2023 01:32:19 PM

MEDIWHEEL-FULL BODY CHK-BELOW40-MALE

| TEST NAME | RESULT | BIOLOGICAL REFERENCE INTERVALS | UNITS |
|-----------|--------|--------------------------------|-------|
|-----------|--------|--------------------------------|-------|

URINE FOR ROUTINE EXAMINATION : (Solubility Method)

PHYSICAL EXAMINATION

| | | | |
|------------------|-------------|--|--|
| Specific Gravity | 1.010 | | |
| Colour: | Pale-Yellow | | |
| Transparency: | Clear | | |

CHEMICAL EXAMINATION

| | | | |
|----------------|----------|--|---------|
| pH | 6 | | |
| Protein : | Nil | | |
| Sugar: | Nil | | |
| Blood: | Negative | | |
| Ketone | Absent | | |
| Bile Pigments: | Absent | | |
| Urobilinogen | Normal | | |
| Nitrite | Negative | | E.U./dL |

Cells:

| | | | |
|------------------|------------|---------|------|
| Pus Cells | Occasional | | |
| RBC | Nil | 0-5/hpf | |
| Epithelial Cells | Occasional | 0-5/hpf | /hpf |
| Casts: | Absent | | |
| Crystals: | Absent | | |

STOOL ROUTINE : (Supra Vital Staining)

PHYSICAL EXAMINATION

| | | | |
|---------------|------------|--|--|
| Colour: | Brown | | |
| Consistency : | Semi Solid | | |
| Mucus: | Absent | | |
| Blood: | Negative | | |

CHEMICAL EXAMINATION

| | | | |
|--------------|----------|--|--|
| Occult Blood | Negative | | |
| Cells: | | | |



Organization is Accredited
by Joint Commission International



DEPARTMENT OF CLINICAL PATHOLOGY

Name : Mr. RANJEET KUMAR
 UHID : AHCC.0000126851 / AHCCA4355 Age : 35Yr 11Mth 12Days Gender : Male
 SIN \LRN : 3713259 \ 3713256 \ 1593011 W/BNo/RefNo : AHC
 Specimen : Stool
 Ref Doctor : Mr. AHC DOCTOR



Collected on : 30-JAN-2023 09:06:13 AM Received on : 30-JAN-2023 01:31:03 PM Reported on : 30-JAN-2023 01:32:19 PM

| | | | |
|------------------|---------|---------|------|
| Pus: | Nil | | |
| RBC | Nil | 0-5/hpf | /hpf |
| Epithelial Cells | Absent | | |
| Yeast Cells | Absent | | |
| Vegetable Matter | Present | | |
| Neutral Fat | Absent | | |
| Starch Granules | Absent | | |
| Trophozoite | Absent | | |
| Ova: | Absent | | |
| Cysts: | Absent | | |

30/01/2023
 Report Status:Final

* END OF REPORT *

CHECKED BY : 1058662
 717880



Dr. HARDIK KOSHTI
 MD PATHOLOGY,
 CONSULTANT

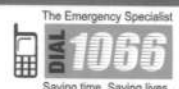Printed On : 30-JAN-2023 03:42:12 PM

For Enquiry/Appointments Contact +91 76988 15003 / +91 79 66701880

Apollo Hospitals International Limited
 Plot No -1A, Bhat, G.D.C. Gandhinagar, Gujarat - 382428, India.
 Phone : +91 79 66701800 | Fax No. : +91 79 66701843
 E-mail : info@apolloahd.com | www.ahmedabad.apollohospitals.com

Apollo Hospitals - City Centre (NON NABH-JCI)
 1, TulsiBaag Society, Nr. Parimal Garden, Ahmedabad.
 Phone : +91 79 66305800 / 01 or +91 76988 15148
 E-mail : infoahcc@apolloahd.com

Regd. Office
 19, Bishop Gardens, R.A. Puram, Chennai - 600 028
 CIN No. : U85110TN1997PLC039016 | GSTIn : 24AACBA4150H225
 For online appointment : www.askapollo.com



For online appointment : www.askapollo.com
 Keep the records carefully and bring them along during your next visit to our Hospital

Saving time. Saving lives.



Organization is Accredited
by Joint Commission International

DEPARTMENT OF BLOOD BANK



Name : Mr. RANJEET KUMAR Age : 35Yr 11Mth 12Days Gender : Male
 UHID : AHCC.0000126851 / AHCCA4355 W/BNo/RefNo : AHC
 SIN/LRN : 3713260 \ 1593011
 Specimen : Blood
 Ref Doctor : Mr. AHC DOCTOR



Collected on : 30-JAN-2023 09:06:13 AM Received on : 30-JAN-2023 04:42:07 PM Reported on : 30-JAN-2023 07:22:46 PM

MEDIWHEEL-FULL BODY CHK-BELOW40-MALE

| TEST NAME | RESULT |
|--|------------|
| BLOOD GROUPING AND TYPING (ABO and Rh) | |
| BLOOD GROUP: | O Positive |
| Report Status:Final | |

* END OF REPORT *

CHECKED BY : 1235263
717844



Printed On : 31-JAN-2023 01:47:10 PM

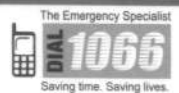Dr. SANJAY GUPTA
MBBS, DIHBT,
CONSULTANT, BLOOD BANK

For Enquiry/Appointments Contact +91 76988 15003 / +91 79 66701880

Apollo Hospitals International Limited
 Plot No.-1A, Bhat, GIDC, Gandhinagar, Gujarat - 382428, India.
 Phone : +91 79 66701800 | Fax No. : +91 79 66701843
 E-mail : info@apolloahd.com | www.ahmedabad.apollohospitals.com

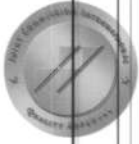Apollo Hospitals - City Centre (NON NABH-JCI)
 1, TulsiBaag Society, Nr. Parimal Garden, Ahmedabad.
 Phone : +91 79 66305800 / 01 or +91 76988 15148
 E-mail : infoahcc@apolloahd.com

Regd. Office
 19, Bishop Gardens, R.A. Puram, Chennai - 600 028
 CIN No. : U85110TN1997PLC039016 | GSTin : 24AABCA4150H225
 For online appointment : www.askapollo.com



For online appointment : www.askapollo.com
Keep the records carefully and bring them along during your next visit to our Hospital


Saving time. Saving lives.



Organization is Accredited
by Joint Commission International



DEPARTMENT OF RADIOLOGY AND IMAGING SCIENCES

Patient Details : Mr. RANJEET KUMAR | Male | 35Yr 11Mth 12Days
UHID : AHCC.0000126851 **Patient Location:** AHC
Patient Identifier: AHCCA4355 
DRN : 223004831 **Completed on :** 30-JAN-2023 09:26
Ref Doctor : Mr. AHC DOCTOR

USG WHOLE ABDOMEN

IMPRESSION

Liver appears normal in size and shows uniform normal echotexture. No evidence of focal or diffuse pathology seen. Intra and extra hepatic biliary radicals are not dilated. Portal vein is normal in caliber. Intrahepatic portal radicals appear normal.

Gall bladder appears normal with no evidence of calculus. Wall thickness appears normal. No evidence of pericholecystic collection.

Visualized pancreas appear normal in size and echotexture. No focal lesions identified. Visualize pancreatic duct appears normal in caliber.

Spleen is normal in size and shows uniform echotexture.

Both kidneys are normal in size and show normal echopattern with good corticomedullary differentiation. Cortical outlines appear smooth. No evidence of calculi. Pelvicalyceal system on both sides appears normal.

No evidence of ascites or significant lymphadenopathy. Visualized bowel loops are unremarkable.

Urinary bladder is normal in contour and outline. Wall thickness appears normal. No evidence of any intraluminal pathology seen.

Prostate (volume 16 cc) is normal in size and echopattern.

IMPRESSION:

No significant abnormality.

Printed on : 30-Jan-2023 11:26

Printed By : 1232062

Reported By : 717876

Page 1 of 2

For Enquiry/Appointments Contact +91 76988 15003 / +91 79 66701880



Organization is Accredited
by Joint Commission International



Mr. RANJEET KUMAR

AHCC.0000126851

AHCCA4355

USG WHOLE ABDOMEN

--- END OF THE REPORT ---

T.V. Parikh

TIRTH VINAYKUMAR PARIKH

Printed on : 30-Jan-2023 11:26

Printed By : 1232062

Reported By : 717876

Page 2 of 2

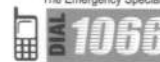For Enquiry/Appointments Contact +91 76988 15003 / +91 79 66701880

Apollo Hospitals International Limited
Plot No.-1A, Bhat, SIDC, Gandhinagar, Gujarat - 382428, India.
Phone : +91 79 66701800 | Fax No. : +91 79 66701843
E-mail : info@apolloahd.com | www.ahmedabad.apollohospitals.com

Apollo Hospitals - City Centre (NON NABH-JCI)
1, TulsiBaag Society, Nr. Panimal Garden, Ahmedabad
Phone : +91 79 66305800 / 01 or +91 76988 15148
E-mail : infoahcc@apolloahd.com

Regd. Office
19, Bishop Gardens, R.A. Puram, Chennai - 600 028
CIN No. : U85110TN1997PLC039016 | GSTIn : 24AABCA4150H225
For online appointment : www.askapollo.com

The Emergency Specialist



Saving time. Saving lives.


For online appointment : www.askapollo.com
Keep the records carefully and bring them along during your next visit to our Hospital



Organization is Accredited
by Joint Commission International



DEPARTMENT OF RADIOLOGY AND IMAGING SCIENCES

Patient Details : Mr. RANJEET KUMAR | Male | 35Yr 11Mth 12Days
UHID : AHCC.0000126851 **Patient Location:** AHC
Patient Identifier: AHCCA4355 
DRN : 123012000 **Completed on :** 30-JAN-2023 08:50
Ref Doctor : Mr. AHC DOCTOR

X-RAY CHEST PA


FINDINGS :

Both lung fields appear normal. No evidence of consolidation or collapse.
 Bilateral hilar shadows appear normal. Trachea and major bronchi appear normal.
 Cardiothoracic ratio is normal.
 Both costophrenic angles are clear. Domes of diaphragm are well delineated.
 Visualized bony thorax appear normal.

IMPRESSION

NORMAL STUDY.

— END OF THE REPORT —



TIRTH VINAYKUMAR PARIKH

Printed on : 30-Jan-2023 11:26 Printed By : 1232062 Reported By : 717876 Page 1 of 1

For Enquiry/Appointments Contact +91 76988 15003 / +91 79 66701880

Apollo Hospitals International Limited
 Plot No.-1A, Bhat, GIDC, Gandhinagar, Gujarat - 382428, India.
 Phone : +91 79 66701800 | Fax No. : +91 79 66701843
 E-mail : info@apolloahd.com | www.ahmedabad.apollohospitals.com

Apollo Hospitals - City Centre (NON NASH-JCI)
 1, Tulsibaug Society, Nr. Parimal Garden, Ahmedabad.
 Phone : +91 79 66305800 / 01 or +91 76988 15148
 E-mail : infoahcc@apolloahd.com

Regd. Office
 19, Bishop Gardens, R.A. Puram, Chennai - 600 028
 CIN No. : U85110TN1997PLC039016 | GSTin : 24AABCA4150H225
 For online appointment : www.askapollo.com

The Emergency Specialist



Saving time. Saving lives.

For online appointment : www.askapollo.com
 Keep the records carefully and bring them along during your next visit to our Hospital

Copy ID: Name:

years

1100 Sinus rhythm
4038 Nonspecific ST elevation [ST elevation (I, II)]

Sex: Birth date:

mmHg

kg

Medications:

Symptoms:

History:

| | | |
|---------------|-----------|-----|
| Vent. rate | 58 | bpm |
| PR int | 190 | ms |
| QRS dur | 94 | ms |
| QT/QTc(E) int | 366/362 | ms |
| P/QRS/T axis | 34/59/21 | ° |
| RV5/SV1 amp | 1.03/0.57 | mV |
| RV5+SV1 amp | 1.61 | mV |

AHCC.0000126851
 MR. RANJEET KUMAR
 Age: 35Year(s) Year(s)/Male
 30 Jan 2023 8:38:20 AM

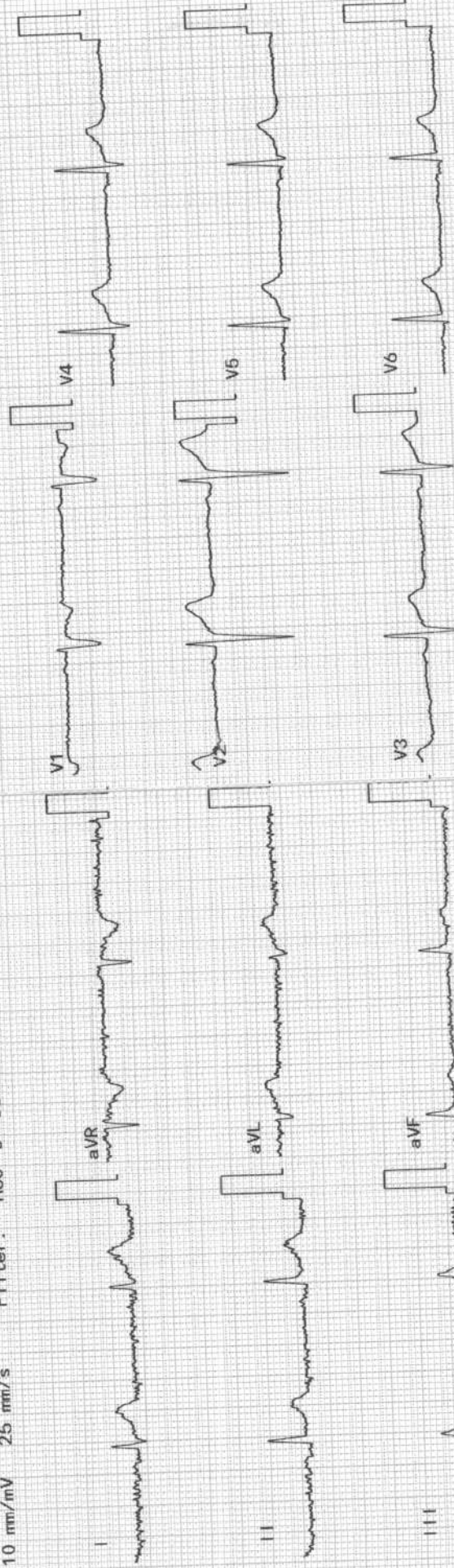


Unconfirmed Report
 Reviewed by:

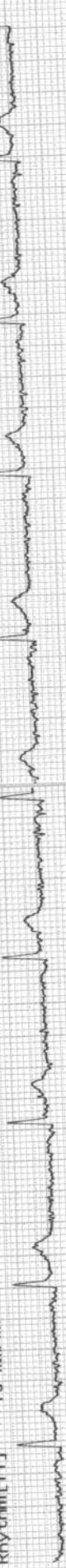
10 mm/mV

10 mm/mV

10 mm/mV 25 mm/s Filter: H50 D 35 Hz 10 mm/mV



Rhythm[11] 10 mm/mV




Exam:

2350K 03-10 07-01 Dept.:



AHCC.0000126851
 MR. RANJEET KUMAR
 Age: 35 Year(s) Year(s)/Male
 30 Jan 2023 8:38:21 AM



ELECTROCARDIOGRAM REPORT

Name: _____ Age/Sex: _____ Date: _____
 Ref. By: _____ ECG No. _____ UHID/IP: _____

Referral Diagnosis:

Atria - Rate:

Rhythm:

Axis:

PR Interval:

P Wave:

Voltage:

Q Wave:

S-T Changes:

Final Impression: *Non specific T wave changes.*

Reported By:

Ventricular Rate:

QRS:

QTc:

| | | | | | |
|-----|-----|----|----|----|----|
| | V4R | V1 | V2 | V5 | V6 |
| R/S | | | | | |



*Caution: Please get the ECG photocopied for future reference.

EYE CHECK UP

NAME Ranjeet kumar

Date 30/11/23

VA $\left\{ \begin{array}{l} R - 6/9 \\ W - 6/6 \end{array} \right\} \text{E.S.I}$

flo

BCVA(Distance & Near)

RE BG - 2-0 96

LE

Colour Vision

$\left\{ \begin{array}{l} BG \\ MAD \end{array} \right\}$

Advice:

Anterior Segment

Fundus

Advice:



Diagnosis

Checked By



DENTISTRY

Name : Date : 30/01/23 Unit No. :
 Occupation : Ref. Physician :
 Age : Sex : Male Female Copies to :

DENTAL RECORD

ALLERGIES :

PAIN : Score (0-10) _____ Location : _____ Character : _____

DENTAL CLEANING HABIT Once Twice Occasionally
 Brush Finger Stick Any other
 Tooth Paste Powder Any other

DO THE GUMS BLEED WHEN YOU BRUSH YOUR TEETH? Yes No

ARE YOUR TEETH SENSITIVE TO HEAT / COLD? Yes No

ORAL HYGIENE Good Fair Poor

| ORAL TISSUE EXAMINATION | PERIODONTAL EXAMINATION | OCCLUSION |
|-------------------------------|--|-----------------------------|
| NORMAL FINDINGS IN DISEASE | MILD MOD SEV | CLASS I II III CROSSBITE |
| Lips : | Gingivitis <input checked="" type="checkbox"/> <input type="checkbox"/> <input type="checkbox"/> | Hypoplasia |
| Cheeks : | Calculus <input checked="" type="checkbox"/> <input type="checkbox"/> <input type="checkbox"/> | Impaction |
| Tongue : | Recession <input type="checkbox"/> <input type="checkbox"/> <input type="checkbox"/> | Non-vital |
| Floor of the mouth : | Periodontal Pockets <input type="checkbox"/> <input type="checkbox"/> <input type="checkbox"/> | Fracture |
| Palate : | Attrition <input type="checkbox"/> <input type="checkbox"/> <input type="checkbox"/> | Abcess |
| Tonsillar Area : | Erosion <input type="checkbox"/> <input type="checkbox"/> <input type="checkbox"/> | Ulcers |
| Any other : | Mobility <input type="checkbox"/> <input type="checkbox"/> <input type="checkbox"/> | Caries <u>6/6.</u> |
| | | Missing Teeth |
| | | Supernumerary |
| | | Others |

PRESENT COMPLAINT :

PRE-MEDICAL HISTORY: DM HTN Thyroid Acidity Pregnancy
 Anticoagulant Under Drug Therapy

APOLLO HOSPITAL - CITY CENTER

OPP. DOCTOR HOUSE, ELLISBRIDGE, AHMEDABAD

Mr. MR RANJEET KUMAR
 Age/Sex : 35/M
 Ref by : MEDIWHEEL
 Indication1 : CVS EVALUATIO
 Indication2 : TECH. JAYESH N SHAH
 Indication3 :

ID : 126851
 H/Wt : 165/72
 Recorded : 30-1-2023 9:22

TREADMILL TEST SUMMARY REPORT
 Protocol: BRUCE PROCTOCAL
 History: Routine Check Up.
 Medication1 : NIL
 Medication2 : NIL
 Medication3 : NIL

| PHASE | PHASE TIME | STAGE TIME | SPEED (Km./Hr.) | GRADE (%) | H.R. (BPM) | B.P. (mmHg) | RPP X100 | II | ST LEVEL (mm) V2 | V5 | METS |
|-----------|------------|------------|-----------------|-----------|------------|-------------|----------|------|------------------|------|-------|
| SUPINE | | | | | 60 | 120/80 | 72 | 1.8 | 1.1 | 0.8 | |
| STAGE 1 | 2:59 | 2:59 | 2.70 | 10.00 | 85 | 122/82 | 103 | 1.6 | 1.2 | 0.7 | 4.80 |
| STAGE 2 | 5:59 | 2:59 | 5.40 | 14.00 | 102 | 128/84 | 130 | 1.6 | 1.8 | 1.0 | 7.10 |
| STAGE 3 | 8:59 | 2:59 | 7.40 | 18.00 | 171 | 134/86 | 229 | -0.1 | 2.4 | -0.3 | 10.00 |
| STAGE 4 | 9:29 | 0:29 | 9.70 | 22.00 | 179 | 146/88 | 261 | -0.3 | 2.5 | -0.5 | 10.65 |
| PEAK EXER | 9:30 | 0:30 | | | 180 | 146/88 | 262 | -0.1 | 2.5 | -0.3 | 10.67 |
| RECOVERY | 2:59 | 2:59 | 0.00 | 0.00 | 100 | 136/86 | 136 | 1.5 | 1.7 | 1.3 | |

RESULTS

Exercise Duration : 9:30 Minutes
 Max Heart Rate : 180 bpm 97 % of target heart rate 185 bpm
 Max Blood Pressure : 146/88 mmHg
 Max Work Load : 10.67 METS
 Reason of Termination :

IMPRESSIONS

- TEST IS NEGATIVE AT HIGH WORK LOAD.
- NO ANGINA OR ARRHYTHMIA PROVOKED.
- NORMAL HEAMODYNAMIC RESPONSE.
- NO GALLOP OR MURMUR HEART AT PEAK EXERCISE.
- TEST TERMINATED DUE TO THR ACHIEVED.
- GOOD EFFORT TOLERANCE.

Z.M. Barot
 DR ZEEL M. BAROT