

HEALTH CHECKUP REPORT

Patient Name: MRS. SANGITA PATEL

DATE: 24/09/2022

Age/Gender: 28/F

Reg. No: 384154

Package: MEDIWHEEL

COMPLAINTS (IF ANY):

- Asymptomatic

HISTORY OF HEALTH STATUS: No

PRESENT MEDICATIONS: No

HYPERSENSITIVITY TO ANY DRUG: No

PERSONAL HISTORY:

- Bowel : Regular
- Micturition : Normal
- Sleep : Adequate
- Appetite : Adequate

Diet : Veg
Habits : No
Physical Activity/Exercise: Walking

HISTORY OF ILLNESS (WITH PAST MEDICATIONS):

- LMP – 1 WEEK

FAMILY HISTORY: NO

VITAL SIGNS:

- Height : 147 cms
- Weight : 48Kgs

Pulse : 84/min.
B.P: 109/67mmHg



CIMS Hospital Private Limited

PHYSICIAN CONSULTATION:

1) Clinical Impression

- Reports within normal limit

2) Recommendations

- No active treatment
- Healthy life style

(Dr. rashmi chovatia)

GYNEC CONSULTATION:

M/H: PMP-

LMP: 15 day

O/H: - AML -

G P2 L2 A - 1 FTND

H/O: TL

P/H : Any other surgeries -

O/E: P/A - Soft

P/S - Cx. NAD

P/V - UT, AV, NS, FMR, Fx. Clear

Adv: USG Pelvis/TVS

Mammography

Pap Smear

} Follow up with reports

(Dr. DEVANG PATEL)

Please take regular medicine as prescribed by the Doctor. (If given)



Reg. No : CIMS/A/2022/384154	VisitNo : HC/240922/10 [HCV]
Patient Name : Mrs. SANGITABEN PATEL	Age(Y-M-D)/Sex : 27 Y 10 M 28 D. / Female
Referring Doctor : Dr. CIMS DOCTOR	Doctor :
Ward/Room :	Bed :

ORD/240922/291 Lab No : 2022145130 LSN : 920930 (Whole Blood) Sample Quality : Normal
 Collection Time : 24/09/2022 8:45:46 Arrival : 24/09/2022 9:06:46 Validation Time : 24/09/2022 11:43:34AM

	Result	Unit	Reference Range
CBC With ESR			
TOTAL COUNT			
Hemoglobin <i>(SLS Hemoglobin Detection method)</i>	12.5	g/dl	12.5 - 16.0 g/dl
Total RBC Count <i>(Hydro Dynamic Focusing Method)</i>	4.2	mill/Cmm	4.2 - 5.4 mill/Cmm
HCT <i>(Hydro Dynamic Focusing Method)</i>	37.9	%	37 - 47 %
Total WBC Count <i>(Flow Cytometry)</i>	5500	/Cmm	4000 - 10500 /Cmm
Platelet Count <i>(Hydro Dynamic Focusing Method)</i>	269000	/Cmm	150000 - 450000 /Cmm
DIFFERENTIAL COUNT (by Flow Cytometry)			
Polymorphs	57	%	40 - 70 %
Lymphocytes	33	%	22 - 45 %
Eosinophils	05	%	01 - 04 %
Monocytes	05	%	01 - 06 %
Basophils	00	%	00 - 01 %
Immature Granulocytes	00	%	0 - 2 %
Smear Study	RBCs are Normochromic & Normocytic. Platelets are adequate in number. Malarial Parasites are not seen. No Premature cells are seen.		
BLOOD INDICES (by Calculated Method)			
M.C.V	90.2	fl	78 - 100 fl
M.C.H	29.8	pg	27 - 31 pg
M.C.H.C.	33	gm/dl	32 - 36 gm/dl
RDW-CV	11.9	%	11.5 - 14.0 %
ESR (Red Cell Aggregation)			


Dr. Kazumi Gondalia
 M.D. (Path)
 Consultant Pathologist
 Reg. No. : G-21729

Dr. Manisha Shah
 MD (Path & Bact)
 Consultant Pathologist
 Reg. No. : G-15496

Dr. Jitendra Nayak
 MD (Path)
 Consultant Pathologist
 Reg. No. : G-14786

Print By : ankita.rajput

Print Date/Time : 24/09/2022 12:02:05



Reg. No	: CIMS/A/2022/384154	VisitNo :	HC/240922/10 [HCV]
Patient Name	: Mrs. SANGITABEN PATEL	Age(Y-M-D)/Sex	: 27 Y 10 M 28 D. / Female
Referring Doctor	: Dr. CIMS DOCTOR	Doctor	:
Ward/Room	:	Bed	:

ORD/240922/291 Lab No : 2022145130 LSN : 920930 (Whole Blood) Sample Quality : Normal
Collection Time : 24/09/2022 8:45:46 Arrival : 24/09/2022 9:06:46 Validation Time : 24/09/2022 11:43:34AM

After One Hour 03 mm 0 - 12 mm

Blood Group Rh
ABO "A"
Rh POSITIVE

HbA1c (Glycosylated Haemoglobin)

TEST

HbA1c (Glyco Hb) 5.67 % 4.8-5.9% Normal
Immuno Turbidimetric
5.9-7.0% Good diabetic control
7.0-10.0% Fair diabetic control
>10.0% Poor diabetic control

Mean Plasma Glucose 124.6 mg/dL 80 - 140 mg/dL

*** END OF REPORT ***



**Dr. Kazumi Gondalia
M.D. (Path)
Consultant Pathologist
Reg. No. : G-21729**

Dr. Manisha Shah
MD (Path & Bact)
Consultant Pathologist
Reg. No. : G-15496

Dr. Jitendra Nayak
MD (Path)
Consultant Pathologist
Reg. No. : G-14786
Print By: ankita.rajput

Print Date/Time: 24/09/2022 12:02:06

Page 2 of 2
CIMS (USA)




OUR ACCREDITATIONS

CIMS Hospital Private Limited

Reg. No : CIMS/A/2022/384154	VisitNo : HC/240922/10 [HCV]
Patient Name : Mrs. SANGITABEN PATEL	Age(Y-M-D)/Sex : 27 Y 10 M 28 D. / Female
Referring Doctor : Dr. CIMS DOCTOR	Doctor :
Ward/Room :	Bed :
ORD/240922/291 Lab No : 2022145131 LSN : 920930 (SERUM)	Sample Quality : Normal
Collection Time : 24/09/2022 8:45:46	Arrival : 24/09/2022 9:06:46 Validation Time : 24/09/2022 10:59:13AM

Liver Function Test

	<u>Result</u>	<u>Unit</u>	<u>Reference Range</u>
Alkaline Phosphatase (PNPP, AMP Buffer Method, Colorimetric)	24.1	U/L	35 - 104 U/L
Billirubin			
Total Billirubin (Diazospecial Iazonium iron with Blank)	1.21	mg/dL	0.0 - 1.0 mg/dL
Direct Billirubin (Diazospecial (Evelyn Malloy) with Blank)	0.38	mg/dL	0.0 - 0.2 mg/dL
Indirect Billirubin (Calculated from Total and Direct Billirubin)	0.83	mg/dL	0.0 - 0.8 mg/dL
SGPT (ALT) (IFCC without pyridoxal phosphate)	25.3	U/L	0 - 33 U/L
SGOT (AST) (IFCC without pyridoxal 5 phosphate)	17.3	U/L	0 - 32 U/L
Total Protein			
Total Proteins (Biuret Method)	7.21	gm/dl	6.4 - 8.3 gm/dl
Albumin (Bromocresol Green Colorimetric)	4.72	gm/dl	3.97 - 4.95 gm/dl
Globulin	2.49	gm/dl	2.2 - 3.5 gm/dl
A/G Ratio	1.9		0.9 - 2.1


Dr. Kazumi Gondalia
M.D. (Path)
Consultant Pathologist
Reg. No. : G-21729

Dr. Manisha Shah
MD (Path & Bact)
Consultant Pathologist
Reg. No. : G-15496

Dr. Jitendra Nayak
MD (Path)
Consultant Pathologist
Reg. No. : G-14786

Print By : ankita.rajput

Print Date/Time : 24/09/2022 12:02:32



Page 1 of 2

CIMS Hospital Private Limited


Plot No 67/1, Opp. Panchamrut Bungalows, Near Shukan Mall, Off Science City Road, Sola, Ahmedabad - 380060, Gujarat
© 1800 309 9999 CIN No. U8510GJ2001PTC039962

Reg. No : CIMS/A/2022/384154	VisitNo : HC/240922/10 [HCV]
Patient Name : Mrs. SANGITABEN PATEL	Age(Y-M-D)/Sex : 27 Y 10 M 28 D. / Female
Referring Doctor : Dr. CIMS DOCTOR	Doctor :
Ward/Room :	Bed :

ORD/240922/291 Lab No : 2022145131 LSN : 920930 (SERUM) Sample Quality : Normal
Collection Time : 24/09/2022 8:45:46 Arrival : 24/09/2022 9:06:46 Validation Time : 24/09/2022 10:59:12AM

	Result	Unit	Reference Range
Creatinine (Buffered Jaffe Reaction Kinetic Compensated)	0.58	mg/dL	0.5 - 0.9 mg/dL
Estimated GFR	110.4	mL/min/1.73m2	72 - 110 mL/min/1.73m2
Fasting Glucose (Hexokinase)	96.4	mg/dL	70 - 100 mg/dL
Thyroid Function Test			
TOTAL T3 (T3) * (Electrochemiluminescence Assay)	1.12	ng/ml	0.846 - 2.02 ng/ml
TOTAL T4 (T4) * (Electrochemiluminescence Assay)	7.71	µgm/dl	5.13 - 14.06 µgm/dl
TSH (Electrochemiluminescence Assay)	1.28	µIU/ml	0.27 - 4.20 µIU/ml
Uric Acid (Uricase Colorimetric Enzymatic)	2.24	mg/dL	2.4 - 5.7 mg/dL

*** END OF REPORT ***


Dr. Kazumi Gondalia
M.D. (Path)
Consultant Pathologist
Reg. No. : G-21729

Dr. Manisha Shah
MD (Path & Bact)
Consultant Pathologist
Reg. No. : G-15496

Dr. Jitendra Nayak
MD (Path)
Consultant Pathologist
Reg. No. : G-14786
Print By : ankita.rajput

Print Date/Time : 24/09/2022 12:02:32



OUR ACCREDITATIONS


CIMS Hospital Private Limited

Plot No 67/1, Opp. Panchamrut Bunglows, Near Shukan Mall, Off Science City Road, Sola, Ahmedabad - 380060, Gujarat
© 1800 309 9999 CIN No. U85110GJ2001PTC039962

Reg. No : CIMS/A/2022/384154	VisitNo : HC/240922/10 [HCV]
Patient Name : Mrs. SANGITABEN PATEL	Age(Y-M-D)/Sex : 27 Y 10 M 28 D. / Female
Referring Doctor : Dr. CIMS DOCTOR	Doctor :
Ward/Room :	Bed :

ORD/240922/291 Lab No : 2022145131 LSN : 920930 (SERUM) Sample Quality : Normal
 Collection : 24/09/2022 8:45:46AM Arrival: 24/09/2022 9:09:08 Validation Time: 24/09/2022 10:50:24

<u>Lipid Profile (With Direct LDL)</u>	<u>Result</u>	<u>Unit</u>	<u>Reference Range</u>
Type of Sample	: Fasting	.	
Cholesterol (Enzymatic/Colorimetric, Cholesterol Oxidase, Esterase, Peroxidase Gen.2)	: 158.4	mg/dL	Less than 160 mg/dl Excellent Less than 200 mg/dl Desirable 200-239 mg/dl Borderline High 240 mg/dl & over High
Triglyceride (Enzymatic Colorimetric without Glycerol Blank without Serum Blank)	: 52.2	mg/dL	Less than 150 mg/dl Normal 150 - 199 mg/dl Borderline High 200-499 mg/dl High 500 mg/dl or greater Very High
H D L Cholesterol (Direct Measured Homogenous Technique Modified Enzymatic Colorimetric Gen. 3)	: 53.3	mg/dL	Less than 40 mg/dl Low 60 mg/dl or above Excellent
L D L Cholesterol (DIRECT) (Homogenous Enzymatic colorimetric Assay)	: 102.5	mg/dL	Less than 80 mg/dl Excellent Less than 100 mg/dl Optimal 100 - 129 mg/dl Near or above optimal 130 - 159 mg/dl Borderline High 160 - 189 mg/dl High 190 mg/dl & above Very High
VLDL Cholesterol (Calculated)	: 10.44	mg/dL	15 - 30 mg%
Cholesterol/HDL Ratio (Calculated)	: 2.97		Normal upto 4.5


Dr. Kazumi Gondalia
 M.D. (Path)
 Consultant Pathologist
 Reg. No. : G-21729

Dr. Manisha Shah
 MD (Path & Bact)
 Consultant Pathologist
 Reg. No. : G-15496

Dr. Jitendra Nayak
 Print By: MD (Path) Ankita Rajput
 Consultant Pathologist
 Reg. No. : G-14786

Print Date/Time: 24/09/2022 12:03:20PM

Page 1 of 2



CIMS Hospital Private Limited

Plot No 67/1, Opp. Panchamrut Bunglows, Near Shukan Mall, Off Science City Road, Sola, Ahmedabad - 380060, Gujarat
 © 1800 309 9999 CIN No. U8510GJ2001PTC039962

Reg. No : CIMS/A/2022/384154	VisitNo : HC/240922/10 [HCV]
Patient Name : Mrs. SANGITABEN PATEL	Age(Y-M-D)/Sex : 27 Y 10 M 28 D. / Female
Referring Doctor : Dr. CIMS DOCTOR	Doctor :
Ward/Room :	Bed :

ORD/240922/291 Lab No : 2022145131 LSN : 920930 (SERUM) Sample Quality : Normal
Collection : 24/09/2022 8:45:46AM Arrival: 24/09/2022 9:09:08 Validation Time: 24/09/2022 10:50:24

LDL/HDL Ratio : 1.92 Less than 3.5
(Calculated)

Remarks :

*** END OF REPORT ***


Dr. Kazumi Gondalia
M.D. (Path)
Consultant Pathologist
Reg. No. : G-21729

Dr. Manisha Shah
MD (Path & Bact)
Consultant-Pathologist
Reg. No. : G-15496

Dr. Jitendra Nayak
MD (Path)
Consultant Pathologist
ankita.rajput
Reg. No. : G-14786

Print Date/Time: 24/09/2022 12:03:21PM

Page 2 of 2



JCI (USA)

NABH

QMS ACCREDITATIONS

CIMS Hospital Private Limited

Reg. No	: CIMS/A/2022/384154	VisitNo :	: HC/240922/10 [HCV]
Patient Name	: Mrs. SANGITABEN PATEL	Age(Y-M-D)/Sex	: 27 Y 10 M 28 D. / Female
Referring Doctor	: Dr. CIMS DOCTOR	Doctor	:
Ward/Room	:	Bed	:

ORD/240922/291 Lab No : 2022145133 LSN :920930 (Urine) Sample Quality : Normal
 Collection Time :24/09/2022 8:45:46 Arrival : 24/09/2022 9:06:46 Validation Time: 24/09/2022 11:51:43AM

	<u>Result</u>	<u>Unit</u>	<u>Reference Range</u>
Urine R & M			
PHYSICAL EXAMINATION			
Quantity	20 cc		
Colour	Pale Yellow		
Transparency	Clear		
Reaction	7.0		
(QDS-10 Strip)			
Sp. Gravity	1.015		1.005 - 1.035
(QDS-10 Strip)			
CHEMICAL EXAMINATION			
U. Albumin	Nil		
(QDS-10 Strip/Manual)			
U. Glucose	Nil		
(QDS-10 Strip/Manual)			
U. Acetone	Absent		
(QDS-10 Strip/Manual)			
BS/BP	Absent		
(QDS-10 Strip/Manual)			
MICROSCOPIC EXAMINATION			
Pus Cell	Occasional	/H.P.F.	/H.P.F.
Red Blood Cell	Nil	/H.P.F.	/H.P.F.
Epithelial Cell	1-2	/H.P.F.	/H.P.F.
Cast	Not Seen		
Crystals	Not Seen		
Amorphous	Absent		
Monilia	Absent		
*** END OF REPORT ***			


Dr. Kazumi Gondalia
M.D. (Path)
Consultant Pathologist
Reg. No. : G-21729

Dr. Manisha Shah
 MD (Path & Bact)
 Consultant Pathologist
 Reg. No. : G-15496

Dr. Jitendra Nayak
 MD (Path)
 Consultant Pathologist
 Reg. No. : G-14786

Print By: ankita.rajput

Print Date/Time: 24/09/2022 12:03:06



CIMS Hospital Private Limited

Name : Miss SANGITABEN PATEL

Reg No : CIMS/A/2022/384154
DoB/Sex: 26/10/1994 / Female**ECHO Report**

Dt : 24/09/2022

Patient Details

Patient ID 318228
Name Miss SANGITABEN PATEL
Age 27 Years
Gender Female
Blood Group
Referral Doctor

ECHO Identification Detail

Doctor Incharge Dr. VIPUL KAPOOR
Clinical Status Of Patient
ECHO Code RP
Finding Description

1. Normal sized LA, LV, RA, RV.
2. Normal LV systolic function, LVEF: 60%.
3. No RWMA.
4. Normal LV diastolic function.
5. MV: AMVL long and redundant, other cardiac valves are structurally normal.
6. Trivial MR, Trivial TR, Trivial PR, No AR.
7. No PAH.
8. IAS/IVS: Intact.
9. No clot/vegetation/pericardial effusion.
10. No coarctation of aorta.

Dr. VIPUL KAPOOR



JCI (USA)

NABH

MC-3049

OUR ACCREDITATIONS

CIMS Hospital Private Limited

Plot No 67/1, Opposite Panchmirut Bunglows Near Shakun Mall, Off Science City Road, Sola, Ahmedabad, Gujarat 380060

1800 309 9999 CIN No. U85110GJ2001PTC039962

<http://victory/rptECHO.aspx?DiagnosticTestDetailID=302229&Print=Y>

24/09/2022

cims-hospital
Ahmedabad

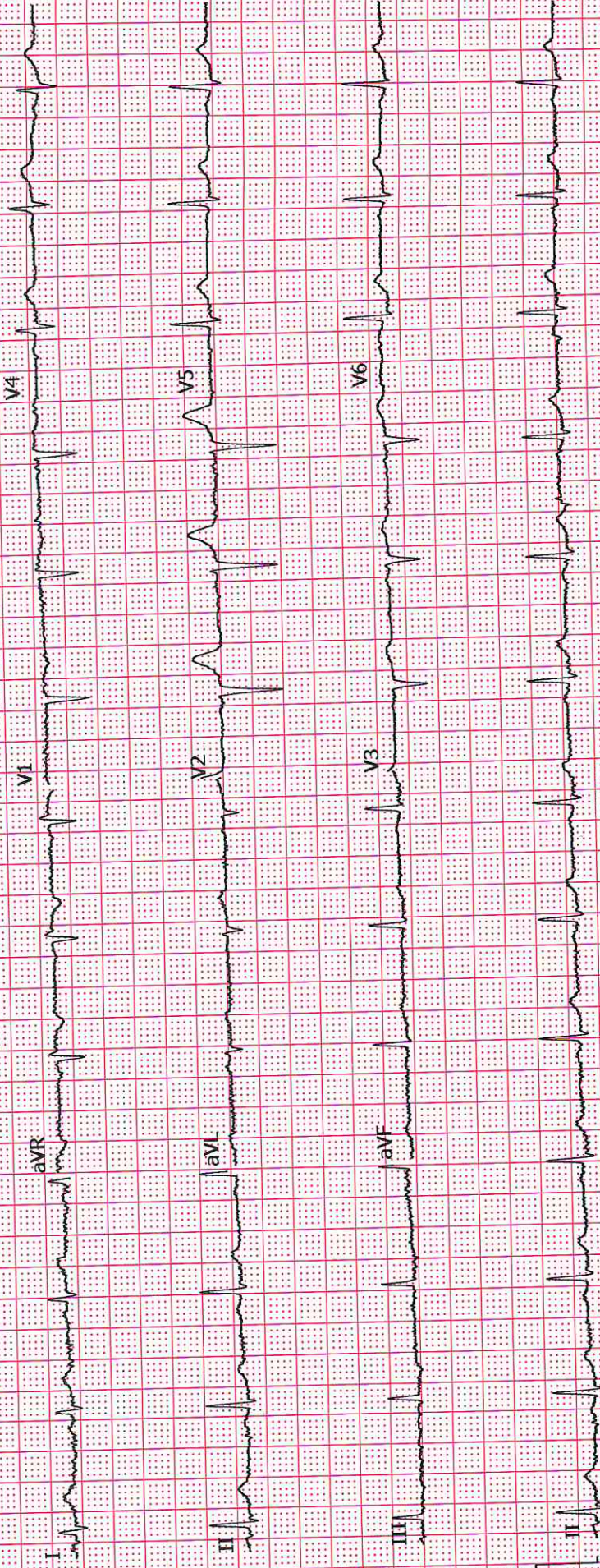
Indication:
Medication 1:
Medication 2:
Medication 3:

mmHg

Name : Miss SANGITABEN PATEL
Reg No : CIMS/A/2022/38415
DoB / Sex : 26/10/1994 / F : male

QRS : 70 ms
QT / QTc Baz : 340 / 384 ms
PR : 128 ms
P : 90 ms
RR / PP : 774 / 779 ms
P / QRS / T : 31 / 83 / 24 degrees

NSR | 60 bpm



MAC2000	1.1	12SL™ V241	25 mm/s	10 mm/mV	ADS	0.56-40 HZ	50 Hz	4x2.5x3_25_R1	Unconfirmed	/1/1
---------	-----	------------	---------	----------	-----	------------	-------	---------------	-------------	------

Patient's Name :SANGITABEN PATEL	Age, Sex :28Y/F
Reg. No. (IP/OP):HC-384154	Date :24/09/2022
Referred By Dr. :CIMS	

USG OF ABDOMEN & PELVIS

LIVER: Liver is normal in size and echotexture. No evidence of focal SOL or dilatation of IHBR seen. Porta hepatis appear normal.

GALLBLADDER: Gallbladder appeared normal. No calculus or mass lesion seen.

PANCREAS: Visualised pancreas appeared normal in size and echotexture. No focal lesion, mass or pancreatitis.

SPLEEN: Spleen appears normal in size and echotexture.

PARAAORTIC REGION: Aorta grossly appeared normal. No paraaortic lymphnodes seen.

KIDNEYS: Both kidneys appear normal in size, shape and in position. Cortex and collecting system of both kidneys appeared normal. No evidence of calculus or obstructive uropathy on either side. Right kidney: 92x37mm. Left kidney: 100x41mm.

URINARY BLADDER: Bladder appeared normal. No calculus or mass lesion is seen.

UTERUS: Uterus appears normal in size and measures 82x28x42mm. Uterus shows homogenous endometrial and myometrial echotexture. Endometrial thickness appears normal and measures 6mm. No fibroid or GS seen.

OVARIES: Both ovaries appear normal. No adnexal mass lesion seen on either side. Right ovary: 24x14mm. Left ovary: 22x13mm.

No evidence of free fluid or collection is seen in peritoneal spaces. Normal small bowel peristalsis noted.

COMMENTS:

- No significant abnormality detected.



DR KIRTAN SHAH M.D. RADIODIAG. CONS. RADIOLOGIST
 DR DEEPA SHAH M.D., D.M.R.E CONS. RADIOLOGIST
 DR UMA MEHTA D.M.R.D. F.R.C.R D.M.R.D. (D.N.B.) CONS. RADIOLOGIST
 DR NIMISH SHARMA D.M.R.D. (D.N.B.) CONS. RADIOLOGIST
 DR RAVINA CHAUHAN M.D. RADIODIAG. CONS. RADIOLOGIST
 DR YASH PATEL M.D., D.N.B. CONS. RADIOLOGIST
 DR SUNALI DESAI MD, DNB, DM, FRCR CONS. RADIOLOGIST NEURORADIOLOGIST

Note: This is only a radiological impression and not the final diagnosis. All diagnostic modalities have their own limitations. Therefore radiological modality report should be interpreted in correlation with clinical and pathological findings..

FOR RADIOLOGY REPORTS ONLY



CIMS Hospital Private Limited

Patient's Name :SANGITABEN PATEL Age, Sex :28Y/F
Reg. No. (IP/OP):HC-384154 Date :24/09/2022
Referred By Dr. :CIMS

Plain Skiagram of Chest PA standing view:
(Serial No-5398)

Both lung fields appear normal.

No evidence of pleural effusion or pneumothorax is seen on either side.

Mediastinal shadow appears normal.

Heart and aorta appear normal.

Domes of diaphragm appear normal.

Bones under view appears normal.

Kindly correlate clinically



DR KIRTAN SHAH
M.D. RADIODIAG.
CONS. RADIOLOGIST

DR DEEPA SHAH
M.D., D.M.R.E
CONS. RADIOLOGIST

DR UMA MEHTA
D.M.R.D. F.R.C.R
CONS. RADIOLOGIST

DR NIMISH SHARMA
D.M.R.D. (D.N.B.)
CONS. RADIOLOGIST

DR VRUSHTI GANDHI
M.D. RADIODIAG.
CONS. RADIOLOGIST

DR RAVINA CHAUHAN
M.D. RADIODIAG.
CONS. RADIOLOGIST

Note: This is only a radiological impression and not the final diagnosis. All diagnostic modalities have their own limitations. Therefore radiological modality report should be interpreted in correlation with clinical and pathological findings.

FOR RADIOLOGY REPORTS ONLY



JCI (USA)



NABH

OUR ACCREDITATIONS

CIMS Hospital Private Limited

Plot No 67/1, Opp. Panchamrut Bunglows, Near Shukan Mall, Off Science City Road, Sola, Ahmedabad - 380060, Gujarat

© 1800 309 9999 CIN No. U85110GJ2001PTC039962