

Mouney

CHECK LIST

| | | |
|------------------|-----------------|-----------------|
| NAME | SRIRUPA BISHWAS | PATHOLOGY/PP |
| OP | | EKG/PFT |
| AGE | | ECHO/TMT |
| DATE | 28/1/23 | USG / CXR |
| PACKAGE | | URINE / STOOL |
| REFERRED BY | | MAMMO/ PAP |
| HT | 158.2" | EYE/ DENTAL |
| WT | 61 kg | GP CONSULTATION |
| BP | 130/80 | DIETITION |
| PULSE | 81 bpm | CARDIOLOGIST |
| WAIST | 92" | GYNECOLOGIST |
| HIP | 100" | DENTAL |
| RESPIRATORY RATE | | |
| CHEST (INHALE) | 99" | |
| CHEST (EXHALE) | 95" | |
| ABDOMEN | 91" | |

(41) (B)


 भारत सरकार
Government of India

 Srirupa Biswas
Year of Birth : 1976
Female




5092 8743 1530


आधार - आम आदमी का अधिकार


 भारतीय विशिष्ट पहचान प्राधिकरण
Unique Identification Authority of India

Address: W/O: Debabrata Biswas, 55/A,
Satyajit Roy, Sarani, Parnasree Pally,
Kolkata, Parnasree Pally, West Bengal,
700060

5092 8743 1530

 1800 300 1947

 help@uidai.gov.in

 www.uidai.gov.in

Srirupa Biswas
8250470930

DIAGNOSTICS REPORT


| | | | |
|--------------|--|-------------|-----------------------------|
| Patient Name | : Mrs. SRIRUPA BISWAS | Order Date | : 28/01/2023 09:51 |
| Age/Sex | : 45 Year(s)/Female | Report Date | : 28/01/2023 15:36 |
| UHID | : NMHK.2302130 | IP No | : |
| Ref. Doctor | : NMH | Facility | : NARAYAN MEMORIAL HOSPITAL |
| Address | : 55/A SATYAJIT ROY SARANI, BEHALA, Kolkata, West Bengal, 700060 | Mobile | : 8134923778 |

ELECTROCARDIOGRAM REPORT (ECG)

| | |
|-------------------|------------------------|
| HR | : 65 bpm |
| Rhythm | : Sinus |
| P wave | : Normal |
| PR Interval | : 152 msec |
| QRS axis | : Normal (23 Degree) |
| QRS duration | : 88 msec |
| QRS configuration | : Normal |
| T wave | : Non specific changes |
| ST segment | : Non specific changes |
| QTc | : 406 msec |
| QT | : 386 msec |

IMPRESSION:

- Sinus rhythm with sinus arrhythmia.
 - Normal QRS axis.
 - Non specific ST-T changes.
- Clinical correlation please.



Dr. SOUMYA KANTI DUTTA ,
MBBS,MD(GEN.MED),DM(CARDIOLOGY)

RegNo: 63887

IRIRUPA BISWAS

HR 65/min

Axis: P 35°

SINUS BRADYCARDIA
OTHERWISE NORMAL ECG

UNCONFIRMED REPORT

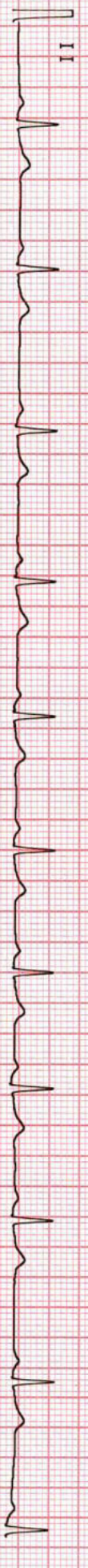
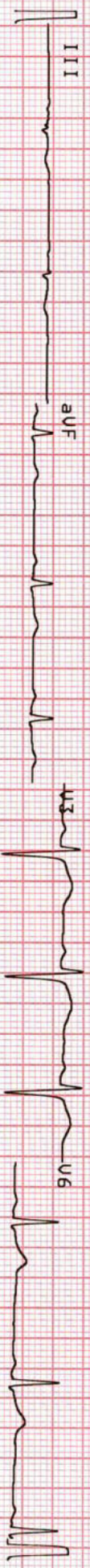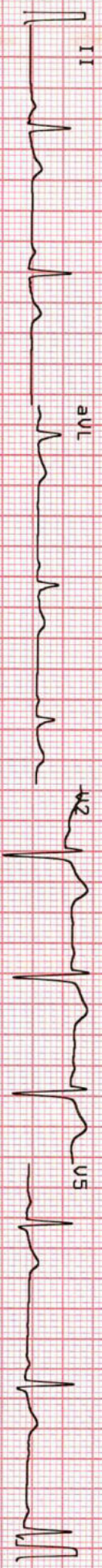
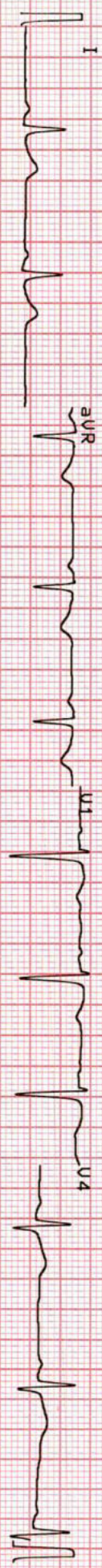
1302130

10 years Female

..... cm / kg

| | | | | | | | |
|------------|-----------|-----------|-----------|----------------|---------------------|----------------|----------------|
| Intervals: | RR 920 ms | PR 152 ms | QR5 88 ms | QT 386 ms | QTc 406 ms (Bazett) | | |
| Axis: | P 35° | QR5 23° | T 18° | P (II) 0.09 mV | S (V1) -1.17 mV | R (V5) 0.97 mV | Sokol. 2.14 mV |

10 mm/mV



10 mm/mV

15 mm/s

0.05-25 Hz FS50 SSF SBS

28.01.2023 11:38:00

NARAYAN MEMORIAL HOSPITAL, BEHRLA

AT-102plus 1.25 C



DIAGNOSTICS REPORT

| | | | |
|--------------|--|-------------|-----------------------------|
| Patient Name | : Mrs. SRIRUPA BISWAS | Order Date | : 28/01/2023 09:51 |
| Age/Sex | : 45 Year(s)/Female | Report Date | : 28/01/2023 15:42 |
| UHID | : NMHK.2302130 | IP No | : |
| Ref. Doctor | : NMH | Facility | : NARAYAN MEMORIAL HOSPITAL |
| Address | : 55/A SATYAJIT ROY SARANI, BEHALA, Kolkata, West Bengal, 700060 | Mobile | : 8134923778 |

ECHOCARDIOGRAPHY (SCREENING)

Status of Patient :

- * No regional wall motion abnormality at rest.
- * Good LV systolic function (EF = 62%).
- * Good RV systolic function (TAPSE = 23 mm).
- * Mild TR. TR gradient = 25 mmHg.
- * Normal valve morphology.
- * Adequate LV diastolic function.
- * No pericardial effusion.
- * No pulmonary arterial hypertension.
- * IVC normal diameter & > 50% respiratory variation.
- * No thrombus, mass, vegetation seen.

**Dr.INDIRA BANERJEE ,
MD,DNB,MRCPC (UK)**

Board Certified Comprehensive
Echocardiographer (USA)



DIAGNOSTICS REPORT

| | | | |
|--------------|--|-------------|-----------------------------|
| Patient Name | : Mrs. SRIRUPA BISWAS | Order Date | : 28/01/2023 09:51 |
| Age/Sex | : 45 Year(s)/Female | Report Date | : 29/01/2023 16:05 |
| UHID | : NMHK.2302130 | IP No | : |
| Ref. Doctor | : NMH | Facility | : NARAYAN MEMORIAL HOSPITAL |
| Address | : 55/A SATYAJIT ROY SARANI, BEHALA, Kolkata, West Bengal, 700060 | Mobile | : 8134923778 |

USG REPORT OF BREAST(SCREENING)

Both breasts were scanned quadrantwise using a high frequency probe.

Both breasts revealed normal parenchymal echotexture.

No obvious focal mass lesion seen.

No microcalcifications are seen.

A small hypoechoic lesion with lobulated margin is noted in right retroareolar region. It measures 16 mm x 10 mm approx.

No significant enlarged lymph nodes seen in either axillary region.

IMPRESSION : A small fibroadenoma in right retroareolar region.

Please correlate clinically.

Dr. MADHUSHREE RAY NASKAR,
MBBS, DMRD

Consultant Radiologist

RegNo: 57032



DIAGNOSTICS REPORT

| | | | |
|--------------|--|-------------|-----------------------------|
| Patient Name | : Mrs. SRIRUPA BISWAS | Order Date | : 28/01/2023 09:51 |
| Age/Sex | : 45 Year(s)/Female | Report Date | : 29/01/2023 16:11 |
| UHID | : NMHK.2302130 | IP No | : |
| Ref. Doctor | : NMH | Facility | : NARAYAN MEMORIAL HOSPITAL |
| Address | : 55/A SATYAJIT ROY SARANI, BEHALA, Kolkata, West Bengal, 700060 | Mobile | : 8134923778 |

USG REPORT OF WHOLE ABDOMEN (SCREENING)

LIVER : Liver is normal in size and parenchymal echotexture. Intrahepatic biliary radicles are not dilated. No focal mass lesion is seen.

PORTA :PV : Normal. PV measures 0.9 cm.

CD : Normal . CD measures 0.3 cm.

GALL BLADDER : Gall bladder is normal in size, contour, outline and position. No calculus is seen. Wall thickness is normal.

PANCREAS : Pancreas is normal in size and parenchymal echogenicity. Pancreatic duct is not dilated.

SPLEEN : Spleen is not enlarged and parenchyma shows normal homogeneous pattern.

KIDNEYS : Both kidneys are normal in size, shape, outline, position and parenchymal echogenicity. Cortico medullary differentiation maintained. No evidence of any calculus/ mass / hydronephrosis is seen. **A well defined clear cyst measuring (5.1 x 4.7) cm is noted in left kidney.** Right kidney measures : 10.0 cm & Left kidney measures : 10.4 cm.

URINARY BLADDER : Urinary bladder is normal in contour, outline and distension. No vesical lesion is seen.

UTERUS : Anteverted normal in size, shape, outline, position and parenchymal echogenicity. Cavity is empty. Uterus measures 8.2 cm x 4.8 cm x 3.7 cm.



DIAGNOSTICS REPORT

| | | | |
|--------------|--|-------------|-----------------------------|
| Patient Name | : Mrs. SRIRUPA BISWAS | Order Date | : 28/01/2023 09:51 |
| Age/Sex | : 45 Year(s)/Female | Report Date | : 29/01/2023 16:09 |
| UHID | : NMHK.2302130 | IP No | : |
| Ref. Doctor | : NMH | Facility | : NARAYAN MEMORIAL HOSPITAL |
| Address | : 55/A SATYAJIT ROY SARANI, BEHALA, Kolkata, West Bengal, 700060 | Mobile | : 8134923778 |

OVARIES : Both ovaries are normal in size, shape and echopattern. Right ovary : measures 2.3 cm x 1.0 cm. Left ovary : measures 2.3 cm x 1.2 cm.

PERITONEUM : :No free fluid is noted.

RETROPERITONEUM : IVC and aorta appear normal. No lymphadenopathy is seen.

IMPRESSION : A cortical cyst in left kidney.

Dr.MADHUSHREE RAY NASKAR,
MBBS,DMRD

Consultant Radiologist

RegNo: 57032