

Facilities:

All clinical Biomedical & Hematology Investigations including Bone Marrow Examination
VPT, Podiascan & Complete Foot Care (First Time in Purvanchal)
All Hormonal Investigation by Chemiluminescent Method
Visceral Fat by (AB-140) Ambulatory BP Monitoring
CGMS & Insulin Pump Available
PFT, 2D-ECHO (Color Doppler), Holter, TMT, Cardiac-3 available
VIA, VILI, Colposcopy available
Special Endocrinological Investigation Protocols.

ISO 9001:2008 Certified
Mobile: 9389994334, 9554572190, 9453837595



Panacea Pathology

Clinical Reference Lab

Persistence, Preparedness and Precision
EQAS (CMC Vellore Attached) & IQAS System
पूर्वांचल की सर्वोत्तम गुणवत्ता वाली पैथोलॉजी

PATIENT NAME : RANJANA SINGH

AGE/GENDER : 32 YRS/FEMALE

REFD BY DR. : ARCO FEMI HEALTHCARE LTD.

RECEIVED DATE : 23-01-2023 (10:00AM)

SAMPLE : BLOOD & URINE

REPORT DATE : 23-01-2023 (17:00PM)

PATHOLOGY REPORT

COMPLETE BLOOD COUNT (CBC)

TEST	LAB TEST VALUES	NORMAL RANGE
HEMOGRAM		
HEMOGLOBIN (FLOW CYTOMETRY)	13.6	13 – 16 gm/dl
TOTAL LEUCOCYTE COUNT (TLC)	4,900	4000 – 11000
RBC COUNT	4.63	3.5 – 5.5
PCV (HCT)	41.3	37 – 47
MCV	89.2	80 – 95
MCH	29.3	28 – 34
MCHC	32.8	30 – 36
PLATELET COUNT	1,86,000	1,50,000 – 4,00,000
E.S.R. (WINTROBE FIRST HOURS)	22.0	20 mm/1 st hr
DIFFERENTIAL LEUCOCYTE		
NEUTROPHILS	58	40 – 75%
LYMPHOCYTES	36	20 – 45%
EOSINOPHILS	03	1 – 6%
MONOCYTES	03	2 – 8%
BASOPHILS	00	< 2%

RENAL & KIDNEY PROFILE, SERUM

TEST	LAB TEST VALUES	NORMAL RANGE
RENAL FUNCTION TESTS		
BLOOD UREA NITROGEN (BUN)	18.6	10 – 50 mg/dl
SERUM CREATININE	0.81	0.60 – 1.60 mg/dl
URIC ACID	4.16	3.60 – 7.70 mg/dl
ALKALINE PHOSPHATASE (ALP)	82.0	142 – 353 mg/dl
TOTAL PROTIENS	7.2	0 – 39 mg/dl
ALBUMIN	4.0	3.8 – 5.4 mg/dl
SERUM GLOBULIN	3.2	2.1 – 3.5 mg/dl
CALCIUM	9.0	8.80 – 10.20
PHOSPHORUS	3.04	2.50 – 5.00
SERUM SODIUM NA+	1.005	135.00 – 155.00 mEq/Ltr
SERUM POTASIUM K+	4.12	3.60 – 5.50 mEq/Ltr
ICALCIUM	1.22	1.10 – 1.35 mmol/L
SERUM CHLORIDE CL+	101.3	98.00 – 110.00 mEq/Ltr

PAGE 1

Lab Technician

PANACEA HOSPITAL
UNIT OF AAROH HEALTH CARE PVT. LTD.,
REG. NO. PAL-1500
B.36/44, B-4, KABIR NAGAR
M.D., Pathology

Timing : 8.00 a.m. to 9.00 p.m. (Sunday 8.00 a.m. to 3.00 p.m.)

This Report is not valid for medico legal purpose

Note: These tests have technical limitations. Clinico-pathological interpretation is necessary. In case of any disparity test may be repeated immediately.

Address : 36/44 FK Kabir Nagar, Durgakund, Varanasi – 221005

Email: dramishra@gmail.com, drpallaviojha@gmail.com Website: panaceahospital.org

Facilities:

All clinical Biomedical & Hematology Investigations including Bone Marrow Examination
VPT, Podiascan & Complete Foot Care (First Time in Purvanchal)
All Hormonal Investigation by Chemiluminescent Method
Visceral Fat by (AB-140) Ambulatory BP Monitoring
CGMS & Insulin Pump Available
PFT, 2D-ECHO (Color Doppler), Holter, TMT, Cardiac-3 available
VIA, VILI, Colposcopy available
Special Endocrinological Investigation Protocols.

ISO 9001:2008 Certified
Mobile: 9389994334, 9554572190, 9453837595



Panacea Pathology

Clinical Reference Lab

Persistence, Preparedness and Precision
EQAS (CMC Vellore Attached) & IQAS System
पूर्वाचल की सर्वोत्तम गुणवत्ता वाली पैथोलॉजी

PATIENT NAME : RANJANA SINGH

AGE/GENDER : 32 YRS/FEMALE

REFD BY DR. : ARCO FEMI HEALTHCARE LTD.

RECEIVED DATE : 23-01-2023 (10:00AM)

SAMPLE : BLOOD & URINE

REPORT DATE : 23-01-2023 (17:00PM)

PATHOLOGY REPORT

LIPID PROFILE, SERUM

TEST	LAB TEST VALUES	NORMAL RANGE
BLOOD CHEMISTRY		
TOTAL CHOLESTEROL (SERUM)	165.0	Desirable:- < 200 mg/dl Borderline:- 200 – 239 mg/dl High:- & gt; 240 mg/dl
TRIGLYCERIDES (SERUM)	142.0	35 – 170 mg/dl
HDL CHOLESTEROL (SERUM)	43.0	35.30 – 79.50 mg/dl
LDL CHOLESTEROL (SERUM)	93.6	& lt; 130 mg/dl
VLDL	28.4	& lt; 40 mg/dl

BLOOD GROUP

TEST	LAB TEST VALUES
BLOOD GROUP ABO & RH FACTOR	
BLOOD GROUP	"A"
RH FACTOR	POSITIVE

GLYCOSYLATED HEMOGLOBIN (HBA1C)

TEST	LAB TEST VALUES	NORMAL RANGE
HBA1C	5.2	Normal : <5.97 % Good Control : 5.97 – 6.81% Fair Control : 6.81 – 7.65% Poor Control : >7.65%

THYROID PROFILE (T3, T4, TSH)

TEST	LAB TEST VALUES	NORMAL RANGE
THYROID FUNCTION TEST		
T3	1.10	0.60 – 1.81 ng/ml
T4	7.50	4.50 – 10.90 ug/dl
TSH	3.70	0.39 – 6.10 uIU/mL

PAGE 2

Lab Technician

PANACEA HOSPITAL
UNIT OF AAROH HEALTH CARE PVT. LTD.)
REG. NO.: AL-1500
B-4/ KABIR NAGAR
M.D., Pathology

Timing : 8.00 a.m. to 9.00 p.m. (Sunday 8.00 a.m. to 3.00 p.m.)

This Report is not valid for medico legal purpose

Note: These tests have technical limitations. Clinico-pathological interpretation is necessary. In case of any disparity test may be repeated immediately.

Address : 36/44 FK Kabir Nagar, Durgakund, Varanasi – 221005

Email: dramishra@gmail.com, drpallaviojha@gmail.com Website: panaceahospital.org

Facilities:

All clinical Biomedical & Hematology Investigations
including Bone Marrow Examination
VPT, Podiascan & Complete Foot Care (First Time in Purvanchal)
All Hormonal Investigation by Chemiluminescent Method
Visceral Fat by (AB-140) Ambulatory BP Monitoring
CGMS & Insulin Pump Available
PFT, 2D-ECHO (Color Doppler), Holter, TMT, Cardiac-3 available
VIA, VILI, Colposcopy available
Special Endocrinological Investigation Protocols.



Panacea Pathology

Clinical Reference Lab

Persistence, Preparedness and Precision
EQAS (CMC Vellore Attached) & IQAS System
पूर्वांचल की सर्वोत्तम गुणवत्ता वाली पैथोलॉजी

PATIENT NAME : RANJANA SINGH

AGE/GENDER : 32 YRS/FEMALE

REFD BY DR. : ARCO FEMI HEALTHCARE LTD.

RECEIVED DATE : 23-01-2023 (10:00AM)

SAMPLE : BLOOD & URINE

REPORT DATE : 23-01-2023 (17:00PM)

PATHOLOGY REPORT

LIVER PROFILE TEST, SERUM

TEST	LAB TEST VALUES	NORMAL RANGE
BIO CHEMISTRY		
TOTAL BILIRUBIN	0.70	0.0 – 1.1 mg/dl
DIRECT BILIRUBIN	0.25	0.0 – 0.2 mg/dl
INDIRECT BILIRUBIN	0.45	< 0.90 mg/dl
SGOT (AST)	26.5	0 – 52 mg/dl
SGPT (ALT)	22.0	0 – 39 mg/dl
GGT (GYT)	18.6	< 55 U/L

URINE ROUTINE EXAMINATION

TEST	LAB TEST VALUES	NORMAL RANGE
PHYSICAL EXAMINATION		
QUANTITY	29	ML
COLOUR	STRAW	PALE YELLOW
APPEARANCE	CLEAR	CLEAR
SPECIFIC GRAVITY	1.010	1.01 – 1.03
PH	5.5	4.7 – 7.5
CHEMICAL EXAMINATION		
GLUCOSE	Not Detected	Not Detected
PROTEIN	NIL	Not Detected
MICROSCOPIC EXAMINATION		
PUS CELLS	1-2	0-5
RBC	Not Detected	Not Detected
EPITHELIAL CELLS	1-2	0-5
CASTS	Not Detected	Not Detected
CRYSTALS	Not Detected	Not Detected
BACTERIA	Not Detected	Not Detected

FASTING/RANDOM BLOOD SUGER

TEST	LAB TEST VALUES	NORMAL RANGE
FBS/RANDOM		
FASTING BLOOD SUGER	110.0	90-110 mg/dl
RANDOM BLOOD SUGAR	125.0	125-140mg/dl

----- End of Report -----

Lab Technician

PANACEA HOSPITAL
UNIT OF AAROH HEALTH CARE RVT. LTD.)
REG. NO. AL-1500
36/44 B-4 KABIR NAGAR
M.D., Pathology

Timing : 8.00 a.m. to 9.00 p.m. (Sunday 8.00 a.m. to 3.00 p.m.)

This Report is not valid for medico legal purpose

Note: These tests have technical limitations. Clinico-pathological interpretation is necessary. In case of any disparity test may be repeated immediately.

Address : 36/44 FK Kabir Nagar, Durgakund, Varanasi – 221005

Email: dramishra@gmail.com, drpallaviojha@gmail.com Website: panaceahospital.org



PANACEA HOSPITAL

B 36/44 F.K KABIR NAGAR, DURGAKUND
TOLLFREE NO-18001233070.
Whatsapp No - 8795832852
www.piire.org



OP Slip

Print Date : 23-Jan-2023 09:44AM



UHID No :- UD-22230003380	OP No :- OP-22230012549	OP Date :- 23 Jan 2023 9:44AM
Patient Name :- Mrs RANJANA SINGH BANK OF BARODA	Age/Sex :- 32 Y/Female ✓	Mobile No :- 9004426657
Husband :- LATE SHAILESH KUMAR SINGH	Department :- DIABETES, ENDOCRINOLOGY & METABOLIC PHYSICIAN	
Pay Type :- Cash	Consultant :- Dr ASHUTOSH MISHRA (MD(MEDICINE), IMS, BHU)	
Token No :- NOR. - 1	Paid/Bal :- 0.00 /500.00	
Patient Type :- Normal		
Address :- SAMNEGHAT ,MARUTI NAGAR COLONY, LANKA, varanasi		

BP :- 110/70
height :- 154 (55kg)
Weight (kg) :- 76.1 (↑)
BMI :-

Rx F = 110 ← Pre-Diabetic
F = 75-80 ← 100 → 126

SpO₂ - 97
PR - 85
~~RBS - 94~~
RBS - 94

Rx exspine pherphly.

Tab. Normsul-MT. 1/2 M x 3
↓
1/3
↓
1/3

F = 110.
116 M/L = 5.7.

Es. Diabem (10) on
Es. Colum 1/2 on

Arved (60) M x 10 - 1/2 on 1/2 on

Diabetic diet 1400 kcal (a)

(ETRE) - MRT. (S.M.)

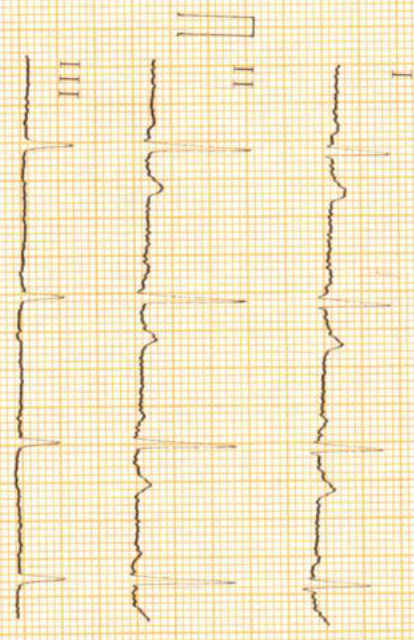
Printed By : Mr NITIN YADAV
Created By : Mr NITIN YADAV

R/A 2 months

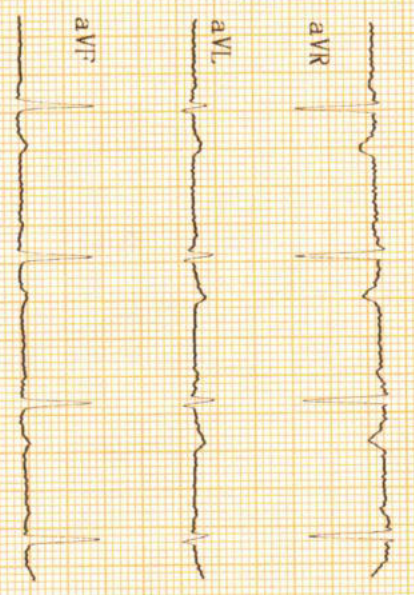
AUTO 10mm/mV

BPL

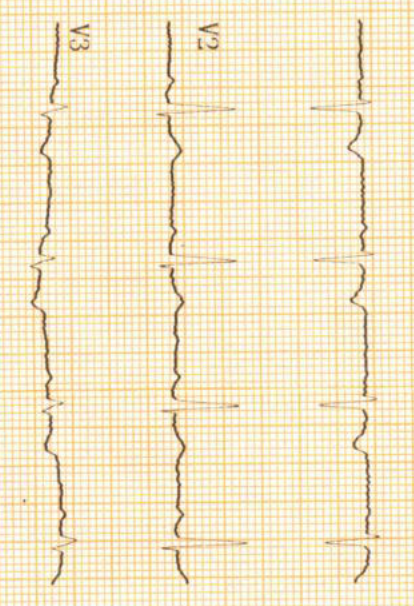
25mm/s ACS50Hz EMG35Hz



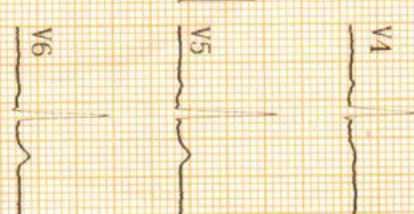
10mm/mV



10mm/mV
V1

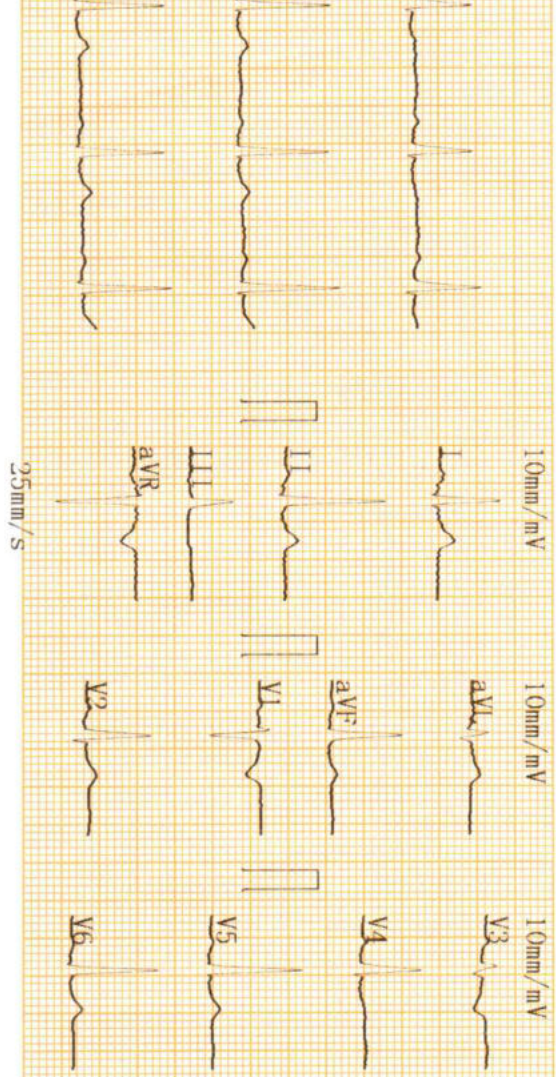


10mm/mV



CARDIART


Bp1



2023-01-23 11:22
 ID :
 Name :
 Sex :
 Height :
 SYS :
 DIA :
 HR : 78 bpm
 PR Interval : 162 ms
 P Duration : 118 ms
 QRS Duration : 75 ms
 T Duration : 175 ms
 QT/QTc : 314/357 ms
 P/QRS/T Axis : 24.4/55.3/19.3 deg
 R (V5) /S (V1) : 1.23/0.63 mV
 R (V5) /S (V1) : 1.87 mV

<< Conclusions >>

Normal Sinus Rhythm;
 Cardiac electric axis normal;
 III aVF V3 V4 V5 Abnormal T wave;
 Report need physician confirm

Physician 
DR. PALLAVI MISHRA
 MBBS, MD (GENERAL MEDICINE)
 MCI Reg. No. 50311



PANACEA HOSPITAL

A shelter for many hearts A Home for many lives

(An ISO 9001:2008 Certified Organisation)

Lab Attached with CMC Vellore Under EQAS Scheme

ame	MR.RANJANA SINGH	Sex /Age	32/F	Date	23/01/2023
ef. by	Dr.Pallavi Mishra(MD)	BSA - m ²		Echo window	fair

Echo - Cardiology

MITRAL VALVE Doppler	AML - normal morphology MV Flow - E - 0.9 A-0.6 E/A=1.30	PML - normal morphology MVA - 3.0 cm ² Mitral Regurgitation - No
TRICUSPID VALVE Doppler	Normal TV Flow -No	Tricuspid Regurgitation - No
PULMONARY VALVE Doppler	Normal PV Flow -No	Pulmonary Regurgitation - No
AORTIC VALVE Doppler	Trileaflet-No AV Flow - no	Aortic Regurgitation - no
MEASUREMENT	Aorta - 22.3 (20-38) mm IVS ed - 8.6 (6 -12) mm LVID ed - 37.1 (35 - 55) mm LVPW ed - 12.6 (6 -12) mm OA - 7 (> 5) mm	LA - 22.8 (24-32) mm IVS es -10.9 (6 - 12) mm LVID es - 26.3 (24 - 40) mm LVPW es - 11.4 (6 -12) mm EPSS - 6 (< 9) mm


CONCLUSION

All cardiac chamber dimensions are WNL
No valvular abnormalities
Good LV systolic function present Modified Simpson's method (4C, 2C) (LVEF-57%)
No diastolic dysfunction present (E/A = 1.30) by tissue Doppler (E/e'=6.2)
No RWMA
No pericardial effusion
Intact IAS / IV
No PAH
No intra cardiac mass /thrombus /vegetation

IMPRESSION

Normal Echocardiogram

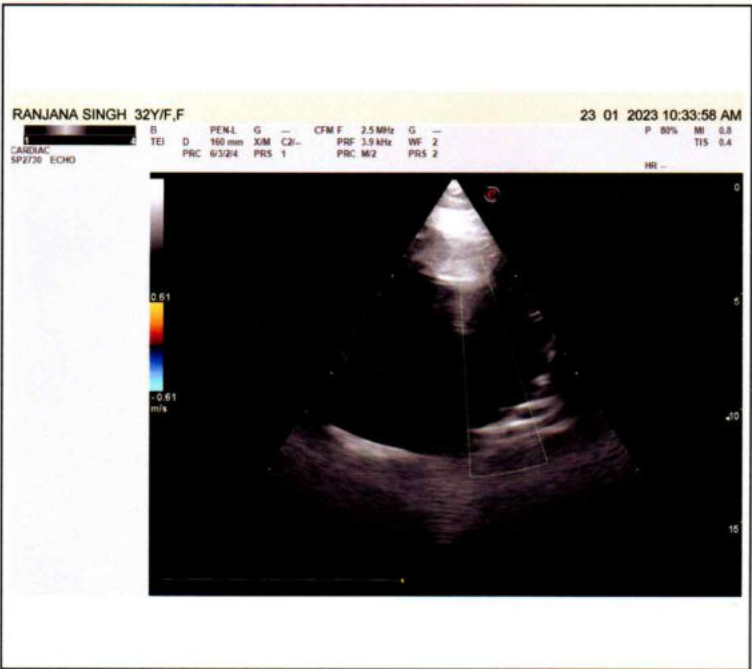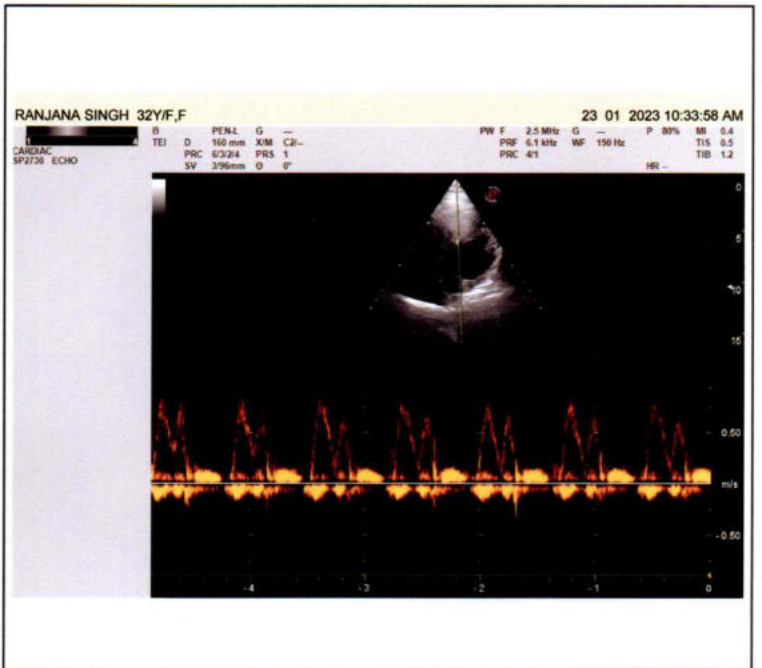
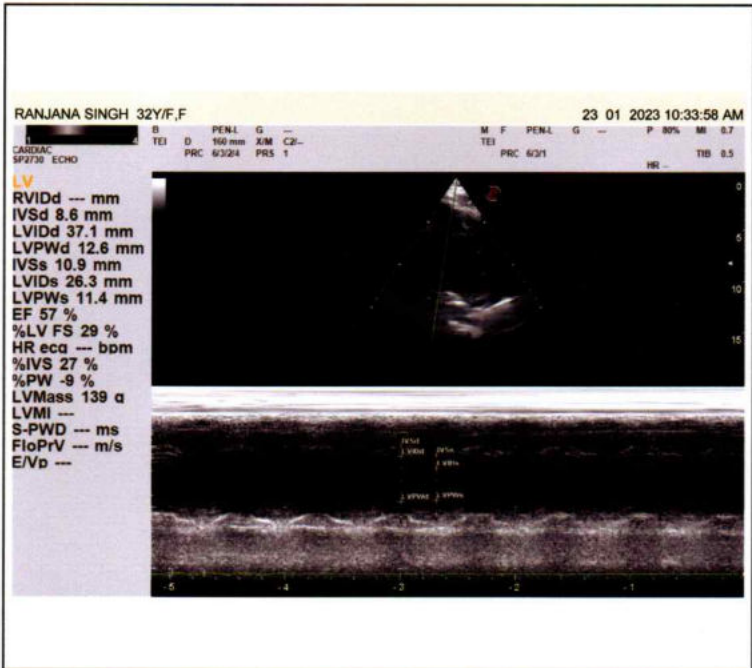
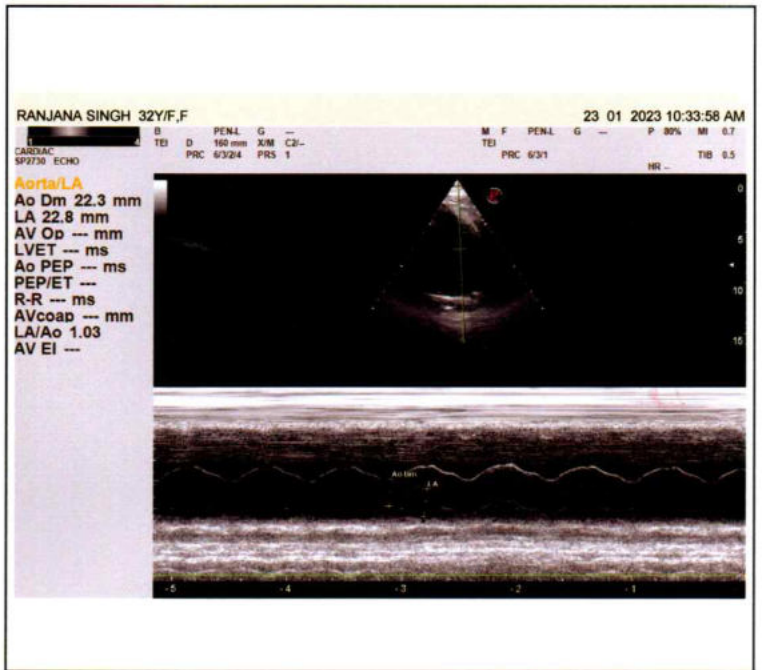
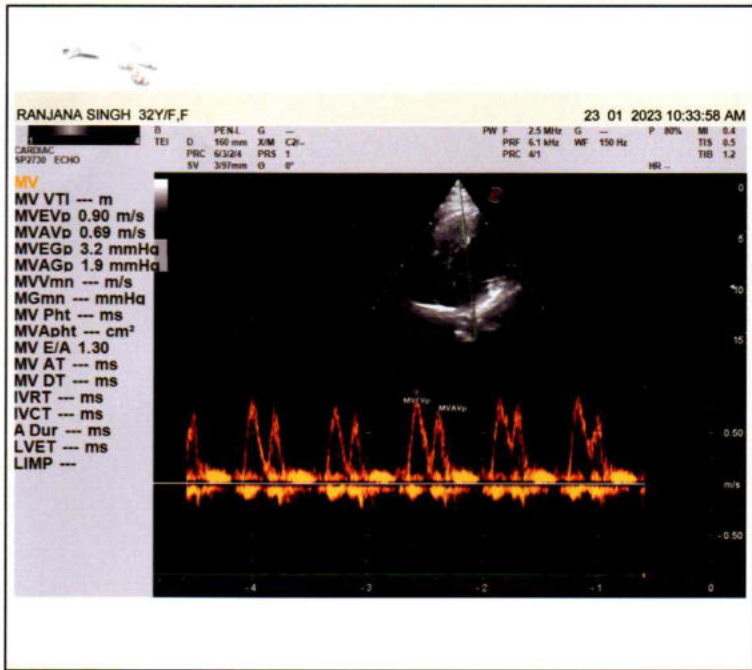

Niraj Mishra
Physician Assistant
(PIRE)

DR. PALLAVI MISHRA
MBBS, MD (GENERAL MEDICINE)
Reg. No. 52033

Dr. Pallavi Mishra
MBBS, MD (MED) Lucknow
Echocardiography Specialist, MIAE
Non-invasive cardiologist
Women Cardiologist
Diabetocardiologist

Address : Kabir Nagar (Near Sanjay Shiksha Niketan), Durgakund, Varanasi

Mobile : 9554572190 / 9453837595 / Recpn. 9389994334

E-mail : dramishra@gmail.com, drpallaviojha@gmail.com, Website: www.pire.org





PANACEA HOSPITAL

A shelter for many hearts A Home for many lives

(An ISO 9001:2008 Certified Organisation)

Lab Attached with CMC Vellore Under EQAS Scheme

NAME: MRS. RANJANA SINGH

AGE/SEX: 32 YRS / FEMALE

F BY: DR. ASHUTOSH MISHRA (MD)

DATE: 23/01/2022

ULTRA SOUND FOR ABDOMEN REPORT

- Liver:** Normal in shape and size(10.6cm) and shows smooth and regular margin.
No diffuse/focal lesion seen.
- Gall bladder** Normal distended with normal wall thickness and echo-free lumen.
- CBD** Visualized part normal in course & caliber.
- Pancreas:** Normal in size, shape & echogenicity.
Margins are smooth & regular.
No diffuse/ focal lesion seen. Pancreatic tail obscured.
- Spleen:** Normal in size(9.7 cm) shape & echogenicity.
Margins are smooth & regular. No diffuse / focal lesion seen.
Splenic vessels at hilum is normal.
- Kidney:** Right kidney: 8.9 X 4.5cm
Left kidney: 8.6 X 5.4 cm
Normal cortical echogenicity with well maintained Cortical-medullary differentiation.
Pelvicalyceal system normal.
No calculus/mass lesion seen.
No hydronephrosis/ hydroureter seen.

Address : Kabir Nagar (Near Sanjay Shiksha Niketan), Durgakund, Varanasi

Mobile : 9554572190 / 9453837595 / Recpn. 9389994334

E-mail : dramishra@gmail.com, drpallaviojha@gmail.com, Website: www.piire.org



Call Now - 1800-123-3070

PANACEA HOSPITAL

A shelter for many hearts A Home for many lives

(An ISO 9001:2008 Certified Organisation)

Lab Attached with CMC Vellore Under EQAS Scheme

Urinary bladder: Normally distended, wall thickness is normal.
No echogenic foci lumen or diverticula seen.
Both VUJ appears normal.
No E.R. calculus / mass lesion seen.

Uterus: Uterus normal in size shape, & echogenicity.
Margins are smooth & regular.
Endometrial thickness within normal limits.

Ovary: Right ovary normal in size and shows normal morphology.
Left ovary normal in size and shows normal morphology.

Others: No free fluid in peritoneal cavity.
No free fluid in bilateral pleural cavity.

IMPRESSION:

- NO SIGNIFICANT SONOLOGICAL ABNORMALITY DETECTED.

Please correlate clinically and further investigations.

DR. PALLAVI MISHRA
MBBS MD (GENERAL MEDICINE)
DR. PALLAVI MISHRA

MBBS MD(MED) Lucknow

Echocardiography specialist, MIAE

Non invasive cardiologist

Women cardiologist


Radiologist

Dr. Tusharika Rai
MBBS MS

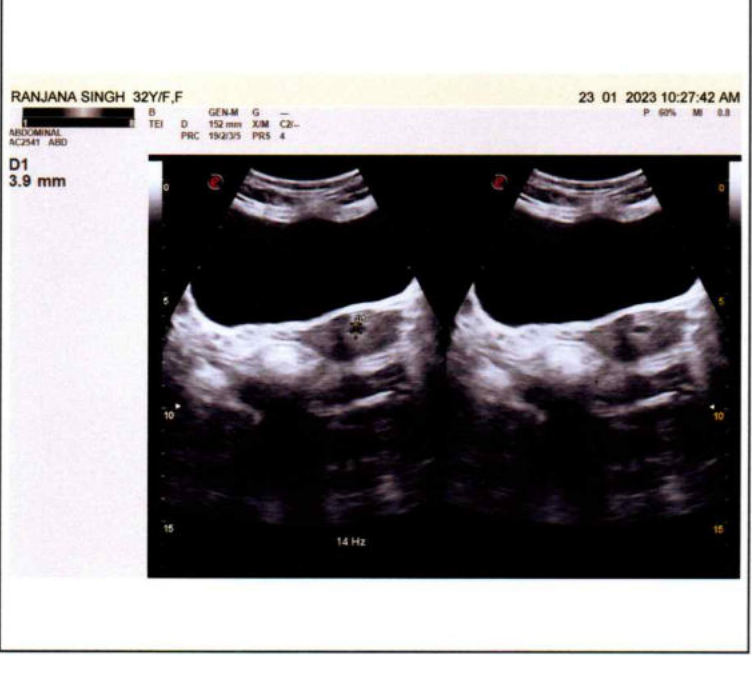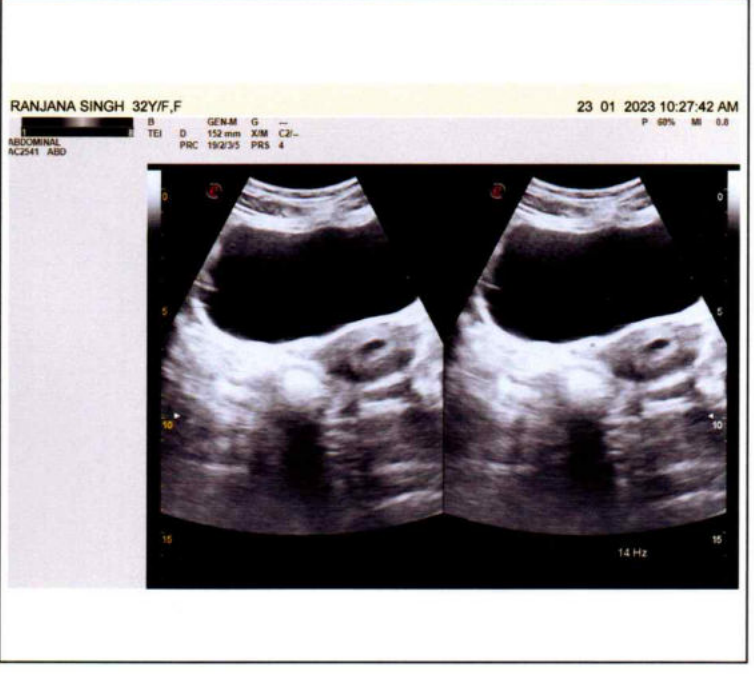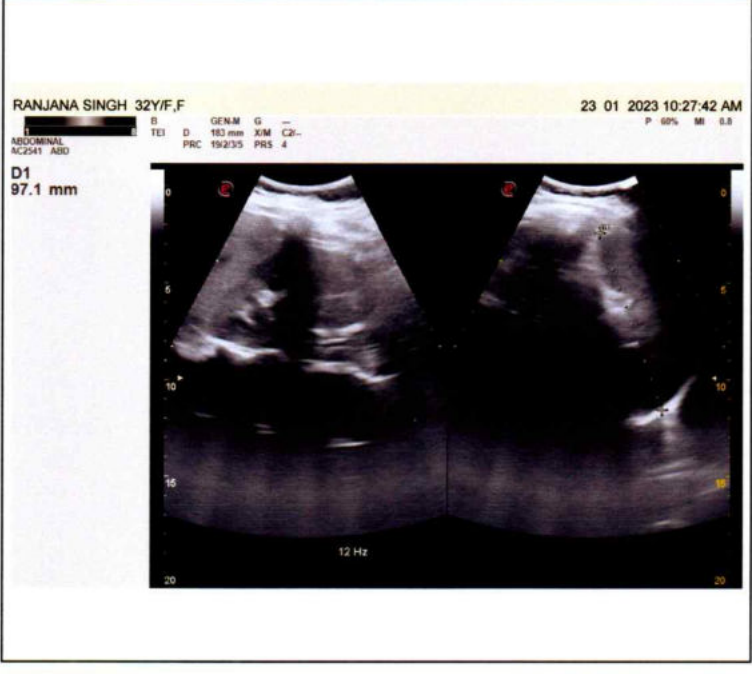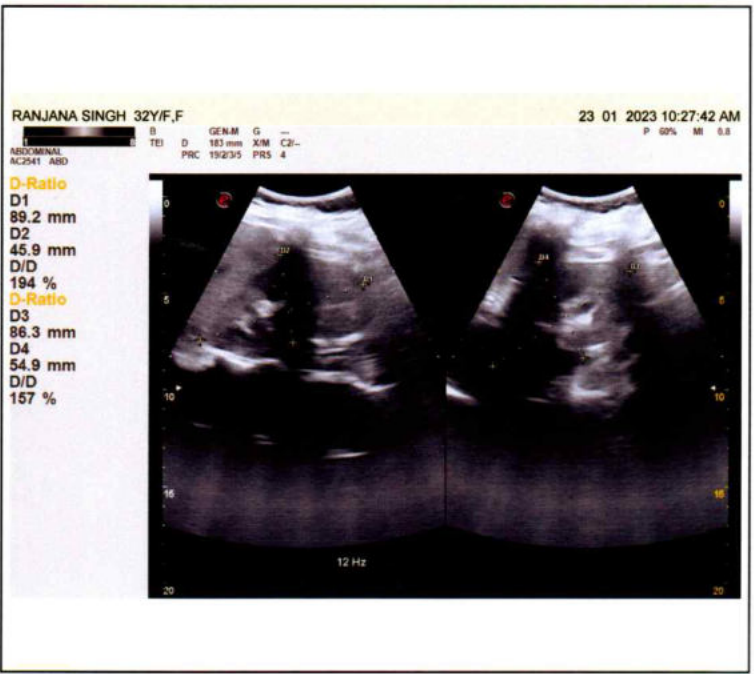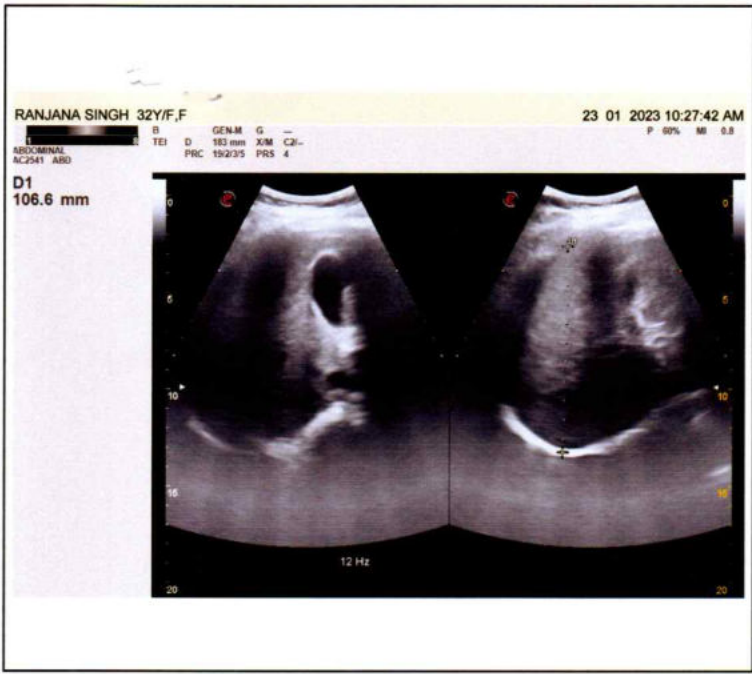
Note: (1) This report is not valid for medico-legal purposes.

(2) In case of any discrepancy due typing error, please get it Rectified immediately.

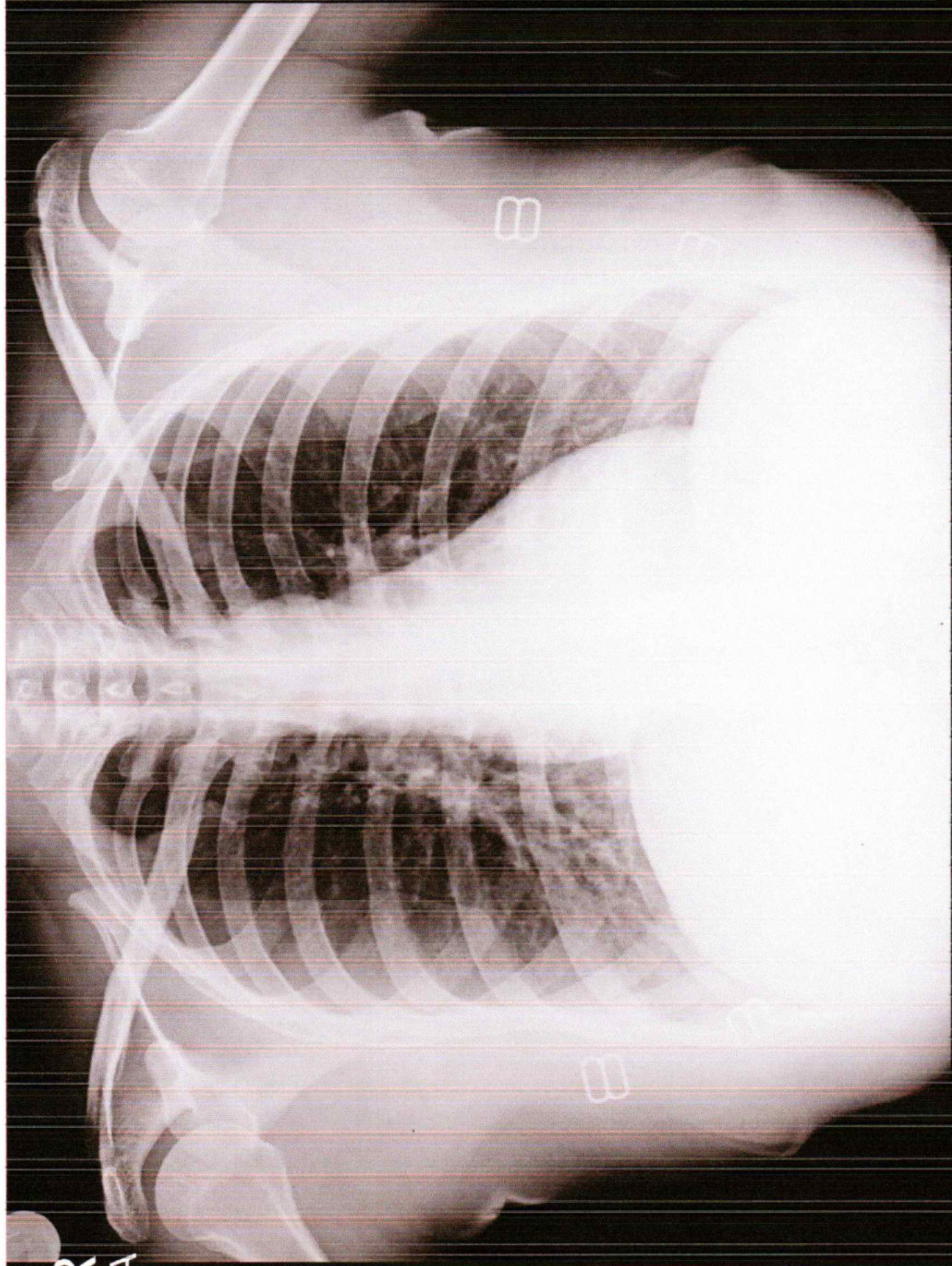
Address : Kabir Nagar (Near Sanjay Shiksha Niketan), Durgakund, Varanasi

Mobile : 9554572190 / 9453837595 / Recpn. 9389994334

E-mail : dramishra@gmail.com, drpallaviojha@gmail.com, Website: www.piire.org



R
PA



RANJANA SINGH 32Y/F 3380 O CHEST P.A. 23-Jan-23 09:57 AM

PANACEA HOSPITAL, KABIR NAGAR, DURGAKUND, VARANASI



PANACEA HOSPITAL

A shelter for many hearts A Home for many lives

(An ISO 9001:2008 Certified Organisation)
Lab Attached with CMC Vellore Under EQAS Scheme

NAME: MRS.RANJANA SINGH

AGE/SEX: 32 YRS / FEMALE

REF BY: DR.ASHUTOSH MISHRA(MD)

DATE: 23/01/2023

X-RAY CHEST PA

BOTH LUNG FIELDS AND PLEURAE:

Both lungs show normal bronchovascular pattern.

Right & left hila are normal

No focal mass or calcification is seen

There is no evidence of any fluid in the both the pleural cavities.

Both domes of diaphragms are normal in position.

MEDIASTINUM:

Trachea is central in position.

Cardiac silhouette is of normal size and configuration.

No evidence of pericardial effusion.

No significant lymphadenopathy is seen.

Visualized skeleton is normal.

NO SIGNIFICANT RADIOGRAPHIC ABNORMALITY

DR. ALPANA PATHAK
MD, RADIOLOGY
REG. NO. 46465

DR. ALPANA PATHAK
MBBS (HONS, GOLD MEDALIST) PMCH, PATNA
MD RADIODIAGNOSIS (GOLD MEDALIST) IMS BHU
EX-SR, IMS BHU, VARANASI

EX-SR, IMS BHU, VARANASI

Address : Kabir Nagar (Near Sanjay Shiksha Niketan), Durgakund, Varanasi

Mobile : 9554572190 / 9453837595 / Recpn. 9389994334

E-mail : dramishra@gmail.com, drpallaviojha@gmail.com, Website: www.piire.org