

Name : Mr. RAMESH N T

Age: 59 Y

Sex: M

UHID:CKOR.0000248310



OP Number:CKOROPV389785

Bill No :CKOR-OCR-79254

Date : 30.11.2023 08:58

Address : kml

 Plan : ARCOFEMI MEDIWHEEL MALE AHC CREDIT PAN
 INDIA OP AGREEMENT

Sl No	Service Type/ServiceName	Department
1	ARCOFEMI - MEDIWHEEL - FULL BODY ANNUAL PLUS ABOVE 50Y MALE - 2D ECHO - PAN INDIA - FY2324	
1	URINE GLUCOSE(FASTING)	
2	GAMMA GLUTAMYL TRANSFERASE (GGT)	
3	PROSTATIC SPECIFIC ANTIGEN (PSA TOTAL)	
4	HbA1c, GLYCATED HEMOGLOBIN	
5	2-D ECHO <i>R10</i>	
6	LIVER FUNCTION TEST (LFT)	
7	X-RAY CHEST PA <i>R11</i>	
8	GLUCOSE, FASTING	
9	HEMOGRAM + PERIPHERAL SMEAR	
10	ENT CONSULTATION <i>Dr. Jayane</i>	
11	FITNESS BY GENERAL PHYSICIAN	
12	DIET CONSULTATION	
13	COMPLETE URINE EXAMINATION	
14	URINE GLUCOSE(POST PRANDIAL)	
15	PERIPHERAL SMEAR	
16	ECG <i>R14</i>	
17	BLOOD GROUP ABO AND RH FACTOR	
18	LIPID PROFILE	
19	BODY MASS INDEX (BMI)	
20	OPHTHAL BY GENERAL PHYSICIAN	
21	RENAL PROFILE/RENAL FUNCTION TEST (RFT/KFT)	
22	ULTRASOUND - WHOLE ABDOMEN <i>R17 (2nd floor)</i>	
23	THYROID PROFILE (TOTAL T3, TOTAL T4, TSH)	
24	DENTAL CONSULTATION <i>R-NO-15</i>	
25	GLUCOSE, POST PRANDIAL (PP), 2 HOURS (POST MEAL)	

(15) Dental

 (20) Physio
 optal

 Height - 155cm
 weight - 54.6kg

NAME: MR. RAMESH N T

AGE: 59Y

SEX: MALE

DATE: 30/11/2023

ECHOCARDIOGRAPHY REPORT

MEASUREMENT

AO -25(20 - 35)mm	LIVD d - 42(36-52)mm	IVS - 10 (06 - 11)mm
LA -28(19- 40)mm	LVID s - 28(23- 39)mm	PWD - 11(06- 11)mm
EF - 60% (>50%)	RVID-22	

VALVES

Mitral Valve : Normal
Aortic Valve : Normal
Tricuspid Valve : Normal
Pulmonary Valve : Normal

CHAMBERS

Left Atrium : Normal
Right Atrium : Normal
Left Ventricle : Normal
Right Ventricle : Normal

SEPTAE

IVS : Intact
IAS : Intact

GREAT ARTERIES

Aorta : Normal

Pulmonary Artery : Normal

DOPPLER DATA

Mitral : E > A

Aortic : Normal

Tricuspid : Normal

Pulmonary : Normal

WALL MOTION ABNORMALITIES : No RWMA

Pericardium : Normal

FINAL DIAGNOSIS

**NORMAL CHAMBERS AND VALVES
NORMAL BIVENTRICULAR FUNCTION
NO RWMA AT REST, LV EF -60%**



DR. MOHAN MURALI
CONSULTANT
CARDIOLOGIST

DR. MAHABALESHWAR.M
MBBS.(MYS), MD(AIIMS DELHI)FICS
D.O (JIPMER)
REG.NO:KMC:9748

DATE: 25.11.23
OP NO:

THE APOLLO MEDICAL CENTER KORAMANGALA

NAME: Rameesh NT
AGE : 59
GENDER: M

OPHTHALMIC REPORT

RIGHT EYE

LEFT EYE

Rameesh

GENERAL APPEARANCE

VISION - DISTANCE

WITHOUT GLASS

WITH GLASS

GLASS POWER

6/60 / 6/60

NEAR

WITHOUT GLASS

WITH GLASS

GLASS POWER

no

no

COLOUR

- normal

ANTERIOR SEGMENT:-

D Pseudo phakia

both eyes

FUNDUS

I.O.P: DIGITAL

Ad Regular checkup

DOCTOR SIGNATURE

DR VIJAYA LAKSHMI M
M.B.B.S, D.L.O, D.N.B(ENT)
Phone No.9972044580,080-25633823/24/23

30/11/23

HEALTH CHECK- ENT

NAME: *Ramesh V.7* **P** **AGE:** *59*

EAR: **RE:** **LE:**

EXTERNAL EAR

MIDDLE EAR

INNER EAR (FN)

HEARING ASSESSMENT: **RE:** **LE:**

RHINNE

WEBER

ABC

NOSE

AIRWAY

SEPTUM

TURBINATES

OTHERS

NECK

NECK NODES

OTHER

AUDIOMETRY

THROAT

ORAL CAVITY

OROPHARYNX

PHARYNX

LARYNX

IMPRESSION

SIGNATURE:

Patient Name	: Mr. RAMESH N T	Age	: 59 Y M
UHID	: CKOR.0000248310	OP Visit No	: CKOROPV389785
Reported on	: 30-11-2023 11:36	Printed on	: 30-11-2023 13:56
Adm/Consult Doctor	:	Ref Doctor	: SELF

DEPARTMENT OF RADIOLOGY

X-RAY CHEST PA

Both lungs fields appear normal.

Both hila are normal.

Both costophrenic and cardiophrenic angles are normal.

The cardiac and mediastinal shadows appear normal.

Bones and soft tissues appear normal.

IMPRESSION : NORMAL STUDY.


DR VINOD JOSEPH DNB,DMRD
RADIOLOGIST

Printed on:30-11-2023 11:36

---End of the Report---

Patient Name : Mr Ramesh N T

Patient ID:248310

Age : 59Year(s)

Sex : Male

Referring Doctor : H/C

Date : 30.11.2023

ULTRASOUND ABDOMEN AND PELVIS

FINDINGS:

Liver is normal in size and shows increased echotexture. No biliary dilatation. No focal lesion
CBD is not dilated. **Portal vein** is normal in size, course and calibre.

Gall bladder is normal without evidence of calculi, wall thickening or pericholecystic fluid.

Pancreas to the extent visualized, appears normal in size, contour and echogenicity

Spleen is normal in size, shape, contour and echopattern. No evidence of mass or focal lesions.

Right Kidney is normal in size, position, shape and echopattern. Corticomedullary differentiation is maintained. No evidence of calculi or hydronephrosis.

Left Kidney is normal in size, position, shape and echopattern. Corticomedullary differentiation is maintained. No evidence of calculi or hydronephrosis.

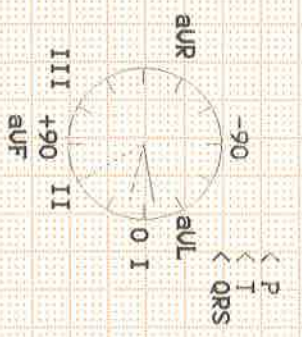
Urinary Bladder is well distended. Wall thickness is normal. No evidence of calculi, mass or mural lesion.

Prostate: normal in size and echotexture. There is no ascites.

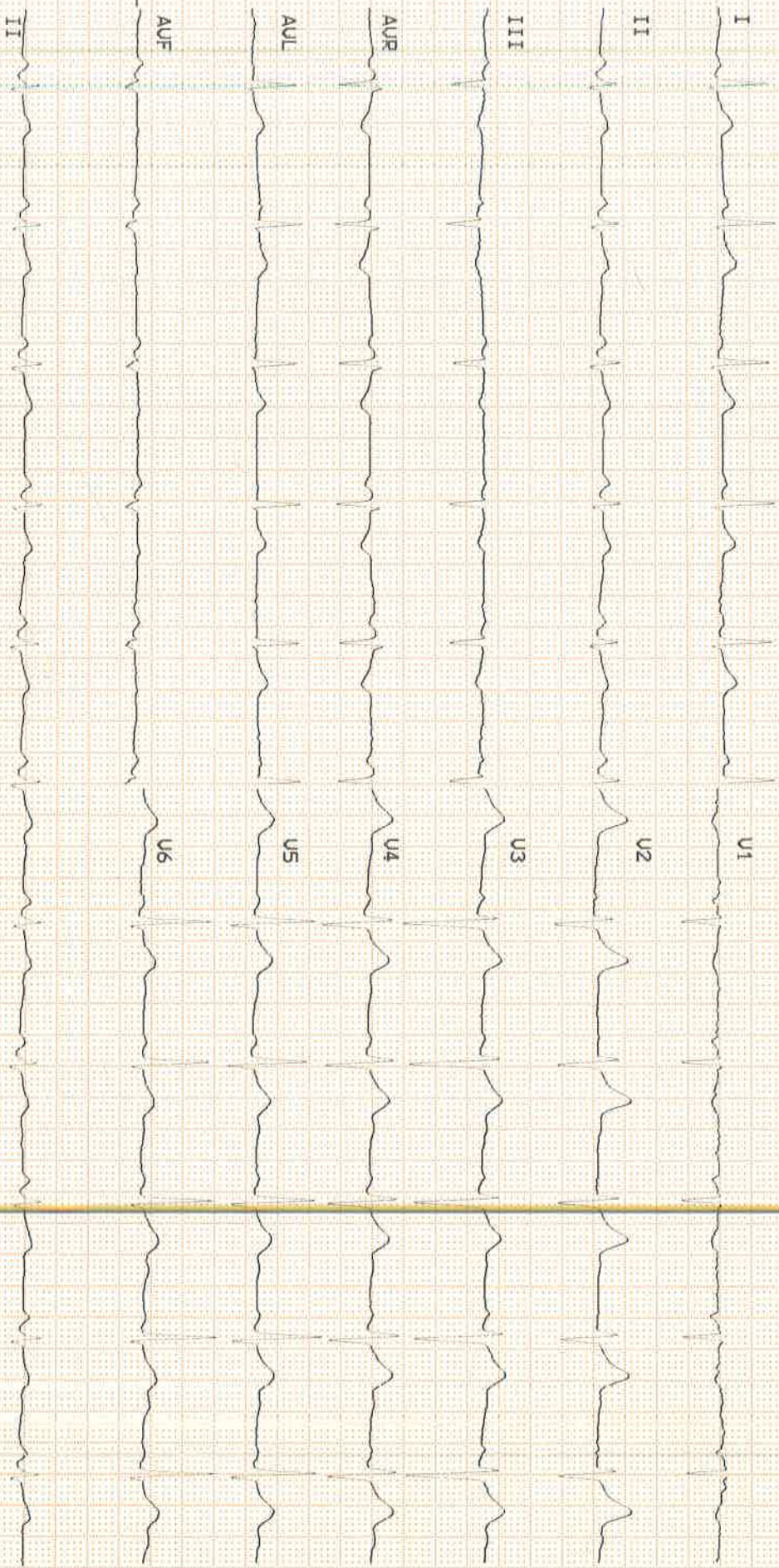
IMPRESSION: GRADE-I FATTY LIVER

DR VINOD JOSEPH DNB,DMRD
RADIOLOGIST

AGE: 59
 Measurement Results:
 QRS : 95 ms
 QT/QTcB : 396 / 420 ms
 PR : 142 ms
 P : 114 ms
 RR/PP : 890 / 890 ms
 P/ORS/T : 60 / -10 / 15 degrees
 QTd/QTcBd : 34 / 36 ms
 Sokolow : 1.7 mV
 NK : 9



Interpretation:



Unconfirmed report.

(Handwritten signature)

2019 10 26 10:00 AM GE MAC1200 ST 2019 10 26 10:00 AM 2019 10 26 10:00 AM

Patient Name : Mr. RAMESH N T
UHID : CKOR.0000248310
Reported By: : Dr. RAJENDRA NARAYAN SHARMA
Referred By : SELF

Age : 59 Y/M
OP Visit No : CKOROPV389785
Conducted Date : 30-11-2023 15:35

ECG REPORT

Observation :-

1. Normal Sinus Rhythm.
2. Heart rate is 67beats per minutes.
3. No pathological Q wave or S-T,T changes seen.
4. Normal P,Q,R,S,T waves and axis.
5. No evidence of chamber, hypertrophy or enlargement seen.


Impression:

NORMAL RESTING ECG.

Dr. RAJENDRA NARAYAN SHARMA
CONSULTANT

NOTE : KINDLY TAKE A PHOTOCOPY OF THE GRAPH
FOR FUTURE REFERENCE IF NEEDED.

----- END OF THE REPORT -----

Name : Mr. RAMESH N T	Age : 59 Y	UIID :CKOR.0000248310
	Sex : M	
Address : kml		OP Number :CKOROPV389785
Plan : ARCOFEMI MEDIWHEEL MALE AHC CREDIT PAN INDIA OP AGREEMENT		Bill No :CKOR-OCR-79254
		Date : 30.11.2023 08:58

Sno	Service Type/ServiceName	Department
1	ARCOFEMI - MEDIWHEEL - FULL BODY ANNUAL PLUS ABOVE 50Y MALE - 2D ECHO - PAN INDIA - FY2324	
1	URINE GLUCOSE(FASTING)	
2	GAMMA GLUTAMYL TRANFERASE (GGT)	
3	PROSTATIC SPECIFIC ANTIGEN (PSA TOTAL)	
4	HbA1c, GLYCATED HEMOGLOBIN	
5	2-D ECHO <i>R10</i>	
6	LIVER FUNCTION TEST (LFT)	
7	X-RAY CHEST PA <i>R11</i>	
8	GLUCOSE, FASTING	
9	HEMOGRAM + PERIPHERAL SMEAR	
10	ENT CONSULTATION <i>Dr. Wayne</i>	
11	FITNESS BY GENERAL PHYSICIAN	
12	DIET CONSULTATION <i>Vinodhini</i>	
13	COMPLETE URINE EXAMINATION	
14	URINE GLUCOSE(POST PRANDIAL)	
15	PERIPHERAL SMEAR	
16	ECG <i>R14</i>	
17	BLOOD GROUP ABO AND RH FACTOR	
18	LIPID PROFILE	
19	BODY MASS INDEX (BMI)	
20	OPHTHAL BY GENERAL PHYSICIAN	
21	RENAL PROFILE/RENAL FUNCTION TEST (RFT/KFT)	
22	ULTRASOUND - WHOLE ABDOMEN <i>R17 (2nd floor)</i>	
23	THYROID PROFILE (TOTAL T3, TOTAL T4, TSH)	
24	DENTAL CONSULTATION <i>R.No-15</i>	
25	GLUCOSE, POST PRANDIAL (PP), 2 HOURS (POST MEAL)	


(15) Dental
(20) Physio
optal

Height - 155cm
weight - 54.6kg

CERTIFICATE OF MEDICAL FITNESS

This is to certify that I have conducted the clinical examination of
Mr. RAMESH-N-T, 59/M on 02/12/2023 After reviewing the medical history and on
 clinical examination it has been found that he/she is

<ul style="list-style-type: none"> • Medically Fit • Fit with restrictions/recommendations <p>Though following restrictions have been revealed, in my opinion, these are not impediments to the job.</p> <p>1. -----</p> <p>2. -----</p> <p>3. -----</p> <p>However the employee should follow the advice/medication that has been communicated to him/her.</p> <p>Review after -----</p>	<input checked="" type="checkbox"/> Tick
<ul style="list-style-type: none"> • Currently Unfit. Review after ----- recommended • Unfit 	


 Dr. _____
 Medical Officer
 The Apollo Clinic (Location)

This certificate is not meant for medico - legal purposes.

Name: Mr. Ramesh
+ Mrs Vijayalakshmi
Age: 59yrs

Date: 2/12/23.

Height: 155cm	Weight: 54.6kg	BMI:	Waist Circum:
Temp:	Pulse:	Resp:	B.P:

General Examination / Allergies

History

Clinical Diagnosis & Management Plan

Early morning : 1 tsp of methi powder + 1 glass of luke warm water
empty stomach
7.00am.

7.30am. Coffee - 1 cup (without sugar).

Break fast Idli, dosa or ~~roti~~ or upma (dhalia) or millet)
8.00am. do's with mixed vegetables
drumstick
Sambhar 1/2 cup

Midmorning 1 cup of Buttermilk. or an apple
11.00am. or a pear or a guava.

Lunch : unpolished or millet + palak + Steamed
1.00pm. rice rice + Sambhar boiled
or indigenous 1/2 cup vegetables
rice variety 1/2 cup
+ curd 1/2 cup

4.00pm. Coffee - 1 cup
Without sugar

Follow up date:

Doctor Signature

Height :	Weight :	BMI :	Waist Circum :
Temp :	Pulse :	Resp :	B.P :

General Examination / Allergies

History

5:00pm - 1-2 tsp
to 6:00pm

Dinner
8:00pm

Bed time

Clinical Diagnosis & Management Plan

to mixed unsalted seeds such as
Pumpkin seeds, chia seeds, watermelon seeds
etc or sprout or groundnut ched + 1/2 cup
Same as lunch. Restrict white rice
and preparation.
1 scoop of D protein in water (1 cup)

Follow up date:

nimochini
Doctor Signature

HEALTH CHECK

Date : 02/12/2023.
MRNO :
Name : Mr. RAMESH-N-T
Age / Gender : 59/M

Department : GENERAL MEDICINE
Consultant : DR TOBY ABRAHAM THOMAS
Qualification : MBBS, DNB
KMC NO-74775
Consultation Timings: 6.00pm to 7.30pm

Height :	Weight :	BMI :	Waist Circum :
Temp :	Pulse :	Resp :	B.P : 130/70mmHg

General Examination / Allergies History

Clinical Diagnosis & Management Plan

O/E
Afebrile.
No Pallor/Icterus
Rx
C/S / W.D.

* T2DM ~ 20 yrs. on Zoryl M2 1-0-1
Lfo @ Bell's Palsy
C/o Numbness feet ~ 1 month.

FBS - 154
PPBS - 271
HbA1c - 9.7
TG - 409
LDL - 111
TSH - 1.56.
Urine Glu 4+
(PP)

Uncontrolled T2DM & Peripheral Neuropathy
Dyslipidemia

B12 - 526.
USG - Fatty liver.

[- Tab - ZORYL M2 1-0-1
- Tab - VILDAPHANE M 50/500 1-0-1
- Tab - ATORVA F10 0-0-1
- Tab - GABANEURON 100mg 0-0-1
x fo continue.

1 month Review : FBS/2hr-PPBS
Urine microalb.

Follow up date:


Doctor Signature